

## ORIGINAL PAPER

# Snake remedies and eosinophilic granuloma complex in cats

Ronit Aboutboul\*

*Animan Veterinary Clinic, Jabotinsky 1, Tel-Aviv 63479, Israel*

**Eosinophilic granuloma complex (EGC) is a syndrome occurring in cats, characterized by lesions affecting the skin and the oral cavity. Conventional treatment is mainly symptomatic and may have undesirable side effects. This paper summarizes homeopathic treatment with snake remedies of cats suffering from EGC. Snake remedies were chosen by individual repertorizations and administered in different dilutions. Reactions were mostly quick, leading to significant improvements, including complete recoveries. Homeopathy (2006) 95, 15–19.**

**Keywords:** homeopathy; veterinary homeopathy; eosinophilic granuloma; EGC; cats; snake remedies

## Introduction

During the last few years, in our veterinary practice, we have made interesting observations concerning the homeopathic treatment of a chronic skin syndrome in cats known as eosinophilic granuloma complex (EGC).

EGC includes three clinical entities characterized by various lesions affecting the skin and oral cavity of the cat.<sup>1–3</sup>

*Linear granuloma* or *eosinophilic granuloma* is a skin condition occurring mainly in young cats and presenting as erythematous, alopecic, well-circumscribed, linear lesions found mainly over the caudal thighs and in a nodular pattern in the oral cavity. Other sites include the bridge of the nose, chin, lips and paws. *Eosinophilic Plaque* is a well-circumscribed, raised, exudative lesion that is very pruritic and generally found over the abdomen or groin. *Eosinophilic Rodent Ulcer* is a well-circumscribed, ulcerated lesion most commonly found on the upper lip of the cat and is generally non-painful and non-pruritic.

Any combination of lesions, symptoms and locations can be observed in individual cases. Suspected aetiologies for EGC are numerous and varied. Under-

lying causes or predisposing factors include allergies (mainly to food, biting insects and inhaled substances, but also to parasites), infectious diseases, genetic predisposition and immune-mediated diseases, and in quite a few cases the cause is unknown. Diagnosis of EGC is based on history, physical symptoms, blood tests and histological findings. Full blood count may reveal peripheral eosinophilia associated with parasitic and allergic disorders. Skin biopsy is the most important diagnostic test, often confirming a suspected clinical finding. Specific histological patterns have been associated with the three clinical entities, all presenting tissue eosinophilia as a constant finding.

Conventional treatment is mainly symptomatic, aiming at controlling the suspected underlying infectious or parasitic agent or minimizing the allergic reaction with corticosteroid, antihistamine or hypsensitization therapies. These treatments do not usually cure the cat and may have undesirable side effects. Symptoms often recur if therapy is interrupted. Avoidance of allergenic factors is problematic too, since most of them exist naturally in the cat's environment. A chronic condition with a significant incidence in cats, EGC is a pathology that can cause major discomfort to the cat and upset their owners. Homeopathic treatment of EGC in cats is usually based, as in other chronic conditions, on repertorization and individual case taking leading to a specific matching remedy. In some cases, symptomatic remedies are also used.

\*Correspondence: Ronit Aboutboul, Animan Veterinary Clinic, Jabotinsky 1, Tel-Aviv 63479, Israel.

E-mail: [ronitvet@zahav.net.il](mailto:ronitvet@zahav.net.il)

Received 11 March 2005; revised 8 August 2005; accepted 5 September 2005

We first used homeopathic treatment for EGC at our clinic in the summer of 1996, when the first EGC case was referred to the clinic by the treating veterinarian, for homeopathic treatment. The patient, Swissa, a male cat aged 2 years, had been suffering from pruritic lesions from the age of 6 months. He had been treated regularly with corticosteroids since the symptoms had appeared. At the first consultation the cat seemed sad and nervous, presenting with a dull, thin fur and pruritic excoriations. The owner said that his cat had become sad because of the corticosteroid treatment, reacting more and more aggressively to the frequent injections he was receiving. The skin condition had not improved, which is the reason why an alternative treatment was considered.

A skin biopsy was performed and histological findings confirmed the suspicion of eosinophilic granuloma. After repertorization, *Lachesis* was selected. Treatment with that remedy brought a swift improvement of both skin lesions and the general condition of the cat. The owner "got back his old cat" as he termed it, the cat became happy and playful again and his fur became dense and lustrous. Several months later Swissa came back presenting with a singular, atypical symptom of swelling of one of his paws. The cat could not use the paw that had tripled in size(!). Treatment with the remedy *Crotalus cascavella* brought a quick and total recovery. This cat has been fine since, with no other symptoms.

A short time after Swissa was cured, another cat was brought to the clinic, also presenting with typical EGC symptoms. After repertorization, *Lachesis* was given again and the symptoms disappeared swiftly. These two cases of quick and lasting recoveries raised some questions and thoughts concerning snake remedies and EGC, ie the possibility that other eosinophilic granuloma cases would respond well to snake remedies because of the similarities in symptoms. This assumption was, from then on, always taken into account when treating cases of confirmed or suspected EGC in cats, even though individual repertorizations were done in most cases.

## Methods and remedies

Over a period of 8 years, 20 EGC cases were seen at our clinic; of these 15 were recorded. All were treated with homeopathic snake remedies. The cats were all young adults, 70% males and 30% females. The first EGC symptoms appeared at ages ranging from several

months to 2 years old. Diagnosis of EGC was based on the clinical observation of characteristic dermatological lesions and usually confirmed by biopsy.

Most snake remedies were chosen through repertorization, using the RADAR program.<sup>4</sup> Symptoms for repertorizations of EGC cases were chosen from several sections of the repertory, usually Mind symptoms accompanied by local characteristic symptoms of Mouth, Face, Skin and Extremities.

In each case, five to seven individual symptoms were chosen.

## Results

Out of the 15 recorded cases, medication was refused by the owner in one case, three were lost to follow-up (owners discontinuing contact or treatment) and one did not improve (treatment discontinued after several weeks). Ten cats were cured.

The remedies used were *Lachesis* (9 cases), *Crotalus cascavella* (1 case), *Crotalus horridus* (1), *Cenchrus contortrix* (1), *Elaps corallinus* (1), *Naja* (1) and *Vipera* (1). In the two cases where *Lachesis* was replaced by a second snake remedy, only the second is counted here. The remedies were given in various centesimal (12CH to 30CH) and LM dilutions, in varying frequencies, according to the dynamics of each case. Follow-ups were conducted every 1 to 6 months.

Out of the 11 cases of which we have follow-ups, amelioration of clinical condition was achieved with the first snake remedy in eight. In two cases, the first remedy, *Lachesis*, was replaced by a second snake remedy; no case required a third remedy to achieve full cure. In one case, the snake remedy *Crot-horr* was given after *Lycopodium*, thus achieving cure (medication repetition is depicted in Table 1).

In the cured cases, effect of the remedy was noted early on in the treatment, in the first 2 weeks, and symptoms completely disappeared in a period ranging from 2 weeks to 3 months. In two of the cases, symptoms tend to reappear periodically, with stress (anaesthesia, vaccinations, long absences of the owners, etc) and disappear again with or without administration of the remedy. In one case only, despite good cooperation of the owners for several weeks, the treatment was discontinued because of lack of response (time schedule for improvement is depicted in Figure 1).

All the cats treated with homeopathy presented typical local EGC symptoms (Table 2). Their local

**Table 1** Outcome in 15 cases of EGC in cats

Lost to follow-up		No response	Good response (cure)			
4		1	10			
Did not take	Remedy given once—lost to follow-up	Remedy given once	Remedy changed	Remedy repeated	Remedy given once	
1	3	1	2	2	6	

The numbers denote no. of cases.

homeopathic symptoms chosen for repertorization surprisingly brought to the forefront various snake remedies (Table 2). Although local symptoms played an important role in repertorizations of the EGC cats, MIND symptoms, as well as a few GENERALS, were also used in the case taking (Table 3). The frequency of snake remedies in all the chapters used for repertorizations of EGC cases is visualized in Table 4.

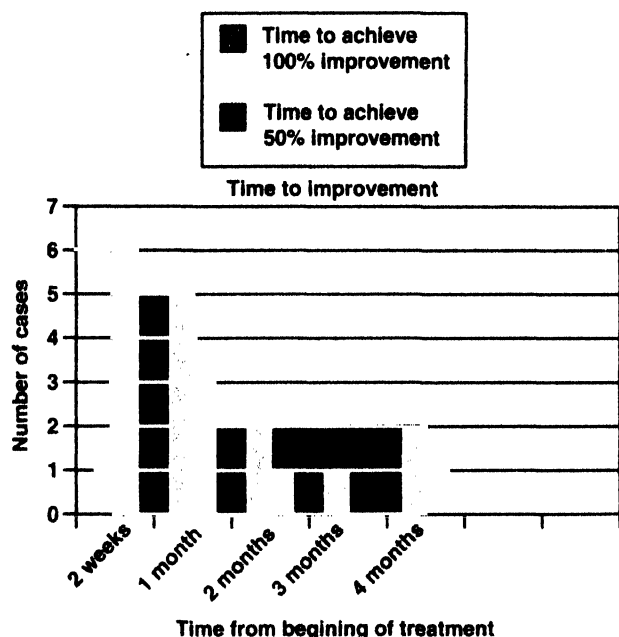


Figure 1. Time to achieve 50% and 100% improvement.

Table 3 Mind and general symptoms chosen for repertorizations

Symptoms in repertory	Frequency of use of symptom in repertorizations
<b>MIND</b>	
ACTIVITY—Desire	1
AFFECTIONATE	1
COMPANY—aversion to	1
COMPANY—desire for	3
CONTRADICTION—intolerant of contradiction	1
CURIOUS	2
DICTATORIAL	1
EXERTION—Physical—desire	2
HIDING—himself	3
JEALOUSY	1
OBSTINATE	2
PLAYFUL	2
POSITIVENESS	1
REPROACHING others	1
RESERVED	2
RESTLESSNESS	1
SENSITIVE—Noise to	2
STARTING, startled—easily	1
TOUCHED—aversion to, being	2
TIMIDITY	2
VIOLENT	1
<b>GENERALS</b>	
FOOD and DRINKS—farinaceous—desire	1
FOOD and DRINKS—milk—desire	1
RUBBING—amel	1
SIDE—left	1
VACCINATION, after	1

Table 2 Comparison of symptoms of EGC cases and snake remedies

Symptoms of EGC in cats	Corresponding symptoms in the repertory	Matching snake remedies in repertory*	Frequency of use of symptom in repertorizations
<b>Skin lesions:</b>	<b>SKIN—</b>	<i>cench. Crot-h. Lach.</i>	2
● Linear, alopecic, erythematous, well-circumscribed lesions on caudal region of thighs, usually pruritic	ITCHING	<i>Lach</i>	1
● Alopecic lesions on various parts of the body (abdomen, back ...), sometimes accompanied by erythema and pruritus	ITCHING—scratching-raw; must scratch until it is ITCHING—violent EXCORIATION—scratching; after-must scratch it raw ERUPTIONS—herpetic ERUPTIONS—herpetic-corrosive ERUPTIONS—itching	<i>lach</i> <i>Lach</i> <i>crot-h. lach.</i> <i>lach</i> <i>Lach</i>	1 4 1 1 1
<b>Mouth lesions:</b>	<b>MOUTH—</b>	<i>Crot-c. crot-h. LACH.</i>	1
● Ulcerated lesions localized on lips, gums or around the mouth	ULCERS	<i>Crot-c. Lach.</i>	1
● Swelling of lips	ULCERS—Gums SWELLING SWELLING—Gums <b>FACE—SWELLING—Lips—upper</b>	<i>vip.</i> <i>Crot-h. LACH. Naja</i> <i>Crot-h. Lach</i>	1 1 1
<b>Foot and pad lesions:</b>	<b>EXTREMITIES—</b>	<i>crot-h, lach, vip</i>	1
● Swelling of the foot, sometimes up to double or triple size ...	SWELLING	<i>crot-c. crot-h. elaps, Lach, naja, vip.</i>	1
● Erythematous, usually very pruritic lesions between the foot pads	SWELLING—Hand SWELLING—Foot ERUPTIONS—Hand ERUPTIONS—Foot ERUPTIONS—Lower limbs	<i>Cench.crot-h. elaps</i> <i>Lach. naja vip.</i> <i>Lach</i> <i>Crot-c. lach</i> <i>Crot-c. elaps lach.</i>	2

\*Intensity of symptoms is denoted by type of letters (as in the Radar program): 1—lach.; 2—Lach.; 3—LACH.

**Table 4** Frequency of snake remedies in the repertorizations of EGC cases

Remedy	MIND	SKIN	EXTREMITIES	MOUTH	FACE	GENERALS
<i>Cenchrus</i>	4	1	1			
<i>Crot-c</i>	7		3	2		1
<i>Crot-h</i>	5	2	3	2	1	2
<i>Elaps</i>	6		4			1
<i>Lachesis</i>	20	7	6	4	1	3
<i>Naja</i>	5		2	1		1
<i>Vipera</i>	2		3	1		1

Two other snake remedies came up in these repertorizations but were not prescribed: *Bothrops lanceolatus* and *Toxicophis pugnax*.

## Clinical case

Ella, a female cat aged 2.5 years, was brought to the clinic in April 2003, for homeopathic treatment of EGC symptoms from which she had been suffering since the age of 6 months. The symptoms included itching, red lesions between the footpads, erythematous alopecic lesions over the caudal thighs (see Figure 2a), thinning of fur on the abdomen (due to constant licking of the area by the cat), ulcers on the lower lip and alternating swellings of the paws. She was being treated with corticosteroid injections every 1-2 months, whenever these symptoms aggravated.

Symptoms taken for repertorization were the following:

MIND - COMPANY - aversion to

MIND - AFFECTIONATE

MIND - REPROACHING others

SKIN - EXCORIATION - scratching; after - must scratch it raw

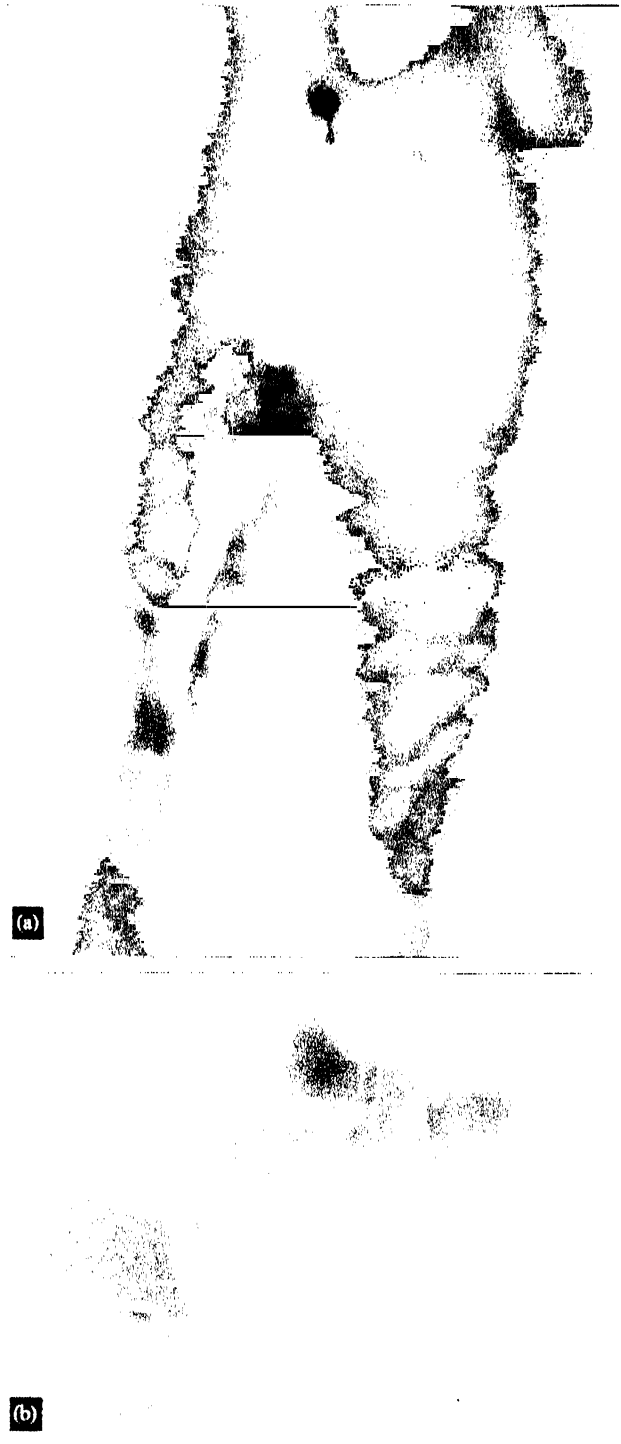SKIN - ERUPTIONS - itching

EXTREMITIES - SWELLING - hand

*Vipera* 30CH, once a day for 3 days was prescribed. Ella started improving immediately, and 2 months later, with a few repetitions of the remedy, all the lesions were healing well and fur was growing on the afflicted areas (see Figure 2(b)). 1.5 years later, she was well. Slight symptoms appear occasionally, usually disappearing spontaneously or with just one dose of the remedy. She was last examined in the summer of 2004, presenting with slight erythema on the caudal region of the right thigh, and was given *Vipera* 30CH once and the symptoms disappeared in a few days.

## Summary

As this case illustrates, most of the EGC cases treated homeopathically at the clinic respond well to snake remedies. The dilution and frequency of repetition vary from case to case. Duration of treatment varies from several weeks to months or years, the aim being complete cure and disappearance of all the symptoms. In some cases that result is achieved, in other cases the specific remedy has to be repeated sporadically, at months' intervals, when owners suspect early symptoms or when stressful situations



**Figure 2.** (a) Eosinophilic granuloma on thighs—before treatment. (b) Eosinophilic granuloma on thighs—after treatment.

occur. Although food allergies are in the list of suspected aetiologies for EGC, usually no specific diet is given to the cats treated at our clinic, except for rare cases when such a diet is chosen specifically by the owners.

## Discussion

Each of the cats diagnosed with EGC at the clinic was treated with a remedy chosen through individual repertorization. However, the high incidence of snake remedies in the first successful cases encouraged us to choose remedies of the same family in the cases that followed. In light of the accumulated experience of successfully treating EGC cats with snake remedies, as presented above, a few questions must be put forward:

Why do homeopathic snake remedies act specifically on EGC?

Why does a rather small, specific, well-defined group of remedies bring a cure in most cases presenting with the same pathology, albeit differing in character, history and even in local symptoms?

Cases differ not only by the localization, intensity and modalities of their symptoms but also in the dynamics of the healing process; yet nearly all responded well to snake remedies. All the repertorizations suggested snake remedies, and in one case, where a different remedy was given first, with no success, cure was achieved on changing the remedy to a snake remedy.

*How do snake remedies affect EGC in cats?*

How do they relate? What is common to snake venom and the characteristic pathology of EGC?

All snake remedies obviously present symptoms that are caused by snakebites; some of these symptoms, such as ulcerated lesions, excoriations and swellings

affecting skin, mouth and extremities, are also characteristic of EGC. Interestingly, in conventional medicine, snake venoms are used in autoimmune syndromes, such as Lupus, for their anticoagulant properties.

Still, it is important to note that, while focusing on the similarities between snake remedies and EGC on the physical level, the mental symptoms cannot be ignored since MIND symptoms were taken into account in all of the repertorizations. Can this remedy—syndrome relation be found in other pathologies? How can this information be put to use in homeopathy? Do these observations open new pathways to cure?

The answers to these questions may be complex and uncertain, but the observation and research of accidental findings such as these can lead us homeopaths and physicians towards new understandings considering the concepts of sickness and cure in homeopathy.

## Acknowledgements

I thank Dr Michal Yakir and Tamar Almog.

## References

- 1 Birchard SJ, Sherding RG. *Saunders Manual of Small Animal Practice*. Philadelphia: WB Saunders, 1994 pp 341-344.
- 2 Harvey RG, McKeever PJ. *Colour Handbook of Skin Diseases of the Dog and Cat*. London: Manson Publishing Ltd, 1998.
- 3 Melman SA. *Skin Diseases of Dogs and Cats*. Dermapet, 1994.
- 4 RADAR 7 & 8—homeopathic repertorization program. Archibel, Belgium.