

27-6-2024

Individualised homoeopathic treatment for pilonidal sinus: A case report

Sumit Paliwal

Department of Practice of Medicine, Nehru Homoeopathic Medical College, New Delhi, India, drsumitpaliwal@gmail.com

Laijun Nahar

Regional Research Institute of Homoeopathy, Agartala, Tripura, India, laijun786@gmail.com

Rachna Paliwal

AYUSH vertical, Central Drugs Standard Control Organisation, Delhi, India, rachna.paliwal@nic.in

Author(s) ORCID Identifier:

<https://orcid.org/0000-0002-2127-3310>

Follow this and additional works at: <https://www.ijrh.org/journal>

 Part of the [Homeopathy Commons](#)

How to cite this article

Paliwal S, Nahar L, Paliwal R. Individualised homoeopathic treatment for pilonidal sinus: A case report. Indian J Res Homoeopathy 2024;18:133-139

This Case Report is brought to you for free and open access by Indian Journal of Research in Homoeopathy. It has been accepted for inclusion in Indian Journal of Research in Homoeopathy by an authorized editor of Indian Journal of Research in Homoeopathy. For more information, please contact ijrhonline@gmail.com.



Individualised homoeopathic treatment for pilonidal sinus: A case report

Abstract

Introduction: Pilonidal sinus is a very common inflammatory disease of the gluteal region. The most common site of occurrence is the natal cleft. It can cause discomfort, absence from work and social embarrassment. There is no single, widely accepted therapy available for this condition. In most cases, the treatment option for this disease is surgical intervention, but recurrences following surgery are common. **Case Summary:** A 15-year-old male patient reported discharge from the sinus cavity in the natal cleft along with pain and discomfort. *Nitric acid*, a homoeopathic medicine, was prescribed during the initial consultation and the patient was followed up for four months at regular intervals. The Visual Analog Scale and the Outcome Related to the Impact on Daily Living (ORIDL) scale were used to assess the patient's subjective improvement. The signs of objective improvement were documented through photographs. The score for Modified Naranjo Criteria for Homoeopathy (MONARCH) was +8, which supports the causal attribution of the individualised homoeopathic medicine *Nitric acid* to the success of this case.

Acknowledgments and Source of Funding

Acknowledgment: The authors gratefully acknowledge the patient and his parents for their active co-operation and participation. **Financial support:** None

Individualised homoeopathic treatment for pilonidal sinus: A case report

Sumit Paliwal¹, Laijun Nahar^{2*} , Rachna Paliwal³

¹Department of Practice of Medicine, Nehru Homoeopathic Medical College, New Delhi, India, ²Regional Research Institute of Homoeopathy, Agartala, Tripura, India, ³AYUSH Vertical, Central Drugs Standard Control Organisation, Delhi, India

Abstract

Introduction: Pilonidal sinus is a very common inflammatory disease of the gluteal region. The most common site of occurrence is the natal cleft. It can cause discomfort, absence from work and social embarrassment. There is no single, widely accepted therapy available for this condition. In most cases, the treatment option for this disease is surgical intervention, but recurrences following surgery are common. **Case Summary:** A 15-year-old male patient reported discharge from the sinus cavity in the natal cleft along with pain and discomfort. *Nitric acid*, a homoeopathic medicine, was prescribed during the initial consultation and the patient was followed up for four months at regular intervals. The Visual Analog Scale and the Outcome Related to the Impact on Daily Living (ORIDL) scale were used to assess the patient's subjective improvement. The signs of objective improvement were documented through photographs. The score for Modified Naranjo Criteria for Homoeopathy (MONARCH) was +8, which supports the causal attribution of the individualised homoeopathic medicine *Nitric acid* to the success of this case.

Keywords: Homoeopathy, Individualisation, *Nitric acid*, Pilonidal sinus

INTRODUCTION

Pilonidal sinus is an infection of the natal cleft that occurs beneath the skin. In healthy young adults, pilonidal illness is a frequent cause of morbidity and reduced productivity.^[1] Simple cysts, acute abscesses with or without cellulitis and chronic draining sinuses are the common manifestations of pilonidal illness.^[2]

Pilonidal sinus is a fairly prevalent anorectal issue that most frequently affects the hair follicles in the natal cleft of the sacrococcygeal region.^[3] Data suggests a predominantly male prevalence, with a ratio of 4:1 affected males to females.^[4] Due to their hirsute nature, men are believed to be at a higher risk.^[3] It typically affects men between the ages of 15 and 30.^[5] It happens infrequently beyond the age of 45.^[6] The likelihood of developing pilonidal illness increases after puberty, and factors such as genetic predisposition (38%), local trauma (34%), being overweight (37%) and obesity (13%) are likely to play a role. In around 50% of patients, it presents as an acute abscess or as a painful oozing sinus.^[4]

For pilonidal sinus (PNS), a variety of conventional therapeutic approaches are employed including incision and drainage,

excision with primary closure, cryosurgery, phenol application, excision with open packing, excision with marsupialisation and most recently, flap surgery. However, the high likelihood of recurrence, the high rate of infection and the loss of productive work hours have rekindled interest in finding the best course of intervention.^[6-8] Therefore, it is important to assess the role of affordable, well-accepted and alternative management strategies for this condition.

To avoid invasive intervention, many PNS sufferers choose homoeopathic treatment as a potential alternative mode of treatment, but their successful results in the form of case reports are not thoroughly documented. In this case, subjective as well as objective symptoms were systematically documented; the treatment outcome was assessed through validated scales such as VAS and Outcome Related to the Impact on Daily Living (ORIDL) and causal attribution was done using Modified

***Address for correspondence:** Laijun Nahar,
Regional Research Institute of Homoeopathy,
Agartala 799045, Tripura, India.
E-mail: laijun786@gmail.com

Received: 10 July 2023; **Accepted:** 6 June 2024

Access this article online

Quick Response Code:



Website:
www.ijrh.org

DOI:
10.53945/2320-7094.1917

This is an open access journal, and articles are distributed under the terms of the Creative Commons Attribution-NonCommercial-ShareAlike 4.0 License, which allows others to remix, tweak, and build upon the work non-commercially, as long as appropriate credit is given and the new creations are licensed under the identical terms.

How to cite this article: Paliwal S, Nahar L, Paliwal R. Individualised homoeopathic treatment for pilonidal sinus: A case report. *Indian J Res Homoeopathy* 2024;18:133-139.

Naranjo Criteria for Homeopathy (MONARCH).^[9-11] The Visual Analog Scale (VAS) is a validated, subjective measure for acute and chronic pain. The VAS consists of a 10 cm line, with two endpoints representing 0 ('no pain') and 10 ('pain as bad as it could possibly be').^[9]

The ORIDL scale records the assessment of response to the previous prescription on the main complaint as well as on general well-being on a numerical scale of -4 to +4.^[10]

In this case, MONARCH^[11] was used to find the possible causal attribution between the homoeopathic intervention and clinical improvement of the patients. The case has been reported as per the HOM-CASE guidelines.^[12]

PATIENT INFORMATION

On 22nd November 2022, a 15-year-old male student presented with the complaint of discharge from a cavity in the natal cleft along with pain and discomfort [Figure 1].

He had been suffering from continuous pain and discomfort with mild discharge from the anorectal region for two years and had consulted with an allopathic physician. He was diagnosed as a case of PNS on 17 February 2022 and was advised to go for a magnetic resonance imaging (MRI) fistulogram, which reported it to be a case of PNS. He underwent excision of the PNS with Limberg flap under general anaesthesia on 21 February 2022. After three months of the surgery, his symptoms began to recur. After that, he again took conservative conventional treatment, but his complaints did not improve. He then ultimately chose to seek homoeopathic treatment.

He did not suffer from any major illnesses in the past. His mother had allergic rhinitis. His younger brother also had a history of PNS. He was a student and belonged to an upper-middle-class background.

Clinical findings

General examination

The blood pressure of the patient was found to be 120/80 mmHg and his pulse was 90/min. Nothing abnormal was detected in his general condition, except mild pallor.

Local examination

On inspection, a pit-like cavity with a well-defined, ovoid-shaped margin was observed at the natal cleft. The surrounding skin was erythematous [Figure 1] but exhibited no swelling. There was a serosanguineous discharge from the cavity. On palpation, the cavity was notably tender. Induration was present around the cavity, along with fibrosis, likely due to a history of previous surgical intervention. No fluctuation was noted. The size of the cavity was approximately 6 cm × 3 cm × 3 cm. Associated findings included the absence of signs of infection, such as fever, chills or malaise and no inguinal lymph node enlargement was detected.

Generals

His appetite was good, with a strong desire for salty and fatty food. He drank 2.5–3 L of water daily, and his tongue was

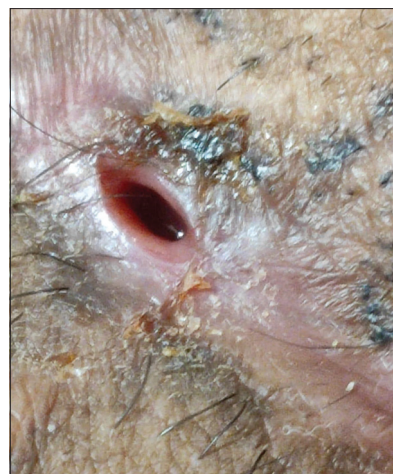

Figure 1: Pilonidal Sinus opening as seen during the first visit (22 November 2022)

moist. The patient reported moderate sweating all over the body, which was very offensive but left no stain on the clothes. His bowel movements were regular and satisfactory. The urine was normal in colour but very offensive. His thermal reaction was chilly, and there were no complaints related to his sleep. The patient was very irritable, and little things annoyed him. He used to get angry easily, followed by throwing things here and there. His memory was good.

Diagnostic assessment

The case was diagnosed to be of PNS through MRI fistulogram.

Therapeutic intervention

The following characteristic symptoms were considered for framing the totality:

- Irritable
- Angered easily
- Desire for salty things
- Desire for fatty food
- Chilly patient
- Offensive perspiration
- Offensive urine
- Fistulous opening hip
- Discharge mixed with blood from PNS cavity.

After evaluation of the case, a repertorial totality was constructed, followed by repertorisation done with the help of the Repertory of J.T. Kent by Radar Opus 3.0.16 software^[13] [Figure 2].

On the basis of the repertorial result and final consultation with materia medica,^[14,15] individualised, single homoeopathic medicine, *Nitric acid* was selected and prescribed in the 50 millesimal potency (LM scale), starting from 0/1, to be taken daily, once a day, in the morning on an empty stomach for 15 days, followed by 0/2 for the next 15 days in a similar manner. One globule of poppy seed size was mixed with 100 ml of distilled water, and 12 drops of rectified spirit were added to the medicine bottle. Before taking the medicine, 10 strokes were given to the medicine bottle, and then, one tablespoon

of medicine was dissolved in half a cup of water, followed by stirring. From this solution, one tablespoon was to be taken and the rest to be discarded. The patient was also instructed to keep the affected area clean and maintain personal hygiene. The medicines were prescribed for a limited duration as per the need and were followed by placebo pills for the rest of the period.

Follow-up and outcomes

The patient was monitored and treated for over 4 months. The changes observed in symptoms and indications, as well as medication administered at each consultation, are detailed in Table 1.

A series of photographs were used to document the outcome [Figures 1, 3a-d, 4].

As a validated tool, the VAS and the ORIDL scale were used to assess the patient’s perception of the outcome and how those

had influenced his way of life.^[9,10] The patient was requested to record the ORIDL score for his primary complaint and overall well-being at each follow-up. The ORIDL score for both aspects was +4 at the conclusion of the 4-month period [Table 1]. VAS score was used for the assessment of pain. At every follow-up visit. the patient, and at the end of treatment, the score fell from six to zero [Table 1]. In every follow-up consultation, the patient was questioned regarding timely consumption of medicine as per the prescribed dose and compliance with additional limitations. The patient reported to have complied with the advice and had no concerns regarding his tolerance for the intervention. No negative or unexpected events were reported during the entire period that the patient received homoeopathic care.^[16] In addition, he did not refer to any initial deterioration of his pre-existing issues or any other concerns that would have pointed to a homoeopathic aggravation.^[17,18]

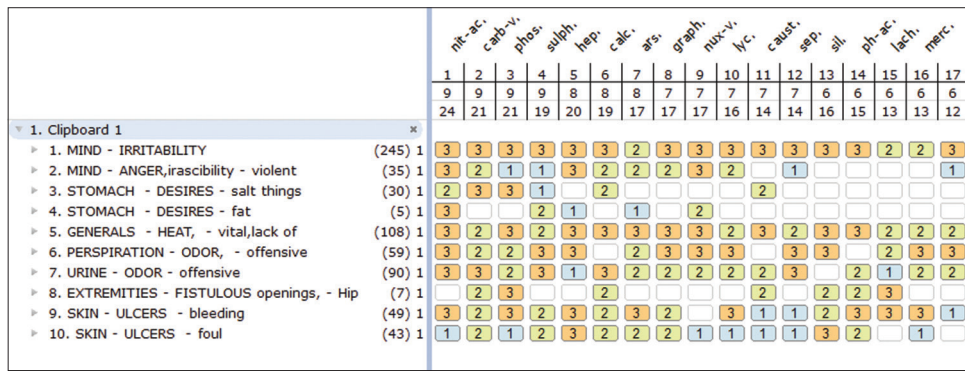


Figure 2: Repertorisation chart

Table 1: Follow-up details					
Date	Signs and symptoms	Prescription	VAS scores	ORIDL	
				MC	OWB
1 st visit, 22 November 2022 Figure 1	Irritable, Angered easily. Desire for salty fatty food, Chilly patient, Offensive perspiration, Offensive urine, Fistulous opening in the natal cleft, Discharge mixed with blood from PNS cavity.	<i>Nitric acid</i> 0/1 to be taken daily, once a day, in the morning on an empty stomach for 15 days, followed by <i>Nitric acid</i> 0/2 for the next 15 days in a similar manner.	6	NA	NA
1 st FU, 24 December 2022 Figure 3a	Cavity size decreased, discharge reduced and pain decreased.	<i>Nitric acid</i> 0/3 to be taken daily, once a day, in the morning on an empty stomach for 15 days, followed by <i>Nitric acid</i> 0/4 for the next 15 days in a similar manner.	3	+2	+2
2 nd FU, 25 January 2023 Figure 3b	No discharge, slight pain present, cavity almost healed, the offensive smell of sweat reduced.	<i>Nitric acid</i> 0/5 to be taken daily, once a day, in the morning on an empty stomach for 15 days, followed by <i>Nitric acid</i> 0/6 for the next 15 days in a similar manner.	2	+3	+3
3 rd FU, 22 February 2023 Figure 3c	No pain, no discharge, the offensive smell of urine disappeared and offensive perspiration was greatly reduced.	<i>Nitric acid</i> 0/7 to be taken daily, once a day, in the morning on an empty stomach for 15 days, followed by <i>Nitric acid</i> 0/8 for the next 15 days in a similar manner.	1	+3	+3
4 th FU, 20 March 2023 Figure 3d	All the complaints were relieved.	No medicine was prescribed as improvement continued.	0	+4	+4
5 th FU, 17 October 2023	There were no recurrences of old complaints; all the generals were normal and the physician advised the patient to visit the clinic every 3 months to check for recurrences of pilonidal sinus [Figure 4].				

FU: Follow-up, VAS: Visual Analog Scale, ORIDL: Outcome related to the impact on daily living, MC: Main complaint, OWB: Overall well-being, NA: Not applicable

Table 2: Assessment by Modified Naranjo Criteria for Homoeopathy

S. No.	Domains	Yes	No	Not sure/NA
1	Was there an improvement in the main symptom or condition for which the homeopathic medicine was prescribed?	+2		
2	Did the clinical improvement occur within a plausible timeframe relative to the medicine intake?	+1		
3	Was there a homeopathic aggravation of symptoms?		0	
4	Did the effect encompass more than the main symptom or condition (i.e., were other symptoms, not related to the main prescribing complaint, improved or changed?)	+1		
5	Did overall well-being improve (suggest using a validated scale)?	+1		
6	A. Direction of cure: did some symptoms improve in the opposite order of the development of symptoms of the disease? B. Direction of cure: did at least one of the following aspects apply to the order of improvement of symptoms: -from organs of more importance to those of less importance -from deeper to more superficial aspects of the individual -from the top downwards		0	0
7	Did 'old symptoms' (defined as non-seasonal and non-cyclical symptoms that were previously thought to have resolved) reappear temporarily during the course of improvement?		0	
8	Are there alternative causes (other than the medicine) that – with a high probability – could have produced the improvement? (consider a known course of disease, other forms of treatment and other clinically relevant interventions)		+1	
9	Was the health improvement confirmed by any objective evidence? (e.g., investigations, clinical examination, etc.)	+2		
10	Did repeat dosing, if conducted, create similar clinical improvement?			0

Total score=+8 (Maximum score=+13, minimum score=-6)

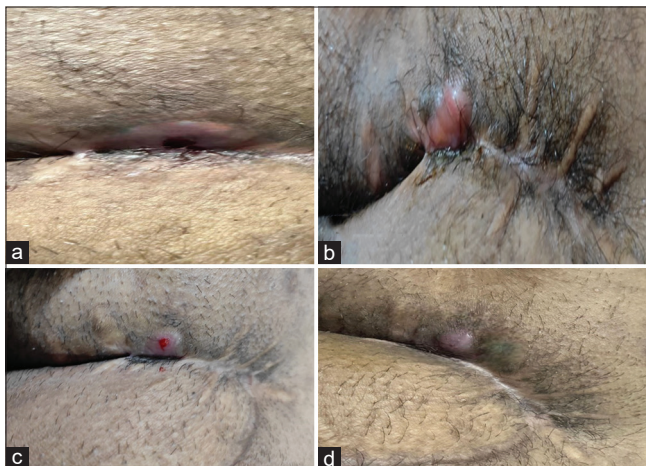


Figure 3: During treatment (a) The sinus cavity is seen to be reduced in appearance and discharge during the second visit (24 December 2022); (b) The cavity is seen to be further reduced during the third visit (25 January 2023); (c) The cavity is seen to be healed with bare minimum discharge during the fourth visit (22 February 2023); (d) A small nodule is seen as a result of completely healed cavity with no discharge during the fifth visit (20 March 2023)

The MONARCH, a causal attribution evaluation tool, was used to evaluate whether there was a causal relationship between the homoeopathic intervention and the outcome of the treatment.^[11] The results for each of the ten MONARCH domains are shown in Table 2, which totals +8 on a scale of ‘-6–+13.’

DISCUSSION

Since PNS is a common inflammatory disease of the gluteal region,^[5] with a limited scope of treatment in conventional medicine, it is necessary to assess the role of alternative strategies to reduce recurrence and enhance acceptability for treatment of such apparent surgical conditions. Homoeopathy

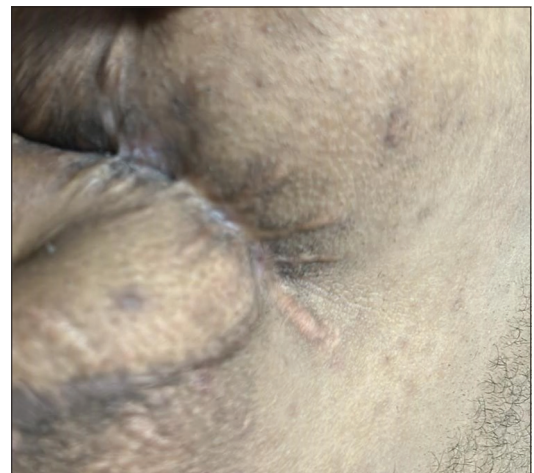

Figure 4: After treatment: The sinus is seen to be totally cleared up during the sixth visit (17 October 2023)

is currently the second most prevalent form of medical care in India. Thirty-one percent of the population exclusively uses Homoeopathy for health care.^[19] In this case, the patient had been taking conventional treatment for PNS for two years and even got it treated surgically. However, after surgery, the symptoms recurred within three months, which was subsequently healed completely with Homoeopathy in just four months. If Homoeopathy can be proven to treat PNS without the need for surgery through evidence-based trials, it will give patients a reliable choice for a non-invasive and cost-effective therapy. There is a scarcity of published case reports in this regard, even though one case report of PNS successfully treated by homoeopathic medicine with the integration of ayurvedic treatment has been documented.^[20]

In this chronic case, the medicine was given in LM potency so that frequent repetition could be done and quick recovery could

be achieved in this chronic case. This case report provides evidence of the patient's improvement through both subjective and objective changes, measured through VAS and ORIDL. At every follow-up, the patient enquired about the pain, the overall effect of the treatment on his major complaint and his general sense of well-being. The VAS score changed from six to zero during the treatment and his ORIDL score for both aspects was +4, indicating that he had returned to normal [Table 1]. On examination at the end of the treatment, no discharge was seen, and the cavity of the PNS had completely healed. The photograph of the natal cleft also showed a normal appearance [Figure 4]. The final MONARCH score was +8, indicating a correlation between the intervention and the outcome [Table 2].

This case study supports the use of homoeopathy in the treatment of PNS without the use of topicals or side effects.

CONCLUSION

The purpose of this case report is to demonstrate the beneficial effects of homeopathy in treating PNS, thus negating the need for any surgery. The photographs are a record of the patient's status and improvement. However, it would not be appropriate to generalise this outcome on the basis of this single case. Hence, rigorous trials are suggested to ascertain the result reported here.

Declaration of patient consent

The authors have obtained written, informed consent from the patient's parents, upon the patient's verbal assent, to publish his case records and photographs in a scientific journal without revealing the identity of the patient.

Financial support and sponsorship

Nil.

Conflict of interest

None declared.

REFERENCES

1. Khanna A, Rombeau JL. Pilonidal disease. *Clin Colon Rectal Surg* 2011;24:46-53.
2. Humphries AE, Duncan JE. Evaluation and management of pilonidal disease. *Surg Clin North Am* 2010;90:113-24.
3. Cherkasov MF, Galashokyan KM, Startsev YM, Cherkasov DM, Melikova SG. Comparative study of treatment methods of pilonidal sinus. *New Armen Med J* 2016;10:61-5.
4. Bradley L. Pilonidal sinus disease: A review. Part one. *J Wound Care* 2010;19:504-8.
5. Isik A, Idiz O, Firat D. Novel approaches in pilonidal sinus treatment. *Prague Med Rep* 2016;117:145-52.
6. Spyridakis M, Christodoulidis G, Chatzitheofilou C, Symeonidis D, Tepetes K. The role of the platelet-rich plasma in accelerating the wound-healing process and recovery in patients being operated for pilonidal sinus disease: Preliminary results. *World J Surg* 2009;33:1764-69.
7. McCallum I, King PM, Bruce J. Healing by primary versus secondary intention after surgical treatment for pilonidal sinus. *Cochrane Database Syst Rev* 2007;4:CD006213.
8. Keshava A, Young CJ, Rickard MJ, Sinclair G. Karydakis flap repair for sacrococcygeal pilonidal sinus disease: How important is technique? *ANZ J Surg* 2007;77:181-3.
9. Couper MP, Tourangeau R, Conrad FG, Singer E. Evaluating the effectiveness of visual analog scales: A web experiment. *Soc Sci Comput Rev* 2006;24:227-45.
10. Reilly D, Mercer SW, Bikker AP, Harrison T. Outcome related to impact on daily living: Preliminary validation of the ORIDL instrument. *BMC Health Serv Res* 2007;7:139.
11. Lamba CD, Gupta VK, Van Haselen RA, Rutten L, Mahajan N, Molla AM, *et al*. Evaluation of the modified Naranjo Criteria for assessing causal attribution of clinical outcome to homeopathic intervention as presented in case reports. *Homeopathy* 2020;109:191-7.
12. Van Haselen RA. Homeopathic clinical case reports: Development of a supplement (HOM-CASE) to the CARE clinical case reporting guideline. *Complement Ther Med* 2016;25:78-85.
13. RADAR 10. Archibel Homoeopathic Software. Belgium: RADAR; 2009.
14. Boericke W. *New Manual of Homoeopathic Materia Medica with Repertory*. 3rd ed. New Delhi: B Jain Publishers Pvt Ltd.; 2016.
15. Kent JT. *Lectures on Homoeopathic Materia Medica*. New Delhi: B Jain Publishers Pvt Ltd.; 2005.
16. Stub T, Musial F, Kristoffersen AA, Alraek T, Liu J. Adverse effects of homeopathy, what do we know? A systematic review and meta-analysis of randomized controlled trials. *Complement Ther Med* 2016;26:146-63.
17. Stub T, Kristoffersen AE, Alraek T, Musial F, Steinsbekk A. Risk in homeopathy: Classification of adverse events and homeopathic aggravations—a cross sectional study among Norwegian homeopath patients. *Complement Ther Med* 2015;23:535-43.
18. Stub T, Salamsen A, Alraek T. Is it possible to distinguish homeopathic aggravation from adverse effects? A qualitative study. *Forsch Komplementmed* 2012;19:13-19.
19. Kaur H, Chalia DS, Manchanda RK. Homeopathy in public health in India. *Homeopathy* 2019;108:76-87.
20. Dixit AK, Javed D, Giri N. Management of pilonidal sinus using homeopathic medicine in combination with Kshar solution: A case report of a novel approach. *J Surg Spec Rural Pract* 2022;3:70-3.

Traitement homéopathique individualisé du sinus pilonidal : un cas

Introduction: Le sinus pilonidal est une maladie inflammatoire très fréquente de la région fessière. Le site d'apparition le plus courant est la fente natale. Cela peut causer de l'inconfort, de l'absence du travail et de l'embarras social. Il n'existe pas de traitement unique et largement accepté pour cette maladie. Dans la plupart des cas, l'option de traitement de cette maladie est l'intervention chirurgicale, mais les récurrences après la chirurgie sont fréquentes. **Résumé de cas:** Un patient de 15 ans a signalé un écoulement de la cavité sinusale dans la fente natale avec de la douleur et de l'inconfort. *L'acide nitrique*, un médicament homéopathique, a été prescrit lors de la consultation initiale et le patient a été suivi pendant 4 mois à intervalles réguliers. L'échelle visuelle analogique et l'échelle de résultats liés à l'impact sur la vie quotidienne (ORIDL) ont été utilisées pour évaluer l'amélioration subjective du patient. Les signes d'amélioration objective ont été documentés par des photographies. Le score pour les critères Naranjo modifiés pour l'homéopathie était de +8, ce qui soutient l'attribution causale de la médecine homéopathique individualisée de *l'acide nitrique* au succès de ce cas.

Individualisierte homöopathische Behandlung der Steißbeinfistel: Ein Fallbericht

Einleitung: Die Steißbeinfistel ist eine sehr häufige entzündliche Erkrankung der Gesäßregion. Der häufigste Ort des Auftretens ist die Geburtsspalte. Es kann zu Unbehagen, Abwesenheit von der Arbeit und sozialer Verlegenheit führen. Es gibt keine einzige, allgemein akzeptierte Therapie für diese Erkrankung. In den meisten Fällen ist die Behandlungsoption für diese Krankheit ein chirurgischer Eingriff, aber Rezidive nach einer Operation sind häufig. **Fallzusammenfassung:** Ein 15-jähriger männlicher Patient berichtete über Ausfluss aus der Nasennebenhöhle in der Geburtsspalte zusammen mit Schmerzen und Beschwerden. *Salpetersäure*, ein homöopathisches Arzneimittel, wurde während der Erstkonsultation verschrieben und der Patient wurde in regelmäßigen Abständen 4 Monate lang nachbeobachtet. Die visuelle Analogskala und die ORIDL-Skala (Outcome Related to the Impact on Daily Living) wurden verwendet, um die subjektive Verbesserung des Patienten zu bewerten. Die Anzeichen einer objektiven Verbesserung wurden durch Fotos dokumentiert. Die Punktzahl für die modifizierten Naranjo-Kriterien für die Homöopathie betrug +8, was die kausale Zuschreibung des individualisierten homöopathischen Arzneimittels *Salpetersäure* zum Erfolg dieses Falles unterstützt.

पाइलोनिडल साइनस के लिए व्यक्तिगत होम्योपैथी उपचार: एक केस रिपोर्ट

परिचय: पाइलोनिडल साइनस ग्लुटियल क्षेत्र की एक बहुत ही सामान्य सूजन की बीमारी है। इसका सबसे आम स्थल जन्मजात फांक है। यह असुविधा, काम से अनुपस्थिति और सामाजिक शर्मिंदगी का कारण बन सकता है। इसके लिए कोई एकल, व्यापक रूप से स्वीकृत चिकित्सा उपलब्ध नहीं है। ज्यादातर मामलों में, इस बीमारी के लिए उपचार का विकल्प केवल सर्जरी ही है, लेकिन सर्जरी के बाद पुनरावृत्ति होना सामान्य बात है। **केस सारांश:** एक 15 वर्षीय पुरुष रोगी को दर्द और परेशानी के साथ जन्मजात फांक में साइनस गुहा से स्त्राव की शिकायत थी। प्रारंभिक परामर्श के दौरान *नाइट्रिक एसिड*, एक होम्योपैथी दवा विहित की गई और नियमित अंतराल पर 4 महीने तक रोगी का इलाज किया गया था। विजुअल एनालॉग स्केल (VAS) और इम्पैक्ट ऑन डेली लिविंग (ORIDL) स्केल से संबंधित परिणाम का उपयोग रोगी के व्यक्तिपरक सुधार का आकलन करने के लिए किया गया था। वस्तुनिष्ठ सुधार के संकेतों को तस्वीरों के माध्यम से प्रलेखित किया गया था। होम्योपैथी के लिए संशोधित नारंजो मानदंड का स्कोर +8 था, जो इस मामले की सफलता के लिए व्यक्तिगत होम्योपैथी दवा *नाइट्रिक एसिड* के कारणात्मक आरोपण का समर्थन करता है

Tratamiento homeopático individualizado para el seno pilonidal: Presentación de un caso

Introducción: El seno pilonidal es una enfermedad inflamatoria muy frecuente de la región glútea. El sitio más común de ocurrencia es la hendidura natal. Puede causar malestar, ausencia del trabajo y vergüenza social. No existe una terapia única y ampliamente aceptada disponible para esta afección. En la mayoría de los casos, la opción de tratamiento para esta enfermedad es la intervención quirúrgica, pero las recurrencias después de la cirugía son comunes. **Resumen del caso:** Un paciente masculino de 15 años de edad informó secreción de la cavidad sinusal en la hendidura natal junto con dolor y malestar. *Durante la consulta inicial se prescribió ácido nítrico*, un medicamento homeopático, y se realizó un seguimiento regular del paciente durante 4 meses. Se utilizaron la Escala Visual Analógica y la Escala de Resultados Relacionados con el Impacto en la Vida Diaria (ORIDL) para evaluar la mejoría subjetiva del paciente. Los signos de mejoría objetiva se documentaron a través de fotografías. La puntuación de los Criterios Naranjo Modificados para la Homeopatía fue de +8, lo que apoya la atribución causal del medicamento homeopático individualizado *Ácido nítrico* al éxito de este caso.

藏毛窦的个体化顺势疗法治疗：病例报告

简介：藏毛窦是一种非常常见的臀区炎症性疾病。最常见的发生部位是先生裂。它会导致不适、缺勤和社交尴尬。对于这种情况，没有单一的、被广泛接受的治疗方法。在大多数情况下，这种疾病的治疗选择是手术干预，但手术后复发很常见。**病例摘要：**一名 15 岁男性患者主诉产间裂窦腔分泌物伴有疼痛和不适。硝酸是一种顺势疗法药物，在初次咨询期间开具，并定期对患者进行为期 4 个月的随访。使用视觉模拟量表和与日常生活影响相关的结果（ORIDL）量表来评估患者的主观改善。通过照片记录了客观改善的迹象。改良的 Naranjo 顺势疗法标准得分为 +8，这支持了个体化顺势疗法药物硝酸与本病例成功的因果关系。