

27-6-2024

Management of post-operative breast nodules with Homoeopathy: A case report

Nisanth K.M. Nambison

Government Homeopathic Medical College, Bhopal, Madhya Pradesh, India, dmrghmc@gmail.com

Smita N. Nambison

N. S. Homeopathic Medical College, Bhopal, Madhya Pradesh, India

Abhishek D. Dwivedi

Government Homeopathic Medical College, Bhopal, Madhya Pradesh, India

Nisha Chakravarty

Government Homeopathic Medical College, Bhopal, Madhya Pradesh, India


Follow this and additional works at: <https://www.ijrh.org/journal>

 Part of the [Homeopathy Commons](#)

How to cite this article

Nambison NK, Nambison SN, Dwivedi AD, Chakravarty N. Management of post-operative breast nodules with Homoeopathy: A case report. Indian J Res Homoeopathy 2024;18:92-98

This Case Report is brought to you for free and open access by Indian Journal of Research in Homoeopathy. It has been accepted for inclusion in Indian Journal of Research in Homoeopathy by an authorized editor of Indian Journal of Research in Homoeopathy. For more information, please contact ijrhonline@gmail.com.



Management of post-operative breast nodules with Homoeopathy: A case report

Abstract

Introduction: Palpable masses after mastectomy are commonly detected by patients or their physicians. Imaging of palpable masses is advised following a complete history and physical examination. This is a case of breast nodules occurring after the removal of cancerous tissue in the breast. Homoeopathy, with its holistic approach, can treat the disease by addressing its multifactorial origin.

Case summary: A 71-year-old female, diagnosed with post-operative breast nodules after surgical excision of mucinous carcinoma portion of the left breast, was treated with individualised homoeopathic treatment for six months with subsequent improvement. This case provides preliminary evidence for the potential usefulness of homoeopathy as an alternative therapy for the treatment of breast nodules.

Acknowledgments and Source of Funding

NIL

Management of post-operative breast nodules with Homoeopathy: A case report

Nisanth K. M. Nambison^{1*}, Smita N. Nambison², Abhishek D. Dwivedi¹, Nisha Chakravarty¹

¹Department of Surgery, Government Homeopathic Medical College, Bhopal, Madhya Pradesh, India, ²Department of Pharmacy, N. S. Homeopathic Medical College, Bhopal, Madhya Pradesh, India

Abstract

Introduction: Palpable masses after mastectomy are commonly detected by patients or their physicians. Imaging of palpable masses is advised following a complete history and physical examination. This is a case of breast nodules occurring after the removal of cancerous tissue in the breast. Homoeopathy, with its holistic approach, can treat the disease by addressing its multifactorial origin. **Case Summary:** A 71-year-old female, diagnosed with post-operative breast nodules after surgical excision of mucinous carcinoma portion of the left breast, was treated with individualised homoeopathic treatment for six months with subsequent improvement. This case provides preliminary evidence for the potential usefulness of homoeopathy as an alternative therapy for the treatment of breast nodules.

Keywords: *Asterias rubens*, Breast lump, *Calcarea sulphurica*, Homoeopathy, *Silicea*

INTRODUCTION

Palpable masses after mastectomy are commonly detected by patients or their physicians. A palpable lump is the most common presentation of recurrent disease after mastectomy (96%).^[1] Many benign post-mastectomy lesions can result in palpable masses. These include mainly post-operative fluid collections such as seroma, haematoma and abscesses; scar tissue; normal axillary lymph nodes and fat necrosis.^[2] In localised breast tumours, even though after the removal of cancerous tissue, the patients are considered to be relatively free from cancer and its metastasis, the resultant lump can be very discomforting and a cause of pain and concern for the patients.

Breast cancer is a malignant neoplasm characterised by the uncontrolled proliferation of epithelial cells within the breast tissue. Breast cancer is a malignancy that can affect any gender, although it is more prevalent in females. The incidence of breast cancer increases with advancing age.^[3] In post-menopausal females, the incidence of breast cancer is higher among obese individuals, likely due to the increased conversion of steroid hormones to oestradiol within adipose tissue.^[4] With 22.6 lakh new cases in 2020, it is the cancer that affects women most frequently worldwide.^[5] In India, every 4 min, a woman is diagnosed with cancer.^[6]

With a mortality incidence of 12.7 per 100,000 women and an age-adjusted rate as high as 25.8 per 100,000 women, breast cancer has been identified as the most common cancer among Indian women. Breast carcinoma development is associated with several risk factors, including increasing age >50 years, nulliparity, early menarche, late menopause, obesity, personal and familial history, radiation therapy to the chest, BRCA1 and BRCA2 genetic mutations and saturated fatty acids-rich diet.^[7]

The prevalent subtypes of breast cancer include ductal carcinoma *in situ*, lobular carcinoma *in situ*, invasive lobular carcinoma, inflammatory breast carcinoma and Paget's disease of the breast.^[3] The common symptom includes a breast lump that exhibits morphological and/or textural differences from surrounding breast tissue, including changes in size, shape or appearance. In addition, there may be alterations in the surrounding skin, such as dimpling, or changes in the areola, including pigmentation changes and the development of skin lesions, such as scaling, crusting or flaking, accompanied by

***Address for correspondence:** Nisanth K. M. Nambison, Government Homeopathic Medical College, Bhopal, Madhya Pradesh, India.
E-mail: dmrghmc@gmail.com

Received: 25 March 2023; **Accepted:** 04 June 2024

Access this article online

Quick Response Code:



Website:
www.ijrh.org

DOI:
10.53945/2320-7094.1863

This is an open access journal, and articles are distributed under the terms of the Creative Commons Attribution-NonCommercial-ShareAlike 4.0 License, which allows others to remix, tweak, and build upon the work non-commercially, as long as appropriate credit is given and the new creations are licensed under the identical terms.

How to cite this article: Nambison NK, Nambison SN, Dwivedi AD, Chakravarty N. Management of post-operative breast nodules with Homoeopathy: A case report. Indian J Res Homoeopathy 2024;18:92-98.

erythema and/or skin indentation.^[8] When diagnosing breast carcinoma, it is important to identify and differentiate it from other conditions that may present with similar clinical symptoms, such as fibroadenoma, breast abscess and fat necrosis.^[9]

At present, chemotherapy is routinely used to treat breast cancer at various stages. The potential negative effects of chemotherapy in cancers are revealed by several studies which include low immunity, hair loss and thinning, nausea, and vomiting episodes, constipation or diarrhoea, oral complications, dry skin and brittle nails, fatigue, infertility and menopausal symptoms. Psychological complications include fear, anxiety, insomnia and depression.^[10]

A study revealed that the therapeutic effects of individualised homeopathic medicines play a significant role in the management of fibroadenoma of breast.^[11] In another study, a randomised, double-blind clinical trial assessed the efficacy of homeopathic medicines on the heat of the skin during radiotherapy for breast cancer.^[12] Homeopathic literature and other studies too favour homeopathic management for treating cases of breast carcinoma.^[13,14] The present case demonstrates the usefulness of individualised homeopathic medicine in the treatment of post-operative breast nodules without any surgical intervention. This case is being reported in compliance with the HOM-CASE guidelines.^[15]

PATIENT INFORMATION

A 71-year-old female visited our clinical setting in Bhopal, India, on July 17, 2022, and presented with a complaint of breast nodule in her left breast with serous, offensive discharge aggravated since one month. On July 4, 2011, the patient was diagnosed with mucinous carcinoma of the left breast. Soon after, she underwent surgical excision of a small mass in her left breast. She was not on any medication after the excision, but gradually, she noticed a regrowth of the mass within a year of excision. Subsequently, in June 2013, the patient observed multiple small masses at the site of excision, which prompted her to visit a surgeon who advised a full body PET scan. However, the PET scan was not done as the patient was anxious about this elaborate procedure, as well as wanted to avoid this expenditure due to financial constraints. The case was then left unattended until June 2022, when she noticed increased swelling in a tumorous mass in her left breast, with speedy growth in the mass within a month, accompanied by ulceration on its surface [Figure 1].

The patient reported that all the symptoms like accelerated growth accompanied by serous, offensive discharge from the small ulcer site and a swelling in her left axilla, had aggravated since one month. She also complained of offensive sweat in the axilla. There were redness and pitting of the skin over her breast. There was violent and stinging chest pain and cough with yellow, mucopurulent lumpy expectoration. The patient also had pain in both knee joints, which was ameliorated by cold fomentation. In addition, she had complaints of xeroderma pigmentosum on the soles of feet.

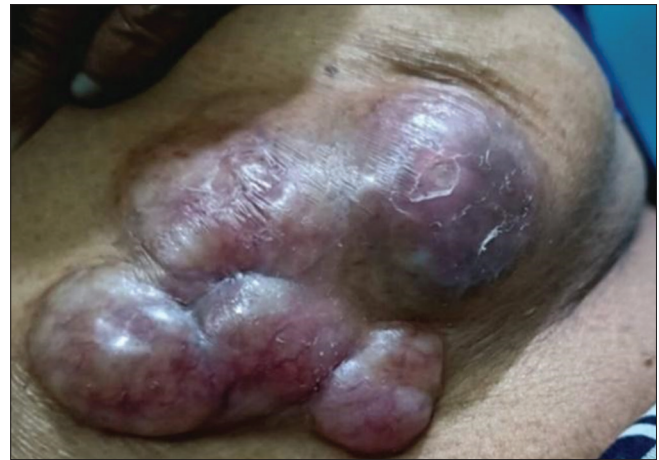

Figure 1: A lesion at the initial visit before treatment (17 July 2022)

The patient had a history of diabetes mellitus, high blood pressure for the past 10–12 years and osteoarthritis for the past six years for which she was taking conventional medication.

Clinical findings

On examination, the affected breast was asymmetrical, with peeling, scaling and crusting, along with a flaking pigmented area surrounding the nipple and areola. On palpation, no palpable masses or lymph nodes were found other than in the breast tissue. There was an excessively suppurating tumorous mass in the lower outer quadrant of the left breast, resulting from 2 to 3 nodules coalesced together.

The patient was oversensitive to all external impressions. She used to feel depressed and anxious about her illness, and her family informed that it was hard to convince her of the possibility of recovery. She did not seem to be willing to listen to anyone about it and had fixed ideas about her illness. She felt exhausted and could not focus on day-to-day stuff. She had a weeping tendency in front of everyone and also had fear of needles. She liked company and her anger was ameliorated by consolation.

Her complaints were aggravated by lying on the left side and in cold weather. The patient had a desire for sweets and pickles.

Diagnostic assessment

A histopathological report dated July 4, 2011, had revealed mucinous carcinoma of the breast. Further, a PET scan was also advised by the laparoscopic surgeon on June 6, 2013. She was also advised for other related investigations later, but she was apprehensive and declined to go for any scan or biopsy again due to fear of needles as well as lack of financial resources.

The ultrasonography of the left breast dated December 27, 2022, revealed a large, ill-defined dermal-based soft tissue mass (5.9 × 5.5 × 4.1 cm) present in the lower quadrant of the left breast, with suspicious, deep infiltration. Rest of the breast showed normal fibrofatty and glandular parenchymal echotexture. The nipple-areolar complex and retro-areolar region were normal. No ductal dilatation, parenchymal calcification or intra-substance lymph nodes were seen. Underlying ribs, pectoralis muscle and superficial fascia were

also normal. No significant lymphadenopathy was seen in the left axillary region [Figure 2], which indicated the presence of a soft tissue mass lesion in the lower quadrant of the left breast and deep infiltration, often associated with malignancy. However, the radiologist also mentioned the possibility of it being a keloid and recommended fine needle aspiration cytology, which the patient refused to undertake.

During her first visit to our clinic, the TNM classification of the case was found to be T3N0M0.

Totality of symptoms

- Fixed ideas
- Prostration of mind
- Oversensitive to all external impressions
- Yellowish green expectoration with mucous
- Swelling of left breast
- Painful breast; aggravation from cold, lying on the left

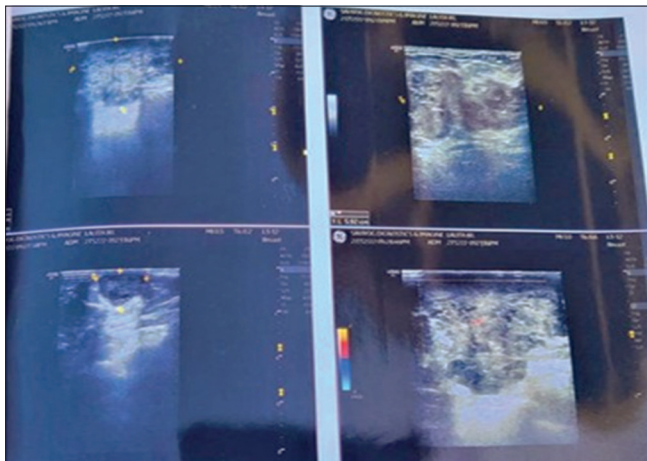


Figure 2: Ultrasonography left breast film

- side; amelioration from warm and wet application
- Breast affection is ulcerative in nature and the discharge was offensive
- Eruptions over the affected part of the chest were scaly and yellowish discolouration of nipples and areola
- Stinging pain in the breast
- Offensive perspiration of axillae
- The complaints were radiating in nature
- Mucoid expectoration.

Repertorial analysis

The symptoms of the patient were repertorised by using Complete Dynamics software based on Complete repertory, which includes some cancer-based rubrics (since she was a known case of Ca breast in the past), and the results are shown in Figure 3. Furthermore, 12 out of 19 rubrics used for repertorisation were covered by the remedy *Silicea*.

Therapeutic intervention

According to the repertorial analysis and totality, *Silicea* was given as the similimum in 30C potency, 6 pills, to be taken twice a day, followed by *Calcarea sulphurica* 6X, 4 tablets thrice a day.

Follow-up and outcomes

The patient reported of not taking any intervention other than the homoeopathic medicines prescribed to her. On the next visit, dated 9 August 2022, the patient reported of pus exuding from one of the five tumorous masses. She reported that after taking the medicine, *Silicea*, there was oozing of pus, followed by bloody discharge and subsequent healing of the affected area [Figure 4].

Eventually, she reported drying up of the lesion and the ulcer cavity was noted to be reducing in size, and related redness,

Complete Dynamics - Translator edition

General View Navigate Book Case Analysis MM Help

Analysis uses 19 rubrics in 5 symptoms.

Most similimum remedy *Silicea* is selected

	sil	sulph	con	phos	lvs	puls	arsar	praty	calc	br	fricr	nit.ac	sep	thaj	ars
10079	78	65	61	60	54	47	44	44	43	42	42	40	37	37	
12	11	11	10	10	9	7	8	9	8	8	8	7	7		
693 Mental															
3 90 Mind; Ideas; fixed	3	4	3	3	3	3		1	1	4	3	3	4		
4 588 Mind; Prostration of mind	4	4	4	4	4	4	3	3	4	4	3	4	4	3	4
4 245 Mind; Sensitive, oversensitive; impressions, to all external	3	3	1	4	4	2		1	3	3	1	1	4	1	3
100 Breast Cancer															
4 1 Expectoration; Mucous; lumps; yellowish green															
4 26 Chest; Cancer; mammae; left						2	3	1	1			1		2	
4 1 Chest; Cancer; painful; mammae; applications, warm, wet, amel.															
4 8 Chest; Cancer; ulcerating, mammae; offensive								1	4	1					1
2 1 Chest; Eruptions; scaly; yellow, nipples, areola															
2 25 Chest; Pain; stinging; mammae						3									
4 60 Chest; Perspiration; offensive; axillae						4	4	2	2	4		3	3	3	4
4 13 Chest; Swelling; mammae; left						1	2				3	3		1	3
4 13 Chest; Tumors; mammae; left						2	1		1	1	1				
4 1 Chest; Ulcers; mammae; left											3				
214 General															
4 88 Chill; Cold agg.						2	1		1	3	3	3	3	3	3
3 164 Generalities; Radiating, spreading complaints						3	3	1	1	4	3	3	1	1	4
4 39 Vet-Generalities; Agg.; Lying; side, on; left						3	3	1	4	1	4		1	3	3
19 Cough															
2 19 Expectoration; Mucous; cough; during															1
655 Extremities															
3 655 Extremities; Pain; knees						4	4	4	4	4	4	4	4	4	4
2 4 Extremities; Pain; knees; cold; amel.															3

Figure 3: Repertorial chart

swelling, pain, etc., were also reported to annihilate.

Details of the follow-up, patient's response to treatment and prescription of medicines are given in Table 1. The Modified Naranjo Criteria for Homoeopathy (MONARCH) score was used to evaluate the causal attribution of the clinical outcome to homoeopathic medicine. The score of +8 indicated a probable causal relationship between the prescribed medicine and the treatment outcome^[16] as indicated in Table 2. The patient did not turn up for follow-up after December 2022. We tried reaching her, however, we could only connect her son who informed us that he was not aware of the status of the nodules in particular, but the

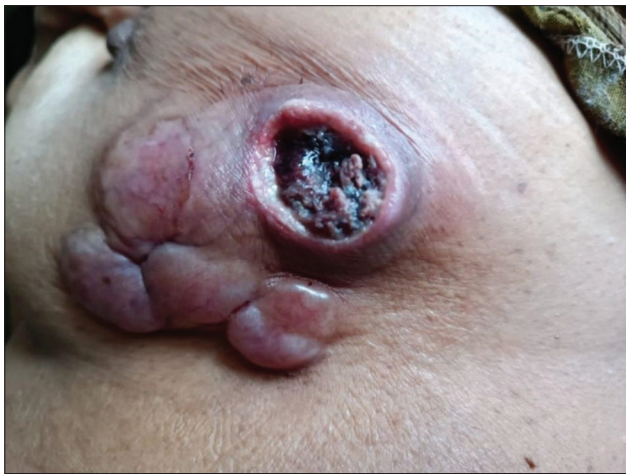

Figure 4: Second visit during treatment (09 August 2022)

patient was in a healthy state overall, and had no health-related issues that needed attention.

Re-repertorisation

Re-repertorisation of the case was done and all rubrics used for repertorisation in the follow-up were covered by the remedy *Asterias rubens* [Figure 5]. The following rubrics were taken for repertorisation:

- Mind; anxiety; weeping; amel.
- Mind; fear; misfortune, of; hysteria, in, weeping amel.
- Chest; cancer; mammae; left
- Chest; cancer; painful; mammae; left
- Chest; pain; mammae; extending to; inwards
- Chest; redness; mammae
- Chest; swelling; painful; mammae

DISCUSSION

The basic concept of Homoeopathy, '*similia similibus curentur*' which means 'like cures like,' refers to not one, but a holistic approach to the totality of many symptoms. Homoeopathy is a therapeutic system that treats the patient, not the disease. It also seeks to restore health in a rapid, gentle and permanent manner.^[17] It analyses the patient's individualistic characteristics in addition to treating them holistically. This case report describes the effectiveness of homoeopathic treatment in a post-operative breast nodule. The tumorous mass in the lower left outer quadrant of breast was accompanied by a serous offensive discharge from the site of the ulcer. There was an excessively suppurating, tumorous nodule and stinging

Table 1: First and follow-up visits

Date of prescription	Symptoms	Prescription
17 July 2022 Baseline visit	Swelling and growth of the mass in the left breast, development of surface ulceration on the breast mass with serous and offensive discharge, swelling in the left armpit (left axilla) with offensive sweating in axillary region; redness and pitting of the skin over the affected breast, violent and stinging chest pain, cough with mucopurulent (yellow, lumpy) expectoration, bilateral knee joint pain, knee pain relieved by cold fomentation, xeroderma pigmentosum present on both soles of the feet. Aggravation of symptoms when lying on the left side or exposed to cold.	<i>Silicea</i> 30C BD 30 days <i>Calcarea sulph</i> 6x TDS 30 days
09 August 2022	Collection of pus, which turned bloody. One tumour mass came out. Ulcer cavity showed healing and the remaining tumours with oedema and crusting conditions with reduction in size. However, other enlarged and swollen tumours with breast soreness continue to be present. Tumour had the appearance of lumpy, yellowish scabs, with purulent, pus-like exudation underneath the scabs. Livid redness and pitting over the tumorous mass and around the ulcer. Pain radiated to the left arm and axilla, worse in motion. Anxious weeping over the fear of misfortune.	The case was re-repertorised. <i>Phosphorus</i> 30C BD 5 days Followed by <i>Asterias rubens</i> 30C BD 1 month and <i>Calcarea sulph</i> 6x TDS 30 days
03 October 2022	Ulcer left behind by expulsion of one of the nodule mass healed now, bringing relief from pain, swelling, redness and skin pitting [Figure 6].	<i>Asterias rubens</i> 30C BD 15 days <i>Calcarea sulph</i> 6x TDS 30 days
14 December 2022	There was no inflammation and pitting of skin and the overall condition continued to get better. However, the other 4 masses continued to be present [Figure-7].	<i>Calcarea sulph</i> 6x TDS 30 days

Table 2: MONARCH inventory (improved version of the Modified Naranjo criteria for Homoeopathy)

S. No.	Domain	Yes	No	Not sure or N/A
1	Was there an improvement in the main symptom or condition for which the homoeopathic medicine was prescribed?	+2	-1	0
2	Did the clinical improvement occur within a plausible timeframe relative to the medicine intake?	+1	-2	0
3	Was there a homoeopathic aggravation of symptoms?	+1	0	0
4	Did the effect encompass more than the main symptom or condition (i.e., were other symptoms, not related to the main presenting complaint, improved or changed)?	+1	0	0
5	Did overall well-being improve? (suggest using a validated scale or mention about changes in physical, emotional and behavioural elements)	+1	0	0
6a	Direction of cure: did some symptoms improve in the opposite order of the development of symptoms of the disease?	+1	0	0
6b	Direction of cure: did at least one of the following aspects apply to the order of improvement in symptoms: - from organs of more importance to those of less importance? - from deeper to more superficial aspects of the individual? - from the top downwards?	+1	0	0
7	Did "old symptoms" (defined as non-seasonal and non-cyclical symptoms that were previously thought to have resolved) reappear temporarily during the course of improvement?	+1	0	0
8	Are there alternative causes (i.e., other than the medicine) that – with a high probability – could have produced the improvement? (consider known course of disease, other forms of treatment and other clinically relevant)	-3	+1	0
9	Was the health improvement confirmed by any objective evidence? (e.g., investigations, clinical examination, etc.)	+2	0	0
10	Did repeat dosing, if conducted, create similar clinical improvement?	+1	0	0
Total score: +8				
Maximum score= +13, Minimum score= -6				

*The numbers in bold font represent the option selected

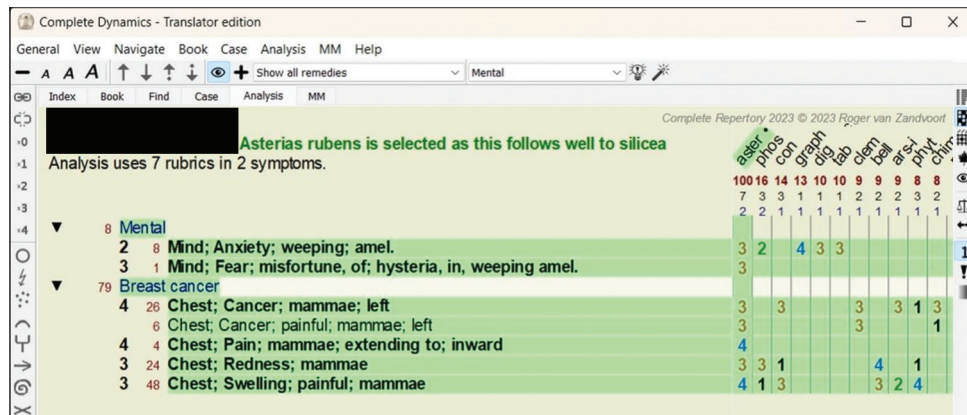


Figure 5: Follow- up repertorial chart

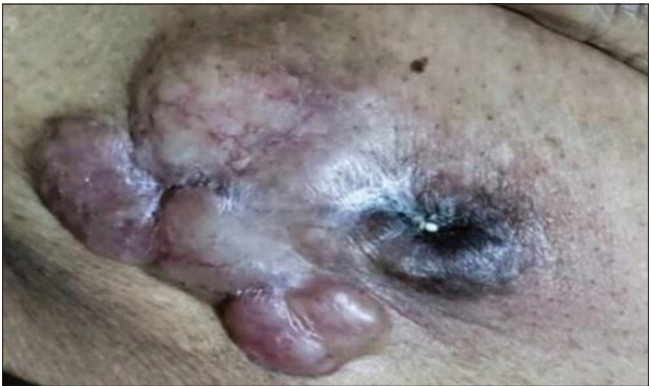

Figure 6: Third visit during treatment (03 October 2022)

pain with swelling, redness and pitting of the skin. In this case, *Silicea* 30C and *Calcarea sulph* 6x were selected on the basis of the totality of symptoms. This case is a testimony to

the catchphrase of *Silicea* as ‘surgeon without knife’, seeing its action of peeling out the tumorous mass.^[18] Further, based on the follow-up, *Phosphorus* 30C was prescribed to prevent bleeding^[19] from the ulcer site with *Asteris rubens* 30C, which led to recovery of the case [Figure 6]. The MONARCH score of +8 also indicated the probable causal role of individualised homoeopathic medicine in recovery [Table 2].

Sorrentino *et al.* reported a randomised clinical trial with *Arnica montana* which reduced post-operative seroma and bleeding in women undergoing unilateral total mastectomy.^[13] Another case report also revealed the benefits of homoeopathic complementary treatment in patients with breast carcinoma, which seemed to help patients to tolerate the side effects of cancer treatment.^[14] The above studies suggest that homoeopathic medicines can be used for treating surgical cases like breast carcinoma.

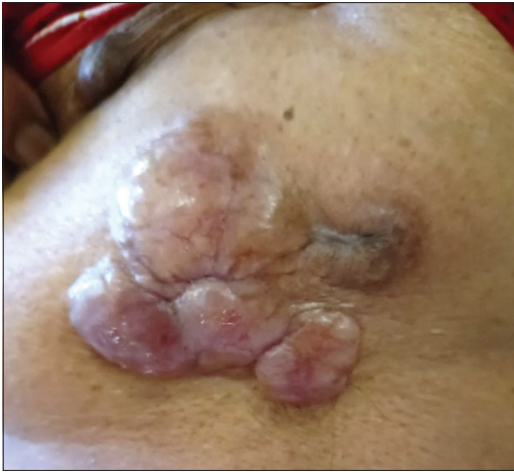

Figure 7: Fourth visit after treatment (14 December 2022)

A major limitation of this case report is that since the patient was afraid of needles and investigations, as well as due to her financial constraints and age-related issues, further histopathological investigations for assessment of recovery could not be done.

The positive outcome of this case report brings to light the usefulness of individualised homeopathic medicine in treating post-operative breast nodule [Figure 7]. Although, this single case does not support any conclusive evidence, it opens a new avenue of possibility. A large-scale, randomised controlled trial is advised to evaluate the efficacy of homeopathic treatment of breast nodules.

CONCLUSION

The present case report suggests that homeopathic treatment may offer potential benefits for managing cases of post-operative breast nodule. The use of homeopathic medicine, in this case, demonstrates its effectiveness as a non-invasive alternative to surgical intervention, in accordance with its purported action of facilitating the expulsion of the tumorous mass. Thus, it has been demonstrated that Homeopathy is an effective method for treating surgical cases like post-operative breast nodule. Further research is warranted to validate and extend these findings.

Declaration of patient consent

The authors certify that they have obtained the patient's written consent for using her images and other clinical information reported in the journal, with best efforts to maintain anonymity.

Financial support and sponsorship

Nil.

Conflict of interest

None declared.

REFERENCES

- Newman LA, Kuerer HM, Hunt KK, Kroll SS, Ames FC, Ross MI, *et al*. Presentation, treatment, and outcome of local recurrence after skin-sparing mastectomy and immediate breast reconstruction. *Ann Surg Oncol* 1998;5:620-6.
- Pryce C, Owen W. Palpable masses after mastectomy: Differentiating benign postoperative findings from recurrent disease. *J Breast Imaging* 2020;2:501-10.
- Sharma GN, Dave R, Sanadya J, Sharma P, Sharma KK. Various types and management of breast cancer: An overview. *J Adv Pharm Technol Res* 2010;1:109-26.
- Williams NS. *Bailey and Love's Short Practice of Surgery*. 27th ed. United States: CRC Press; 2018. p. 4646.
- Ferlay J, Colombet M, Soerjomataram I, Mathers C, Parkin DM, Pineros M, *et al*. Estimating the global cancer incidence and mortality in 2018: Globocan sources and methods. *Int J Cancer* 2019;144:1941-53.
- Cytecare Hospitals. Statistics of Breast Cancer in India. Bangalore: Cytecare Hospital; 2019. Available from: <https://cytecare.com/blog/breast-cancer/statistics-of-breast-cancer> [Last accessed on 2024 Apr 28].
- Lukasiewicz S, Czezelewski M, Forma A, Baj J, Sitarz R, Stanislawek A. Breast cancer-epidemiology, risk factors, classification, prognostic markers, and current treatment strategies-an updated review. *Cancers (Basel)* 2021;13:4287.
- Centers for Disease Control and Prevention. CDC - What Are the Symptoms of Breast Cancer? US: Centers for Disease Control and Prevention; 2020. Available from: https://www.cdc.gov/cancer/breast/basic_info/symptoms.htm [Last accessed on 2024 Apr 20].
- Alkabban FM, Ferguson T. Breast Cancer. National Library of Medicine. Treasure Island: StatPearls Publishing; 2022. Available from: <https://www.ncbi.nlm.nih.gov/books/nbk482286> [Last accessed on 2024 Feb 22].
- Senkus Konefka E, Jassem J. Complications of breast-cancer radiotherapy. *Clin Oncol (R Coll Radiol)* 2006;18:229-35.
- Shukla P, Misra P, Misra RK, Jain RK, Shukla R, Manchanda RK, *et al*. Homeopathic management of breast fibroadenoma-an open label, single arm, observational trial. *Homeopath Links* 2020;33:90-8.
- Balzarini A, Felisi E, Martini A, de Conno F. Efficacy of homeopathic treatment of skin reactions during radiotherapy for breast cancer: A randomised, double-blind clinical trial. *Br Homeopath J* 2000;89:8-12.
- Sorrentino L, Piraneo S, Riggio E, Basilic S, Sartani A, Bossi D, *et al*. Is there a role for homeopathy in breast cancer surgery? A first randomized clinical trial on treatment with *Arnica montana* to reduce post-operative seroma and bleeding in patients undergoing total mastectomy. *J Intercult Ethnopharmacol* 2017;6:1-8.
- Medioni J, Scimeca D, Marquez YL, Leray E, Dalichampt M, Hoertel N, *et al*. Benefits of homeopathic complementary treatment in patients with breast cancer: A retrospective cohort study based on the French nationwide healthcare database. *Clin Breast Cancer* 2023;23:60-70.
- Van Haselen RA. Homeopathic clinical case reports: Development of a supplement (HOM-CASE) to the CARE clinical case reporting guideline. *Complement Ther Med* 2016;25:78-85.
- Lamba CD, Gupta VK, Van Haselen R, Rutten L, Mahajan N, Molla AM, *et al*. Evaluation of the modified naranjo criteria for assessing causal attribution of clinical outcome to homeopathic intervention as presented in case reports. *Homeopathy* 2020;109:191-7.
- The School of Homeopathy. Aphorism 1-10 - The Organon; 2024. Available from: <https://www.homeopathyschool.com/the-school/editorial/the-organon/aphorism-1-10> [Last accessed on 2024 Apr 28].
- Clarke JH. *A Dictionary of Practical Materia Medica*. New Delhi: B. Jain Publishers; 1997. p. 988.
- Boger CM. *Boenninghausen's Characteristics Materia Medica and Repertory with Word Index*. New Delhi: B. Jain Publishers; 2002.

Prise en charge des nodules mammaires postopératoires avec homéopathie : un rapport de cas

Introduction: Les masses palpables après mastectomie sont couramment détectées par les patientes ou leurs médecins. L'imagerie des masses palpables est conseillée après une anamnèse complète et un examen physique. Il s'agit d'un cas de nodules mammaires survenant après l'ablation du tissu cancéreux dans le sein. L'homéopathie, avec son approche holistique, peut traiter la maladie en s'attaquant à son origine multifactorielle. **Résumé de cas:** Une femme de 71 ans, diagnostiquée avec des nodules mammaires postopératoires après l'excision chirurgicale d'une partie du carcinome mucineux du sein gauche, a été traitée avec un traitement homéopathique individualisé pendant six mois avec une amélioration ultérieure. Ce cas fournit des preuves préliminaires de l'utilité potentielle de l'homéopathie comme thérapie alternative pour le traitement des nodules mammaires.

Management postoperativer Brustknoten mit Homöopathie: Ein Fallbericht

Einleitung: Tastbare Massen nach Mastektomie werden häufig von Patienten oder ihren Ärzten festgestellt. Die Bildgebung tastbarer Massen wird nach einer vollständigen Anamnese und körperlichen Untersuchung empfohlen. Dies ist ein Fall von Brustknötchen, die nach der Entfernung von Krebsgewebe in der Brust auftreten. Die Homöopathie mit ihrem ganzheitlichen Ansatz kann die Krankheit behandeln, indem sie sich mit ihrem multifaktoriellen Ursprung befasst. **Fallzusammenfassung:** Eine 71-jährige Frau, bei der nach chirurgischer Entfernung des muzinösen Karzinomanteils der linken Brust postoperative Brustknoten diagnostiziert wurden, wurde sechs Monate lang mit einer individualisierten homöopathischen Behandlung mit anschließender Besserung behandelt. Dieser Fall liefert erste Beweise für den potenziellen Nutzen der Homöopathie als alternative Therapie zur Behandlung von Brustknoten.

होम्योपैथी के साथ सर्जरी के बाद बनी स्तन की गांठ का प्रबंधन: एक केस रिपोर्ट

परिचय: मास्टेक्टॉमी के बाद स्पर्शनीय द्रव्यमान आमतौर पर रोगियों या उनके चिकित्सकों द्वारा पता लगाया जाता है। एक पूर्ण केस हिस्ट्री और शारीरिक परीक्षा के बाद स्पर्शनीय द्रव्यमान की इमेजिंग की सलाह दी जाती है। यह स्तन में कैंसर के ऊतकों को सर्जरी से हटाने के बाद होने वाले स्तन की गांठ का केस है। होम्योपैथी, अपने समग्र दृष्टिकोण के साथ, इसकी बहुक्रियात्मक उत्पत्ति को संबोधित करके बीमारी का इलाज करती है। **केस सारांश:** एक 71 वर्षीय महिला के बाएं स्तन के श्लेष्म कार्सिनोमा हिस्से के सर्जरी के बाद पोस्ट-ऑपरेटिव स्तन गांठ का निदान होम्योपैथी द्वारा किया गया, जो बाद में सुधार के साथ छह महीने के लिए व्यक्तिगत होम्योपैथी उपचार के साथ इलाज किया गया था। यह केस स्तन गांठ के उपचार के लिए वैकल्पिक चिकित्सा के रूप में होम्योपैथी की संभावित उपयोगिता के लिए प्रारंभिक साक्ष्य प्रदान करता है।

Manejo de nódulos mamarios postoperatorios con homeopatía: reporte de un caso

Introducción: Las masas palpables después de la mastectomía son comúnmente detectadas por las pacientes o sus médicos. Se recomienda la obtención de imágenes de masas palpables después de una historia clínica completa y un examen físico. Este es un caso de nódulos mamarios que ocurren después de la extirpación de tejido canceroso en el seno. La homeopatía, con su enfoque holístico, puede tratar la enfermedad abordando su origen multifactorial. **Resumen del caso:** Mujer de 71 años, diagnosticada de nódulos mamarios postoperatorios tras la extirpación quirúrgica de una porción de carcinoma mucinoso de la mama izquierda, fue tratada con tratamiento homeopático individualizado durante seis meses con posterior mejoría. Este caso proporciona evidencia preliminar de la utilidad potencial de la homeopatía como terapia alternativa para el tratamiento de los nódulos mamarios.

顺势疗法术后乳腺结节的治疗：病例报告

简介： 乳房切除术后可触及的肿块通常由患者或其医生检测到。建议在完整病史和体格检查后可触及肿块进行影像学检查。这是在切除乳房癌组织后发生的乳房结节的情况。顺势疗法采用整体方法，可以通过解决其多因素起源来治疗疾病。 **病例摘要：** 一名71岁女性，手术切除左乳粘液癌部分后诊断为术后乳腺结节，接受个体化顺势疗法治疗6个月，随后改善。该病例为顺势疗法作为治疗乳腺结节的替代疗法的潜在有用性提供了初步证据。