

Malignant Meningioma

Abstract: A truly astounding case which proves the efficacy of this greatest of all medical sciences! Not only is it documented and shows the meningioma disappearing but we also have a long 16 yr old follow up- which is very rare to achieve. This case is most convincing of all our sure shot cases on njhonline! This case is included in this issue as a balast: proving the human brain is of prime importance and can give astounding results even without technology !

Dr S K MANGAIK

Honors and Awards: Doon Ratna; Garhwal Gaurav; Gold Medalist; veteran Homoeopath; & C.

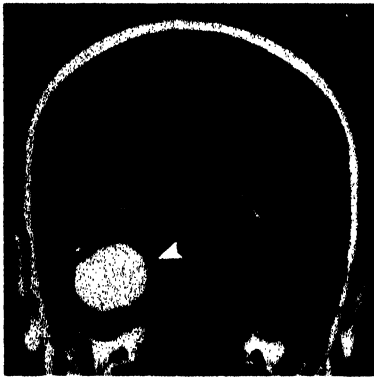
Mangaiik Homoeo Clinic: 218, D. L. Road, Dehradun - 248 001

E-mail: drsmangaiik@gmail.com **Web:** <http://www.homoeopathy-milddose.com>

Proper homoeopathic help in early stage of the malignancy, can make cure take place, as defined by Hahnemann in Aphorism No 2 of the Organon. The basic laws of Homoeopathy are universal and natural, and hold true under all circumstances in our universe. To illustrate, I present a case of Malignant Meningioma which has been cured and followed up for long, in the real sense.

Mosby's Medical Encyclopedia explains **meningioma** as:

A tumor of the meningeal membranes covering the brain and spinal cord, Meningiomas often grow slowly. They usually contain blood vessels. The tumors may vary in shape and structure. They may invade the skull, causing weakening of bones and pressure on the brain tissue. Meningiomas usually occur in adults. In some cases, they follow after a head injury.



Malignant meningioma - Meningioma that either invades brain parenchyma or metastasizes. (Stedman's Electronic Medical Dictionary). Mosby's Encyclopedia says that Meningiomas usually occur in adults. The patient was a young man of 22 with a history of falling from a height, with possible injury to the head. The case was

treated in 1992, when patient was a student of BHMS III year at Homoeopathic Medical College, Kanpur.

The past history of the case (vide Summary Card of Sanjay Gandhi P. G. I. of Medical Sciences, Lucknow, where patient was initially treated

- Hemiparesis, left.
- Brachioradial neuralgia.
- Asphyxial fits for one year.
- Papilloedema
- High intra-cranial tension.
- Bradycardia.
- Acaculia.

For the past ten years, he also had:

- Pain in whole cranium, with a occasional severe attacks.
- The pain was maximum in temples.
- History of falling from a height.
- Eczema.
- Numbness and formication in left arm.
- Recurrent episodes of reflex projectile vomiting without preceding nausea.
- Vomitus sometimes fluid, sometimes food.
- Visual disturbances. Sudden loss of vision, cannot read for the past one year.
- Reflex choking and breathing difficulty for the last one year, episodic attacks.
- Attacks of vertigo, whirling sensation and giddiness.
- No history of hypertension.
- Non smoker, non alcoholic.
- No significant lymph nodes.

He had been given Radio Therapy at Sanjay Gandhi P. G. I. of Medical Sciences, Lucknow, on 19-2-1991; 11-12-1991 and 24-1-1992. (See photo of the Summary Card below Fig 1:

He was advised complete rest mental as well as physical and he was a BHMS III year student.

Fig 1

His whole career was at stake. He was looking for an alternative therapy.

So he approached me through post. He related his story in the letter dt. 31st Jan 1992 (see photo copy Fig 2) and begged for help. The symptoms given in the letter were considered a n d medicines made and sent by post. *Asteria-rubens* 30 was sent in p o t i o n s




Fig 2

containing 4-5 globules of No 10 size in little sugar of milk to be taken one potion daily. Later some potions of *Conium-maculatum* 200 were also sent to be taken at an interval of one month. On the day *Conium-maculatum* was taken *Asterias-rubens* was skipped. There was some aggravation in the beginning in the size of the meningioma (Hom<) but later it reduced and finally vanished. (See Fig 3). On 22nd February 1992 it was confirmed in CT scan that the patient has Meningioma in left parasagittal region. Previous diagnosis was based on exploratory cytology. In first CT Scan size of the tumor: 1x2 mm.

CT Scan on 19th August 1992 size of tumor: 2x3 mm (See Fig 4). But the patient was feeling better in general.

Fig 3

CT Scan 20th September 1992 size of tumor: 2x2mm (See Fig 5). This shows the pathological improvement.

Final CT Scan done on 26th December 1992 shows NORMAL study ie no presence of the tumor! (See Fig 6).




Fig 4

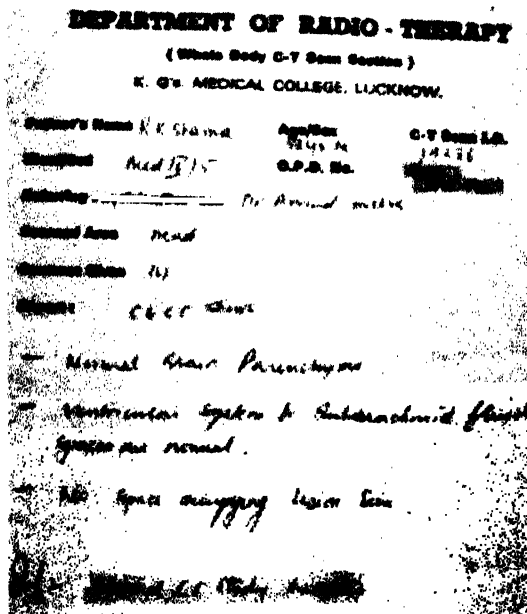


Fig 6

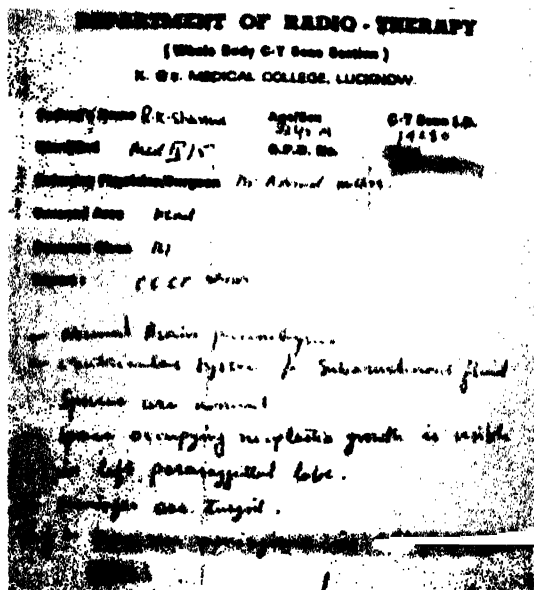


Fig 5

studies he started practice at Kashipur, Udham Singh Nagar, Uttarakhand. Later he started his own Nursing Home there and is enjoying good clientele, and doing yeoman's work in Homoeopathy.

The wonder of the wonders is – the body of any individual develops from a single cell (Stem cell) from division of which all kinds of cells develop and consequently forming up the complete body before birth later this goes on growing into different milestones of the life from infancy to old age; therefore when *Asterias-rubens* can produce in its pathogenesis so can CURE cancer of the breast. Can't it cure the cancer of brain with its general symptoms present in a patient?

Some symptoms taken into consideration for the diagnosis:

(1) *Asterias-rubens*

CLARKE – It powerfully affects the mind and head, producing symptoms suggesting apoplexy. Cerebral congestion with obstinate constipation. Sudden fullness in head, as if congested. Electric shocks in the head. Irritable, slightest cause moves her to tears. This agent produces cerebral congestion, epilepsy, neuralgia, and chorea.

When tumor regressed, medication was stopped. The patient regained his normal health and has remained healthy to this day 19th October 2008 ie even after sixteen years.

After 16 years I can certainly claim that the patient has been CURED. The patient qualified his BHMS at due time. He regained his intelligence which is higher than normal people. After completing his



The diseases are functional in origin, with the exception of cancerous diseases, especially cancer of the breast, which it cures even in the stage of ulceration.

C HERING – Feeling of extreme anxiety from noon to 3 P.M.

Ill-humored and disposed to weep.

After mental exertions, brain agitated.

Vertigo : transitory; when walking, with insensibility of lower limbs.

Determination of blood to head; sensation of fullness, heat; it feels as if it would split.

Sudden pain on right side of head.

Pain in vertex as if skull would break.

Disposition to sleep after reading a moment.

Eruption on thighs and insteps of small itching vesicles which tear easily and form superficial ulcer.

VITHOULKAS - An analogy may be drawn between the tendency of a malignant tumor to develop fast as an outlet for inner imbalance and the brain or nervous system's tendency to proceed towards its own particular outlet in the form of twitchings, convulsions, chorea or intellectual overactivity. After mental exertions, the brain feels agitated. With such a constitution it is not difficult to understand that all symptoms will become worse from drinking coffee.

Electric shocks in the brain with internal pressure. It powerfully affects the circulation in head, producing symptoms strongly suggesting apoplexy, face red, strong congestion to the head, which is hot and feels as if surrounded with hot air. This remedy, due to its symptomatology, should be considered in tumors of the brain as well.

(2) *Conium-maculatum*

H C ALLEN says *Conium* has Glandular induration of stony hardness; of mammae and testicles in persons of cancerous tendency; after bruises and injuries of glands (compare, *Aster- rub*).

Vertigo: especially when lying down or turning in bed; moving the head slightly, or even the eyes; must keep head perfectly still; in turning the head to the left (*Col*); of old people; with ovarian and uterine complaints. Great difficulty in voiding urine; flow intermits, then flows again; prostatic or uterine affections. In urinating the water flows at first in a full stream, then stops, flows again, again stops".


Dr KENT says – This medicine is a deep, long acting antipsoric, establishing a state of disorder in the economy that is so far reaching and so long lasting that it disturbs almost all the tissues of the body.

ADVERTISEMENT INDEX

LKP Shares	Inside Front Cover	Hompath: E-clinician	Page 02
Dr M L Dhawale Mem Trust	Inside Back Cover	Aarish Academy	Page 04
J K Cement	Back Cover	Sameer Corporation	Page 22

Fr Muller Hom Med Coll Page 38

Queries and Solutions



PROF DR KASIM CHIMTHANAWALA MBBS LTMH DDV DMS (HOM) CAL, FNAHI
 President, The National Academy of Homoeopathy, India. Shaad Hospital Complex & Research Centre,
 Near Itwari Railway Station, Nagpur.
 Ph: 0712-2766286, 2532008, 2522563 • Email: adilkc@rediffmail.com

Q1. The village where I reside is endemic for Filariasis. The local government health agencies distribute Hetrazan Tablets for prevention of Filariasis. Can they be taken along with homoeopathy? Do we have any preventives for filaria in homoeopathy?

Dr SUSHIL CHANDEL (SIDDIHI-MP)

Ans – As a matter of fact, we cannot claim to have a specific preventive against a disease which has not yet affected as an epidemic. Hence on safer side, if the chances of getting the disease are more then it will not be out of place to take some non homoeopathic medicinal agent which claims to prevent the disease. However, if the patient is on constitutional treatment for any other sickness then he or she is automatically being prevented from the acute epidemic disease. If at all he / she gets the infection then it can be treated with appropriate homoeopathic remedy.

Q2. In Boericke's Materia Medica, in *Aconite-nap*, it is given, "Complaints after surgical shock and injury". My question is what complaints does a patient have after sustaining a surgical shock and what is the place of homoeopathy in managing surgical shocks?

Dr VIVEK CHAUHAN (BHOPAL)

Ans – It has been observed that the immediate manifestations of surgical shock are fainting & hypotension, profuse perspiration, acute urinary retention, convulsion, etc. In order to manage these life endangering situations, appropriate auxillary measures play a major role in maintaining the vital parameters within normal range. At our hospital we use

remedies like *Aconite-nap*, *Carbo-veg*, *Veratrum-alb*, *Pyrogen* and *Staphysagria* with unbelievable results.

Q3. What are the advantages of using LM Potencies in homoeopathic practice?

Dr ABOLI SHEMBEKAR (NAGPUR)

Ans – Nowadays we are using drugs in LM Potencies in majority of our indoor patients. The major advantages that we have experienced are – immediate results, frequent repetitions, no danger of medicinal aggravation, drug can be changed without any ill effects and it can be used well with auxillary measures. Earlier we were using fractional doses of drugs in Centiscimal potency but since the time we have shifted to LM potency, the management of acute patients has become relativmely easy.

Q4. Nowadays, it is being heard at various seminars that the drugs are being selected on the basis of themes. Please let me know in which authentic book are the themes given?

Dr ZOHER BOHRI (PUNE)

Ans – A good question indeed! It is true that homoeopathic treatment based on themes is being practiced amongst the new homoeopaths. Frankly speaking, I have not been able to lay hands on any such authentic book written by the stalwarts of yester years where the drugs are described on the basis of themes. In my practice, I strictly follow the totality approach and get majority of my cases repertorized for selection of the indicated remedies. Of course, the miasmatic state of disposition is always considered before the remedy is administered.