

27-6-2024

Homoeopathic medicine Arsenic album 200C in treatment of plaque psoriasis: A case report

Neha Nagar

Bakson Homoeopathic Medical College and Hospital, Noida, Uttar Pradesh, India, dr.neha678@gmail.com

Ravi K. Poswal

Bakson Homoeopathic Medical College and Hospital, Noida, Uttar Pradesh, India

Ajay Kumar

Bakson Homoeopathic Medical College and Hospital, Noida, Uttar Pradesh, India

Kanak Singhal

Bakson Homoeopathic Medical College and Hospital, Noida, Uttar Pradesh, India

Author(s) ORCID Identifier:

<https://orcid.org/0009-0001-7583-278x>

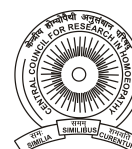Follow this and additional works at: <https://www.ijrh.org/journal>

 Part of the [Homeopathy Commons](#)

How to cite this article

Nagar N, Poswal RK, Kumar A, Singhal K. Homoeopathic medicine Arsenic album 200C in treatment of plaque psoriasis: A case report. Indian J Res Homoeopathy 2024;18:118-126.

This Case Report is brought to you for free and open access by Indian Journal of Research in Homoeopathy. It has been accepted for inclusion in Indian Journal of Research in Homoeopathy by an authorized editor of Indian Journal of Research in Homoeopathy. For more information, please contact ijrhonline@gmail.com.



Homoeopathic medicine Arsenic album 200C in treatment of plaque psoriasis: A case report

Abstract

Introduction: Psoriasis is a non-communicable, chronic, mostly painful, disfiguring disease. It can have a negative impact on patients' quality of life, which may occur at any age. The conventional treatment includes local and systemic therapies, as well as phototherapy. The need for treatment is usually lifelong as remission occurs quite frequently. **Case Summary:** We present here a case report of a 32-year-old woman with psoriatic lesions all over the body for 15 years with intolerable itching. The present case was completely cured after 1 year 6 months of regular treatment with individualised homoeopathic medicine without any adverse effects. After detailed case taking, *Arsenic album* 200C was administered. The Psoriasis Area and Severity Index (PASI) score was 49 before the treatment and 0 at the end of the treatment. The Modified Naranjo criteria for Homoeopathy (MONARCH) was used for assessing causal attribution, where the score was +8, suggesting that the clinical improvement was the result of the homoeopathic treatment. Before and after treatment photographs were taken to assess the improvement. This evidence-based case could pave way for further research into using individualised homoeopathy for plaque psoriasis.

Acknowledgments and Source of Funding

None

Homoeopathic medicine *Arsenic album* 200C in treatment of plaque psoriasis: A case report

Neha Nagar*¹, Ravi K Poswal, Ajay Kumar, Kanak Singhal

Bakson Homoeopathic Medical College and Hospital, Noida, Uttar Pradesh, India

Abstract

Introduction: Psoriasis is a non-communicable, chronic, mostly painful, disfiguring disease. It can have a negative impact on patients' quality of life, which may occur at any age. The conventional treatment includes local and systemic therapies, as well as phototherapy. The need for treatment is usually lifelong as remission occurs quite frequently. **Case Summary:** We present here a case report of a 32-year-old woman with psoriatic lesions all over the body for 15 years with intolerable itching. The present case was completely cured after 1 year 6 months of regular treatment with individualised homoeopathic medicine without any adverse effects. After detailed case taking, *Arsenic album* 200C was administered. The Psoriasis Area and Severity Index (PASI) score was 49 before the treatment and 0 at the end of the treatment. The Modified Naranjo criteria for Homoeopathy (MONARCH) was used for assessing causal attribution, where the score was +8, suggesting that the clinical improvement was the result of the homoeopathic treatment. Before and after treatment photographs were taken to assess the improvement. This evidence-based case could pave way for further research into using individualised homoeopathy for plaque psoriasis.

Keywords: *Arsenic album*, Autoimmune disorder, Homoeopathy, Psoriasis

INTRODUCTION

Psoriasis is a non-contagious autoimmune disease of the skin and joints. The word psoriasis is derived from the Greek word 'Psora' meaning itching and 'Iasis' means pain.^[1] Psoriasis affects the skin and nails and is known to have many complications. The disease can either be localised or generalised and the lesions are usually symmetrical, well-defined red pustular plaques, often covered with white or silvery scales. It mainly causes itching and pain.^[2] Psoriasis can affect physically, emotionally and socially. Overall quality of life is often greatly affected too. The most common symptoms of psoriasis reported by patients are^[3] skin peeling: 92%, pruritus: 72%, erythema: 69%, fatigue: 27%, swelling: 23%, burning: 20%, bleeding: 20% and pain.^[4]

Chronic plaque-type psoriasis accounts for about 90% of all cases of the disease. Sharply defined, erythematous, pruritic plaques covered in silvery scales are the hallmark clinical symptoms. Large amount of skin can be covered by the plaques if they merge. The scalp, the extensor surfaces of the limbs and the trunk are typical sites.^[5,6]

Multiple studies have explored the efficacy of homoeopathic treatment in cases of psoriasis. In a prospective, multicentric

observational study evaluating the details and impact of homoeopathic treatment in psoriasis patients receiving standard medical care, diagnoses and severity of symptoms notably improved, yielding large effect sizes. In addition, there was a marked improvement in the patients' quality of life, coupled with a significant reduction in conventional treatment usage and health-care service utilisation.^[7] A case series demonstrates the potential usefulness of classical homoeopathy in addressing psoriasis and associated outcomes. It presents six psoriasis cases with varying degrees of severity. Erythroderma was reported to occur in two cases, one of which progressed to septicæmia. All of them received individualised homoeopathic treatment, and as a result, the overall health and Psoriasis Area and Severity Index (PASI) scores of the patients improved.^[8] In another report, regular homoeopathic treatment significantly reduced the severity of psoriasis and improved quality of

***Address for correspondence:** Neha Nagar,
Bakson Homoeopathic Medical College & Hospital, Greater Noida,
Uttar Pradesh, India.
E-mail: dr.neha678@gmail.com

Received: 08 June 2023; **Accepted:** 14 June 2024

Access this article online

Quick Response Code:



Website:
www.ijrh.org

DOI:
10.53945/2320-7094.1894

This is an open access journal, and articles are distributed under the terms of the Creative Commons Attribution-NonCommercial-ShareAlike 4.0 License, which allows others to remix, tweak, and build upon the work non-commercially, as long as appropriate credit is given and the new creations are licensed under the identical terms.

How to cite this article: Nagar N, Poswal RK, Kumar A, Singhal K. Homoeopathic medicine *Arsenic album* 200C in treatment of plaque psoriasis: A case report. Indian J Res Homoeopathy 2024;18:118-126.

life.^[9] Various other studies also provide evidence in favour of homoeopathic treatment for different types of psoriasis, without any side effects.^[10-13] This case report is an attempt to emphasise the positive effect of individualised treatment of psoriasis with Homoeopathy. The case is being reported in accordance with HOM-CASE guidelines.^[14]

PATIENT INFORMATION

On February 4, 2021, a 32-year-old female patient, a homemaker, presented with raised, scaly lesions persisting for 15 years, predominantly affecting her back, hands and legs that bled upon scratching. The lesions were red with marked scaling and intolerable itching. Her itching was aggravated by cold air, washing the affected part, warmth of the bed and while undressing.

The complaint started 15 years back, while she was working in her farm where she was attacked by an unknown insect that caused severe itching with urticarial rashes all over the body. She took conventional treatment (anti-allergic drug) for 15 days and got cured. But a few days later, she noticed some red raised lesions on her hands that gradually spread all over the body with itching and pain at the time of onset. She took conventional treatment (topical corticosteroid ointment and other prescribed allopathic drugs) with some temporary relief. Every year, she had a relapse of the complaints during the winter season. Since the results from conventional treatment were not long lasting, she opted for the homoeopathic treatment.

She lived in a village, was married and had two children. She had a good relationship with her husband and children. Her mother suffered from bronchial asthma and her father had the same type of psoriatic lesions. No other relevant medical history was noticed during the case taking.

Clinical findings

The site of onset of the lesions was her back, hands and legs. The direction of the spread of lesions was centripetal. The erythematous plaques of varying size, covered with white scales, on thick and dry well-demarcated body were found to be present

on the affected sites. The distribution of scales was symmetrical, bilateral and scattered all over the body. Her skin was icy cold to touch. This coldness was also verified on examination.

Generals

The patient had an increased appetite and wanted to eat even after a full meal. She was completely thirstless and could not drink enough, even though she knew that she should drink more water. She had a desire for cold milk. Her urine was offensive. She was extremely chilly and wanted to cover herself with some extra light clothes every time. She also said that her body always remained cold, just like ice.

Moreover, her illness had left her feeling abandoned. Her mother-in-law used to constantly criticise her for having skin issues. She wanted to end her life since she believed that her illness was incurable. Her husband and her kids were the only members of her family who seemed to be interested in talking to her. She wanted to escape somewhere, but she was always stopped from doing so by her children. She used to get very tearful during her anxious period. She avoided social events due to her skin issue.

Diagnostic assessment

On examination, the Auspitz sign was found to be positive. Based on the clinical findings and history, the diagnosis was confirmed to be plaque psoriasis.

Totality of symptoms

After analysis and evaluation of the symptoms, the totality was constructed based on the following symptoms:

- Forsaken feeling
- Wants to commit suicide
- Wants to run away
- Weeps in anxiety
- Ravenous appetite
- Thirstless but wants to drink
- Cold milk desire
- Offensive smell of urine
- Extremely chilly and wants to cover herself by some extra light clothes every time
- Psoriatic lesions with intolerable itching

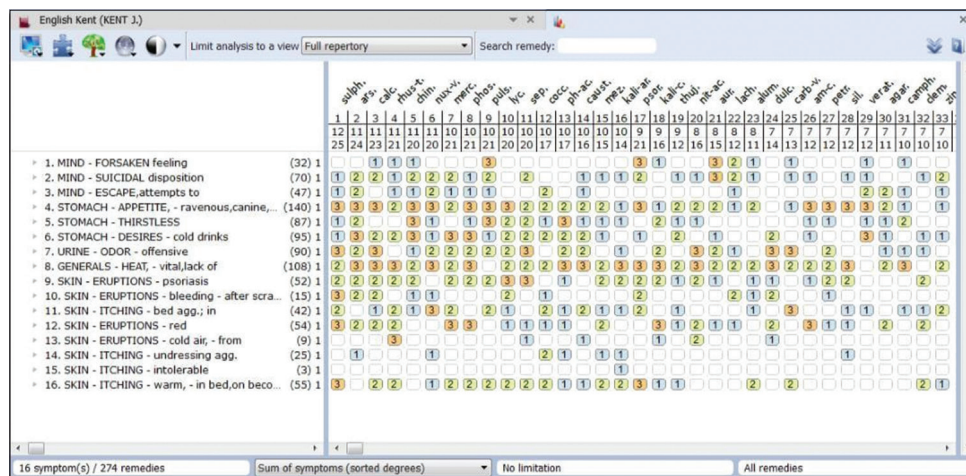


Figure 1: Repertorisation chart

- Blood comes out while she scratches
- Lesions are red with marked scaling
- Aggravation by cold air, washing, warmth of bed and while undressing.

Repertorisation was done with the help of Radar 10 software.^[15]

Therapeutic intervention

After repertorisation, *Sulphur*, *Arsenic album*, *Calcarea carbonica* and *Psorinum* came up as the leading medicines [Figure 1]. After eliminating *Sulphur* (being a hot remedy), we

further excluded *Calcarea carbonica* and *Psorinum*, as these medicines did not have the peculiar potential differential field symptoms, such as icy coldness of the body and the feeling that her disease was incurable. *Arsenicum album* was finally selected, conforming to materia medica, and covered all the symptoms.^[16]

The potency and dosage were determined based on the susceptibility as per the patient's age, pathology and the disease's nature. All the medicines were administered orally. One single dose consisted of five medicated globules of size 30 followed by identical looking placebo. Placebos were advised to be taken thrice daily every day for 15 days.^[17] In between

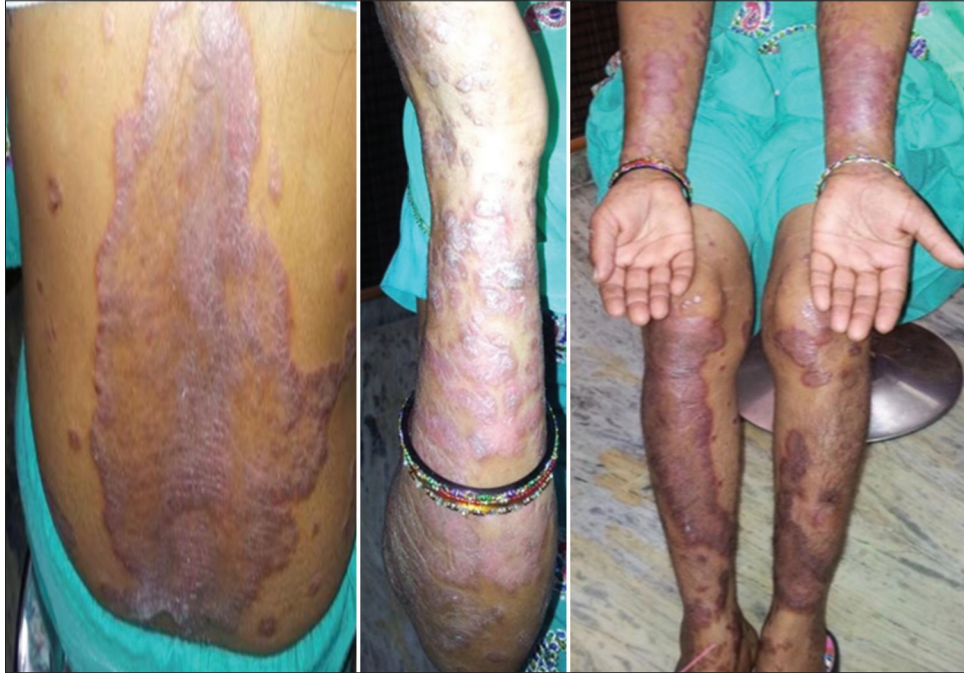

Figure 2: Before treatment (04 February, 2021)

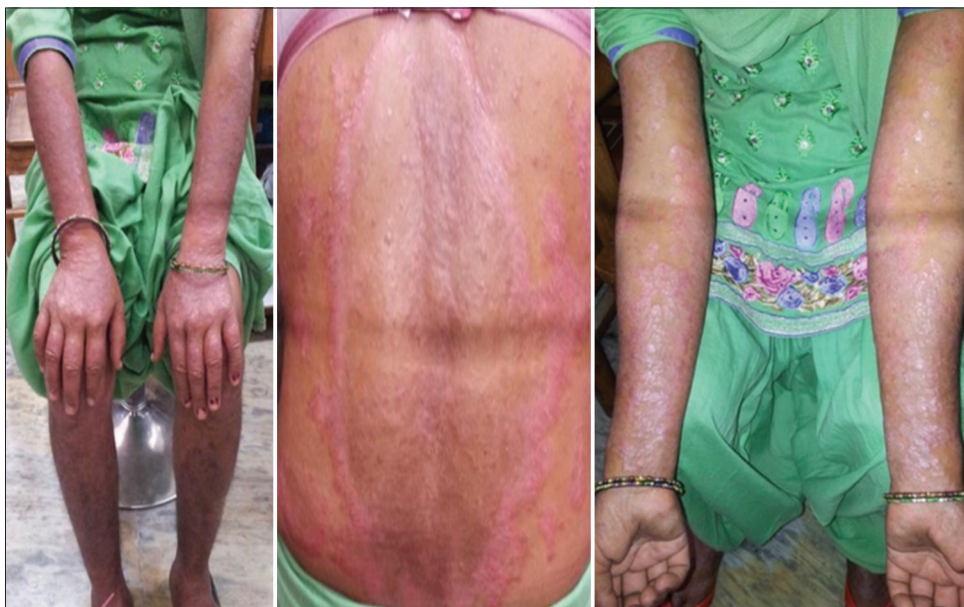

Figure 3: During treatment (19 February 2021–4 April 2022)

Table 1: Follow-up details

Follow-up date	Indication of prescription	Medicine with dose
4 th February, 2021 1 st visit	Psoriatic lesions with intolerable itching, bloody discharge while scratching, red lesions with marked scaling, aggravation by cold air, washing, warmth of bed and while undressing.	<i>Arsenicum album</i> 200C/1 dose
19 th February, 2021 1 st follow-up	Psoriatic patches - No relief Intolerable Itching - slightly reduced Bleeding - slightly better, now on excessive movement only.	No medicine was prescribed as improvement continued
25 th February, 2021 2 nd follow-up	Itching - slightly better, but still occurred. Patches started to reduce mainly from the back. Appetite - increased Thirst - no change.	No medicine was prescribed as improvement continued
5 th March, 2021 3 rd follow-up	Her itching and scaling were improving. Patches started to dry from hands and chest also, but she complained of headache for the past 2 days due to some family matter. Thirst- better than before.	No medicine was prescribed as improvement continued
7 th April, 2021 4 th follow-up	Patient did not come on this visit; her husband told that she was feeling much better.	No medicine was prescribed as improvement continued
9 th May, 2021 5 th follow-up	Loss of appetite with marked gas formation in the upper abdomen after eating food in function. Itching reduced Bleeding better.	No medicine was prescribed as improvement continued
5 th June, 2021 6 th follow-up	All general complaints were better.	No medicine was prescribed as improvement continued
10 th July, 2021 7 th follow-up	Her back and upper extremities almost cured, slight itching still there, bleeding improved.	No medicine was prescribed as improvement continued
16 th August, 2021 8 th follow-up	All general complaints started improving, she felt better and the offensive smell in urine gone.	No medicine was prescribed as improvement continued
12 th October, 2021 9 th follow-up	No further improvement in skin symptoms as well as physical symptoms.	<i>Arsenic album</i> 200C/1 dose
11 th November, 2021 10 th follow-up	She felt better in all aspects mentally as well as physically, her appetite and thirst also normal.	No medicine was prescribed as improvement continued
15 th January, 2022 11 th follow-up	Itching better now Scaling and redness - better.	No medicine was prescribed as improvement continued
19 th February, 2022 12 th follow-up	All general complaints better. Mentally, the patient is relaxed. Feeling positive regarding ongoing treatment	No medicine was prescribed as improvement continued
04 th April, 2022 13 th follow-up	Itching - reduced Scaling - better now Lesions almost gone from the chest, back, hand and feet.	No medicine was prescribed as improvement continued
12 th June, 2022 14 th follow-up	Feeling better, no scaling, no itching Mentally too, she felt good.	No medicine was prescribed as improvement continued

Table 2: Lesion score

Erythema (E) Induration (I) Scaling (S)	No symptom	Mild	Moderate	Marked	Very marked
Score	0	1	2	3	4

Table 3: Area score

Area	0	1-9%	10-29%	30-49%	50-69%	70-89%	90-100%
Score	0	1	2	3	4	5	6

or during the follow-ups, when the physician did not feel the need of repetition of the medicine, placebo was prescribed.

Follow-up and outcomes

After the administration of this remedy twice over the course of 1 year 6 months, psoriatic patches from back, legs and hands completely disappeared with the individualised homoeopathic treatment. Photographic evidence collected before, during and after the treatment are presented in Figures 2-4. The follow-up details are given in Table 1. Her PASI score,^[18] which was 49 at the start of the treatment was eventually reduced to 0 as seen in Table 2 (lesion score), Table 3 (area score), Table 4 (before treatment) and Table 5 (after treatment).

DISCUSSION

Psoriasis is an autoimmune skin condition, which has a limited scope of treatment in modern medicine. This case report

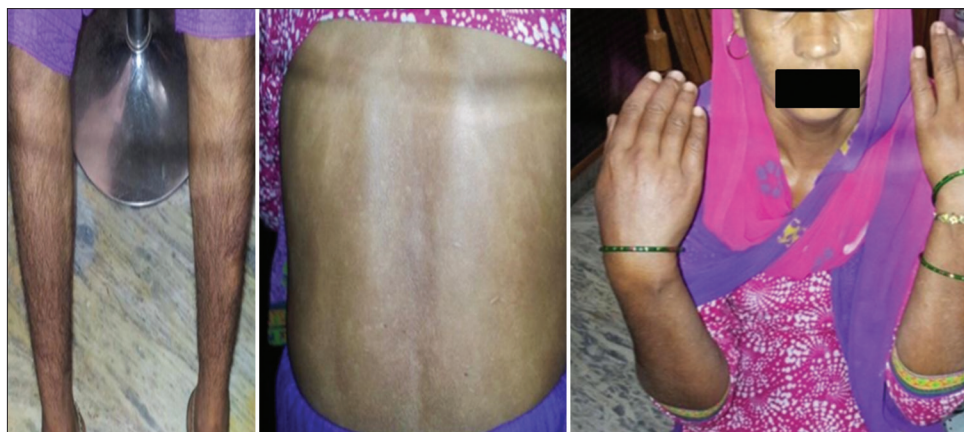

Figure 4: After treatment (12 June 2022)

Table 4: Before treatment						
Intensity score	Head and neck		Upper limb	Trunk	Lower limb	
Erythema (E)	0		3	3	4	
Indurations (I)	0		3	3	4	
Scaling (S)	0		4	4	4	
SUM: E+I + S=S	0		10	10	12	
	A1=0		A2=10	A3=10	A4=12	
Intensity score: $A \times 0.1 - 0.4 = B$	$A1 \times 0.1 = 0$		$A2 \times 0.2 = 2$	$A3 \times 0.3 = 3$	$A4 \times 0.4 = 4.8$	
	B1=0		B2=2	B3=3	B4=4.8	
Area score	Head and neck		Upper limb	Trunk	Lower limb	
Percentage of affected area	0		5	5	5	
Area score: $B \times \text{affected area} = C$	$0 \times 0 = 0$		$2 \times 5 = 10$	$3 \times 5 = 15$	$4.8 \times 5 = 24$	
	C1=0		C2=10	C3=15	C4=24	

Table 5: After treatment					
Intensity score	Head and neck	Upper limb	Trunk	Lower limb	
Erythema (E)	0	0	0	0	
Indurations (I)	0	0	0	0	
Scaling (S)	0	0	0	0	
SUM: E+I + S=S	0	0	0	0	
Area score	Head and neck	Upper limb	Trunk	Lower limb	
Percentage of affected area	0	0	0	0	
PASI score= $C1+C2+C3+C4=49$. After treatment-PASI score=0					

describes the role of the homoeopathic medicine *Arsenic album* 200C in treatment of plaque psoriasis. *Arsenic album* was given after repertorisation and after consultation of materia medica. While upon repertorisation, *Sulphur* and *Arsenic album* [Figure 1] came close, *Sulphur* covered the maximum rubrics with the highest marks, but the patient was chilly. Upon further inquiry, we could not find the characteristics symptoms of *Sulphur* in the patient. In this case of plaque psoriasis, severe symptoms such as scaling, bleeding and intolerable itching were seen to improve successfully with *Arsenic album* in 200C potency. During the follow-ups, all the complaints of the patient progressively decreased without any

aggravation, which confirms to Kent’s fourth observation of “no aggravation with recovery of the patient”, which indicates that the patient was given the correct remedy and in the right potency. Dr Hahnemann also mentioned in § 191 ‘Internal administration of a remedy causes important changes in general health and particularly in the affected external parts. It restores health of the entire body, along with the disappearance of the external affections’.^[19] In a prospective and observational study, homoeopathic remedies such as *Arsenicum album*, *Hydrocotyle asiatica*, *Ignatia amara*, *Tuberculinum*, *Calcarea carbonica*, *Kali arsenicosum*, *Lycopodium clavatum*, *Natrum muriaticum*, *Nux vomica*, *Opium*, *Petroleum*, *Psorinum*, *Sepia*, *Sulphur* and *Thyroidinum* were found to be effective in the treatment of psoriasis.^[20]

The improvement in this case was documented through photographs and PASI score, which was seen to reduce to zero. For evaluating the clinical severity of psoriasis quantitatively, this score is the highest that has been validated, and it is still reported to be the most reliable single scoring system for determining the severity of plaque psoriasis.^[21] The Modified Naranjo Criteria for Homoeopathy^[22] used for causality assessment showed that homoeopathic medication could be the reason behind the improvement in the case, with the score of +8 (Table 6). The patient was further observed for six months.

Table 6: Modified Naranjo Criteria for Homoeopathy

Domains	Yes	No	Not sure or N/A
1. Was there an improvement in the main symptom or condition for which the homoeopathic medicine was prescribed?	+2		
2. Did the clinical improvement occur within a plausible time frame relative to the medicine intake?	+1		
3. Was there a homeopathic aggravation of symptoms?			
4. Did the effect encompass more than the main symptom or condition (i.e., were other symptoms, not related to the main presenting complaint, improved or changed)?	+1		
5. Did overall well-being improve? (suggest using a validated scale or mention about changes in physical, emotional and behavioural elements)		0	
6. (A) Direction of cure: Did some symptoms improve in the opposite order of the development of symptoms of the disease? (B) Direction of cure: Did at least one of the following aspects apply to the order of improvement in symptoms -from organs of more importance to those of less importance? -from deeper to more superficial aspects of the individual? -from the top downwards?		0	
7. Did 'old symptoms' (defined as non-seasonal and non-cyclical symptoms that were previously thought to have resolved) reappear temporarily during the course of improvement?		0	
8. Are there alternative causes (i.e., other than the medicine) that – with a high probability – could have produced the improvement? (consider the known course of the disease, other forms of treatment and other clinically relevant interventions)		+1	
9. Was the health improvement confirmed by any objective evidence? (e.g., investigations, clinical examination, etc.)	+2		
10. Did repeat dosing, if conducted, create similar clinical improvement?		0	
Total score:+8			

She did not develop any lesions or itching during this period.

This case demonstrates that homoeopathy, when used with an individualised approach, can be effective in treating plaque psoriasis. As this is a single case study and plaque psoriasis is notorious to have unpredictable remissions, well-designed, randomised, controlled studies can be used as gold standard for firmer evidence.

CONCLUSION

Homoeopathy can be effective in treatment of plaque psoriasis, by reducing the severity of symptoms, as well as by enhancing the quality of life.

Declaration of the patient's consent

The authors certify that the patient had given her consent for using her non-revealing photographs and other clinical information for reporting this case in the journal. She understands that the name and initials will not be published, and due efforts will be made to conceal the identity.

Financial support and sponsorship

Nil.

Conflict of interest

None declared.

REFERENCES

- Ritchlin CT, Fitzgerald O. Psoriatic and Reactive Arthritis: A Companion to Rheumatology. Philadelphia, PA: Mosby; 2007. p. 256.
- Pariser D, Schenkel B, Carter C, Farahi K, Brown TM, Ellis CN, *et al.* A multicenter, non-interventional study to evaluate patient-reported experiences of living with psoriasis. *J Dermatol Treat* 2016;27:19-26.
- Dubertret L, Mrowietz U, Ranki A, Van De Kerkhof PC, Chimenti S, Lotti T, *et al.* European patient perspectives on the impact of psoriasis: The EUROPSO patient membership survey. *Br J Dermatol*

2006;155:729-36.

- World Health Organization. Psoriasis. Available from: <https://www.who.int/docs/default-source/ncds/psoriasis-info-sheet-3.pdf?sfvrsn=a5d14e81> [Last accessed on 2023 Aug 01].
- Ortonne JP, Chimenti S, Luger T, Puig L, Reid F, Trueb RM. Scalp psoriasis: European consensus on grading and treatment algorithm. *J Eur Acad Dermatol Venereol* 2009;23:1435-44.
- Nestle FO, Kaplan DH, Barker J. Psoriasis. *N Engl J Med* 2009;361:496-509.
- Witt CM, Ludtke R, Willich SN. Homeopathic treatment of patients with Psoriasis-A prospective observational study with 2 years follow-up. *J Eur Acad Dermatol Venereol* 2009;23:538-43.
- Mahesh S, Shah V, Mallappa M, Vithoulkas G. Psoriasis cases of same diagnosis but different phenotypes-Management through individualized homoeopathic therapy. *Clin Case Rep* 2019;7:1499-507.
- Taneja D, Sadhukhan M, Rath P, Sarangi MR, Mittal R, Prusty AK, *et al.* Open-label study to evaluate the response to homeopathic treatment of psoriasis. *OBM Integr Complement Med* 2022;7:1-19.
- Nwabudike LC. Psoriasis and homeopathy. *Proc Rom Acad Ser* 2011;3:237-42.
- Mandal S, Biswas B. An evidence-based case of planter psoriasis treated by individualized homoeopathic medicine. *Int J Ayush Case Rep* 2021;5:84-90.
- Rahman S, Dey JK. A case report of plantar Psoriasis treated with homoeopathy. *Homoeopathic Links* 2018;31:248-53.
- Nagar N, Poswal RK. Efficacy of individualized homoeopathic treatment in psoriasis-A case report. *Homoeopathic Heritage* 2023;49:52-4.
- Van Haselen RA. Homeopathic clinical case reports: Development of a supplement (HOM-CASE) to the CARE clinical case reporting guideline. *Complement Ther Med* 2016;25:78-85.
- Schroyens F. RADAR10 Homoeopathic Repertory Software. CDROM. Available from: <http://www.archibel.com/radar10.html> [Last accessed on 2020 Jun 23].
- Boericke W. Boericke's New Manual of Homoeopathic Treatment with Repertory. 3rd ed. New Delhi: B. Jain Publishers Pvt. Ltd; 2010. p. 79-81, 620-3.
- Close S. Homoeopathic posology. In: *The Genius of Homoeopathy, Lecture, and Essays on Homoeopathic Philosophy*. New Delhi: B. Jain Publishers Pvt. Ltd; 2001. p. 183-212.
- Oakley A. PASI (Psoriasis Area and Severity Index). *DermNet*. Available from: <https://dermnetnz.org/topics/pasi-score> [Last accessed on 2023 Aug 01].

19. Hahnemann S. Organon of Medicine. 6th ed. New Delhi: B. Jain Publishers Pvt. Ltd; 1996. p. 160.
20. Singh H, Manchanda RK, Arora S. Evaluation of homoeopathic drugs in psoriasis. CCRH Quar Bull 1990;12:22-8.
21. Manchanda Y, De A, Das S, Chakraborty D. Disease assessment in psoriasis. Indian J Dermatol 2023;68:278-81.
22. Lamba CD, Gupta VK, Van Haselen RA, Rutten L, Mahajan N, Molla AM, *et al.* Evaluation of the modified naranjo criteria for assessing causal attribution of clinical outcome to homeopathic intervention as presented in case reports. Homeopathy 2020;109:191-7.

Médecine homéopathique Arsenic album 200 dans le traitement du psoriasis en plaques : un rapport de cas

Introduction: Le psoriasis est une maladie non transmissible, chronique, principalement douloureuse et défigurante. Elle peut avoir un impact négatif sur la qualité de vie des patients, qui peut survenir à tout âge. Le traitement conventionnel comprend des thérapies locales et systémiques, ainsi que la photothérapie. Le besoin de traitement est généralement à vie car la rémission se produit assez fréquemment. **Résumé de cas:** Nous présentons ici un rapport de cas d'une femme de 32 ans présentant des lésions psoriasiques sur tout le corps depuis 15 ans avec des démangeaisons intolérables. Le cas présent a été complètement guéri après 1 an 6 mois de traitement régulier avec une médecine homéopathique individualisée sans aucun effet indésirable. Après une étude détaillée du cas, l'album d'arsenic 200C a été administré. Le score de l'indice PASI (Psoriasis Area and Severity Index) était de 49 avant le traitement et de 0 à la fin du traitement. Les critères modifiés de Naranjo pour l'homéopathie (MONARCH) ont été utilisés pour évaluer l'attribution causale, où le score était de +8, suggérant que l'amélioration clinique était le résultat du traitement homéopathique. Des photos avant et après le traitement ont été prises pour évaluer l'amélioration. Ce cas fondé sur des preuves pourrait ouvrir la voie à d'autres recherches sur l'utilisation de l'homéopathie individualisée pour le psoriasis en plaques.

Homöopathische Medizin Arsenalbum 200 bei der Behandlung von Plaque-Psoriasis: Ein Fallbericht

Einleitung: Psoriasis ist eine nicht übertragbare, chronische, meist schmerzhaft, entstellende Krankheit. Es kann sich negativ auf die Lebensqualität der Patienten auswirken, was in jedem Alter auftreten kann. Die konventionelle Behandlung umfasst lokale und systemische Therapien sowie Phototherapie. Die Notwendigkeit einer Behandlung ist in der Regel lebenslang, da eine Remission recht häufig auftritt. **Fallzusammenfassung:** Wir präsentieren hier einen Fallbericht einer 32-jährigen Frau mit Psoriasis-Läsionen am ganzen Körper seit 15 Jahren mit unerträglichem Juckreiz. Der vorliegende Fall wurde nach 1 Jahr und 6 Monaten regelmäßiger Behandlung mit individualisierter homöopathischer Medizin ohne Nebenwirkungen vollständig geheilt. Nach eingehender Fallaufnahme wurde Arsenalbum 200C verabreicht. Der Psoriasis Area and Severity Index (PASI) lag vor der Behandlung bei 49 und am Ende der Behandlung bei 0. Das modifizierte Naranjo-Kriterium für Homöopathie (MONARCH) wurde zur Beurteilung der kausalen Attribution verwendet, wobei der Score +8 betrug, was darauf hindeutet, dass die klinische Verbesserung das Ergebnis der homöopathischen Behandlung war. Vor und nach der Behandlung wurden Fotos gemacht, um die Verbesserung zu beurteilen. Dieser evidenzbasierte Fall könnte den Weg für weitere Forschungen zur Verwendung der individualisierten Homöopathie bei Plaque-Psoriasis ebnen.

होम्योपैथी दवा आर्सेनिक एल्बम 200 प्लाक सोरायसिस के उपचार में: एक केस की रिपोर्ट

परिचय: सोरायसिस एक गैर-संचारी, दीर्घकालिक, ज्यादातर दर्दनाक, विरूपित करने वाली बीमारी है। यह रोगियों के जीवन की गुणवत्ता पर नकारात्मक प्रभाव डाल सकती है, जो किसी भी उम्र में हो सकती है। पारंपरिक उपचार में स्थानीय और प्रणालीगत उपचार, साथ ही फोटोथेरेपी भी शामिल है। ऐसे उपचार की आवश्यकता आमतौर पर आजीवन होती है। **केस सारांश:** यहां एक 32 वर्षीय महिला की केस रिपोर्ट प्रस्तुत है, जिसमें असहनीय खुजली के साथ 15 साल तक पूरे शरीर में सोरायसिस घाव थे। वर्तमान केस बिना किसी प्रतिकूल प्रभाव के व्यक्तिगत होम्योपैथी दवा के साथ 1 वर्ष 6 महीने के नियमित उपचार के बाद पूरी तरह से ठीक हो गया था। विस्तृत केस लेने के बाद, आर्सेनिक एल्बम 200C दी गई। सोरायसिस क्षेत्र और गंभीरता सूचकांक (पीएसआई) स्कोर उपचार से पहले 49 और उपचार के अंत में शून्य था। होम्योपैथी के लिए संशोधित नारंजो मानदंड का उपयोग कारणात्मक आरोपण का आकलन करने के लिए किया गया था, जहां स्कोर +8 था, मतलब कि नैदानिक सुधार होम्योपैथी उपचार का परिणाम था। सुधार का आकलन करने के लिए उपचार से पहले और बाद में तस्वीरें ली गईं। यह साक्ष्य-आधारित मामला प्लाक सोरायसिस के लिए व्यक्तिगत होम्योपैथी का उपयोग करने में आगे के शोध का मार्ग प्रशस्त कर सकता है।

Medicina homeopática Álbum de arsénico 200 en el tratamiento de la psoriasis en placas: informe de un caso

Introducción: La psoriasis es una enfermedad no transmisibles, crónica, mayoritariamente dolorosa y desfigurante. Puede tener un impacto negativo en la calidad de vida de los pacientes, que puede ocurrir a cualquier edad. El tratamiento convencional incluye terapias locales y sistémicas, así como fototerapia. La necesidad de tratamiento suele ser de por vida, ya que la remisión se produce con bastante frecuencia. **Resumen del caso:** Presentamos el caso clínico de una mujer de 32 años con lesiones psoriásicas en todo el cuerpo desde hace 15 años con prurito intolerable. El presente caso se curó completamente después de 1 año y 6 meses de tratamiento regular con medicina homeopática individualizada sin efectos adversos. Después de una toma detallada del caso, se administró el álbum de arsénico 200C. La puntuación del Índice de Área y Gravedad de la Psoriasis (PASI) fue de 49 antes del tratamiento y de 0 al final del mismo. Para evaluar la atribución causal se utilizó el Criterio Naranjo Modificado para la Homeopatía (MONARCH), donde la puntuación fue de +8, lo que sugiere que la mejoría clínica fue el resultado del tratamiento homeopático. Se tomaron fotografías antes y después del tratamiento para evaluar la mejoría. Este caso basado en la evidencia podría allanar el camino para futuras investigaciones sobre el uso de la homeopatía individualizada para la psoriasis en placas.

顺势疗法药物砒专辑 200 治疗斑块状银屑病：病例报告

简介： 牛皮癣是一种非传染性的慢性疾病，主要是疼痛的毁容性疾病。它可能对患者的生活质量产生负面影响，这可能发生在任何年龄。常规治疗包括局部和全身治疗，以及光疗。治疗的需要通常是终生的，因为缓解经常发生。

病例摘要： 我们在此介绍一名 32 岁女性的病例报告，她全身银屑病病变 15 年，瘙痒难以忍受。本病例在 1 年 6 个月的个体化顺势疗法药物常规治疗后完全治愈，没有任何不良反应。经过详细的病例处理，砒专辑 200C 被管理。治疗前银屑病面积和严重程度指数（PASI）评分为 49，治疗结束时为 0。使用改良的 Naranjo 顺势疗法标准（MONARCH）评估因果归因，得分为 +8，表明临床改善是顺势疗法治疗的结果。拍摄治疗前后的照片以评估改善情况。这个基于证据的病例可以为进一步研究使用个体化的顺势疗法治疗斑块状银屑病铺平道路。