

27-6-2024

Laryngopharyngeal reflux disease with vocal cord oedema treated with individualised homoeopathic medicine: A case report

Partha Pratim Pal

Dr. Anjali Chatterji Regional Research Institute for Homoeopathy, Kolkata, India, justdoit.parpa007@gmail.com

Laijun Nahar

Regional Research Institute of Homoeopathy, Agartala, India, laiun786@gmail.com

Author(s) ORCID Identifier:

<https://orcid.org/0000-0002-2127-3310>


Follow this and additional works at: <https://www.ijrh.org/journal>

 Part of the [Homeopathy Commons](#)

How to cite this article

Pal PP, Nahar L. Laryngopharyngeal reflux disease with vocal cord oedema treated with individualised homoeopathic medicine: A case report. Indian J Res Homoeopathy 2024;18:110-117.

This Case Report is brought to you for free and open access by Indian Journal of Research in Homoeopathy. It has been accepted for inclusion in Indian Journal of Research in Homoeopathy by an authorized editor of Indian Journal of Research in Homoeopathy. For more information, please contact ijrhonline@gmail.com.



Laryngopharyngeal reflux disease with vocal cord oedema treated with individualised homoeopathic medicine: A case report

Abstract

Introduction: The diagnosis of laryngopharyngeal reflux disease (LPRD) is still ambiguous due to limited and cumbersome diagnostic standards. To achieve regression of both symptoms and laryngeal findings due to LPRD, it typically requires more vigorous and sustained treatment. In certain patients with chronic acid or non-acid reflux, surgery may be helpful. **Case Summary:** This is the case of a 68-year-old man who was diagnosed with LPRD and had vocal cord oedema. Individualised homoeopathic medicine, *Natrum sulphuricum*, was prescribed, and the patient improved steadily in terms of signs and symptoms and had no further complaints at the end of 16 months. The patient's improvement was assessed using the outcome related to the impact on daily living scale (ORIDL). Clinical improvement was correlated with objective evidence from the laryngoscopy report. The Modified Naranjo Criteria for Homoeopathy score (+8 on the '-6 to +13' scale) determines if the patient's progress can be attributed to the homoeopathic treatment. This case report implies that homoeopathy may be an appropriate choice for treating LPRD with vocal cord oedema cases. This is the rare instance of a documented LPRD case report associated with vocal cord oedema followed by a successful therapeutic homoeopathic treatment. For further conclusion regarding the disease, more studies are warranted.

Acknowledgments and Source of Funding

Acknowledgments - The authors gratefully acknowledge the patient for his active cooperation and participation. Financial support and sponsorship - Nil.

Laryngopharyngeal reflux disease with vocal cord oedema treated with individualised homoeopathic medicine: A case report

Partha Pratim Pal¹ , Lajjun Nahar^{2*} 

¹Dr. Anjali Chatterji Regional Research Institute for Homoeopathy, Kolkata, India

²Regional Research Institute of Homoeopathy, Agartala, India

Abstract

Introduction: The diagnosis of laryngopharyngeal reflux disease (LPRD) is still ambiguous due to limited and cumbersome diagnostic standards. To achieve regression of both symptoms and laryngeal findings due to LPRD, it typically requires more vigorous and sustained treatment. In certain patients with chronic acid or non-acid reflux, surgery may be helpful. **Case Summary:** This is the case of a 68-year-old man who was diagnosed with LPRD and had vocal cord oedema. Individualised homoeopathic medicine, *Natrum sulphuricum*, was prescribed, and the patient improved steadily in terms of signs and symptoms and had no further complaints at the end of 16 months. The patient's improvement was assessed using the outcome related to the impact on daily living scale (ORIDL). Clinical improvement was correlated with objective evidence from the laryngoscopy report. The Modified Naranjo Criteria for Homoeopathy score (+8 on the '-6 to +13' scale) determines if the patient's progress can be attributed to the homoeopathic treatment. This case report implies that homoeopathy may be an appropriate choice for treating LPRD with vocal cord oedema cases. This is the rare instance of a documented LPRD case report associated with vocal cord oedema followed by a successful therapeutic homoeopathic treatment. For further conclusion regarding the disease, more studies are warranted.

Keywords: Laryngopharyngeal reflux disease, Modified Naranjo Criteria for Homoeopathy, *Natrum sulphuricum*, Outcome in relation to impact on daily living, Vocal cord oedema, Homoeopathy

INTRODUCTION

The reflux of gastric contents into the larynx, pharynx and other areas of the upper aerodigestive tract leading to throat symptoms is referred to as laryngopharyngeal reflux disease (LPRD). The frequency of this inflammatory illness is incredibly high; according to epidemiological studies, it is around 5–30%.^[1] LPRD is associated with symptoms of laryngeal irritation such as throat clearing, coughing, and hoarseness of voice. The main diagnostic methods currently used are laryngoscopy and pH monitoring. The most common laryngoscopic signs are redness and swelling of the throat.^[2]

As a relatively recent clinical diagnosis, LPRD is thought to have a wide range of clinical presentations that are treated by several branches of medicine, frequently without a clear diagnosis.^[3] It is still regarded in gastroenterology as a symptom of gastro-oesophageal reflux disease (GERD).^[2] Although it has

a connection to GERD, it has a different set of symptoms and after-effects. A step-up-type programme of dietary and lifestyle modifications combined with pharmacologic antisecretory therapy constitutes the mainstay of medical treatment.^[4]

Patients with LPRD initially consult with their primary care providers, and since more advanced treatment may require a multidisciplinary approach, it is crucial to have a cohesive strategy across specialists when caring for these patients.^[3] Some laryngopharyngeal reflux (LPR) patients experience inadequate disease resolution despite receiving medical care.^[4] Untreated LPRD can be one of the aetiological causes of laryngeal cancer. The development of the disease can be

***Address for correspondence:** Lajjun Nahar,
Regional Research Institute of Homoeopathy, Agartala, India.
E-mail: laijun786@gmail.com

Received: 06 June 2023; Accepted: 16 May 2024

Access this article online

Quick Response Code:



Website:
www.ijrh.org

DOI:
10.53945/2320-7094.1890

This is an open access journal, and articles are distributed under the terms of the Creative Commons Attribution-NonCommercial-ShareAlike 4.0 License, which allows others to remix, tweak, and build upon the work non-commercially, as long as appropriate credit is given and the new creations are licensed under the identical terms.

How to cite this article: Pal PP, Nahar L. Laryngopharyngeal reflux disease with vocal cord oedema treated with individualised homoeopathic medicine: A case report. *Indian J Res Homoeopathy* 2024;18:110-117.

benign or malignant and life-threatening, and its entire form can considerably affect life quality in patients.^[2] Additionally, problems with compliance and the ineffectiveness of acid suppression may prompt the use of alternative therapeutic techniques.^[4] As a first line of treatment for patients with suspected LPR, a double-dose empiric trial with proton pump inhibitors (PPIs) has been suggested. The initial trial of medicines is at least 6 months at a twice-a-day dosage (depending on the severity of LPR changes seen on examination) because of the high sensitivity of the mucosal membrane in the pharynx and larynx.^[5,6] PPIs are not superior to placebos in the treatment of LPR, according to a recent comprehensive evaluation.^[5] LPR disease is still linked to recurrent symptoms and a poor quality of life that comes at a high cost to the patient and society.^[7] If this ailment can be successfully treated with homoeopathic medications without the use of surgery, it will provide patients with a cost-effective, non-invasive therapy option.

After a thorough literature search, not a single article on the homoeopathic treatment of LPRD and vocal cord oedema could be found, although there were many articles where homoeopathic medicines were reported to be beneficial in cases of other laryngeal disorders and GERD.^[8-11] Following the HOM-CASE CARE^[12] guidelines, the treatment outcome of a patient with LPRD and vocal cord oedema is described in this case report. Such documentation is intended to strengthen the point that Homoeopathy can reverse pathological changes in cases that are curable, in addition to relieving symptoms.

PATIENT INFORMATION

A 68-year-old male patient came to the outpatient department of Dr. Anjali Chatterji Regional Research Institute for Homoeopathy, Kolkata, on September 7th, 2021, with a complaint of pain in the throat during deglutition and a constant tendency to hem and hawk to get the throat cleared. He was also complaining of a sensation of obstruction in the throat while swallowing and dyspnoea during walking or physical exertion. He also complained of a constant rattling cough, shortness of breath during coughing episodes and heartburn, especially after meals.

His complaints started six months ago, and he took conventional medication without any improvement.

Past history

The patient had a cerebrovascular accident (CVA) in 2007 and was on allopathic medicines for hypertension (HTN) and dyslipidaemia since then. The ultrasonography (November 25, 2020) of the kidney, ureter, bladder (KUB) and prostate showed post-void residual urine volume = 18.25 cc, and no other abnormalities were detected in the investigation.

Family history

Both his parents had hypertension. No LPRD-related illness was present in the family history.

Personal history

The patient came from a middle-class background. He used to smoke and drink, but he quit both 16 years ago, after suffering from a cerebral vascular accident.

Clinical findings

The weight of the patient was 66 kg, and his height was 5 ft. 5 inches. On inspection, there was no cyanosis, jaundice, oedema or pallor. His blood pressure was slightly high and recorded as 160/86 mm Hg at the time of presentation.

Generals

The patient had a good memory. He would get irritated and angry over minor issues and have vomiting during acute episodes. The patient had a thermal reaction towards hot. Though he had a good appetite, he could not digest milk in any form and it, which led to flatulence. He had a clear tongue, consumed 3-3.5 litres of water daily, had regular bowel movements, and had no micturition-associated problems. He said that he was barely perspiring and left no unpleasant odours or stains on his clothes. He felt refreshed after sleep.

Analysis of the case

Following an analysis of the symptoms, the distinctive mental, physical and specific symptoms were taken into account to represent the case's overall symptoms [Table 1].

Repertorial analysis

The Kent philosophy's guiding principles were used to frame the repertorial totality.^[13] The Kent Repertory using Radar Opus 3.0.16 software was used to repertorise the case once the symptoms were turned into rubrics.^[14] [Figure 1]. After repertorisation, it was shown that *Natrum sulphuricum* covered all the symptoms with the highest score.

Miasmatic analysis

Table 1 presents the miasmatic analysis of each of the symptoms.^[15] The patient had a background of several miasms with a psoro-sycotic pre-dominance.

Diagnostic assessment

The patient underwent fibre-optic laryngoscopy on August 01, 2021, and it was found that false vocal cords were oedematous on the left side, arytenoids were congested and oedematous, and the final impression was LPRD with left false cord oedema [Figure 2a].

Therapeutic intervention

First prescription

Nine doses (1 dose = 1 drop) of potentised homoeopathic medicine, i.e., *Natrum sulphuricum* 6 C were given in 30 ml of distilled water. The medicine prescribed was manufactured by a good manufacturing practice certified pharmaceutical company. The patient was advised to take 10 drops from 30 ml of distilled water once early in the morning, on an empty stomach, and again in the evening 30 minutes before any kind of food or beverages for consecutive 15 days. The medicines were prescribed for a limited duration as per the need and was followed by placebo pills for rest of the period. The patient was advised to maintain

Table 1: General and miasmatic analysis of the symptoms

Symptom category	General analysis	Psora	Sycosis	Syphilis	Tubercular
Mental general	Irritated and angry on minor issues	1	1		
Physical general	Hot patient			1	
	Cannot digest milk in any form			No classification	
Particular.	Pain in throat while eating during deglutition	1			
	Constant tendency to hem and hawk to get the throat cleared			No classification	
	Sensation of obstruction in the throat while swallowing	1			
	Dyspnoea during walking or physical exertion	1			
	Constant rattling cough with shortness of breath during coughing episodes			No classification	
	Heartburn especially after meals	1			
Pathological finding	False cord oedema		1		
Medical history	History of – cerebrovascular accident (ischemic stroke)		Predominance of Psoric miasm		
	Hypertension		1		
	Dyslipidaemia		1		
Family history	Family history of hypertension		1		

	nat-s	merc	lyc	lach	carb-v	nat-m	bar-c	nux-v	alum	phos	sep	bell
1. STOMACH - VOMITING - vexation, after (7) 1	1		1									
2. STOMACH - HEARTBURN (118) 1	2	2	3	2	3	2	1	3	2	2	2	1
3. ABDOMEN - FLATULENCE - milk, after (5) 1	2	1			1							
4. GENERALS - WARM - agg. (82) 1	2	2	2	2	1	2	1		3	2		1
5. RESPIRATION - DIFFICULT - cough, with (80) 1	2	1	2	2	2	1	1	3	3	3	2	2
6. COUGH - RATTLING (73) 1	2	1	2	2	2	2	2	1	1	3	2	2
7. THROAT INTERNAL - PAIN - swallowing, - on (138) 1	2	3	3	2	2	1	2	2	3	2	1	3
8. THROAT INTERNAL - HAWK, - disposition to (108) 1	2	1	3	3	2	3	2	3	2	3	3	2
9. THROAT INTERNAL - LUMP, plug, etc., sensation of - swallowing, on (14) 1	1	2				2	2	2			2	

Figure 1: Repertorial sheet

a healthy diet (avoiding spicy, fatty and oily food) with minimal amount of saturated fat and carbohydrates, so that the chances of recurrence (if any) can be minimised. The patient was also counselled to control his anger outbreaks as he was supposedly suffering from a psychosomatic problem.

Basis of prescription

Different Materia Medica references were consulted, and the initial prescription was chosen after taking into account the patient’s complete symptomatology, reportorial analysis, medical history, family history and active miasmatic state.^[16,17] In light of the above context, *Natrum sulphuricum* was chosen.

Follow-up and outcomes

The patient was periodically followed up for 1 year and 4 months. Table 2 provides information on changes in symptoms and signs as well as medications prescribed at each visit.

A fibre optic laryngoscopy report was used to document the treatment’s outcome both during the initial visit and 16 months later [Figures 2 and 3].

The outcome in relation to impact on daily living (ORIDL) scale was used as a validated outcome measuring tool to assess the patient’s perception of how the results have influenced his way of life.^[18] The patient recorded the ORIDL score for his

primary complaint and overall well-being at each follow-up. The ORIDL score for both aspects was +4 at the conclusion of the 16-month period [Table 2]. In the follow-ups, the patient was questioned regarding compliance with the medication regime and his ability to manage anger episodes. It was discovered that the patient followed the recommendations and had no complaints about the tolerance of the intervention. Throughout the entire time, the patient received homoeopathic care, and no unfavourable or unexpected events were reported.^[19] He also didn’t mention any initial worsening of his pre-existing problems or any other complaints that would have indicated a homoeopathic aggravation.^[19-21] In the 16-month follow-up, the Modified Naranjo Criteria for Homoeopathy (MONARCH), a causal attribution assessment instrument, was used to determine whether there was a causal link between the homoeopathic intervention and the treatment’s success.^[22] Table 3 lists the scores attained in each of the ten MONARCH domains. The score was +8 on a scale from ‘-6 to +13’.

DISCUSSION

LPRD is a clinical condition brought on by the direct and indirect effects of refluxed stomach contents on the upper aerodigestive tract.^[2]

Table 2: Follow-up and outcomes

Date	Status of the patient	Medicine prescribed	ORIDL score	
			Main complaints	Overall well-being.
1 st visit (07 September 2021)	Totality of symptoms as per the general and miasmatic analysis mentioned in Table 1. BP -160/86 mm Hg.	<i>Natrum sulph</i> 6C/9 doses (1 dose= 1 drop) in 30 ml distilled water 10 drops×twice a day×15 days Followed by placebo for 2 weeks.	0	0
1 st follow-up (23 November 2021)	Pain in throat during swallowing status quo. No change in sensation of obstruction in throat. Slight relief in shortness of breath (SOB) but cough was persisting. Heartburn and flatulence were same. Vomiting episodes due to anger issues were same. BP - 160/80 mm Hg.	<i>Natrum sulph</i> 30C/7 doses in 30 ml distilled water 10 drops×twice a day×15 days Followed by placebo for 2 weeks.	0	0
2 nd follow-up (04 January 2022)	Pain in throat during swallowing 80% gone (as patient said). Sensation of obstruction still persisting as regurgitation of food seems to occur now and then. Cough with SOB is also improved. Heartburn and flatulence are slightly improved. Vomiting episode due to anger issues is same. BP - 154/84 mm of Hg.	No medicine was prescribed as improvement continued.	+1	+1
3 rd follow-up (15 February 2022)	Pain in throat during swallowing almost gone. Rest of complains same as before. 2 times vomiting occurred due to anger issues in last 1 month. BP - 138/80 mm Hg.	No medicine was prescribed as improvement continued.	+1	+1
4 th follow-up (25 March 2022)	Pain in throat reappearing and there is no marked improvement in SOB and cough. Flatulence has increased. BP - 120/80 mm Hg.	<i>Natrum sulph</i> 200C/4 doses in 30 ml distilled water 10 drops×twice a day×15 days Followed by placebo for 2 weeks.	+1	+1
5 th follow-up (13 May 2022)	Pain in throat again subsided. SOB and cough reduced to great extent. Flatulence and heartburn also improving. BP - 120/70 mm Hg.	Placebo prescribed for 1 month	+2	+2
6 th follow-up (17.06.22)	Throat complains improving well. Heartburn also decreased to great extent. But, a new c/o trigger finger occurred on middle, index, ring finger of left hand <flexion. BP - 110/74 mm Hg.	<i>Ruta</i> 200C/4 doses in 30 ml distilled water 10 drops×twice a day×15 days Followed by placebo for 2 weeks.	+2	+2
7 th follow-up (12 August 2022)	Pain in throat almost gone. Improvement in SOB and Cough is same as before. Flatulence occurring but in less intensity. Heartburn is much better. Movement of fingers is also improving. BP - 120/82 mm Hg.	<i>Natrum sulph</i> 1M/2 doses in 30 ml distilled water 10 drops×twice a day×15 days Followed by placebo for 2 weeks	+2	+2
8 th follow-up (30 September 22)	Pain in the throat is totally gone. Cough and SOB are showing marked improvement. Episodes of vomiting did not occur. Heartburn and flatulence are much better. BP - 122/80 mm Hg.	No medicine was prescribed as improvement continued.	+3	+3
9 th follow-up (01 December 2022)	Patient is improving well. Laryngoscopy was advised. BP - 116/78 mm Hg.	No medicine was prescribed as improvement continued.	+3	+3
10 th follow-up (19 January 2023)	Patient with the laryngoscopy report, done from the same centre and same ENT specialist certified the improvement. BP - 118/80 mm Hg.	Nil	+4	+4

1 dose: 1 drop

The patient, in this case, reported having LPRD with vocal cord oedema. He had received homoeopathic care for about a year and 4 months. The patient was receiving combined treatment for his complaints of hypertension and dyslipidaemia. On his initial appointment, he was instructed to continue his homoeopathic treatment for the course of the treatment along

with his anti-hypertensive and dyslipidaemia medications at the same doses. After a follow-up of 6 months, his blood pressure returned to normal. As an adjunct therapy to modern medicine, homoeopathic medicine demonstrated its positive effects. In the present case, apart from potentised *Natrum sulphuricum*, another medicine, *Ruta* 200C, was given for the acute trigger

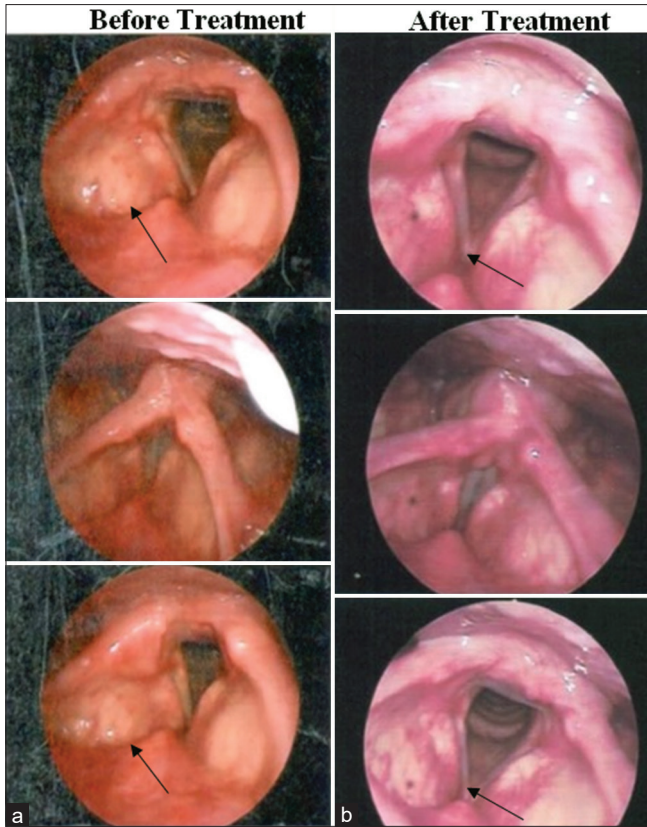


Figure 2: Fibre optic laryngoscopy images showing – (a) Before treatment (01 August 2021) and (b) after treatment (02 January 2023)

Before treatment	After treatment
Base of Tongue, vallecula: NAD	Base of Tongue, vallecula: NAD
Epiglottis: NAD	Epiglottis: NAD
False vocal cords: Oedematous on left side	False vocal cords: NAD
True vocal cords: NAD	True vocal cords: NAD
Pyriform sinuses: NAD	Pyriform sinuses: NAD
Arytenoids: Congested and Oedematous	Arytenoids: NAD
Post-cricoid region: NAD	Post-cricoid region: NAD
Impression: LPRD with left false vocal cord odema	Impression: NAD

finger. However, the symptoms of LPRD started decreasing after the prescription of *Natrum sulphuricum*. It may be further clarified that the patient did not have any medicine other than homoeopathy during the six months of follow-up.

Both subjective and objective changes were included in this case report as proof of the patient’s improvement. The patient was questioned about the overall impact of the treatment on his primary complaint and his general sense of well-being at every follow-up appointment.

Here, we did not monitor the oropharyngeal pH values, which may be a limitation of this case. To the best of our knowledge, this is the first example that has been documented and shows how homoeopathic treatment effectively manages LPRD with vocal cord oedema. Additionally, this exhibits crucial clinical judgement about the repetition of dosage and potency

Table 3: MONARCH inventory (Assessment after 16 months of treatment)

S.No.	Domains	Yes	No	Not sure/NA
1	Was there an improvement in the main symptom or condition for which the homoeopathic medicine was prescribed?	+2	-1	0
2	Did the clinical improvement occur within a plausible timeframe relative to the medicine intake?	+1	-2	0
3	Was there a homeopathic aggravation of symptoms?	+1	0	0
4	Did the effect encompass more than the main symptom or condition (i.e., were other symptoms, not related to the main presenting complaint improved or changed)?	+1	0	0
5	Did overall well-being improve (suggest using validated scale or mention about changes in physical, emotional, or behavioural elements?)	+1	0	0
6	A. Direction of cure: did some symptoms improve in the opposite order of the development of symptoms of the disease?	+1	0	0
	B. Direction of cure: Did at least one of the following aspects apply to the order of improvement of symptoms:	+1	0	0
	- from organs of more importance to those of less importance?			
	- from deeper to more superficial aspects of the individual?			
	- from the top downward?			
7	Did ‘old symptoms’ (defined as non-seasonal and non-cyclical symptoms that were previously thought to have resolved) reappear temporarily during the course of improvement?	+1	0	0

(Contd)...

Table 3: (Continued)

S.No.	Domains	Yes	No	Not sure/ NA
8	Are there alternative causes (i.e., other than the medicine) that-with a high probability-could have produced the improvement? (Consider known course of disease, other forms of treatment and other clinically relevant interventions)	-3	+1	0
9	Was the health improvement confirmed by any objective evidence? (e.g., investigations, clinical examination, etc.)	+2	0	0
10	Did repeat dosing, if conducted, create similar clinical improvement?	+1	0	0

Total score = +8 (maximum score = +13, minimum score = - 6).

modification. The outcome may help with decision-making in both practice and research, and it can also be used to develop hypotheses for upcoming clinical investigations. However, a more well-planned randomised clinical trials are required to fully understand the range and efficacy of homoeopathic therapy in this condition.

Patient perspective

The patient conveyed that he was very happy after taking the homoeopathic medicine for his complaints. He also reported that he had a sense of satisfaction because his vomiting episodes resulting from his anger issues had also resolved.

CONCLUSION

This case study demonstrates how homoeopathy can be used to treat LPRD with vocal cord oedema. *Natrum sulphuricum* was found effective as an individualised remedy, and the results were favourable. However, a case series or controlled clinical trials are required to validate the results.

Declaration of patient consent

The authors obtained written informed consent from the concerned patient to publish his case records and reports without revealing his identity.

Financial support and sponsorship

Nil.

Conflict of interest

None declared.

REFERENCES

- Alam KH, Vlastarakos PV. Diagnosis and management of laryngopharyngeal reflux. *Indian J Otolaryngol Head Neck Surg* 2014;66:227-31.
- Salihefendic N, Zildzic M, Cabric E. Laryngopharyngeal reflux disease-LPRD. *Med Arch* 2017;71:215-18.
- KhanAM, Hashmi SR, Elahi F, Tariq M, Ingrams DR. Laryngopharyngeal reflux: A literature review. *Surgeon* 2006;4:221-25.
- Westcott CJ, Hopkins MB, Bach K, Postma GN, Belafsky PC, Koufman JA. Fundoplication for laryngopharyngeal reflux disease. *J Am Coll Surg* 2004;199:23-30.
- Takeda H, Oridate N, Shimizu Y, Kato M, Asaka M, Fukuda S, *et al.* Laryngopharyngeal reflux. *Nippon Rinsho* 2007;65:921-5.
- Sung CK. Laryngopharyngeal Reflux (LPR) Protocol. Available from: https://med.stanford.edu/content/dam/sm/ohns/documents/voicecenter/resources/stanford_ent_clinic-lpr_protocol.pdf [Last accessed on 2024 Jul 01].
- Lechien JR, Akst LM, Hamdan AL, Schindler A, Karkos PD, Barillari MR, *et al.* Evaluation and management of laryngopharyngeal reflux disease: State of the art review. *Otolaryngol Head Neck Surg* 2019;160:762-82.
- Pareek A. Homeopathic management of Reinke's edema in a non-smoker: A case report. *Indian J Res Homoeopath* 2022;16:308-12.
- Nanda SK, Galagali JR, Guruprasad V. Thuja-in management of laryngeal papillomatosis. *Med J Armed Forces India* 2000;56:87.
- Gupta N. Homeopathic perspective in treating a case of barrett's oesophagus. *Homoeopath Herit* 2015;41:19.
- Agarwal R. Usefulness of robinia pseudoacacia in the treatment of gastroesophageal reflux disease. *Homoeopath Links* 2019;32:152-58.
- Van Haslen RA. Homeopathic clinical case reports: Development of a supplement (Hom-case) to the care clinical case reporting guideline. *Complement Ther Med* 2016;25:78-85.
- Kent JT. Lectures on Homoeopathic Philosophy. 7th ed. New Delhi, India: B Jain Publishers P Ltd.; 2007.
- Radar Opus version 3.0.16. Archibel Homoeopathic Software. Belgium; 2019.
- Patel RP. Chronic Miasms in Homoeopathy and their Cure with Classification of their Rubrics: Symptoms in Dr. Kent's Repertory. Kerala: Hahnemann Homoeopathic Pharmacy; 1996.
- Boericke W. New Manual of Homoeopathic Materia Medica with Repertory. 3rd ed. New Delhi: B Jain Publishers Pvt Ltd.; 2016.
- Kent JT. Lectures on Homoeopathic Materia Medica. New Delhi: B Jain Publishers Pvt Ltd.; 2005.
- Reilly D, Mercer SW, Bikker AP, Harrison T. Outcome related to impact on daily living: Preliminary validation of the ORIDL instrument. *BMC Health Serv Res* 2007;7:139.
- Stub T, Musial F, Kristoffersen AA, Alræk T, Liu J. Adverse effects of homeopathy, what do we know? A systematic review and meta-analysis of randomized controlled trials. *Complement Ther Med* 2016;26:146-63.
- Stub T, Salamonsen A, Alraek T. Is it possible to distinguish homeopathic aggravation from adverse effects? A qualitative study. *Forsch Komplementmed* 2012;19:13-9.
- Stub T, Kristoffersen AE, Alræk T, Musial F, Steinsbekk A. Risk in homeopathy: Classification of adverse effects and homeopathic aggravations--a cross sectional study among norwegian homeopath patients. *Complement Ther Med* 2015;23:535-43.
- Lamba CD, Gupta VK, Van Haselen R, Rutten L, Mahajan N, Molla AM, *et al.* Evaluation of the modified naranjo criteria for assessing causal attribution of clinical outcome to homeopathic intervention as presented in case reports. *Homeopathy* 2020;109:191-7.

Reflux laryngopharyngé avec œdème des cordes vocales traité par la médecine homéopathique individualisée : un rapport de cas

Introduction: Le diagnostic du reflux laryngopharyngé (LPRD) est encore ambigu en raison de normes diagnostiques limitées et lourdes. Pour obtenir une régression des symptômes et des résultats laryngés dus au LPRD, il faut généralement un traitement plus vigoureux et plus soutenu. Chez certains patients souffrant de reflux acide ou non acide chronique, une intervention chirurgicale peut être utile. **Résumé de cas:** Il s'agit du cas d'un homme de 68 ans qui a reçu un diagnostic de LPRD et qui avait un œdème des cordes vocales. Un médicament homéopathique individualisé, *Natrum sulphuricum*, a été prescrit, et le patient s'est amélioré régulièrement en termes de signes et de symptômes et n'a plus eu de plaintes au bout de 16 mois. L'amélioration du patient a été évaluée à l'aide du critère de jugement lié à l'échelle d'impact sur la vie quotidienne (ORIDL). L'amélioration clinique a été corrélée avec les preuves objectives du rapport de laryngoscopie. Le score des critères de Naranjo modifiés pour l'homéopathie (+8 sur l'échelle de « -6 à +13 ») détermine si les progrès du patient peuvent être attribués au traitement homéopathique. Ce rapport de cas implique que l'homéopathie peut être un choix approprié pour traiter la LPRD avec des cas d'œdème des cordes vocales. Il s'agit du rare cas documenté d'un rapport de cas LPRD associé à un œdème des cordes vocales suivi d'un traitement homéopathique thérapeutique réussi. Pour plus de conclusion concernant la maladie, d'autres études sont nécessaires.

Laryngopharyngeale Refluxkrankheit mit Stimmbandödem, die mit individualisierter homöopathischer Medizin behandelt wird: Ein Fallbericht

Einleitung: Die Diagnose der laryngopharyngealen Refluxkrankheit (LPRD) ist aufgrund begrenzter und umständlicher diagnostischer Standards immer noch unklar. Um eine Rückbildung sowohl der Symptome als auch der Kehlkopfbefunde aufgrund von LPRD zu erreichen, ist in der Regel eine energischere und nachhaltigere Behandlung erforderlich. Bei bestimmten Patienten mit chronischem saurem oder nicht-saurem Reflux kann eine Operation hilfreich sein. **Fallzusammenfassung:** Dies ist der Fall eines 68-jährigen Mannes, bei dem LPRD diagnostiziert wurde und der ein Stimmbandödem hatte. Es wurde ein individualisiertes homöopathisches Arzneimittel, *Natrum sulphuricum*, verschrieben, und der Patient verbesserte sich stetig in seinen Anzeichen und Symptomen und hatte nach 16 Monaten keine weiteren Beschwerden. Die Verbesserung des Patienten wurde anhand des Ergebnisses in Bezug auf die Auswirkungen auf das tägliche Leben (ORIDL) bewertet. Die klinische Verbesserung wurde mit objektiven Beweisen aus dem Laryngoskopiebericht korreliert. Der Modified Naranjo Criteria for Homoeopathy Score (+8 auf der Skala “-6 bis +13”) bestimmt, ob der Fortschritt des Patienten auf die homöopathische Behandlung zurückgeführt werden kann. Dieser Fallbericht impliziert, dass die Homöopathie eine geeignete Wahl für die Behandlung von LPRD bei Stimmbandödem sein kann. Dies ist der seltene Fall eines dokumentierten LPRD-Fallberichts im Zusammenhang mit einem Stimmbandödem, gefolgt von einer erfolgreichen therapeutischen homöopathischen Behandlung. Für weitere Schlussfolgerungen bezüglich der Krankheit sind weitere Studien gerechtfertigt.

वोकल कॉर्ड इडिमा के साथ लैरींगोफेरींजल रिफ्लेक्स रोग का इलाज व्यक्तिगत होम्योपैथी दवा के साथ: एक केस रिपोर्ट

परिचय: सीमित और बोज़िल नैदानिक मानकों के कारण लैरींगोफेरींजल रिफ्लेक्स रोग (LPRD) का निदान अभी भी अस्पष्ट है। LPRD प्रतिगमन के लिए आमतौर पर अधिक जोरदार और निरंतर उपचार की आवश्यकता होती है। दीर्घकालिक एसिड या गैर-एसिड भाटा वाले कुछ रोगियों में सर्जरी सहायक हो सकती है। **केस सारांश:** यह एक 68 वर्षीय व्यक्ति का मामला है जिसे LPRD का पता चला था और वोकल कॉर्ड इडिमा था। इसे व्यक्तिगत होम्योपैथी दवा, *नैटम सल्फ्यूरिकम* विहित की गई, और रोगी में संकेतों और लक्षणों के मामले में लगातार सुधार हुआ और 16 महीने के अंत में उसे कोई और शिकायत नहीं हुई। दैनिक जीवन स्तर (ORIDL) का उपयोग करके रोगी के सुधार का मूल्यांकन किया गया था। नैदानिक सुधार लैरींगोस्कोपी रिपोर्ट में बदलाव के साथ सहसंबद्ध था। होम्योपैथी स्कोर के लिए संशोधित नारंजो मानदंड (-6 से +13) पैमाने पर +8) यह निर्धारित करता है कि रोगी की प्रगति को होम्योपैथी उपचार के लिए जिम्मेदार ठहराया जा सकता है। इस मामले की रिपोर्ट का तात्पर्य है कि वोकल कॉर्ड इडिमा सम्बन्धी LPRD के इलाज के लिए होम्योपैथी एक उपयुक्त विकल्प हो सकता है। बीमारी के संबंध में आगे के निष्कर्ष के लिए, अधिक अध्ययन की आवश्यकता है।

Enfermedad por reflujo laringofaríngeo con edema de las cuerdas vocales tratada con medicina homeopática individualizada: reporte de un caso

Introducción: El diagnóstico de la enfermedad por reflujo laringofaríngeo (DRLP) es aún ambiguo debido a los estándares diagnósticos limitados y engorrosos. Para lograr la regresión tanto de los síntomas como de los hallazgos laríngeos debido a la LPRD, generalmente se requiere un tratamiento más vigoroso y sostenido. En ciertos pacientes con reflujo ácido o no ácido crónico, la cirugía puede ser útil. **Resumen del caso:** Este es el caso de un hombre de 68 años que fue diagnosticado con LPRD y tenía edema en las cuerdas vocales. Se prescribió un medicamento homeopático individualizado, *Natrum sulphuricum*, y el paciente mejoró constantemente en términos de signos y síntomas y no tuvo más quejas al cabo de 16 meses. La mejoría del paciente se evaluó mediante la escala de resultados relacionados con el impacto en la vida diaria (ORIDL). La mejoría clínica se correlacionó con la evidencia objetiva del informe de la laringoscopia. La puntuación de los Criterios de Naranjo Modificados para

la Homeopatía (+8 en la escala de -6 a +13) determina si el progreso del paciente puede atribuirse al tratamiento homeopático. Este informe de caso implica que la homeopatía puede ser una opción adecuada para el tratamiento de la DRLP en casos de edema de las cuerdas vocales. Este es el raro caso de un informe de caso documentado de LPRD asociado con edema de las cuerdas vocales seguido de un tratamiento terapéutico homeopático exitoso. Para obtener más conclusiones sobre la enfermedad, se justifican más estudios.

咽喉反流病伴声带水肿接受个体化顺势疗法治疗：病例报告

简介： 由于诊断标准有限且繁琐，咽喉反流病（LPRD）的诊断仍然不明确。为了实现LPRD引起的症状和喉部表现的消退，通常需要更积极和持续的治疗。对于某些慢性胃酸反流或非胃酸反流患者，手术可能有帮助。 **病例摘要：** 这是一名68岁男性的病例，他被诊断为LPRD并患有声带水肿。开具了个体化的顺势疗法药物 *Natrum sulphuricum*，患者的体征和症状稳步改善，并且在 16 个月结束时没有进一步的抱怨。使用与对日常生活量表的影响（ORIDL）相关的结果评估患者的改善。临床改善与喉镜检查报告的客观证据相关。改良的 Naranjo 顺势疗法标准评分（“-6 至 +13”量表上的 +8）确定患者的进展是否可以归因于顺势疗法治疗。该病例报告表明顺势疗法可能是治疗声带水肿病例的 LPRD 的合适选择。这是与声带水肿相关的记录在案的 LPRD 病例报告的罕见实例，随后是成功的治疗性顺势疗法治疗。为了进一步得出关于该疾病的结论，需要更多的研究。