



10/

P. C. Chaudhri
Masangang
B. L. S. P. Co.

474



OPHTHALMIC DISEASES AND THERAPEUTICS.

BY

A. B. NORTON, M.D.

*Professor of Ophthalmology in the College of the New York Ophthalmic Hospital; Surgeon
the New York Ophthalmic Hospital; Visiting Oculist to the Laura Franklin Free
Hospital for Children; Consulting Oculist to the Protestant Half Orphan
Asylum; Associate Editor, Department of Ophthalmology,
North American Journal of Homoeopathy.*

WITH FIFTY-THREE ILLUSTRATIONS AND TWELVE
CHROMO-LITHOGRAPHIC FIGURES.

PHILADELPHIA:
BOERICKE & TAFEL.

1892.

Copyrighted, 1892.
By A. B. NORTON, M.D.



Yours
Geo. S. Norton

DEDICATION.

TO THE MEMORY OF MY BROTHER.

Geo. S. Norton, M.D.,

Author of the Ophthalmic Therapeutics,

THIS BOOK IS AFFECTIONATELY DEDICATED AS A TRIBUTE TO HIS
LIFE-WORK IN OPHTHALMOLOGY.

P R E F A C E.

THE appearance of this work has been due to two causes, namely: The desire to continue the publication of the OPTHALMIC THERAPEUTICS, which was first brought out by Drs. T. F. Allen and George S. Norton, and subsequently a second edition by Dr. Norton alone. Both editions having received the hearty support and commendation of the profession, and the last being now nearly exhausted, it has seemed best that it should be continued. In its present form we hope that it will prove of even greater value than before.

This work has also been completed in order to continue and carry out the plans of my brother, the late Dr. George S. Norton. For several years prior to his death it had been his desire to present to the profession a text-book upon ophthalmology, devoting especial attention to the homœopathic treatment of the diseases of the eye. His extended experience and labor in the field of ophthalmology made him particularly well qualified to bring forth a valuable work in this line. Finding, however, that the extensive demands upon his time from both college and hospital work, in addition to a large private practice, such a work would become too severe a tax upon his strength, he arranged with the writer to bring out such a book together. The plan and scope of the work was then thoroughly considered and mapped out. The work was commenced and some of it completed when Dr. Norton's illness and death put a stop to further progress. After some months of careful consideration and grave doubts as to the ability of the writer to complete the task creditably, it was finally decided to finish the undertaking.

The scope of the work as originally planned has been followed out closely and was to give as *concisely as possible* all the essential features necessary to a thorough knowledge of the diseases of the eye, commencing with sufficient anatomy of the various structures to aid in an understanding of their diseases.

In treating of the different diseases it has been our aim to follow a definite and systematic order, taking up successively the pathology, symptoms, course, causes, diagnosis, prognosis and treatment of each separate disease.

As the object of the work has been to furnish the student and the general practitioner with a *concise*, practical manual, all useless verbiage has been discarded and the effort made to present a practical condensation of all important facts, believing such a book to be of more value to the student than one which hides the kernel under a profuse, even though interesting, envelopment.

Special attention has been devoted to the homœopathic treatment of diseases; at the same time, knowing the importance of both local and operative measures, it has been our aim to omit nothing that may be of value in these methods. The homœopathic treatment has, of course, been practically that of the last edition of the *OPHTHALMIC THERAPEUTICS*, to which several new remedies and many new symptoms of old ones have been added; on the other hand, some of the old remedies have been cut down by dropping out the reports of some of the clinical cases and occasionally some general symptom of the drug. In the revision of this department of the work all homœopathic publications of the last ten years, together with copious case records of my brother's as well as my own, have been carefully sifted and scrutinized. As this work practically includes all of the old *OPHTHALMIC THERAPEUTICS*, it seems appropriate to quote from the prefaces of that work.

In the first edition the authors say:

“Material for this work has been accumulating for many years, especially since the adoption of the homœopathic method by the New York Ophthalmic Hospital.

“When we first took our chairs in that institution there were few indications for remedies associated with definite lesions of the eye; our cases were diagnosticated and then carefully examined at all points for indications of the remedy, and from time to time groups of remedies have become associated with definite lesions and characteristic local indications recognized.

“These local indications seem at times to be purely clinical or empirical, but they have always, or nearly always, been discovered while co-existing with positive and pure symptoms of the remedy,

but they so often occur independently of the latter that they frequently assume a relatively greater importance.

“Our knowledge of the pure effects of drugs upon the eye is unfortunately meagre, often quite indefinite and unsatisfactory; still, we have endeavored to keep to the standard and have only permitted the introduction of clinical matter when the evidence has seemed to justify.

“It is proper to explain that the plan of this work is substantially the same as that projected by Dr. Allen a few years since and prematurely announced; the material then in hand has been augmented by the observations of Dr. Norton, the whole work written out by him and revised by us jointly.

“Incomplete as we know it to be, we feel that its publication should not be longer delayed and we offer it to the profession for most critical examination. *All the symptomatology given in this work has been verified*; when no authority is referred to, the editors are responsible, except when general reference is made to cases reported. Some observations may be ill-founded; many, we feel sure, will prove reliable and contribute to the preservation and restoration of sight.”

In the preface to the second edition, Dr. Norton says:

“The many additions to ophthalmic therapeutics within the past six years, have rendered necessary a complete revision of this little manual.

“Part First (*Part Second of the present work*) has been wholly rewritten and several new remedies added. The verified symptomatology, which precedes the clinical application of each drug, has been taken from ‘Allen’s Encyclopædia of Pure Materia Medica,’ with such other confirmations as have been made by the author. The clinical indications have, however, received chief attention, as a further experience of six years in a large ophthalmic clinic has naturally developed new remedies and new indications for old remedies. Much valuable aid has also been received from leading oculists throughout the country who have kindly sent cases and clinical indications from their own practice, to which their names will be found appended as authority. More space has been given, as will be noticed, to illustrative cases, with a view of showing the actual symptoms of the disease, for which the

remedy should be prescribed, and the results of treatment. In order to make this section as practical and reliable as possible, considerable matter found in the first edition has been eliminated. For instance, all material gathered from doubtful sources, from practitioners not personally known to the writer, or, in whom he has not the most implicit confidence as to their ability to correctly diagnose and truthfully report their cases, also all statements which further experience has failed to verify, are omitted in this edition. Statements and clinical cases in the first edition which were only verified by Dr. Allen are so indicated in the text. In every instance when no authority is given, the author may be considered responsible."

With the issuance of the second edition, Dr. Allen withdrew from the work, and, in an introduction to that edition, says:

"Some years have elapsed since the issue of 'Allen and Norton's Ophthalmic Therapeutics,' the edition has been sold and a new one demanded. Our colleague, Dr. Norton, has continued to work in the field with unwearied perseverance and with striking success; the writer has been called to labor more particularly in the broader field of general Materia Medica and deems it proper that his name should not continue to be associated with Dr. Norton's in this work, simply because to Dr. Norton is wholly due the honor of having revised and enlarged this work.

"While there is no doubt that the conditions of the eye, in diseases of that organ, is a most important factor in the selection of the remedy, still we must not forget that eye diseases are often, perhaps generally, the expression of a general cachexia, the remedy for which can only be found by a close examination of the whole individual. A knowledge of remedies for any disease of the eye has been attained *in the beginning* only by a study of the whole case, and, if it has been found that for certain pathological states but few drugs are appropriate, it must still be kept in view that new remedies are to be found and that any case may require a drug hitherto unused for its cure. Among the most brilliant pathological generalizations in ophthalmic therapeutics may be mentioned the use of *Gelsemium*, for intra-ocular inflammations, characterized by serous exudation; *Rhus tox.*, for suppurative intra-ocular and orbital inflammations; *Bryonia*, for plastic-exudation, and, we may be permitted to add,

the American Aconite (*A. uncinatum*) for ciliary and peri-orbital neuralgia. No therapist will, however, be content to limit his remedial resources, in any one of the above diseases, to the remedy mentioned. Pilocarpine may be required instead of Gelsemium; Silicea in place of Rhus; Phytolacca in place of Bryonia, or Spigelia instead of Aconite; how shall we decide? And the selection must be accurate and prompt, for in the eye, more than anywhere else, delay is dangerous: *the symptoms must always be studied.*"

In closing, the author desires to acknowledge his indebtedness to Dr. George A. Shepard for his valuable aid in searching out all notes of reference, together with the examination and compilation from all the homœopathic literature of every symptom or verification they contained for the OPTHALMIC THERAPEUTICS.

To Dr. William H. Bleecker we also extend our sincere thanks, for his inestimable services in preparing a most thorough index, together with a careful revision of the proof of the entire work.

A. B. NORTON.

152 West Thirty-fourth Street,
August 15, 1892.



CONTENTS.

CHAPTER I.

DISEASES OF THE EYELIDS.

Anatomy—Blepharitis Acuta—Blepharitis Ciliaris—Hordeolum—Ptosis—Blepharospasmus—Nictitatio—Blepharophimosis—Trichiasis and Distichiasis—Entropium—Ectropium—Symblepharon—Anechyloblepharon—Epicanthus—Moluscum Contagiosum—Xanthelasma—Miliium—Papillomata—Dermoid Cyst—Nævi—Chalazion—Epithelioma—Lupus and Sarcoma—Herpes Zoster Frontalis—Syphilitic Ulcers, Chancre and Gummata—Contusions—Wounds—Burns and Scalds, 17

CHAPTER II.

AFFECTIONS OF THE LACHRYMAL APPARATUS.

Anatomy—Dacryoadenitis—Hypertrophy of the Lachrymal Gland—Tumors of the Lachrymal Gland—Strictura Ductus Lachrymalis—Dacryocystitis Catarhalis—Dacryocystitis Phlegmonosa—Fistula Lachrymalis, 43

CHAPTER III.

DISEASES OF THE ORBIT.

Anatomy—Cellulitis Orbitæ—Tenonitis—Periostitis Orbitæ—Caries and Necrosis—Empyema of the Frontal Sinus—Tumores Orbitæ—Wounds and Injuries of the Orbit—Morbus Basedowii, 52

CHAPTER IV.

AFFECTIONS OF THE OCULAR MUSCLES.

Anatomy—Paralysis of Ocular Muscles—Paralysis, External Rectus—Paralysis, Superior Oblique—Paralysis, Internal Rectus—Paralysis, Superior Rectus—Paralysis, Inferior Rectus—Paralysis, Inferior Oblique—Complete Paralysis of the Third Nerve—Strabismus or Squint—Strabismus Convergens—Strabismus Divergens—Strabismus Sursum and Deorsum Vergens—Nystagnus—Muscular Asthenopia—Hyperphoria—Esophoria—Exophoria, 62

CHAPTER V.

DISEASES OF THE CONJUNCTIVA.

Anatomy—Hyperæmia—Conjunctivitis Catarrhalis—Conjunctivitis Purulenta—Ophthalmia Neonatorum—Conjunctivitis Gonorrhœica—Conjunctivitis Diphtheritica—Conjunctivitis Crouposa—Conjunctivitis Follicularis—Conjunctivitis Trachomatosa—Papillary Trachoma—Conjunctivitis Phlyctenularis—Conjunctivitis Vernalis—Amyloid Degeneration of the Conjunctiva—Xerosis Conjunctivæ—Pterygium—Subconjunctival Effusions—Subconjunctival Emphysema—Tuberculosis Conjunctivæ—Lesions of the Conjunctiva—Tumors of the Conjunctiva, 97

CHAPTER VI.

DISEASES OF THE CORNEA.

Anatomy—Inflammation of the Cornea—Keratitis Phlyctenularis—Keratitis Fascicularis—Keratitis Pannosa—Keratitis Vesiculosa—Ulcer Corneæ—Hypopyon Keratitis—Asthenic Ulcer—Keratitis Dendritica—Abscessus Corneæ—Keratitis Neuro-Paralytica—Keratitis Parenchymatosa—Keratitis Bullosa—Desemetitis—Opacities of the Cornea—Staphyloma Corneæ—Keratoconus—Kerato-Globus—Injuries and Wounds of the Cornea—Tumors of the Cornea, . . . 146

CHAPTER VII.

DISEASES OF THE SCLERA.

Anatomy—Episcleritis—Scleritis—Staphyloma Scleræ—Injuries of the Sclera, 185

CHAPTER VIII.

DISEASES OF THE IRIS.

Anatomy—Hyperæmia Iris—Iritis—Iritis Syphilitica—Iritis Rheumatica—Iritis Spongiosa—Iritis Parenchymatosa—Iritis Traumatica—Iritis Serosa—Tumors of the Iris—Mydriasis—Myosis—Hippus—Iridodonesis—Iridoncosis—Hyperæmia—Iridodialysis—Coloboma Iris—Aniridia—Membrana Pupillaris Persistans—Heterochromia—Operations on the Iris, . . . 190

CHAPTER IX.

DISEASES OF THE CILIARY BODY.

Anatomy—Cyclitis—Cyclitis Plastica—Cyclitis Serosa—Cyclitis Purulenta—Injuries Implicating the Ciliary Region—Paresis Musculus Ciliaris—Spasmodic Musculus Ciliaris—Irido-Choroiditis, 214

CHAPTER X.

SYMPATHETIC OPHTHALMIA.

Symptoms—Causes—Treatment, 225

CHAPTER XI.

DISEASES OF THE CHOROID.

Anatomy—Hyperæmia—Choroiditis—Choroiditis Serosa—Choroiditis Disseminata Simplex—Choroiditis Areolaris—Choroiditis Circumscripta—Choroiditis Syphilitica—Choroiditis Metastatica—Choroiditis Suppurativa—Sclerotico-Choroiditis, Anterior—Sclerotico-Choroiditis, Posterior—Senile Changes of the Choroid—Albinism—Tumors of the Choroid—Ossification of the Choroid—Hæmorrhages in the Choroid—Detachment of the Choroid—Rupture of the Choroid—Coloboma of the Choroid, 231

CHAPTER XII.

DISEASES OF THE RETINA.

Anatomy—Hyperæmia Retinæ—Retinitis Simplex—Retinitis Nyctalopica—Retinitis Albuminurica—Retinitis Diabetica—Retinitis Leucocythæmica—Retinitis Hæmorrhagica—Retinitis Syphilitica—Retinitis Punctata Albescens—Retinitis Proliferans—Retinitis Pigmentosa—Detachment of the Retina—Ischæmia Retinæ—Embolia Arteria Centralis Retinæ—Hyperæsthesia Retinæ—Commo-tio Retinæ—Glioma Retinæ, 256

CHAPTER XIII.

DISEASES OF THE OPTIC NERVE.

Anatomy—Opaque Nerve Fibres—Coloboma of the Sheath—Hyperæmia of the Disc—Hæmorrhage of the Optic Nerve—Neuritis Optica—Neuritis Retro-bulbaris—Atrophia Nervus Opticus—Injury of the Optic Nerve—Tumors of the Optic Nerve, 288

CHAPTER XIV.

AMBLYOPIA AND AMAUROSIS.

Congenital Amblyopia—Traumatic Amblyopia—Amblyopia from Lightning—Amblyopia from Loss of Blood—Toxic Amblyopia—Hysterical Amblyopia—Pretended Amblyopia—Hemeralopia—Snow Blindness—Color blindness—Hemianopsia, 308

CHAPTER XV.

DISEASES OF THE VITREOUS BODY.

Anatomy—Hyalitis Suppurativa—Opacitates Vitrei—Hæmorrhage into the Vitreous—Foreign Bodies in the Vitreous—Cysticercus in the Vitreous—Persistent Hyaloid Artery—Detachment of the Vitreous, 317

CHAPTER XVI.

DISEASES OF THE CRYSTALLINE LENS.

Anatomy—Cataract—Varieties of Cataract—Complete Congenital Cataract—Cataracta Lamellaris—Cataracta Zonalaris—Cataracta Polaris Anterior—Cataracta Pyramidalis—Cataracta Polaris Posticum—Cataracta Traumatica—Cataracta Secundaria—Cataracta Capsularis—Operative Treatment of Cataract—Aphakia—Luxatio Lentis, 324

CHAPTER XVII.

GLAUCOMA.

Anatomy—Physiology of Secretion and Excretion—Pathology—Symptoms—Course—Causes—Diagnosis—Prognosis—Treatment—Varieties of Glaucoma—Glaucoma Acuta—Glaucoma Chronica—Glaucoma Simplex—Glaucoma Hæmorrhagica—Glaucoma Absolutum—Glaucoma Consecutiva, 355

PART SECOND.

Acetic Acid to Zincum, 377-538

PART I.

OPHTHALMIC DISEASES.

OPHTHALMIC DISEASES.

CHAPTER I.

Diseases of the Eyelids.

Anatomy.—The eyelids form the external covering of the eye-balls, and serve to protect the eye from injury, both from excessive light and from foreign substances; they also serve at the same time to distribute to the eyes the moisture secreted by the various glands.

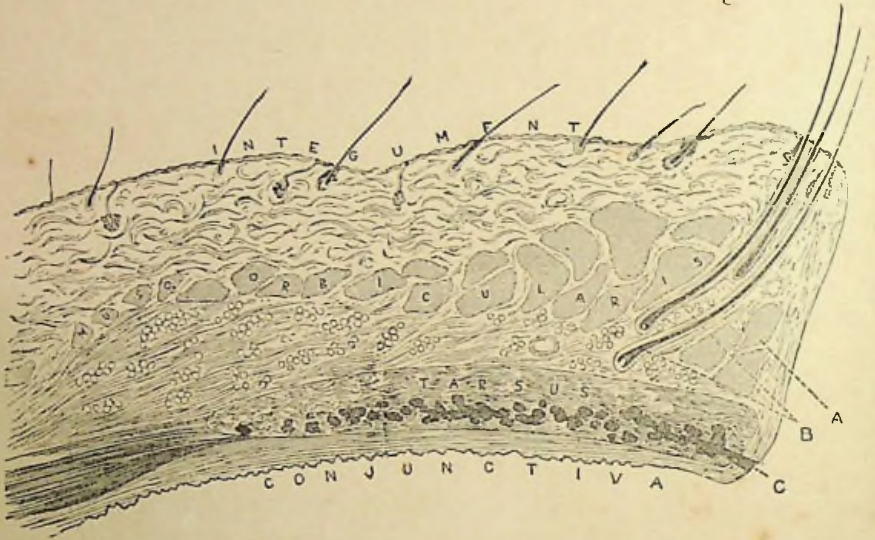
The eyelids, or palpebræ, are two thin movable folds, the upper being the larger and more movable of the two; their movement is both voluntary and involuntary, the latter action being due to the orbicularis muscle. The opening of the lids is chiefly by the action of the levator palpebræ superioris lifting the upper lid; when opened an elliptical space is left between the margins of the lids; this opening varies greatly, being larger in prominent eyes than in sunken ones, and greater when looking upward. The angles of junction of the upper and lower lids are called *canthi*; the *outer canthus* is more acute than the inner; near the extremity of the *inner canthus* is found on both the upper and lower lid a slight elevation, the apex of which is pierced by a small orifice, the *punctura lachrymale*, the commencement of the small channels or *canaliculi* leading to the tear sac.

The eyelids are composed of four layers, arranged from without inward in the following order, the integument, a layer of muscular fibres, the tarsus, or as often erroneously called the tarsal cartilage, and the conjunctiva. The *integument*, which is extremely thin but similar in every other respect to the integument elsewhere, becomes, at the margins of the lids, continuous with the conjunctiva.

The muscular fibres consist of the *orbicularis palpebrarum*, a large, flat, voluntary muscle extending over the orbital margins above and below and terminating by tendinous attachments at the angles of the

lids, the tendons, together with some fibres of the muscle, being inserted in the adjacent bony wall. The fibres of the orbicularis which lie upon the tarsi are paler than the others, and certain bundles of these which give to the lid its involuntary action are known as the ciliary muscle of Riolani. The orbicularis is somewhat adherent to the skin, but glides loosely over the tarsus. Its fibres are more or less circular in arrangement, and, acting as a sphincter, serves to close the eyes.

FIG. 1.



Section through Upper Eyelid. *A*, the ciliary muscles of Riolanus; *B*, follicles of the eye-lashes; *C*, opening of the Meibomian follicles.

The *levator palpebræ superioris* arises at the apex of the orbit and passing along its upper wall becomes intermingled in front of the tarsus with the orbicularis; other fibres become attached to the upper edge of the tarsus, and still others go to the conjunctiva. This muscle is supplied by a branch from the third nerve, and its action is, as its name implies, to raise the upper lid. The lower lid is supplied with a prolongation from the inferior rectus, whose insertion and action is analogous to that of the *levator palpebræ*.

The *tarsi* are two thin, elongated plates composed of condensed fibrous tissue, and serve to form the framework of the lids; they are united to each other and to the adjacent bone through the medium of the internal and external lateral ligaments.

The *conjunctiva* is a delicate mucous membrane which commences

at the free border of the lid, where it is continuous with the skin; it lines the inner surface of the lids and is then reflected upon the globe, over which it passes and becomes continuous with the cornea. The palpebral portion is thicker and more vascular than that covering the globe, and is firmly attached to the tarsus. Where it passes from the lids to the globe it is thin and loose, and forms what are called the *fornix conjunctivæ*.

The *cilia* are short, thick, curved hairs, arranged in double or triple rows at the margins of the lids; their follicles are surrounded by sebaceous glands and the glands of Moll. Within the tarsus are embedded the Meibomian glands, which in structure resemble the sebaceous glands. These various glands by their secretions serve to lubricate the eye, and discharge their secretion through excretory ducts, opening by minute orifices upon the free border of the lids between the rows of cilia.

Blepharitis Acuta (*Acute Phlegmonous Inflammation* [Abscess] of the Lids).—Suppuration of the connective tissue of the lid is generally the result of trauma, and is then due to a breaking down of the blood-clot formed at the time of the contusion. It may also follow debilitating diseases, or be associated with adenitis in scrofulous children. There will be great swelling of the lid, with more or less heat, redness and pain. Fluctuation may be detected early, and inflammation of the conjunctiva is apt to be associated with this disease. General inflammation of the lid may sometimes be seen in children without suppuration; while in cachectic subjects we may have a gangrenous condition.

TREATMENT.—By a careful selection of our remedy in the first stage, we can often cause the inflammation to subside before suppuration has taken place. It is also possible to promote the resolution and discharge of pus already formed. Cold (iced) applications are recommended if the disease is seen at the outset; but if we suspect that the formation of pus has commenced, a change to hot applications (poultices) should be made.

As soon as fluctuation can be felt, a free incision into the swelling parallel to the margin of the lids should be made, in order to give free vent to the confined pus. After the escape of the pus, warm applications of Calendula and water (ten drops to the ounce) are advised. A compress bandage should also be employed if the abscess

is extensive, so as to keep the lid in position and the walls of the abscess in contact, and thus hasten the union.

If it has already spontaneously opened, the perforation should be enlarged, if it be insufficient and unfavorably situated; also if there be several apertures, they should be united by an incision, in order to leave as small a cicatrix as possible. A generous diet should be prescribed. For remedies, see *blepharitis ciliaris*.

Blepharitis Ciliaris (*Tinea Tarsi, Ophthalmia Tarsi, Blepharitis Marginalis, Blepharo-Adenitis, etc.*).—Inflammation of the edges of the eyelids is met with in various degrees, from the most simple form, where there is merely a slight hyperæmia of the border of the lids, to the most severe, in which we find large ulcerations or a smooth, thickened, everted condition of the lids.

SYMPTOMS.—At the commencement there is a slight burning and smarting in the eyelids, which is aggravated by cold winds, smoke, dust, exposure to bright light, or use of the eyes at close work. There is agglutination of the eyelids in the morning, with dry scales or scabs adhering to the margins of the lids; photophobia and lachrymation are present. In the advanced cases the hair follicles may be destroyed and the cilia fall out, or they may be of a stunted or irregular growth; the thickening and eversion of the lids may cause ectropium.

COURSE.—The course of the disease is usually very chronic, and yet should be cured by thorough and prolonged treatment.

CAUSES.—The disease occurs most frequently in young, delicate persons of a strumous diathesis, and, as the causes are so closely associated with the treatment, they will be considered further under that heading.

TREATMENT.—First, we should examine the refraction, and, if any error is found, correct the same with the proper glass, as in some cases this alone will cure the entire trouble.

In rare cases the presence of lice on the eyelashes may be the exciting cause (*phtheiriasis ciliarum*), when we should be careful to remove them and apply either cosmoline or some mercurial ointment, which will destroy them and prevent their recurrence.

Fungous growths in the hair follicles are also said to cause this disease, in which case the hairs should be extirpated, and either external or internal medication employed.

Another cause is frequently found in affections of the lachrymal canal, particularly catarrh of the lachrymal sac and stricture of the duct; in these cases the tears, being hindered from flowing through their natural passage into the nose, collect in the eye, flow over the lids and down the cheek; thus the retention of the tears will cause an inflammation of the margins and eventually of the whole structure of the lids. Any other affection which will have the same result (flowing of the tears over the lids) will, of course, produce the same trouble, and this is often found in slight degrees of eversion of the lower lids (ectropium), which displaces the puncta lachrymalis and thus prevents the tears from passing into the sac. In all such cases the first thing to be done is to open the canaliculus into the sac, and, if necessary, the nasal duct into the nose, so as to give a free passage for the tears into that organ, after which the treatment is the same as in uncomplicated cases.

But the most common causes of ciliary blepharitis are exposure to wind, dust, smoke, etc., especially when complicated with *want of cleanliness*; it is for this reason we see this trouble so frequently among the poorer classes. As it is upon this point—cleanliness—that the success of our treatment depends to a great extent, we should impress upon the patient's mind the necessity of it in terms as forcible as possible.

They should be directed to remove the scales or crusts from the margins of the lids *as soon as formed*, not allowing them to remain even a few minutes. This should not be done by rubbing, as the patient is inclined to do on account of the itching sensation, for by so doing, excoriations are made, lymph is thrown out and new scabs form, which only aggravate the inflammation. But they should be directed to moisten the crusts in warm water and then carefully remove them with a piece of fine linen, or by drawing the cilia between the thumb and fingers; at the same time gentle traction may be made on the lashes, so as to remove all that are loose, as they act only as foreign bodies. Sometimes the scabs are so thick and firm that moistening in warm water is not sufficient to remove them; in such cases, hot compresses or poultices should be applied for ten or twenty minutes at a time, until they can be easily taken away.

In the treatment of *chronic* inflammation of the margins of the lids, *external applications* are of great value and without their use a cure

is often impossible. It is true that a careful attention to cleanliness, together with the internal administration of the indicated remedy, will cure a large proportion of our cases, but the duration of treatment will be usually much longer than if we employ local means at the same time we give internal remedies.

Cosmoline or Vaseline.—This unguent has been of great service in the treatment of ciliary blepharitis. It may be used alone or to form a base for the administration of other remedies. It prevents the formation of new scales and the agglutination of the lids, besides seeming to exert a beneficial influence over the progress of the disease. This, like all other ointments, should be used once or twice a day, or even oftener, if the case is very severe. All scales or crusts should first be carefully removed; after which a very little of the ointment may be applied to the edge of the lids with the finger or a camel's hair brush. The smallest amount possible, to oil the ciliary margins of the lids, should be applied, as an aggravation of the inflammation may result from its too free use.

Grapho-vaseline.—Graphites, as will be seen in the symptomatology, is more commonly indicated in ciliary blepharitis than any other one remedy. Many cures have resulted from its internal administration alone, when indicated, but more brilliant results may be obtained by employing at the same time locally the following collyrium:

R. Graphites,	gr. ij.
Vaseline,	ʒij.
Misce.	

Mercury.—For years this has been a favorite local application in ciliary blepharitis. It seems to be better adapted to the severe forms of inflammation of the lids than Graphites, for there is more redness, more swelling, more secretion and more tendency toward ulceration. The two following prescriptions have been employed with the most favorable results, especially the yellow-oxide:

R. Hydrarg. oxyd. flav.,	gr. ij.
Vaseline,	ʒij.
Misce.	
R. Liq. Hydrarg. Nitr.,	gtt. ʒij.
Ol. Morrhuæ,	ʒj.
Misce.	

In some cases more of the mercury is used, in others less, according to the severity of the symptoms.

Various other ointments and washes have been used with variable success. The use of milk, cream, lard and simple cerate, to prevent the lids from sticking together, have also been of aid, with internal medication.

Aconite.—Chiefly called for in the acute variety of this trouble, especially when caused from *exposure to cold dry winds* and in the *very first stage* of blepharitis acuta. *The lids—especially the upper—are red and swollen, with a tight feeling in them, while great heat, dryness, burning and sensiliveness to air are present; the dry heat is temporarily relieved by cold water. The conjunctiva is usually implicated.*

Alumina.—Chronic inflammation of the lids (particularly if complicated with granulations), characterized by burning and *dryness* of the lids, especially in the evening; *itching, dryness, and excoriation at the canthi. Absence of lachrymation.* There is not usually much destruction of tissue nor great thickening of the lids.

Antimonium crud.—Obstinate cases in which the lids are red, swollen and moist, with pustules on the face. Especially in cross children. *Pustules on the ciliary margins.*

Apis mel.—Incipient stage of abscess, before the formation of pus, if there is *great puffiness of the lids, especially of the upper, with stinging pains.* Much reddish-blue swelling of the lids; temporary relief from cold water. There is often chemosis and the lachrymation is profuse, hot and burning (Rhus), though not acrid, as under Arsenicum. Drowsiness and absence of thirst are often present.

Argentum nit.—*Lids sore, very red and swollen.* especially when complicated with granular conjunctivitis or some other external trouble. There is usually *profuse discharge* from the eyes, causing firm agglutination in the morning. The symptoms are often *relieved in the cold air*, or by cold applications, and may be associated with headache, pain in the root of nose, etc.

Arsenicum.—Inflammation of the margins of the lids, which are *thick, red and excoriated by the burning, acrid lachrymation.* The cheek may also be excoriated. The lids are sometimes cedematously swollen and spasmodically closed, especially when the cornea is at the same time affected. The *characteristic burning pains* are important and usually present. The general condition of the patient

decides us in the selection, as the great prostration, restlessness, aggravation after midnight and thirst are commonly seen in scrofulous children. Often useful in the early stages of abscess of the lids.

Aurum.—Rarely useful in uncomplicated blepharitis, except when occurring in scrofulous or syphilitic subjects, after the abuse of Mercury. The lids may be red and ulcerated, with stinging, pricking or itching pain in them. Cilia rapidly fall out.

Calcareo carb.—Blepharitis occurring in persons inclined to grow fat, or in *unhealthy*, “*pot-bellied*” children of a scrofulous diathesis who sweat much about the head. The lids are red, swollen and *indurated*. Inflammation of the margins of the lids, causing loss of the eyelashes, with thick, purulent, excoriating discharge and burning, sticking pains. *Great itching* and burning of the margins of the lids, particularly at the canthi; throbbing pain in the lids. Most of the eye symptoms are worse in the morning, on moving the eyes, and in *damp weather*. Great reliance should be placed on the general cachexia of the patient.

Calcareo iodata.—Seems to act better than the carbonate in blepharitis found in those unhealthy children afflicted with *enlargement of the glands and especially of the tonsils*.

Causticum.—Blepharitis, with warts on the eyebrows and lids. The symptoms are ameliorated in the open air. *Feeling of sand in the eye*.

Chamomilla.—Of benefit as an intercurrent remedy, even if it does not complete the cure, in cross, peevish children who want to be carried. The local symptoms are not marked.

Cinnabaris.—Ciliary blepharitis, with *dull pain over or around the eye*. There may be dryness of the eye, or considerable discharge.

Croton tig.—When there is complicated with the blepharitis a *vesicular eruption on the lids and face*.

Euphrasia.—A valuable remedy, if the lids are red, swollen and excoriated by the profuse, acrid, muco-purulent discharge, or even if ulcerated. *The lachrymation is also profuse, acrid and burning*; often accompanied by fluent coryza. The cheek around the eye is also usually sore and red from the nature of the discharges.

Graphites.—This is one of the most important remedies we possess for the chronic form of this disease, though it may be indicated in acute attacks, especially if complicated with ulcers or pustules on

the cornea. Particularly useful if the inflammation occurs in scrofulous subjects covered with *eczematous eruptions* chiefly on the head and *behind the ears, which are moist, fissured and bleed easily*. The edges of the lids are slightly swollen, of a pale red color and covered with *dry scales or scurfs*, or the margins may be ulcerated. The inflammation may be confined to the canthi, especially the *outer, which have a great tendency to crack and bleed, upon any attempt to open the lids*. Burning and dryness of the lids are often present, also biting and *itching*, causing a constant desire to rub them. It is important in *eczema of the lids*, if the eruption is moist, with tendency to crack, while the margins are covered with scales or crusts.

Hepar sulph.—This is the remedy most frequently employed in acute phlegmonous inflammation, especially after the first stage has passed and *suppuration is about to, or has already, taken place*. The lids are inflamed, as if erysipelas had invaded them, with *throbbing, aching, stinging pains, and very sensitive to touch*; the pains are aggravated by cold and from contact, but *ameliorated by warmth*. It may also be useful in certain forms of blepharitis in which the lids are inflamed, sore and corroded, as if eaten out, or if small red swellings are found along the margins of the lids, which are painful in the evening and *upon touch*. There is *general amelioration from warmth*. Often called for when the Meibomian glands are affected. For *eczema palpebrarum*, in which the scabs are thick and honeycombed in character on and around the lids, it is very valuable.

Mercurius sol.—Very favorable results have been gained by this remedy in blepharitis, especially if dependent upon or found in a *sypilitic subject*, or if caused from working over *fires or forges*. *The lids are thick, red, swollen and ulcerated* (particularly the upper) and *sensitive to heat or cold and to touch*. *Profuse acrid lachrymation* is usually present, which makes the lids sore, red and painful, especially worse in the open air or by the constant application of cold water. *All the symptoms are worse in the evening after going to bed and from warmth in general*, also from the glare of a fire or any artificial light. The concomitant symptoms should receive special attention, as excoriation of the nose from the acrid coryza, flabby condition of the tongue, nocturnal pains, etc., etc.

Mercurius corr.—This form of Mercury differs very little in its symptomatology from the above, and that is chiefly in degree, *as the*

pains are generally more severe and spasmodic in character, lachrymation more profuse and acrid, secretions thinner and more excoriating and inflammatory swelling greater than in any other preparation. It has proved curative in inflammatory swelling of indurated lids, inflammatory swelling of cheeks and parts around the orbits, which are covered with small pustules, and especially in *scrofulous inflammation of the lids*. Nocturnal aggravation of the symptoms is usually present.

Mezereum.—Blepharitis accompanied by tinea capitis; or *eczema of the lids* and head, characterized by *thick hard scabs*, from under which pus exudes on pressure.

Natrum mur.—Ciliary blepharitis, particularly if caused by the use of caustics (nitrate of silver). The lids are thick and inflamed, smart and burn, with a feeling of sand in the eye. The lachrymation is acrid, excoriating the lids and cheeks, making them *glossy and shining*; often accompanied by eczema.

Nux vom.—Chronic inflammation of the lids, with smarting and dryness, especially *worse in the morning*. It is particularly indicated in ciliary blepharitis dependent upon gastric disturbances.

Petroleum.—Has been of benefit in ciliary blepharitis, especially if combined with the use of cosmoline externally. Great reliance should be placed on the occipital headache, rough skin, etc., generally found when this drug is indicated, though it has been used with advantage when no marked symptoms were present.

Psorinum.—Old chronic cases of inflammation of the lids, especially when subject to occasional exacerbations. It has also been of service in the acute variety when the internal surface of the lids was chiefly affected, with considerable photophobia. Particularly indicated in a *strumous diathesis*, with unhealthy, offensive discharges from the eyes.

Pulsatilla.—Blepharitis, both acute and chronic, especially if the glands of the lids are affected (blepharo-adenitis) or when there is a great tendency to the formation of *styes* or abscesses on the margin of the palpebræ. Blepharitis resulting from high living or fat food and when accompanied by acne of the face; also in cases in which the lachrymal passages are involved. The swelling, redness and discharges vary, though the latter are more often *profuse and bland*, causing agglutination of the lids in the morning. *Itching and burn-*

ing are the chief sensations experienced. The symptoms are usually *aggravated in the evening*, in a warm room or in a cold draught of air, but *ameliorated in the cool open air*.

Rhus tox.—Its chief use is in acute phlegmonous inflammation of the lids and erysipelas; lids œdematously swollen (especially the upper) and accompanied by *profuse lachrymation*; there may be *erysipelalous swelling* of the lids, with vesicles on the skin; *chemosis* is often present. The pains are worse at night, and in cold, damp weather, but relieved by warm applications. It may be of service in acute aggravations of chronic inflammation from exposure in wet weather or when worse at that time, with much *swelling of the lids* and *profuse lachrymation*.

Sepia.—Chronic inflammation of the edges of the lids with scales on the cilia and *small pustules on the lid margins* (acne ciliaris). Feeling as if the lids were too heavy, or as if they were too tight and did not cover the ball. *Worse morning and evening*.

Silicea.—Blepharitis from working in a damp place or being in the cold air. (Calc., Rhus.) Indicated in abscess, after suppuration has commenced. Silicea is more particularly called for in the carbuncular form, and especially if the patient is very nervous and the local symptoms are accompanied by sharp pains in the head, relieved by wrapping up warm.

Staphisagria.—Blepharitis, in which the margins of the lids are dry, with hard nodules on the borders and destruction of the hair follicles. *Itching of the lids*.

Sulphur.—A remedy called for, especially in the chronic form of this disease and when found in children of a strumous diathesis who are irritable and cross by day and restless and feverish by night; also for blepharitis appearing after the suppression of an eruption or when the patient is covered with eczema. The lids are red, swollen and agglutinated in the morning, or there may be numerous small itching pustules on the margins. *The pains are usually of a sticking character*, though we may have itching, biting, burning and a variety of other sensations in the lids. There is generally great aversion to water so that *they cannot bear to have the eyes washed*. Eczematous affections of the lids, like eczema in other portions of the body, which indicate Sulphur, are often controlled.

Tellurium.—Eczema of the lids, especially if complicated with a

moist eruption behind the ears and *offensive otorrhœa* smelling like fish brine.

In addition to the above, the following remedies have also proved serviceable: Ant. crud., Arg. met., Lyco., Merc. nitr., Merc. prot., Sang., Seneg.

Hordeolum (*Stye*).—Is an acute inflammation of the cellular tissue of the lid leading to suppuration and pointing at the edge of the lid. The location of the inflammation is usually in the tissue surrounding a hair follicle.

SYMPTOMS.—At first it appears as a circumscribed redness and swelling, which soon extends so that the whole lid will often become œdematously swollen. There is much severe throbbing pain. Often times there are two or more at the same time or they may occur in successive crops.

COURSE.—They will usually point and break in three or four days, though they may undergo absorption without breaking.

CAUSES.—It is usually due to general debility, associated with over use of the eyes, especially in hypermetropes; chronic blepharitis, or conjunctivitis and exposure to cold winds may cause it.

TREATMENT.—We are not often called upon to prescribe for a single stye, but usually to prevent the recurrence of successive crops. If the case is seen at its very outset, especially if severe, cold compresses may be used with advantage, though usually more benefit is derived, especially after its commencement, from hot poultices. If pus has formed, as shown by a yellow point, a small incision can be made to permit its ready escape. If dependent, as it frequently is, upon impairment of the general health, proper hygienic measures must be advised.

Graphites.—Useful in preventing the recurrence of styes. (Compare general symptoms of patient.)

Hepar.—Indicated if suppuration has already commenced, with *throbbing pain, great sensitiveness to touch and amelioration by warmth.*

Pulsatilla.—This is an excellent remedy for styes of every description and in every stage of the disease. If given early, before the formation of pus, it will often cause them to abort; if used later, relief from the pain and hastening of the process of cure is frequently produced, while, as a remedy for the prevention of the recur-

rence of successive crops, it is often of great value. It is especially useful if *dependent upon some gastric derangement*, as from indulgence in high living, fat food, etc., and if *accompanied by acne of the face*; also when found in amenorrhœic females or the peculiar Pulsatilla temperament.

Staphisagria.—Recurrence of styes, especially on the lower lid, which are inclined to abort and leave little hard nodules in the lids.

Sulphur.—To prevent the recurrence of successive crops, especially in a strumous diathesis, as shown by eruptions, boils, etc., on various portions of the body. Cannot bear to have the eyes washed and is restless and feverish at night.

Thuja.—Obstinate forms of styes, which seem to resist treatment and form little hard nodules on the margins of the lids.

The following remedies have also been recommended and used with advantage: Acon., Arsen., Calc., Caust., Con., Lyco., Merc., Pic. ac., Phosph. ac., Rhus and Silicea.

Ptosis is a drooping of the upper lid, due to either partial or complete paralysis of the levator palpebræ superioris. It may occur alone or be associated with a paralysis of the other muscles supplied by the third nerve, and is sometimes congenital. When complete, the upper lid covers nearly the whole of the cornea. The most frequent causes are syphilis, when of a central origin, and trauma when peripheral.

TREATMENT.—Chief reliance must be placed upon internal medication, though sometimes *Electricity* proves of great value, either used alone or in connection with the indicated remedy. If the disease—dependent upon irremediable causes—resists all treatment, operative measures must be resorted to.

Alumina.—The upper lids are weak, seem to hang down as if paralyzed, especially the left. *Burning dryness* in the eyes, especially on looking up. *Absence of lachrymation*. Particularly useful for loss of power in the upper lids *met with in old, dry cases of granulations*.

Causticum.—More benefit has probably been derived from this remedy in the treatment of ptosis than from any other. Its special indication is *drooping of the lid resulting from exposure to cold* (Rhus, from damp cold). The symptoms in the provings very strongly point to Caust. as a remedy in this disorder, as “inclination to close

the eyes; they close involuntarily. Sensation of heaviness in the upper lid, as if he could not raise it easily," etc.

Euphrasia.—If caused from exposure to cold and wet and accompanied by catarrhal symptoms of the conjunctiva.

Ledum.—Ptosis resulting from an injury, with ecchymosis of the lids and conjunctiva.

Rhus tox.—Especially if found in a *rheumatic diathesis* and if the cause can be traced to *working in the wet, getting the feet damp, or to change in the weather*. Heaviness and stiffness of the lids, like a paralysis, as if it were difficult to move them. There may be aching, drawing pains in the head and face, or they may be absent. The concomitant symptoms will point to its selection, though it has proved useful when none are present.

Spigelia.—Ptosis, resulting from inflammation or other causes, in which *sharp, stabbing pains through the eye* are present. Sometimes hot, scalding lachrymation accompanies the above.

Gelsemium, Stannum and *Conium* have been favorably employed in this affection, especially the former. (Compare paralysis of the muscles.)

Many operative measures have been recommended for the relief of *Ptosis*. The old method was simply the removal of a portion of the skin and fibres of the orbicularis muscle, and this, in some cases of partial ptosis, may suffice.

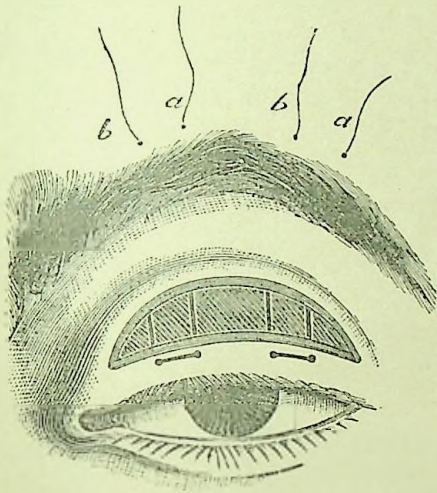
Pagenstecher, in 1881, introduced the operation of inserting subcutaneous sutures, running from near the margin of the lid to the forehead above the brow, and tied tightly, expecting by the resulting cicatrices, as the sutures cut their way out, to raise the lid.

Wecker combines the operation of sutures with the old method of excision, as follows: He removes an elliptical portion of the skin and muscular fibres. He then inserts a strong thread above the brow, running underneath the skin to the upper edge of the wound, over which it passes to the lower border of the wound and then pierces the skin near the free border of the lid; it is now carried parallel to the lid for about five millimetres, where the puncture is again made and it travels backward on a reverse course, parallel to its downward path, to the brow. The two ends are now tied together over a roll of plaster and tightened from time to time as they become loose (Figs. 2 and 3). Two such sutures are introduced

The wound is in this way closed, and, as the sutures cut through, cicatrices are formed which hold the lid up permanently.

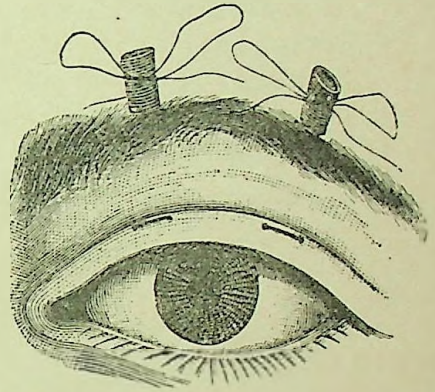
Blepharospasmus.—Spasmodic closure of the lids is often associated with photophobia from some conjunctival irritation, or it may be due to a foreign body, an ulcer of the cornea, iritis, refractive errors, carious teeth, or other reflex conditions. The spasm of the lid may be of the *tonic* variety, in which there is continued and complete closing of the lids, with perhaps an inversion of the eyelashes, which will of course cause great irritation of the eye; or it

FIG. 2.



Wecker's Operation for Ptosis.

FIG. 3.



Wecker's Operation (completed).

may be a *clonic* spasm, when the contractions are intermittent, lasting but a few seconds at a time.

TREATMENT.—This should first be directed to the cause of the irritation, and, as it is usually dependent upon corneal troubles, is relieved with them. When, however, it is independent of other affections, remedies must be prescribed for the spasm *per se*.

Agaricus.—*Twitchings of the lids*, with a feeling of heaviness in them, *relieved during sleep* and sometimes temporarily by washing in cold water. Spasms of the lids. It is very rare to meet a case of morbid nictitation which will not yield to this remedy. (Four-drop doses of the tincture two or three times a day will often relieve when the potencies fail.)

Other remedies which have proved useful in individual cases are Alumina, Cicuta, Ignatia, Nux v., Physos. and Pulsat. Division of the affected nerve may be necessary in aggravated cases. The use of electricity is often of great value in some cases—the positive pole is applied behind the mastoid and the negative on the surface of the lid. Canthotomy, the division of the structures at the outer canthus by means of scissors, may be valuable in cases of tonic spasm.

Nictitatio.—Constant blinking is frequently met with, especially in children and nervous, delicate persons. This condition is generally due to some irritation in the eye itself, or may be reflex, from worms, decayed teeth, etc. Remove the cause, if determinable, and *Agaricus* will complete the cure.

Blepharophimosis.—Narrowing of the palpebral opening is usually caused by chronic *trachoma* and is relieved by canthotomy.

Trichiasis and Distichiasis.—Where there is an irregularity in the shape and position of the eye-lashes so that they become curved in and in contact with the eye, it is called *trichiasis*, and where there

FIG. 4.



Gruening's Epilating Forceps.

is a double row of lashes, one of which is in contact with the eye, it is called *distichiasis*. These conditions are usually due to blepharitis, trachoma, injuries, burns, etc.

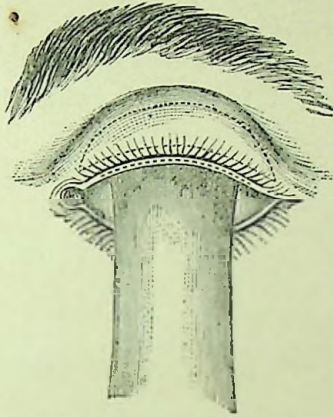
TREATMENT.—Where there are but a few ingrowing lashes, epilation, if often repeated, may cause an atrophy of the hair bulbs and in this way cure the case (Fig. 4).

Electrolysis, as a curative measure, is most serviceable when the lashes to be destroyed are not too numerous. This is done by inserting a needle into the hair follicle and then connecting it with the *negative* pole of the battery, the positive being applied to the temple.

Arlt's operation, when modified to meet the exigencies of the case, seems to be the most generally advisable method of operating for the severe cases and is shown in the illustration (Fig. 5). An in-

cision two or three mm. in depth is made along the free border of the lid, splitting it into two layers. A narrow strip of skin is then excised from the lid, cutting down to the first incision, as shown in the dotted lines in Fig. 5, so that the cilia remain in a bridge of tissue, which is shifted upward and its upper edge attached by sutures to the skin of the lid—its lower margin being left free.

FIG. 5.



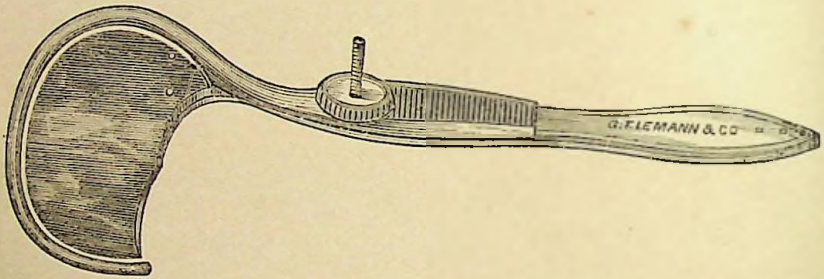
Arit's Operation for Trichiasis.

Entropium is an inversion of the eyelid. We find two varieties of entropium; first the *spasmodic*, which is usually of the lower lid and is due to a spasmodic contraction of the orbicularis muscle. It is often met with in old people, sometimes coming on after operations, and is due to the lax condition of the skin. It may also be due to irritation from a foreign body, from keratitis, etc. The second variety of entropium is the *cicatricial* and is the result of granular and diphtheritic conjunctivitis, burns, etc., where there has been loss of substance in the conjunctiva. The condition gradually comes on during the process of cicatrization and results in an opacity of the cornea.

TREATMENT.—In the spasmodic entropium a cure may often be effected by painting the parts with collodion, which should be renewed every two or three days, or oftener, in order to keep the lid in position. Adhesive strips may be applied for the same purpose. If these measures do not suffice, and always in the cicatricial entropium, operative interference must be resorted to before a cure can be

made. Owing to the excessive vascularity of the lids, free hæmorrhage occurs from any operation upon the lids unless controlled by the use of entropium forceps (Fig. 6.) There are various operations for the relief of entropium, of which perhaps Green's is the most serviceable in the majority of cases. This is made by everting the lid and making an incision parallel to and about two mm. above its free border through the entire thickness of the tarsus, from the conjunctival side, the incision to extend from one canthus to the other. A strip of skin about two mm. wide and from one to two mm. above the cilia is then removed. Three sutures are then passed from the conjunctival side of the cilia through the free edge of the tarsus to just above the lower border of the skin wound; from there they pass through the muscular fibres on the outer surface of

FIG. 6.



Knapp's Entropium Forceps.

the tarsus and emerge from the skin about half an inch above the upper border of the wound. On tying these sutures the ciliary border is everted and the skin wound closed.

Streatfeild's operation is the removal of a strip of skin with subjacent muscular fibres and a portion of the tarsus, just above the border of the lid, by cutting a deep V-shaped groove in its outer surface.

Other operations are Arlt's, already described, and those of Hotz, Snellen, Pope and others.

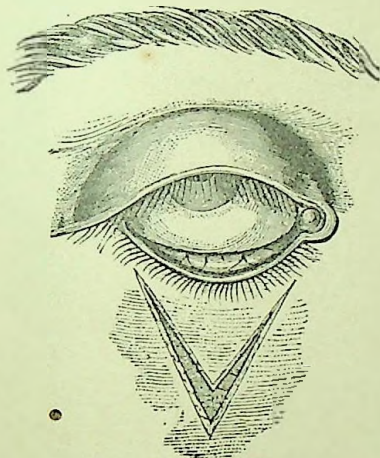
Remedies may possibly be useful, if the inversion is recent and only slight in degree. The following are suggested: Aconite, Argent. nit., Calc. and Natrum mur.

Ectropium is an eversion of the eyelids. The eversion may be slight or so great as to expose almost the whole of the palpebral

conjunctiva. Ectropium is also divided into two classes, the *conjunctival*, due to chronic inflammation and swelling of the conjunctiva, which separates the lid margin from the eye, and this separation serves to increase the trouble by causing the tears to flow over the lid, which, in its turn by this irritation, aggravates the existing trouble. This form is also sometimes seen in children—due to the swelling and inflammation of the conjunctiva, with contraction of the orbicularis. The *cicatricial* ectropium is due to a contraction after loss of the skin of the lids or of the face, following burns, wounds, abscesses, caries of the edge of the orbit with adhesions of the skin, etc.

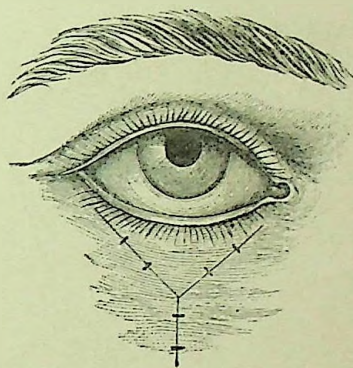
TREATMENT.—In cases of conjunctival ectropium we may some-

FIG. 7.



Wharton Jones' Operation.

FIG. 8.



Wharton Jones' Operation (completed).

times give relief by replacing the lid and retaining it there for several days by the use of the compress bandage. Scarification or removal of a strip of the conjunctiva to reduce the obstruction from thickening of the conjunctiva, together with the slitting up of the canaliculus, to permit the passage of the tears through the normal channels, may be tried. Other operations recommended to correct this affection are legion, and, as they must necessarily vary in nearly every case, according to the cause, degree and position of the eversion, but two will be detailed.

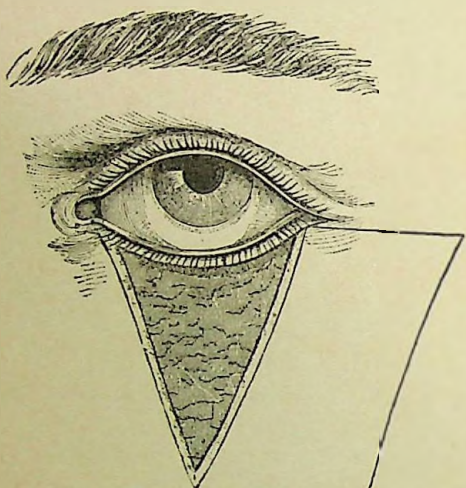
No plastic operation should be attempted until all tendency to

contraction of the cicatrices has disappeared. In all flap operations allowance must be made for shrinking.

In Wharton Jones' operation a **V**-shaped (Fig. 7) incision is made to include all the cicatricial tissue possible; the flap thus formed is to be dissected from the underlying tissues, and the skin at either side undermined sufficiently to allow of the lid being returned to its normal position. The exposed surface is then to be covered by bringing together the edges of the **V**-shaped wound with sutures so that it becomes **Y**-shaped (Fig. 8).

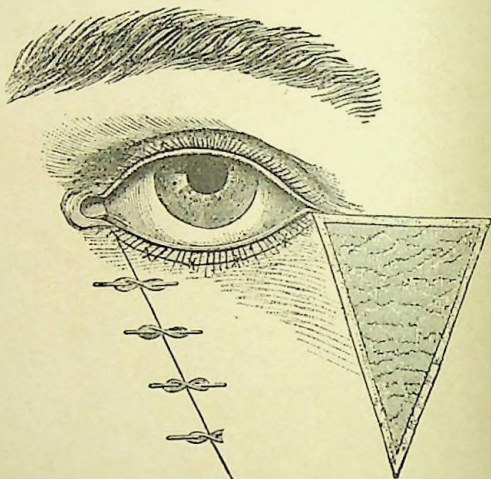
Dieffenbach's operation is made by dissecting away the diseased

FIG. 9.



Dieffenbach's Operation.

FIG. 10.



Dieffenbach's Operation (completed).

tissue by a triangular incision. A flap of skin is then loosened by careful dissection from the immediate neighborhood and shifted up on the exposed surface, where it is kept in position by pins and sutures. (See Figs. 9 and 10.) The surface from which the flap was removed, if small, will become covered by growth of the integument from the edges of the wound; but, when large, it should be filled with grafts of skin from other parts of the body. The ectropium may also be corrected by skin grafting from other parts.

Apis.—Is especially indicated in the first stage of this affection, in which the swelling of the conjunctiva is very great.

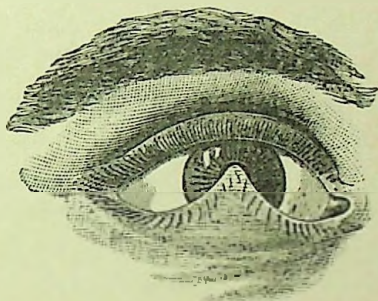
Argent. nit.—If the lids are swollen, inflamed, everted and the *puncta lachrymalia* very red and prominent. The discharge of tears and pus is profuse.

Hamamelis vir.—A dilute solution of "Pond's Extract" applied locally is said to have cured a case occurring during the course of a severe conjunctivitis.

Little reliance must be placed upon internal medication in either entropium or ectropium, as operative measures are almost invariably necessary, except occasionally in the first stage.

Symblepharon.—Adhesion of the eyelid to the eyeball. This condition occurs when, as the result of destruction of the mucous membrane from burns or injuries, or after diphtheritic or trachomatous conjunctivitis, two opposed portions of the conjunctiva grow together and may be either partial, when but one or more bands extend between the lid and globe, or complete, when the entire surface of

FIG. 11.



Symblepharon.

the lid is attached to the globe. The lower lid is most commonly adherent, and more or less limitations in the movements of the eye ensue. It may comprise the cul-de-sacs or the border of the lids (Fig. 11). The thickness of the adherent portions may vary, and we will have a sarcomatous, membranous or fibrinous symblepharon. The mucous membrane in these cases is destroyed to such an extent that simply dividing the adhesions will do no good, as they will at once grow together again. There are two methods of operating upon these cases with some prospect of success. First by separating the affected portions and inserting flaps brought from near by or from the opposite side of the cornea between them; or, second, failing in this, to transplant from another person.

Anchyloblepharon is an adhesion of the ciliary margins of the eyelids. It may be complete or partial, acquired from burns or

wounds, or congenital. The *treatment* is by inserting a grooved director behind the lids and dividing the adhesions.

Epicanthus is a congenital deformity in which a crescentic fold of skin projects in front of the inner canthus. As the child grows it disappears altogether, or becomes much less noticeable, so that operative interference is only called for in high degrees for cosmetic purposes. The operation is to remove an elliptical piece of skin from the bridge of the nose and uniting the edges of the wound together with sutures, care being taken to secure union by first intention by preventing any dragging on the stitches.

Molluscum Contagiosum is an affection of the sebaceous glands. It consists of small, round, whitish prominences which may become inflamed and go on to suppuration. It is a hypertrophy of the gland and the tumor is composed of epithelial elements. For treatment see *chalazion*.

Xanthelasma is a fatty degeneration of the connective tissue of the skin. They appear as yellowish patches, especially on the upper lid. They may be removed by excision for cosmetic purposes.

Milium are small, circular, white tumors. They are removed by incision and pressing out of the contents.

Papillomata (*warts*) are occasionally found upon the edge of the eyelid and upon the conjunctiva. They should be snipped off.

Dermoid cyst is congenital, and contains hair-follicles, hairs, connective tissue, fat, etc. It is generally situated at the outer angle of the orbit, develops slowly and causes but little inconvenience. It should be removed without rupturing the tumor, if possible.

Nævi are found on the eyelids and are similar in appearance to those occurring elsewhere. They are best removed by the galvanopuncture.

Chalazion (*Meibomian or Tarsal Cyst*) is a small tumor situated in the substance of the lid, and is caused by a retention of the secretion of a Meibomian gland, followed by an inflammation of the surrounding tissues. It varies in size, rarely growing larger than a good-sized pea; several may occur at the same time or they may recur in successive crops. The skin is movable over them, but the tumor is adherent to the tissues.

It develops slowly, causing no inconvenience for months. It may suppurate, and, when it does, it usually points on the conjunctiva.

TREATMENT.—*Excision*, as a rule, is the most satisfactory treatment of tarsal tumors, providing there are only one or two. But as it is usually tedious and painful to remove entire a small solid tumor, we may substitute for excision, opening of the tumor squeezing out its contents, and stirring up the sac with the point of a knife. This will cause a slight inflammation which will hasten absorption. It may have to be repeated several times, but, as there will be little pain attending the operation, no objection will be made by the patient. This is also the most efficacious treatment in cases of multiple tumors. After opening and at other times also, I usually apply locally the indicated remedy—especially the tincture of Thuja. In the case of cystic tumors the whole of the cyst wall should be removed; it may be destroyed by the use of a seton, but removal with the knife is usually more satisfactory. Many cases have been cured by internal medication alone, and remedies should always be employed, whether the knife is used or not, for they no doubt hasten the cure and serve to prevent recurrence.

Calcarea carb.—Tarsal tumors occurring in fat, flabby subjects.

Causticum.—Tumors, especially warts, found on the lids and eyebrows.

Conium.—Indurations of the lids remaining after inflammation.

Hepar.—Tarsal tumors that have become inflamed and are sensitive to touch. It also aids absorption after operation.

Pulsatilla.—Tarsal tumors of recent origin that are subject to inflammation, or are accompanied by catarrhal conditions of the eye. The temperament and general symptoms will decide the choice.

Staphisagria.—An important remedy for tumors of the lid. Enlargement of the glands of the lids, which are red and accompanied by tensive tearing pains, especially in the evening. For little *indurations of the lids, resulting from styes*, or for successive crops of small tarsal tumors, this drug is especially indicated.

Thuja.—This is one of the most valuable remedies for tarsal tumors, whether single or multiple, especially if they appear like a condyloma, either of the internal or external surface of the lid. We have seen them disappear by simply giving the drug internally, though it usually seems to act more speedily if we use, at the same time, the tincture externally. It is also recommended for the prevention of their return after removal by the knife and for hasten-



ing their absorption after operation. For condylomata, or warty excrescences on the lids, especially if occurring in syphilitic subjects, this drug deserves attention.

Zincum.—Tumors of the lids with *soreness and itching in the internal canthi*.

Baryta carb. and iod., Graph., Lyco., Kali iod., Merc., Nitric acid, Sep., Sil. and Sulph. may be required.

Epithelioma is the most frequent malignant growth affecting the eyelid. It rarely occurs before the age of forty, and appears first as small hard nodules, and later becomes covered with a scab, which, on being removed, shows a slight excoriation; this increases to an ulceration of considerable depth, with purulent secretion and irregular, hardened edges. It may remain indolent for months, then assume an active stage, leading rapidly to extensive destruction of tissue. In the early stages there is little or no pain, but becomes excessively painful in the later stages.

Lupus and Sarcoma have both been found affecting the eyelids. A lupoid growth is more slow in development than an epithelioma, and both may result in ulceration; but, as Noyes¹ so well says, "A discrimination between them is hardly needful for practical purposes."

TREATMENT.—*Excision* is advised in all malignant growths of the lids, if the disease is circumscribed and moderate in extent; care being taken that all the morbid tissue is removed. The edges of the wound may be brought together by sutures, or a plastic operation may be made, bringing the integument from the temple or some adjoining point.

Juler² advises *scraping* away all the diseased tissue by means of a small steel scoop. This is attended with considerable hæmorrhage, and is tedious, but he claims its success in arresting this malignant affection is marvellous.

Various caustics have also been employed, chief among which may be mentioned caustic potash, nitrate of silver, chloride of zinc, arsenic paste and acetic acid. An objection to the use of caustics lies in the deformity apt to occur afterward. Electrolysis has been recommended.

¹ Diseases of the Eye, 1890.

² Ophthalmic Science and Practice, 1884.

If the disease is very extensive, involving the tissues of the face to such an extent that extirpation is impracticable, we then rely chiefly upon our internal remedies, using only such local applications as prove agreeable and of temporary relief to the patient. For instance, if the discharge is profuse and offensive, a weak solution of carbolic acid, salicylic acid, or some other disinfectant proves of service. An application from which we have often seen excellent results is carbolic acid and linseed oil (4 grains to the ounce); it relieves the patient and seems to exert a beneficial effect over the progress of the disease.

Apis.—Lupus non exedens, *sharp, stinging pains*, and tendency toward puffiness of the lower lids.

Hydrocotyle asiatica.—Has obtained a high reputation in the hands of Dr. Boileau as a remedy for lupus and deserves our attention. (We have, however, failed to perceive any results from its use).

Phytolacca dec.—Benefit seems to have been derived in relieving, if not curing, malignant ulcers of the lids, when used both externally and internally.

Thuja.—Epithelioma of the lids.

Herpes Zoster Frontalis commences with severe neuralgic pains along the frontal and nasal nerves. The skin becomes swollen and red, covered with herpetic vesicles which unite, crusts form upon them and ultimately leave deep cicatrices. The disease involves one-half of the face, never extending beyond the median line, and has often associated with it corneal ulcers and iritis.

TREATMENT.—The remedies most useful are: *Ars.*, *Croton tig.*, Electricity, Graph., *Merc.*, Puls., *Ranunculus btbl.* and *Rhus*.

Syphilitic Ulcers, Chancre, and Gummata are all occasionally found on the eyelids, and should be treated the same as occurring elsewhere. The most useful remedies are the following, prescribed according to general indications: *Ars.*, *Apis*, Aurum, Cannab., *Hepar*, *Kali. iod.*, *Merc.*, Nitric ac., and *Thuja*.

Contusions are very often found, and are frequently accompanied by some lesion of the globe or orbit.

TREATMENT.—Immediately after contused wounds of the lids, cold compresses should be employed; they should be applied with a firm bandage, which often proves of advantage in limiting the amount of ecchymosis.

Arnica, our great remedy for all contusions, deserves its extensive reputation for curing "black eyes," as there is no other drug better adapted to this condition. A solution of the tincture in water, ten drops to the ounce, is usually employed, though both stronger and weaker solutions are in vogue. *Ledum*, used in the same manner, has also proved of service.

Wounds.—We may have an incised, lacerated, or penetrating wound of the lid; and, in all cases, the condition of the orbit and globe should be carefully examined to see if they remain intact.

TREATMENT.—The first object in view should be to bring together the edges of the wound by means of *sutures*, adhesive strips or collodion; after which the application of a solution of *Calendula*, ten drops to the ounce of water, may be applied. If the tissues are very much bruised *Arnica* may be employed, though, as a rule, *Calendula* will be found more useful in cut wounds. If the wound is incised, without any contusion, and the edges are early brought accurately together, a dry dressing will often be found most beneficial.

Hamamelis and *Ledum* have both been recommended for wounds of the lids.

Burns and Scalds must be treated as usual in other parts of the body, except that care should be taken to prevent the union of the lids (*anchyloblepharon*) by frequently opening them, and by inunction of the edges with simple-cerate or *cosmoline*; also, great attention should be paid to the prevention of a *cicatrix* (which causes *ectropium*) by keeping the skin on the stretch by a bandage during the period of *cicatrization*. *Cosmoline* is especially recommended as an external application.

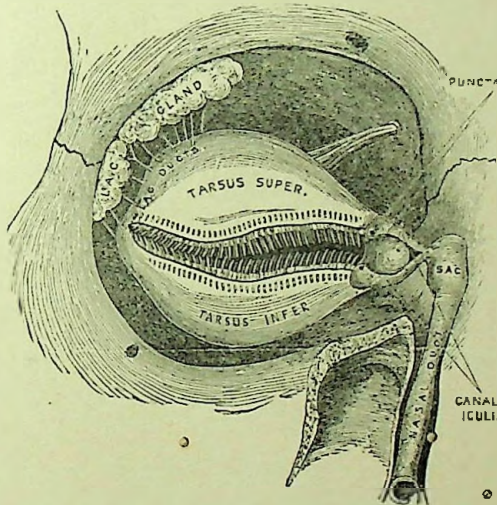
When dependent upon the stings of insects, the sting should be removed and cold-water dressings applied.

CHAPTER II.

Affections of the Lachrymal Apparatus.

Anatomy.—The *lachrymal gland* is lodged in a fossa at the outer and upper part of the orbit and close to its anterior margin. It is separated into two portions by a septum of connective tissue, the larger part of the gland being about twenty mm. in length and ten to twelve in breadth. It is an acinous gland like the salivary. The excretory ducts, some ten to fourteen in number, run from both por-

FIG. 12.



Dissections of the Lachrymal Apparatus.

tions of the gland to the upper and outer part of the superior fornix of the conjunctiva. The secretion of the lachrymal gland is faintly alkaline, containing about 1.25 per cent. of sodium chloride and .5 per cent. of albumin. It serves to moisten the anterior surface of the eye, and passes off through the puncta, canaliculi, lachrymal sac, and nasal duct, into the inferior meatus of the nose (Fig. 12). The *puncta* are the two minute openings of the canaliculi, on the free

margin and about six mm. from the inner angle of the lids. The *canaliculi*, both upper and lower, extend from the puncta to the lachrymal sac, just before reaching which they unite. The upper canaliculus is slightly smaller than the lower, and first ascends, then turns downward and inward. The lower canaliculus first descends, then runs horizontally to the sac. The *lachrymal sac* is the upper dilated portion of the nasal duct. It is located in a groove formed by the lachrymal and superior maxillary bones; its upper end is closed and rounded. The *nasal duct* extends from the lachrymal sac to the inferior meatus of the nose. The bony canal is lined with a fibrous membrane, and this, in turn, by cylindric epithelium like that of the nostrils. It is highly vascular and thrown into folds at two or three points. The total length of the sac and duct is about one inch. Its direction is downward, backward and slightly inward. The tears are forced into the excretory passages by muscular action, aided by a kind of suction caused by the muscular fibres of the puncta and canaliculi.

Dacryoadenitis.—Inflammation of the lachrymal gland is extremely rare. In the *acute* form the symptoms are, great swelling and redness of the upper lid at its outer angle. The globe may be displaced downward and inward by the swelling. The pain is severe and increased by touch. The conjunctiva is inflamed and may be chemosed. The inflammation may terminate by resolution, suppuration, or run into the *chronic* form, in which all the acute symptoms are less severe, merely a considerable swelling remaining. Dacryoadenitis is generally caused by injury, and this fact, together with its symptoms, makes it very difficult to diagnose from periostitis of the orbit or abscess of the lid.

TREATMENT.—When in the early stage, before there is a formation of pus, ice will often cut short an attack which might otherwise go on to suppuration. As soon, however, as there is evidence of suppuration, we should resort to hot fomentations in order to promote suppuration, and, when well established, a free incision should be made through the conjunctiva, if possible. The most useful remedies are Acon., Apis., *Hepar*, Rhus. and Silicea. For indications see *dacryocystitis phlegmonosa*.

Hypertrophy of the Lachrymal Gland is very rare. It is a circumscribed, nodular tumor of gradual growth and has been known


to occur in children and infants. If it increases sufficiently to cause interference with the movements of the eyeball it should be removed.

Tumors of the Lachrymal Gland, such as fibroids, sarcomatas, adenomas, hydatid cysts and cancers have all been recorded. They require extirpation of the gland.

Anomalies of the Puncta and Canaliculi.—Eversion of the puncta is frequently found in blepharitis and conjunctivitis, causing epiphora, or watering³ of the eye.

The same result will occur from a narrowing or stoppage of the canaliculus, wounds of the lid involving the canaliculus, or foreign bodies in the canaliculi blocking the passage of the tears. Obstruction of the canaliculus can be relieved by slitting up the canal with the canaliculus knife (Fig. 13), a narrow-bladed, probe-pointed

FIG. 13.



Agnew's Canaliculus Knife.

knife, which is to be entered into the puncta vertically, the handle then brought to a horizontal position, when the knife is pushed directly inward until it reaches the inner wall (the lid being kept taut with the thumb of the other hand), the knife is then brought to the vertical position, cutting through the whole length of the canaliculus. The edge of the knife should be kept toward the conjunctiva during its passage, so as to divide the canaliculus close to the mucocutaneous junction.

Stricture of the Ductus Lachrymalis.—Stricture of the nasal duct is the most common affection of the lachrymal apparatus.

SYMPTOMS.—The *symptoms* are few. The chief characteristic symptom of stricture is the overflow of tears, which is increased on exposure to cold wind or bright light. There is also often noticed a dryness of the nostril on the same side as the stricture. Usually on making pressure with the finger over the sac we can press out from the puncta a few drops of clear viscid secretion. We may also find a slight conjunctivitis present.

CAUSES.—The cause of this affection is often difficult to determine. It may come on as an extension of a nasal catarrh. Injury or peri-

ostitis of the nasal bones, carious teeth, or pressure from tumors in that vicinity may cause it.

Dacryocystitis Catarrhalis.—Catarrhal inflammation of the lachrymal sac is generally the result of a stricture or associated with it. While, on the other hand, the catarrhal inflammation may be the cause of the stricture, as the swelling of the mucous membrane will in itself cause a damming up of the secretions. The retention of the tears causes a gradual distension of the sac—a swelling at the inner angle of the eye. By making firm pressure on this swelling the mucus can be pressed either out of the canaliculus or down through the nasal duct into the nose. The contents of the swelling may be either clear and transparent or mixed with pus. This disease usually develops very slowly, with simply the history of having had a watery eye for a long while previous to noticing any swelling of the sac, and often times they will notice a dryness of the corresponding nostril. The swelling is usually free from pain or sensitiveness to touch.


TREATMENT.—Since lachrymal diseases are frequently dependent upon nasal catarrh, treatment must be directed to this affection; if aggravated by the presence of nasal polypi, or caused by foreign bodies, these must of course be removed.

As in nearly all cases of blennorrhœa of the sac, a more or less firm stricture of the lachrymal duct is present, this will require our special attention. Slight or moderate strictures (almost always dependent upon catarrhal inflammation) may be treated by appropriate medication, from which better results will be finally obtained than from probing. If there is a stricture in the canaliculus, as is often the case, at the entrance to the sac, so as to prevent the collection of tears and diseased secretions in the sac from being readily pressed out, the canaliculus should be divided at once. If the stricture in the nasal duct is so great as to almost close it, or if there is closure, the best operation to divide the stricture is that of Stillings, who, after slitting the canaliculus (as already described), introduces into the lachrymal sac a triangular shaped knife (Fig. 14) in the same way as a probe, and then forces it down two or three times in succession, the blade being turned in a different direction at each passage. Blood issuing from the nostrils is proof that the passage has been opened. Care should be taken for a day or two after the operation

to see that the canaliculus does not close, and, commencing on the second day after the operation, the duct should be probed every two or three days until it remains permanently opened.

A passage sufficient to admit of a Bowman probe from No. 5 to 8 (varying in different cases) should be secured (Fig. 15). The use of larger probes has been recommended, but in my experience they have not proved as satisfactory. If there is very little catarrhal inflammation, especially in children, it is not always necessary to probe

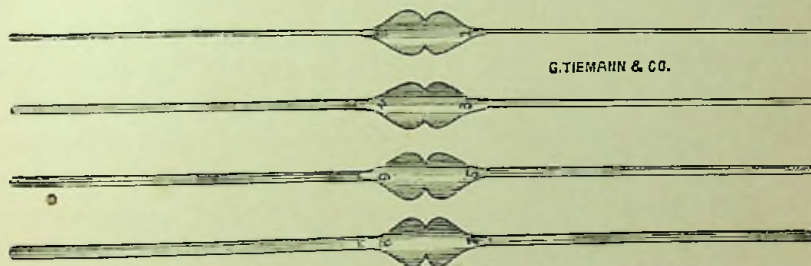
FIG. 14.



Stillings's Knife for Stricture of the Lachrymal Passage.

after Stillings's operation. A far better method than operating, when it can be carried out, is that of gradual dilatation of the strictures by using larger and larger probes. Commencing with No. 0 or 00, the canaliculus and duct can be gradually distended so as to admit of a No. 4 or 5 Bowman probe without even slitting the canaliculus.

FIG. 15.

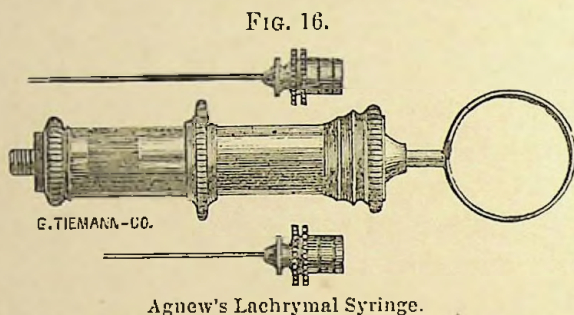


Bowman's Set of Probes, Nos. 1, 2, 3, 4, 5, 6, 7, 8.

Rarely, where the puncta is occluded, it will be necessary to slightly nick it with the point of the knife so as to admit of the smallest sized probe. The advantages of this method seems to lay in the fact that we do not destroy the function of the parts and that the normal suction action of the canal is retained. This plan, of course, is not practical in very firm or bony strictures. Marked benefit has also been observed from electrolysis, and there is no doubt it should be more extensively employed. My plan has been to insert a probe in the usual way until it comes in contact with the stricture, then

attaching the probe to the *negative* pole of a battery, apply the positive to the temple, and make gentle pressure as the stricture yields. Usually four or five treatments will be sufficient to keep the passage permanently opened.

In the treatment of the blennorrhœa, a free vent for the secretions through the opened or unopened canaliculus being present, the patient should be instructed to press out the matter several times a day. Also anything that tends to produce irritation, as cold winds and over exertion of the eyes, should be avoided. Mild astringent injections of boracic acid, sulphate of zinc of a two to four per cent. solution or some similar preparation may sometimes prove very serviceable.



Recently I have been using with good results an injection of the blue pyoktanin, 1 to 1,000.

Aconite.—Inflammation of the lachrymal sac, with great heat, dryness, tenderness, sharp pains and general fever.

Argentum nit.—Discharge very profuse, caruncula lachrymalis swollen, looking like a lump of red flesh; conjunctiva usually congested.

Aurum triph.—Catarrh of the lachrymal sac, with desire to bore into that side of the nose; nose obstructed, compelling to breathe through the mouth; nostrils sore, the left discharges continually.

Calendula.—As a local application in blennorrhœa of the sac has been found useful, especially in cases of great tenderness after the canaliculus has been opened.

Euphrasia.—Much *thick, yellow, acrid discharge*, making the lids sore and excoriated. Blurring of the vision relieved by winking. Thin, watery, *bland discharge* from the nose.

Hepar sulph.—Inflammation of the lachrymal sac after pus has

formed or in blennorrhœa, with great sensitiveness to touch and to cold, with profuse discharge. Also useful in controlling the discharge after the canaliculus has been opened.

Mercurius.—Discharge thin and excoriating; acrid coryza; nocturnal aggravation.

Petroleum.—Discharge from the lachrymal sac, with roughness of the cheek, occipital headache, and other marked concomitant symptoms.

Pulsatilla.—One of the most important remedies for dacryocystitis, which may sometimes be cut short at its very beginning with it, and may be useful at any stage of the inflammation. It is also important in blennorrhœa of the sac, if the *discharge is profuse and bland*. Profuse thick and bland discharge from the nose; especially beneficial in children.

Silicea.—Occasionally indicated in dacryocystitis characterized by the usual symptoms; even cases that have far advanced toward suppuration have been checked. Blennorrhœa of the lachrymal sac often calls for it. The patient is particularly sensitive to cold air and wishes to keep warmly covered.

Stannum.—Very favorable results have frequently been obtained in controlling the yellow-white discharge from the lachrymal sac, itching or sharp pain in the inner canthus, especially at night.

Other remedies which have been recommended and proved useful are Bell., Calc., *Cinnab.*, Hydrast., Kali iod., Merc. prot., *Nat. mur.*, Nux, Sulph. and *Zinc. sulph.*

Dacryocystitis Phlegmonosa.—Phlegmonous inflammation of the lachrymal sac may be considered as merely a higher stage or extension of the preceding disease.

SYMPTOMS.—In this the swelling is greatly increased and extremely sensitive to touch. The integument becomes very tense and assumes a dusky-red hue. There is usually an œdematous infiltration of the surrounding parts, viz: Eyelids, side of the nose and cheek. There is intense pain and heat, with sometimes general symptoms of chills, fever and vomiting. The conjunctiva may be inflamed and even chemosed. The appearance at this time resembles an abscess of the cellular tissue overlying the lachrymal sac and must be carefully differentiated, but in dacryocystitis phlegmo-

nosa firm pressure over the swelling will usually empty the tumor either through the puncta or downward through the nose, while in abscess it will not. In dacryocystitis we also have the previous history of a long-continued lachrymation, which is, of course, absent in abscess.

COURSE.—If left to itself the swelling usually increases steadily, the skin over the sac becomes thinner and thinner, until it finally gives way, causing a fistula of the lachrymal sac, which often-times is extremely difficult to heal.

CAUSE.—The exciting cause of a phlegmon of the sac is probably in the majority of cases a simple cold in the head, which serves to aggravate an already existing catarrh of the sac.

TREATMENT.—At the commencement of an inflammation of the lachrymal sac, before the formation of pus has begun, cold compresses (even ice) are advisable, which, together with the indicated remedy, may cause the inflammation to abort before an abscess has formed.

As soon, however, as pus has begun to collect in the lachrymal sac, our treatment must undergo a decided change. The first and most important step to be taken is the opening of the canaliculus into the sac and the evacuation of its contents, thus giving the pus free exit through the natural channel. This, as we have said, must be done as soon as suppuration is suspected, for, if not attended to, an opening externally will be made, and a lachrymal fistula may be the result. But if the disease has so far advanced that perforation is inevitable, a free incision into the sac should be made externally, after which, and also in case the abscess has opened spontaneously, warm compresses may be employed for twenty-four or forty-eight hours, but must not be continued too long. After the subsidence of the inflammation this opening will usually close without trouble, though it may be necessary to open the nasal duct and establish a free passage for the tears before it does so. Probing of the nasal duct should be avoided until the severity of the inflammation has subsided. Warm applications should be substituted for the cold as soon as suppuration has commenced. Among the best of those in use is a solution of calendula. Internal medication during the whole course of the disease will form an important feature in the treatment.

Aconite.—In the first stage, when the lids are much swollen, with

a tight feeling in them; chemosis, with much *heat* and *sensitiveness* in and around the eye, and a sensation as if the eyeball were protruding, making the lids tense.

Apis mel.—Before the formation of pus. *Lids œdematously swollen, with stinging, shooting pains.* Patient drowsy, without thirst.

Hepar sulph.—Especially after pus has formed. Lids swollen and *very sensitive to both touch and cold.* *Throbbing pains.*

Mercurius.—In the later stages, after pus has become *thin* in character and especially when occurring in syphilitic patients. Pains in and around the eye, always worse at night.

Pulsatilla.—In the early stages, when there is considerable swelling of the lids, with burning pains. *Profuse lachrymation*, aggravated in the open air. Pulsatilla will sometimes abort an inflammation and prevent the formation of pus, even when the swelling is extensive and sensitive to touch.

Silicea.—Is often indicated in dacryocystitis characterized by pain, swelling, tenderness and lachrymation, especially if patient takes cold easily or is very sensitive to a draught of air.

Fistula Lachrymalis.—An opening externally of the lachrymal sac when the result of an abscess breaking, is often very obstinate and difficult to heal; hence, when evidently about to break, it should be opened with a bistoury.

TREATMENT.—The first point to be attended to is to see that the passage is free into the nose. We must therefore slit up the canaliculus and divide any stricture found in the nasal duct, providing it is sufficient to interfere with the flow of tears; after which the canal should be kept open.

The fistula must now be healed, and, if recent, this is best done by touching the edges with a stick of nitrate of silver. The galvano-cautery, lightly applied to the edges of the fistula, may also greatly aid the healing process. Packing it with alumen exsiccatum has also proved of advantage. If the edges of the fistula are healed and covered with smooth skin, it will be necessary to pare the edges and unite with a suture.

The following remedies have been advised and may have been of service in recent cases, though we doubt if any effect can be obtained in old chronic fistulæ: Brom., Calc., Fluoric ac., Lach., Merc., Nat. mur., Petrol., Sil. and Sulph.

CHAPTER III.

Diseases of the Orbit.

Anatomy.—The shape of the orbit is that of a quadrangular pyramid, the base or facial opening, the four walls and the apex. The axes of the orbits converge posteriorly at an angle varying in different individuals. The bones entering into the formation of the orbital walls are the frontal, sphenoid, superior maxillary, malar, palate, ethmoid and lachrymal. The optic foramen, situated at the apex of the orbit, transmits the optic nerve and the ophthalmic artery. The superior orbital fissure transmits the third, fourth and sixth nerves, ophthalmic branch of the trigeminus and the superior and inferior ophthalmic veins. The inferior orbital fissure gives passage to the malar and infraorbital nerves, infraorbital vessels and a facial branch of the ophthalmic vein. The supraorbital notch, at the upper and inner margin of the orbit, contains the supraorbital nerves and artery as they pass to the forehead. The orbit, in addition to the eyeball, vessels, muscles, etc., contains considerable adipose tissue.

Tenon's Capsule is the limiting membrane between the cellulofatty tissue and the globe and conjunctiva. It ensheaths to some extent the muscles, vessels, nerves, etc., that pass through it, and is continuous with the periosteum of the orbit as well as with the conjunctiva. It is somewhat analogous to the pleura, and serves as a cup in which the globe revolves. It constitutes a secondary attachment for the ocular muscles, and by this attachment it renders it possible to sever the tendon of a muscle without losing its entire action upon the eye, for it still remains in connection with the eye through Tenon's capsule, unless too extensive lateral cuts have been made, separating the tendon from the capsule. The dura mater is firmly attached at the sphenoidal fissure and optic foramen and is continuous with the outer sheath of the optic nerve and with the periosteum of the orbit.

Cellulitis Orbitæ.—Inflammation of the cellular tissue of the orbit

may occur as a simple *œdematous cellulitis* or in a far more active form as a *phlegmonous cellulitis*.

SYMPTOMS.—In *œdematous cellulitis* the eye will be slightly bulged forward, its movements limited and sometimes diplopia is complained of. There is usually in these mild cases little or no swelling or redness of the lids or conjunctiva, and but little dull pain, except on pressure upon the globe. This form of cellulitis generally occurs in young and delicate children, and usually subsides within a few days.

In the severer form, or *phlegmonous cellulitis*, the onset is apt to be accompanied with a chill and rise in temperature. There will be swelling and dusky discoloration of the lids, especially the upper, and a more or less intense pain, greatly increased by pressure upon the globe. The eyeball is protruded directly forward, and its movements limited in all directions; in some severe cases it will have absolutely no motion. (In periostitis the protrusion of the eye and the limitation in its movement is in but one direction.) The conjunctiva is chemosed. Diplopia is usually present and the vision may be greatly impaired. Digital examination will find the tissues firm, tense and very painful to the touch. In extreme cases the eyeball may become involved and end in panophthalmitis.

CAUSES.—Various and frequently obscure. May be metastatic from phlebitis, septicæmia, puerperal fever, etc. It is often coincident with facial erysipelas. May result from injuries, periostitis and inflammation of the lachrymal gland.

PROGNOSIS.—Is always serious as it usually leads to suppuration. The large majority recover, though it may terminate fatally through meningitis and abscess of the brain.

TREATMENT.—When this form of inflammation results from an injury, or the introduction of a foreign body, the latter should be first removed, and then cold compresses of Calendula solution, or ice bags, be employed to subdue the inflammatory symptoms. But if suppuration has already set in, poultices should be applied to promote the discharge of pus, which should be evacuated *at an early period*, by a free incision through the conjunctiva if practicable, if not, through the lid itself. Care should be taken that the pus has free vent at all times. Noyes (*loc. cit.*) advises an early incision, even before pus forms, claiming its value “as a means of arresting the

phlegmonous inflammation and the formation of pus," as by the incision "the tension of the oculo-orbital fascia is relieved, the vessels are unloaded, serum finds vent and the tissues are relaxed." Diet and rest should be prescribed according to the general tone of the patient and severity of the attack.

Aconite.—In the first stage, when the lids are much swollen, with a tight feeling in them; chemosis, with much *heat* and *sensitiveness* in and around the eye, and a sensation as if the eyeball were protruding, making the lids tense, associated with the general Aconite fever.

Apis mel.—Before the formation of pus. *Lids œdematously swollen, with stinging, shooting pains.* Patient drowsy, without thirst.

Hepar sulph.—Especially after pus has formed. Lids swollen and *very sensitive to both touch and cold.* The pains are usually of a *throbbing character.*

Lachesis.—Orbital cellulitis following squint operation, point of tenotomy sloughing, with a *black spot in the centre*; chemosis, and much discharge, with general Lach. condition.

Mercurius.—In the later stages after pus has formed, and even after it has discharged for some time and has become *thin* in character, especially if occurring in a syphilitic subject. There is often much pain in and around the eye, always worse at night.

Phytolacca.—Inflammation of the cellular tissue of the orbit without much pain, slow in its course and with little tendency to suppuration. The eye will be protruded and the infiltration into the orbit and lids will be hard and *unyielding to touch.*

Rhus tox.—This is a remedy of the very first importance in this form of inflammation, whether or not of traumatic origin. *The lids are œdematously swollen, as well as the conjunctiva,* and, upon opening them, a profuse gush of tears takes place. The pains vary in character and may be greatly influenced by any change in the weather. Panophthalmitis is liable to complicate the trouble. See under Rhus. Other remedies may be thought of, as Ars., Bell., Bry., Kali iod., Sil., Sulphur.

Tenonitis.—Inflammation of the capsule of Tenon is a comparatively rare disease which may follow operations for strabismus and less frequently occurs idiopathically, especially in those of a rheumatic diathesis.

SYMPTOMS.—There may be slight swelling of the lids, chemosis of the conjunctiva, exophthalmos and diminished mobility of the eye. Pain more or less severe, especially on pressure, is apt to be present.

TREATMENT.—Internal medication is all sufficient in this disease and the most serviceable remedies are *Kalmia lat.*, *Kali iod.*, *Rhus* and *Puls.*

Periostitis Orbitæ.—Inflammation of the orbital periosteum may result from injuries or occur idiopathically in rheumatic, syphilitic or scrofulous subjects. The disease is most commonly found in early life and its usual location is the margin of the orbit.

SYMPTOMS.—There is present pain, especially from pressure on the bone, œdema of the lids, chemosis and a tense, swollen, sensitive spot in which fluctuation may be detected later. Periostitis in its *acute* form resembles very closely a phlegmonous cellulitis, and must be differentiated by the acute pain on pressure upon the orbital margin; by less swelling and redness of the lids; the inflammation is more circumscribed, so that the displacement of the eyeball is in one direction and its mobility is more restricted in one direction.

In the *chronic* form of periostitis there is simply slight swelling of the upper lid and supraorbital pain, together with localized swelling at the seat of the inflammation.

COURSE.—When chronic, it is very tedious, lasting months or years, and is apt to result in caries of the bone, fistulæ, deformity of the lids, etc. In the acute form, if the abscess is near the surface and promptly opened, it may heal in a short time; but if deep and neglected, or if occurring in one of a syphilitic or scrofulous constitution, will usually be much more serious.

Caries and Necrosis of the orbital walls is almost universally a result of periostitis, although it may occur in the bone itself without a previous inflammation of the periosteum. After the abscess has opened, a fistula is formed which leads to the roughened and denuded bone. The discharge of pus through the fistula has the peculiarly fetid odor of osseous caries. The general symptoms of periostitis are present in caries, and, in addition, the diseased bone can be detected by the probe.

TREATMENT.—The general plan of treatment is very similar to that recommended for cellulitis, as we should at first endeavor to

prevent destruction of tissue, but, if that does occur, give the pus free vent. If the bone should be diseased the opening must be kept open and an injection of a solution of carbolic acid 1 to 100, or of the sulphate of zinc gr. x to ʒj may be used with advantage. If any loose pieces of the bone are discovered they should be removed. The remedies described under cellulitis are also applicable to this disease; in addition to which we note the following:

Aurum.—For both periostitis and *caries*, when *dependent upon or complicated with a mercurio-syphilitic dyscrasia*; also useful in strumous subjects. The pains are tense, and seem to be in the bones, are worse at night, bone sensitive to touch and the patient is excessively sensitive to pain.

Calc. hypophos.—In appreciable doses, has been used as a “tissue remedy” in scrofulous subjects, apparently with good results.

Kali iod.—This form of potash is one of the most important remedies we possess for periostitis. It is especially adapted to the syphilitic variety, though useful when dependent upon other causes. The pain is usually marked, though may be absent entirely. The lids will often be œdematous. The crude salt in large doses has seemed to act more rapidly than the attenuations.

Mercurius.—As described under cellulitis, will be found very useful in both periostitis and *caries*, particularly when dependent upon syphilis, as the nocturnal aggravation is very marked under both the drug and disease. The different forms are employed according to general indications.

Silicea.—Its action upon diseased bone renders it especially valuable in *caries* of the orbit. The roughened bone and moderately profuse yellow-white discharge are the principal indications, though the weakened general condition, relief from warmth and other concomitant symptoms will be present.

The following remedies may be required: Asaf., Calc. carb., Fluoric acid, Hecla lava, Lyco., Mezer., Nitr. ac., Petrol., Phosphor. and Sulphur.

Empyema of the Frontal Sinus is extremely rare. The cause is uncertain. It may occur at any time of life, except in young children. The early swelling and distension are unnoticed, but it finally perforates the bony wall and a swelling appears at the upper and inner angle of the orbit, causing epiphora, displacement of the eye

downward, forward, and outward, with diplopia. The patient may have had headache for a long time, or it may have caused but little discomfort. "

TREATMENT.—Similar to that given for cellulitis and periostitis.

Tumores Orbitæ.—In the orbit may be found both benign and malignant tumors, which may have developed primarily in the orbit or have spread from the eyeball or face. They usually cause more or less exophthalmos and restriction in the mobility of the eye; the displacement of the eye depends upon the location of the growth. The eye may suffer from inflammation, the optic nerve may become inflamed or atrophic, the retina detached, etc. The examination should be directed to the degree and direction of the exophthalmos; to the impairment in motion, whether in one direction or all; to the feel of the growth, its smoothness, mobility, solidity, pulsation, fluctuation, etc.

We note the effect of pressure upon the eyeball, if it causes pain on being pushed backward, or if the position of the tumor is altered. We inspect the nostrils, the pharynx, the frontal and maxillary sinuses. The tumor may be explored with the hypodermic syringe. The history of the case should be elicited for hereditary tendency, the progress of the growth whether slow or rapid, whether associated with pain or not. All these points and many more should be considered as an aid to diagnosis, prognosis and treatment. Nearly all varieties of tumors may be found in the orbit, viz.: Osteoma, nævi, angioma, lipoma, fibroma, cysts (dermoid or hydatid), neuro-fibroma, lymphoma, sarcoma, scirrhus, encephalocele, epithelioma, etc.

TREATMENT.—The most approved method of treatment of all tumors of the orbit is to remove them as early as possible, endeavoring to save the eye whenever sight is present, unless it be a malignant growth and there is danger of not removing the whole of the tumor without sacrificing the globe; in which case it is usually better to remove all the contents of the orbit. A careful diagnosis must be made before operating, in order to aid in the operation and prevent the opening of a vascular tumor.

Electricity is of great value in removing vascular tumors of the orbit. When the growth is small the negative pole may be applied by a sponge to the temple, but if large both poles should be attached to platinum needles, two or three inches in length, which are then to

be inserted into the tumor. The positive needle should remain in one position while the negative may be inserted at different points for a few moments at a time. Care should be taken to make the first sitting brief, from fear of a too severe inflammatory reaction.

Our remedies are the same as for tumors in other portions of the body, though we would especially mention *Thuja* and *Kali iodata*, which have been of service in some cases.

Wounds and Injuries of the Orbit may prove serious from inflammation of the orbital tissue, or periostitis, which they may cause. Injury causing fracture of the orbital walls may prove more or less serious according to the location and extent of the fracture; a slight lesion of the orbital margin may heal without trouble; in fracture of the frontal or ethmoidal cells we will usually have emphysema of the orbit and lids, due to an entrance of air into the cellular tissue. If the injury has occurred in the vault of the orbit, we may have a serious inflammation of the brain or its membranes. Fracture of the roof of the orbit has frequently been found with a fracture of the base of the skull. Out of 86 cases of fracture of the base of the skull, fracture of the orbital roof was found in 79.¹ Hæmorrhage into the cellular tissue is very apt to occur in all injuries or wounds of the orbit. Foreign bodies of large size have frequently remained imbedded in the orbital tissues for a long while without creating any material disturbance.

TREATMENT.—When a foreign body has penetrated the orbit it should be removed as soon as possible, after which cold compresses of calendula in solution, or bags of ice, should be applied.

If there has been an effusion of blood into the orbit, as the result of any injury, or when spontaneous (as is rarely the case), causing the eye to protrude, a cold compress and a firm bandage will be found very beneficial. In emphysema of the orbit and lids a compress bandage will be required.

Morbus Basedowii (*Exophthalmic Goitre, Graves' Disease*).

SYMPTOMS.—The main symptoms of this disease are: rapidity of the heart's action, enlargement of the thyroid and protrusion of the eyes, although any one of these symptoms may be absent. The acceleration of the heart's action is the earliest, most constant and essential symptom, and this may reach from 100 to 200

¹ Berlin: Graefe and Saemisch, Handbuch der Augenheilkunde, 1880.

beats per minute and may be weak and irregular. Linnell¹ in an excellent paper on this disease calls attention to one case in which there was no change in the pulse beat, whether sitting or standing, the usual variation returning as the case improved. The heart symptoms are usually first developed, followed later by the enlargement of the thyroid and the exophthalmos either simultaneously or in succession. The goitre may develop suddenly, has a soft, elastic feel and the size of the enlargement varies greatly. The enlargement of the thyroid and the exophthalmos are originally due to vascular engorgement. The exophthalmos is almost universally bilateral, though it may be confined to one side. The degree of protrusion varies. It may be so excessive that the lids are unable to cover the eye; it may be but transient, confined to one or both eyes, or may be altogether absent. The protrusion is straight forward, causes no interference with the movements of the eye, and the eyes may be pressed back into their normal position, but will become prominent again on relief of the pressure. The exophthalmos gives the patient a frightened, staring appearance. On turning the eyes downward the upper lid either does not follow it at all, or moves along for a certain distance and then remains stationary. This peculiarity, called Graefe's sign, because first noticed by him, is of much diagnostic value, because highly characteristic of this disease, and is rarely if ever found in exophthalmos from any other cause. Other symptoms of this disease are dyspnoea and excessive nervousness. There is usually excessive nervous excitability and tremulousness of the hands. The disposition is often changed. The patient is easily frightened and flushes readily. Epistaxis or hæmorrhage from other parts may occur. Dilatation and pulsation of the retinal arteries has been observed. Anæmia is often present, and in women may be associated with menstrual disturbances; rapid emaciation may occur in some cases. Exposure of the cornea and conjunctiva may result in inflammation or ulceration.

COURSE.—The disease as a rule is very chronic, lasting for several years with frequent temporary improvements and relapses; the symptoms may then gradually subside, though often some enlargement of the thyroid or exophthalmos will remain permanently. Rarely death occurs in this disease from organic disease of the heart

¹ Trans. Amer. Inst. Homœ., 1892.

or exhaustion. The majority of these cases, however, practically recover.

CAUSES.—Basedow's disease is much more often found in women than in men, some authorities claiming that over 85 per cent. of all cases are found in women. The majority of cases occur between the age of puberty and thirty in women, while the average age in men for the appearance of this disease is from thirty to fifty.

This disease has at various times been attributed to a disease of the sympathetic, to rheumatism, etc., and, while its cause has not yet been definitely demonstrated, it will probably be found in some central lesion located near the vaso-motor centre and the origin of the pneumogastric. It is generally brought on by some mental shock, by exhaustion from disease, excessive hæmorrhages, or severe labor.

TREATMENT.—We are compelled to place our chief reliance upon internal remedies in the treatment of this disorder, though there are several measures which may be employed as adjuvants. Galvanization of the sympathetic in the neck has been followed by very good success in many instances, especially when combined with internal medication.

To promote a permanent cure, rest, especially in the country; freedom from all excitement, especially emotional; exercise in open air; a generous diet, and abstinence from all stimulants, are particularly required and should be insisted upon whenever practicable.

Amyl nit.—Cases have been entirely cured by olfaction of this drug alone. The eyes are protruding, staring, and the conjunctival vessels injected, as well as those of the fundus. Especially indicated when there are frequent flushes of the face and head, oppressed respiration, etc.

Badiago.—Exophthalmic goitre, with aching pains in the posterior portion of the eyeballs, aggravated on moving them, accompanied by tremulous palpitation of the heart and glandular swellings. The pulse is rapid and irregular.

Cactus grand.—Cases of exophthalmic goitre have been improved, when prescribed on the heart symptoms.

Ferrum.—Both the iodide and acetate have been followed by favorable results, especially when the disease comes on after the suppression of the menses; protruding eyes, enlargement of the thyroid,

pælpitation of the heart and excessive nervousness. Linnell found good results from the simultaneous use of Iron and Digitalis in one case, after both had been tried separately with no benefit.

Lycopus virg.—Judging from its provings, in which we find a rapid, irregular, intermittent and very compressible pulse, together with a bellows murmur over the heart and large vessels, it should be a valuable remedy in this disorder. Linnell (*loc. cit.*) reports very gratifying results from the use of this remedy.

Spongia.—Exophthalmos, enlargement of the thyroid and palpitation of the heart, great uneasiness and easily frightened, especially at night; stitches in the ball and burning around the eyes, with lachrymation in the light; the eye feels twisted around; chromopsies, especially deep red, and photopsies, even when the eye is closed at night—all indicate this drug, which has proved serviceable.

Nat. mur. and *Baryta c.* are reported to have cured well-marked cases. Other remedies which have been recommended are *Ars.*, *Bell.*, *Brom.*, *Calc.*, *Iod.*, *Phos.*, *Sil.*, *Sulph.* and *Veratrum alb.* and *viride.*

CHAPTER IV.

Affections of the Ocular Muscles.

Anatomy.—The movements of the eyeball are carried on through the action of six voluntary muscles; four of these passing directly from their origin, around the optic foramen, to their insertion in the sclerotic, are called the recti muscles. These muscles are inserted at varying distances, from 6.5 to 8 mm. from the corneal margin, and are distinguished by their relations to the eyeball, as internal, external, superior and inferior rectus. The insertion of the internal rectus is the nearest to the corneal margin, and that of the superior rectus is the most posterior.

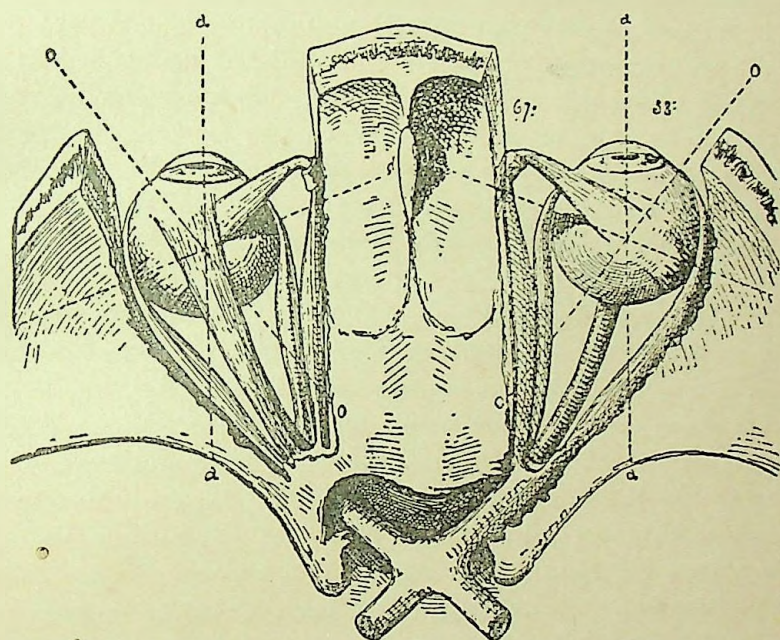
The remaining muscles, from their taking a curved direction around the eyeball, are known as the superior and inferior oblique muscles. The obliquus superior arises at the optic foramen, passes forward along the upper part of the inner orbital wall to a pulley attached at the superior-internal angle at the front of the orbit; from here it is reflected backward and outward between the superior rectus and the eyeball, and is inserted into the sclerotic, 16 to 18 mm. from the corneal margin on the posterior and outer part of the globe, between the superior and external recti.

The obliquus inferior arises from the inner and anterior part of the floor of the orbit and passes outward and backward between the inferior and external recti and the globe, and is inserted near the superior oblique, between the superior and external rectus, 17 to 19 mm. from the corneal margin. The internal, superior and inferior recti and the inferior oblique are supplied by the *third nerve* (oculomotorius), the superior oblique by the *fourth* (patheticus) and the external rectus by the *sixth* (abducens).

The action of all these muscles is to turn the eye around a point, called the *centre of rotation*, situated on the antero-posterior axis of the globe, about 14 mm. behind the anterior surface of the cornea and about 10 mm. in front of the posterior surface of the lens. These six muscles form three pairs of antagonistic muscles. The

axis of rotation of the internal and external recti is vertical, as these muscles turn the globe directly inward and outward. The axis of rotation of the superior and inferior recti is horizontal, although not exactly straight across; it forms an angle of 67° with the visual axis, the nasal end of the line being in front of the temporal. The axis of the superior and inferior oblique is also horizontal, forming an angle of 38° with the visual axis and with the temporal extremity in front of the nasal (Fig. 17).

FIG. 17.



Axes of Ocular Muscles.

Taken singly, the muscles act as follows: The internal rectus draws the cornea directly inward, the external rectus turns the cornea directly outward, the superior rectus turns the cornea upward and slightly inward, the inferior rectus draws the cornea downward and slightly inward, the superior oblique, taking its point of action from the pulley through which it passes, turns the cornea downward and outward and rotates from above downward; the inferior oblique turns the cornea upward and outward and rotates it from below upward.

Each movement of the eye results from the combined action of certain muscles, and there is never a period at which one or the other is entirely inactive, as by its living and elastic tension it aids in guiding a definite movement, even though it does not take part in it. In looking directly upward both the superior rectus and inferior oblique are brought into action, the inclination inward of the former being counteracted by the outward tendency of the latter, and so in all other movements of the eye the action of all the muscles must be considered. Paralysis of any one muscle will cause all movements of the eye to be less sure.

The function of the ocular muscles is to secure single vision with the two eyes by directing both eyes to the point of fixation in such a manner that the image of the object fixed shall fall simultaneously on the macula lutea of each eye. When this is done, all objects lying in the same horopter will form images upon the respective retinae which will be equidistant from the fovea centralis and will, therefore, be appreciated as single, giving what is called binocular vision.

The *horopter*, as described by Müller, is represented by a circle which passes through the centres of rotation of each eye and through the apex of the point of fixation of the visual lines. All objects beyond or inside the horopter will cast images on parts of the retinae not equidistant from the fovea and will create the impression of two objects or double vision; for example, holding two pins in the same line, one eight inches and the other twenty from the eyes, on looking at the nearest pin the other is seen double, and *vice versa*. This double vision of objects not lying in the horopter causes no annoyance, because the mind ignores the impression of objects with which it does not concern itself. The symmetrical position of the physiological centres of the retina is the anatomical ground for binocular vision. If a distant object be fixed with parallel lines of vision, to fix an object at one side which throws its image in both eyes at an equal distance from the macula lutea, both eyes must move through an equal angle; consequently, equal innervation on both sides is necessary for the symmetrical movements of the eyes. All objects are seen single only when retinal images fall on corresponding points of the two retinae. If the visual line of the left eye be directed on an object and there is convergence of the right eye, the

image, which would in the left eye be formed on the fovea in the right would fall upon the retina to the inner side of the fovea and would be projected outward to the right of the object fixed, or homonymous diplopia. If there is divergence of the right eye at the time the visual line of the left eye is directed upon an object, the impression from the object fixed would in the right eye fall upon the retina to the outer side of the fovea and when projected outward would appear to the left of the object fixed, causing crossed or heteronymous diplopia. The displacement of the false image is always in the direction which is opposite to that of the deviation of the eye. When the eye deviates inward, the diplopia is homonymous; when outward, heteronymous; when upward, the false image is below, and, when downward, it is above. The false image is the image of the deviating eye.

Paralysis of Ocular Muscles.—We may have one or more muscles paralyzed, and the cause may be either orbital or intracranial; if the latter, it may be along the course of the nerves or in the brain. Lesions of the spinal cord may cause paralysis through fibres which proceed to the brain.

SYMPTOMS.—The characteristic indications of paralysis are false position of the eye, limitation and irregularity in motion, and double images. As secondary effects, we find dizziness, nausea, headache, incorrect projection of the field of vision and inability to guide the hands or feet aright. If only one eye is involved the inclination is to close it. Another peculiar effect is the attitude which the head assumes to obviate the double images. In paralysis the secondary deviation is always greater than the primary, while in concomitant strabismus the primary and secondary deviations are equal. The *primary deviation* is the deviation of the affected eye when the healthy eye fixes, while the *secondary deviation* is the deviation of the good eye when the affected eye fixes. If recovery does not occur, there follows secondary contraction of the opposing or associated muscle. For example, in paralysis of the right external rectus, from diminished resistance, the right internal rectus will turn the eye unduly inward, and the left internal rectus will also undergo contraction, and, if the right eye looks directly forward, the left will consequently squint inward. This fact in old cases often makes the diagnosis as to which muscle was first affected very difficult.

CAUSES.—The effective causes are localized periostitis, inflammations of the sheath of the nerves, basilar meningitis, hæmorrhages, tumors, degeneration of nerve structure or of the cerebral nerve centres, injuries, diphtheria, rheumatism, draught of air, etc. The majority of cases of ocular paralysis occur in syphilitic subjects and are most frequently of orbital origin. Paralysis may also be the first premonition of sclerosis of the spinal cord. Both eyes may be affected, and the cause then is intracranial and generally basilar. Paralysis may occur at any age and may be temporary or permanent.

DIAGNOSIS.—Theoretically the examination of the double images should render the diagnosis easy and accurate, but in practice the inability of many patients to appreciate and describe the relations of the images, together with secondary contractions and involuntary compensations, makes it often-times extremely difficult to attain an accurate chart of the double images. In many recent cases we can tell what muscle is affected without an analysis of the double images. The movement of the eye in the direction of action of the paralyzed muscle is less than normal, and is increased in the opposite direction; its movements are irregular and jerky. The inclination of the head, when present, will be such as to favor the lamed muscle and will be in its line of action. When, however, there is any uncertainty as to the muscle affected, the examination of the double images should always be made. The double images are best detected by having one eye covered with a red glass, and the patient to describe the position and inclination of the two lights (one red and the other white) seen when looking at the flame of a candle eight to ten feet away. The images are to be noted in the different parts of the field as follows: First on the level with the patient's eyes directly in front, then to the right and left, and also at about three feet above and below this level at the centre, right and left. The use of the red glass aids the patient in detecting the two images and at the same time informs the physician to which eye each belongs.

Paralysis, External Rectus.—Paralysis of the external rectus muscle causes a limitation in the outward movement of the eye. In complete paralysis the eye can only be turned but little beyond the median line, while in incomplete it may often go to nearly the normal limit, but with an irregular, jerking motion. The deviation of

the affected eye is inward; the diplopia is homonymous; the double images are on the same level and parallel, and the distance between the images increases on looking toward the affected side. The line which separates that part of the field in which there is single vision from that in which it is double is not exactly vertical, but is inclined obliquely, the diplopia extending further toward the healthy side below than above.

Paralysis, Superior Oblique.—The restriction in motion is downward and outward, and in complete paralysis of this muscle the motion downward is diminished. The deviation of the affected eye is upward and inward, and the image of the affected eye is inclined inward at the top, owing to the torsion action of this muscle on the eyeball. The obliquity of the false image is increased on looking toward the affected side. The diplopia is homonymous and present only in the lower part of the field. The image of the affected eye is lower than that of the healthy eye, and the difference in height between the two images is increased on looking downward and toward the healthy side. The image of the affected eye generally appears nearer to the patient than that of the healthy eye. The direction of the healthy eye, when the diseased eye fixes, is downward and inward. The line of demarcation between the true and false images is slightly oblique to the horizontal, the end corresponding to the affected side being lower. The face is inclined downward and to the healthy side.

Paralysis, Internal Rectus.—In this, the restricted movement is inward, the affected eye is outward, the diplopia is heteronymous, the double images are parallel and of the same height, the distance between them increases on looking toward the healthy side and on looking upward. The line of demarcation between the true and false images is oblique to the vertical, the diplopia extending further toward the healthy side above than below. The face is turned in the direction of the affected eye.

Paralysis, Superior Rectus.—The restricted motion is upward and slightly inward, the deviation of the affected eye is downward and on looking up is downward and outward; diplopia is slightly crossed and in the upper part of the field the false image is higher than the true, its upper end is inclined to the healthy side; the difference in height between the two images increases on looking up-

ward and the obliquity increases on looking to the healthy side. The line of demarcation is inclined to the horizontal, the diplopia extending lower toward the affected side. The face is directed slightly upward.

Paralysis, Inferior Rectus.—In this we find the restricted movement is downward, the deviation of the affected eye is upward and outward, the diplopia is slightly crossed, especially in the lower part of the field; the false images are lower and inclined toward the affected side; the difference in height increases on looking downward and to the affected side, and the obliquity increases on looking toward the healthy side. The line of demarcation is inclined to the horizontal, the diplopia extending higher toward the affected side. The face is inclined downward and slightly toward the affected side.

Paralysis, Inferior Oblique.—The restricted movement is upward and outward, the deviation of the affected eye is downward and inward, the diplopia is slightly homonymous and especially in the upper part of the field the image of the affected eye is higher and inclined outward, the difference in height increases on looking upward and inward and the obliquity increases on looking to the affected side. The line of demarcation is inclined to the horizontal, the diplopia extending lower toward the affected side. The face is directed upward and slightly toward the sound side.

Complete Paralysis of the Third Nerve.—In this there is ptosis, slight exophthalmos, pupil moderately dilated, accommodation paralyzed; movements are restricted in all directions excepting directly outward; the deviation of the affected eye is outward; there is heteronymous diplopia, the false image is oblique and inclined toward the healthy side, it also appears higher than the true image and nearer to the patient. The distance between the images increases on looking toward the sound side, and the difference in height increases on looking upward. The face is inclined toward the sound side and slightly upward.

TREATMENT.—The treatment varies according to the nature of the cause, which should always receive due consideration in the selection of a drug. Our chief reliance must be on internal medication.

Prismatic glasses to which we frequently resort, may be used for two purposes: 1. To relieve the annoying diplopia by giving that

prism which neutralizes the double vision. 2. For the purpose of exercising the paralyzed muscle by using a weak prism, which nearly fuses the double images, when by the exercise of the will they may be brought together; by daily using weaker and weaker prisms much improvement can be made in restoring the muscle power.

Both faradization and galvanization have proved valuable aids in the cure of these disorders, either alone or in connection with the appropriate remedy.

Forcible movements of the eye made by seizing the conjunctiva over the insertion of the paralyzed muscle with the fixation forceps and strongly turning the eye in the direction of action of the weakened muscle and then in the directly opposite direction has proved of very great value in my hands. Under Cocaine this causes no pain.

As a last resort, after the condition has existed sufficiently long to render all hopes of improvement by other means impossible, careful tenotomy of the opposing muscle may be performed, with or without advancement of the paralyzed muscle, according to the degree of deviation.

Aconite.—Paresis from exposure to a draught of cold air.

Argentum nit.—For weakness of the ciliary muscle or even paralysis of the accommodation, manifest advantage has been derived.

Arnica.—Paralysis of the muscles resulting from a blow or injury.

Causticum.—Paralysis of the muscles resulting from *exposure to cold*. It has been especially successful in paralysis of the sphincter pupillæ (mydriasis), of the ciliary muscle, levator palpebræ superioris (ptosis), orbicularis and external rectus. Its action is not found confined to any one nerve, but is useful in paralysis of any of the ocular muscles, if the particular cause and general indications are present.

Chelidonium.—Paresis of the right external rectus. Distant objects are blurred, and on looking steadily two are seen. Pain in the eye on looking up.

Cuprum acet.—Insufficiency or paralysis of the external rectus muscle.

Euphrasia.—Paralysis of the muscles, particularly of the third pair of nerves, caused from exposure to cold and wet; especially if catarrhal symptoms of the conjunctiva, blurring of the eyes relieved by winking, etc., are present.

Gelsemium.—A valuable remedy in all forms of paralysis of the ocular muscles, especially of the external rectus. Paresis from diphtheria, or associated with paralysis of the muscles of the throat.

Kali iodata.—The iodide of potassium is more commonly indicated than any other drug in *paralysis of the muscles, of syphilitic origin*. Appreciable doses are usually employed.

Merc. iod. flav.—Paralysis of the third pair, especially if syphilitic in origin.

Nux. vom.—Paresis or paralysis of the ocular muscles, particularly if caused or made worse by the use of stimulants or tobacco.

Paris quad.—Paralysis of the iris and ciliary muscle, *with pain drawing from the eye to the back of the head; or pain as if the eyes were pulled into the head*. Eyes sensitive to touch.

Phosphorus.—Paralysis of the muscles caused from or accompanied by spermatorrhœa or sexual abuse.

Rhus tox.—A remedy often indicated in paralysis of the ocular muscles resulting from *rheumatism or exposure in cold wet weather and getting the feet wet*. Causticum is very similar in its action, though it is more especially adapted to those cases resulting from exposure to cold dry weather.

Senega.—Want of power of the superior rectus or superior oblique, in which the *diplopia is relieved by bending the head backward*. The other muscles may be complicated in the trouble.

Spigelia.—When associated with *sharp, stabbing pain* through the eye and head.

Alumina, Aurum, Conium, Hyocyamus and Sulphur have also been used with advantage. Other remedies may be called for by general indications.

Strabismus or Squint is inability to bring the visual axes of both eyes to meet at a certain point, or when the point fixed casts its image only on the macula lutea of one eye, while in the other it falls on some eccentric part of the retina. If the squinting eye deviates inward, it is called strabismus convergens; if outward, divergens; if upward, sursum vergens, and if downward, deorsum vergens. The squint in concomitant strabismus differs from that of paralysis in the following points: The primary and secondary deviation are equal in strabismus, while in paralytic squint the secondary deviation is greater than the primary. In strabismus the extent of the move-

ment in the two eyes is normal and equal, while in paralysis the mobility of the eye decreases in the direction of action of the paralyzed muscle. Diplopia is generally absent in strabismus; but, when present, is found in all parts of the field, and in strabismus there is no particular inclination of the head.

Strabismus is usually *mono-lateral*, that is a faulty position of one eye; or it may be *alternating*, when the patient will be able to fixate objects with either eye separately, and when doing so the other eye becomes the squinting one. The strabismus may also be *intermittent* or *constant*. Strabismus is not observed after death, during deep sleep or in deep narcosis.

Concomitant squint is very seldom accompanied by diplopia. This is believed to be due to a suppression of the retinal image in the squinting eye, for, being that of some object with which the mind is not interested, it is simply ignored at will.

Binocular vision, according to von Graefe, is absent in about 90 per cent. of the cases of strabismus, that it can be produced by prisms in about 25 per cent., and exists after operation in about 50 per cent. Its presence is proved at once by the existence of binocular diplopia, and when not present it is determined by having the patient look at the flame of a candle at the distance of six or eight feet through a prism placed before one eye, when either diplopia or a corrective squint will occur, if the prism is not too strong, for the patient will endeavor to overcome the prism by squinting and fusing the images, or if neither of these effects occur, absence of binocular vision is proven. Binocular vision is frequently only lost over certain portions of the retina.

Apparent Strabismus is the condition where there is a deviation of the optic axes, and yet both eyes fixate and neither moves when the other is closed. This is due to the relation between the optic axis and the visual line. If the optic axis lies to the outer side of the visual line, we have an apparent divergent squint, and, if to the inner side, may have the reverse—an apparent convergent squint.

Strabismus Convergens is the most common form of squint met with, and usually develops between the second and seventh years of life. Diplopia is generally present in all cases which develop later than childhood.

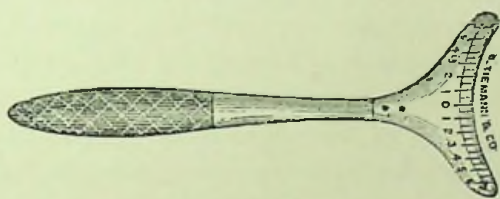
CAUSES.—In a great majority of cases it is found to exist in con-

nection with hypermetropia. Donders first called attention to the relation of hypermetropia to convergent strabismus, and showed it to be present in about 75 per cent. of the cases; other authorities since then have placed it as high as 85 per cent. It has also been estimated that about 16 per cent. of all hypermetropes squint. It is usually the median or slight degrees of hypermetropia that most often induces strabismus. Hypermetropia causes strabismus on account of the normal or physiological relation between convergence and accommodation; that is, with an increase of convergence the relative range of accommodation approaches the eye. All hypermetropic eyes require a strong tension of the accommodation for distinct vision, and hence to aid the accommodation they are inclined to converge too much. The reason that only a few of all hypermetropes squint, and that those are mostly of the slighter degrees of hypermetropia, is because, that as a result of too strong continued convergence the hypermetrope soon learns to give up binocular vision, as he finds he can secure a more distinct image, with less strain on the accommodation, by monocular fixation, and hence allows the poorer eye to squint; while in the high degrees of hypermetropia there will be but slight cause for sacrificing binocular vision when, in spite of too strong convergence, distinct retinal images cannot be obtained. In the medium and lower grades of hypermetropia there does exist the inclination to exchange binocular vision for monocular fixation when any cause makes binocular fixation less valuable, as in differences in refraction, astigmatism, corneal opacities, etc., affecting only one eye. It has also been found by Schweigger and others that the non-squinting eye does not possess full acuity of vision, and this induces squint by an effort to secure by convergence as large an image as possible. Another contributing factor in the causation of convergent squint is an insufficiency of the external recti muscles, which arises from the fact that in hyperopia there is a deviation inward of the visual lines, and the constant effort necessary on the part of the external recti to maintain parallelism of the visual lines finally results in insufficiency, which favors strabismus convergens. As other predisposing causes we find constantly working in poor light, excessive use of the eyes for near work, weakened ciliary muscle and constant looking to one side. Convergent squint may also be found in myopic eyes, due to a preponderance of the internal recti. Macula of the

cornea also cause squint from confusion of the retinal images, which cannot be suppressed while falling upon identical points of the two retinae; hence the eye turns in order to throw the image upon some eccentric part of the retina where it may be suppressed, and the eye is more apt to turn in on account of the greater strength of the internal rectus.

In convergent strabismus amblyopia is usually present in the squinting eye. The amblyopia is considered by some to be a consequence of the squint and by others as the cause. It is probable that both views are correct, and that in some cases it is the cause of the squint, while in others the amblyopia results from the squint. It is easy to understand that the squinting eye will become amblyopic from long disuse, and in these cases, where it is a consequence of the squint, it is called *amblyopia ex anopsia*; in other cases,

FIG. 18.



Lawrence's Strabismometer.

where there may be a difference in the degree of the hypermetropia in the two eyes, the child would naturally use the best eye for vision and allow the poorer eye to turn, in order to more readily suppress the indistinct image. Hence we must conclude that a slight pre-existing amblyopia in one eye, associated with hypermetropia, will have a tendency to cause convergence, and after the squint has become established the amblyopia may increase from disuse.

Strabismus convergens is by far the most common form of squint met with, and is, in the majority of cases, a stationary monolateral squint. The degree of the strabismus can be obtained sufficiently accurate for all practical purposes by means of the *strabismometer*—an ivory scale shaped to fit the lower lid and graduated in millimetres on its free edge (Fig. 18). It is used by covering the good eye and fixing with the squinting eye, the 0 on the scale is then placed directly under the centre of the pupil, the good eye is then uncov-

ered and the squinting eye allowed to resume its ordinary position; the number then exactly under the centre of the pupil gives the linear measure of the deviating eye in millimetres.

Strabismus Divergens is much less frequently seen than convergent squint and generally develops later, after childhood has passed. It is frequently in the beginning periodic, but usually becomes permanent later; it may also be alternating; generally, however, it is monolateral and concomitant, in that the deviation of the affected eye, or primary deviation, will be equal to the deviation of the good eye, or secondary deviation. Diplopia is usually present at the commencement of the affection, especially when periodic, but gradually disappears as the condition advances.

CAUSES.—While convergent strabismus is usually associated with hypermetropia, divergence is, on the other hand, most often associated with myopia. In myopic eyes the antero-posterior axis of the globe is much increased, and the movements of the eye in the horizontal plane are diminished.

The shape of the myopic eye causes a greater tension and resistance on the part of the external rectus, because from its position it comes in contact with the eyeball more than does any of the other muscles of the eye. A greater resistance and strength in the external rectus causes a relative insufficiency of the internal, which leads to divergence. At first convergence is possible, but the necessary tension cannot long be sustained and the eye diverges, when we will have, in place of accommodative movements, only associated movements inward, until finally the insufficiency of the interni become so great that in associated movement inward the squinting eye will fall behind the other.

In some cases where there is myopia of one eye and emmetropia or hypermetropia of the other a similar process ensues: the myopic eye will then usually be used for near vision, because it is impossible to secure binocular vision for reading, and as the myopic eye can be used without any exertion of the accommodation, it is almost invariably used, while the other eye is used for distant vision. The absence of accommodation is sufficient to give the emmetropic eye a relatively divergent position, while the associated, instead of the accommodative, movement results in a preponderance of the externi. Macula of the cornea may also cause divergence as well as con-

vergence, if in such a location that suppression of the indistinct image can be more readily attained by turning the eye outward instead of inward.

Strabismus Sursum and Deorsum Vergens are usually seen as a complication of lateral deviation and disappear when the lateral deviation is relieved. A concomitant vertical deviation, however, may occur alone, and, when it does is increased, if an upward deviation, on looking inward, and if downward the squint is the greatest on looking outward. Diplopia is usually present in cases of vertical deviation.

TREATMENT.—This should first be directed toward preventing the development of the squint. Whenever a tendency to squint is noticed, the child should be prevented from reading, writing and all near use of the eyes as much as possible. As soon as the child is old enough to wear glasses the refractive error should be corrected. My rule is to wait until they are about five years old, and then to prescribe a glass of about a .25 to a .50 D less than the total refractive error as shown by the ophthalmoscope, to be worn constantly. The use of atropine to paralyze the accommodation, and thus preventing near vision, if continued for several weeks, will often greatly benefit an inclination to convergent squint. If the case is one of permanent strabismus, and an early operation is not desired, the *good* eye should be covered for a short period daily and the child compelled to use the affected eye. In this way the vision of the squinting eye will be retained. The fact must also be borne in mind in the treatment of convergent squint that there is a tendency in some cases to a gradual disappearance of the squint as the child grows older, and, when this does occur, it is usually not earlier than the tenth year and often much later.

The use of remedies has in the early stages of many cases relieved the tendency to permanent strabismus.

Cicuta vir.—Indicated in strabismus convergens occurring in children, particularly if spasmodic in nature, or caused from convulsions, to which the child is subject.

Jaborandi.—Strabismus convergens, periodic and resulting from spasm of the internal recti; also for the return of squint after operation.

If helminthiasis has been the cause, Cina, Cyclamen or Spigelia

may be required. If due to spasms, convulsions, or any intracranial disorders, Agar., Bell., Eserine, Gels., Hyos., Nux or Stram. would be first suggested to our minds.

Calc. or Chin. sulph. may be indicated.

In all cases the cause of the difficulty must be determined, if possible, for this, in connection with the general condition of the patient, will govern us in the selection of the remedy.

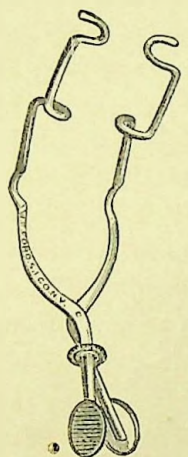
Operative Treatment for strabismus may be by either tenotomy of the contracted muscle, advancement of the weak or opposing muscle, or by both combined. The operation for the relief of squint was first suggested by Taylor in the seventeenth century; his method, however, was unsuccessful, and, consequently, abandoned. In 1839, Dieffenbach made the first successful operation for squint; the method practiced by him was to divide the belly of the muscle instead of its tendon, thereby greatly impairing the action of the muscle and often causing the eye to turn in the opposite direction. At a later period von Graefe placed the operation upon a scientific basis by suggesting the division of the tendon instead of the body of the muscle, and his operation, with some slight modifications, is the one in more common use at present. As to the time when the operation should be made, my preference is to wait until the child is at least seven years of age, unless it is a very pronounced permanent squint, when a tenotomy, aiming to correct only a portion of the squint, may be made at a much earlier age.

As to the advisability of operating upon one or both eyes at the same sitting, authorities seem to be about equally divided. It is, however, always my rule to operate upon but one eye at a time, taking at first the eye with the greatest deviation and making a free division of the muscle, and a few weeks later making a second operation upon the other eye, if needed. Previous to operating we should determine the cause of the squint, the vision, the relative power of the muscles, and the degree of the deviation in each eye. The *technique* of the operation is the same, irrespective of the muscle operated upon.

Tenotomy of the Internal Rectus.—As this operation is quite painful, an anæsthetic should be used. Four to six instillations of a 4 per cent. solution of cocaine at intervals of about five minutes renders the operation painless, and is to be preferred to a general

anæsthetic because we are better able to judge of the effect accomplished. In young or excessively nervous subjects, ether or chloroform may have to be used. The instruments required are a speculum, fixation forceps, curved scissors and strabismus hook (Figs. 19 to 22). The lids should be widely separated by the speculum; the conjunctiva and subconjunctival tissue directly over the inser-

FIG. 19.




Mittendorf's Speculum.

FIG. 20.




Fixation Forceps.

FIG. 21.



Strabismus Hooks.

FIG. 22.



Blunt-Pointed curved Strabismus Scissors.

tion of the muscle to be divided is seized with the fixation forceps, and with a pair of curved, blunt-pointed scissors, make a vertical cut down to the muscle, which is then separated from the subconjunctival tissue by dissecting backward with the scissors as far as it is desired to have the muscle slide for its re-attachment. The

strabismus hook is now to be introduced behind the muscle at its lower edge, and, with the point pressed against the eyeball, turned upward beneath the tendon, which is then to be divided close to its insertion. The hook should then be inserted again to see if all the lateral expansions of the tendon have been divided; but too frequent and extensive excursions of the hook should be avoided, as it tends to increase the inflammatory action. Care must be exercised that too extensive dissections of Tenon's capsule, both above and below the muscle, are not made, as the capsule of Tenon serves as a secondary attachment for the ocular muscles, and, if too freely separated from the sclerotic, the effect of the operation may be too greatly increased and the power of the muscle so much affected that it will have little or no action upon the movements of the eye. The sinking of the caruncle is also the result of a too free dissection of Tenon's capsule.

The use of the suture to limit the effect of the operation, if too extensive, may be necessary; it is introduced through the conjunctiva at the margin of the cornea and then through the conjunctiva over the muscle. In convergent strabismus, with good vision in both eyes, the patient should be able after the operation to fixate and hold the eyes on an object at a distance of about eight inches. If the vision is poor, or the muscles weak, a convergence at twelve inches is sufficient. Diplopia, with the images near together for two or three days after the operation, is not unfavorable, as it is usually due to the inflammatory action and disappears as the inflammation subsides.

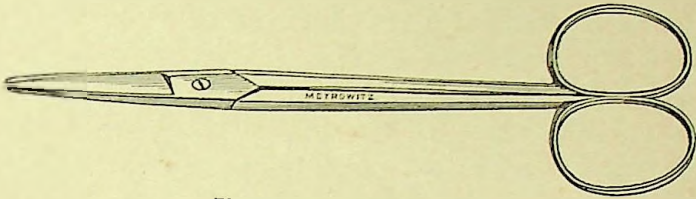
The effect of an operation for convergent squint may be increased, if desired, by a strong suture passed through a fold of the conjunctiva at the outer side near to the cornea, and then carried through the skin at the external canthus, one end above and the other below, about one-eighth of an inch apart, and then tied; or they may be fastened to the skin by strapping. The eye is thus held in the proper position for two days, when the muscle should have become reattached and the suture removed.

Subconjunctival Tenotomy is preferred by many to the operation just described. This is made by snipping the conjunctiva along the lower edge of the insertion of the muscle with blunt straight scissors (Fig. 23). The subconjunctival tissues are then separated over the

muscle, the strabismus hook is then inserted, catching up the muscle on the hook. The scissors are now introduced, one blade in front and the other behind the muscle, which is held on the stretch by the hook, and it is divided subconjunctivally.

Advancement of the Muscle is designed to increase the power of a muscle by shortening it. This operation is useful in cases of ex-

FIG. 23.

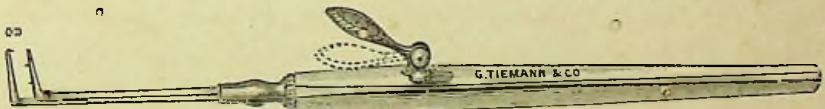


Blunt-pointed Straight Scissors.

treme divergence and especially in those cases where the operation for convergent strabismus has resulted in a deviation in the opposite direction, and hence the internal rectus is the muscle most frequently advanced. A tenotomy of the opposing muscle is usually necessary and is made by some at the same time and by others later.

Critchett's Operation, somewhat modified, has proven of the most value in our hands, and hence is preferred. The patient in this operation should be etherized, the lids separated by the speculum and a vertical incision three-fourths of an inch in length and about one-tenth of an inch from the corneal border is then made through the conjunctiva. The conjunctiva and subconjunctival tissues are now

FIG. 24.

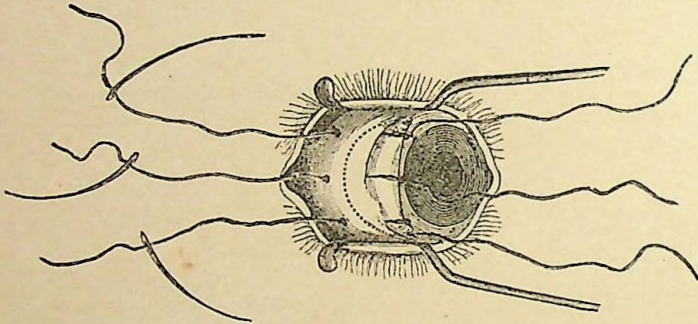


De Wecker's Double Strabismus Hook.

dissected back to the insertion of the muscle, which is then divided close to its insertion. The muscle and tissues overlaying it are then held together *en masse* with De Wecker's double strabismus hook (Fig. 24). Three sutures with a needle at each end are used and are now introduced from within outward through the flap of the conjunctiva at the margin of the cornea, one being placed opposite the

horizontal meridian of the cornea and the others one above and one below. A fourth suture may also be employed, running vertically through the flap of the conjunctiva at the corneal border, to strengthen and prevent the other sutures from tearing out. The needles at the other end of the sutures are next passed from within outward, the first through the middle of the muscle and the others through its upper and lower borders (Fig. 25). These sutures are passed through the muscle, well back from its extremity, and through the conjunctiva. A semilunar fold of the conjunctiva, subconjunctival tissue and muscle is then cut away, varying in amount according to the effect desired. This done, the muscle is advanced by tying the three sutures, the middle suture being first tied. As the greatest

FIG. 25.



Operation for Advancement of Internal Rectus.

strain falls upon the middle suture, it should be made of heavier thread than the others or used double. This operation differs from Critchett's in two particulars—first the reinforcing vertical suture, and secondly in that a portion of the end of the muscle is cut away.

The After-Treatment.—Simple tenotomy creates no serious reaction, and the patients are allowed to return to their homes and to use their eyes as much as is desired. Bathing the eyes in cold water or a solution of calendula gives some relief of the soreness experienced for the first day or two. No bandage should be allowed (except while returning home from the operation), for from protection of the eyes there is not that incentive to parallelism of the visual axes which occurs when the eyes are being used. The advancement of the muscle is accompanied by considerable pain and

swelling, which is usually controlled by keeping the patient in bed with both eyes bandaged, the ice bag applied locally and aconite given internally.

Nystagmus (*Oscillation of the Eyeballs*).—These movements are involuntary, exceedingly rapid, almost rhythmical and affect both eyes at the same time. The mobility of the eye is not otherwise impaired. The oscillation is generally in the horizontal direction, but may be vertical or in the direction of a single muscle. It is usually permanent, but may be periodic and in some positions of the eye may have a point of rest. Nystagmus is increased in near vision and from excitement; in some cases it is complicated by similar movements of the head, but in an opposite direction. The sight is always impaired, but objects are seen as they are by the patient.

CAUSES.—Generally occurs in early childhood and is principally the result of amblyopia, as in congenital opacities of the cornea, congenital cataract, or total blindness.

The nystagmus of miners is a peculiar form of this affection, which first comes on while working in the darkness of the mines, and, as it progresses, lasts through the day, but increases as twilight comes on and has often associated with it night-blindness. These patients are often made dizzy and greatly annoyed by the apparent movement of objects. This form of nystagmus is due to the work done in an insufficient light and with the eyes turned in an unnatural position.

PROGNOSIS.—When once developed, it generally remains, although it may diminish somewhat in advanced life.

TREATMENT.—If strabismus coexists with nystagmus, tenotomy of the contracted muscle should be made. If there is any anomaly of refraction, it must be corrected with glasses.

Agaricus.—Very useful in all spasmodic affections of the muscles of the eye, especially if associated with *spasm of the lids*, or general chorea. *Twitchings of the lids* varying from frequent winking to spasmodic closure of them. *Twitchings of the eyeballs* with various sensations in and around them, chiefly pressing and aching. Eye-ball sensitive to touch. *The spasmodic movements are absent during sleep, but return on waking* and may be transiently relieved by washing in cold water.

Belladonna.—If accompanied by headache and hyperæsthesia of the senses.

Hyoscyamus.—Spasmodic action of the eyeballs.

Ignatia.—Morbid nictitation and spasmodic affections occurring in nervous, hysterical women.

Jaborandi, Physostig., Nux, Puls. and Sulph. have also been used with benefit, as may any of that class of remedies denominated our antispasmodics.

Muscular Asthenopia.—This term is applied in a general way to various tired and strained sensations about the eyes and head resulting from insufficiency of some of the extrinsic muscles of the eye. Special attention was first directed to this subject by von Graefe, which until within a few years had received but meagre attention and had been applied especially to an insufficiency of the internal recti muscles. Within the last five or ten years, however, hardly a number of our current ophthalmological literature has appeared without containing more or less reference to some of the muscular anomalies, and, while vast strides have been made in our knowledge of these defects and their treatment, still any conscientious worker in this field must realize that but the first steps have been taken, and what are now generally considered as valuable facts may five years hence seem truly ridiculous. To Dr. George T. Stevens is due the credit of having been the one to first turn the present attention of ophthalmologists in this direction, and, while we cannot accept in full his methods of treatment, must acknowledge that by his efforts researches in this line have been greatly advanced and stimulated. An exhaustive consideration of the insufficiencies of the ocular muscles is of course impossible within the limits of an ordinary text-book, and it is for this reason presumably that none of the more recent works upon the eye give this subject the attention that it seems it should receive. Another reason is possibly that, owing to the rapid advances in this direction, the knowledge that one may have to retract to-morrow what is written to-day renders one advisedly cautious in the handling of this subject, but the important relation that exists between defects of the ocular muscles and various reflex disorders makes it imperative that the subject be considered to the extent of our present knowledge.

It is a well recognized fact that defects of the ocular muscles can and do cause various reflex disorders, such as vertigo, general nervous excitements, gastric derangements, neuralgic pains of the back,

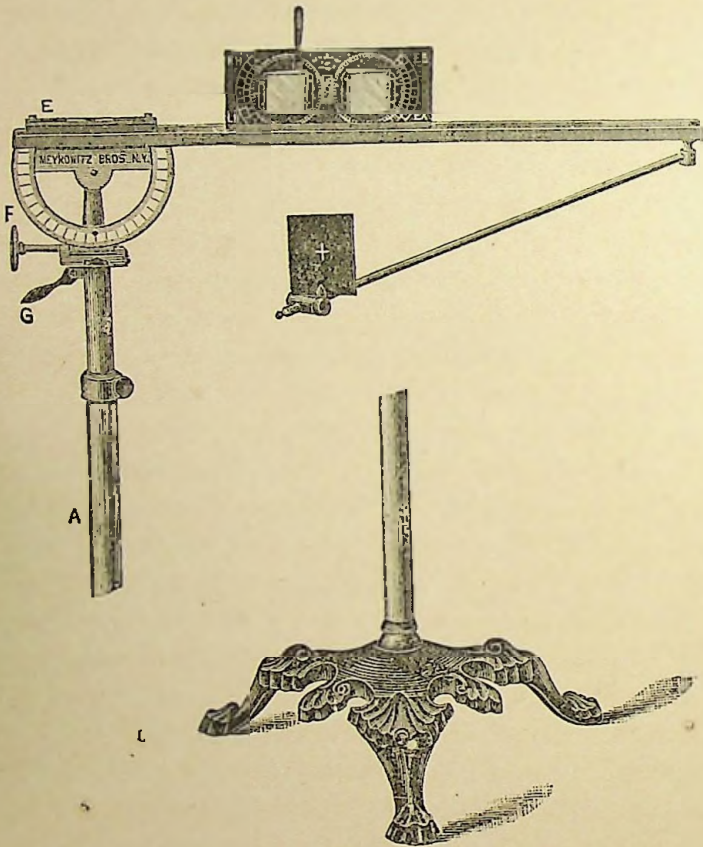
head, etc. On the other hand, many asthenopic symptoms of the eye may be the effect of some remote disorder such as uterine disturbances, etc. In treating of muscular asthenopia frequent reference will be made to the writings of Dr. Stevens as found in the *Archives of Ophthalmology*, vols. xvi., xvii. and xviii., and his work on *Functional Nervous Diseases*. We shall also adopt the terms suggested by him as more accurately describing the various forms of insufficiency, viz.: *Orthophoria*: A tending of the visual lines to parallelism. *Heterophoria*: A tending of these lines in some other way. *Esophoria*: A tending of the visual lines inward. *Exophoria*: A tending of the lines outward. *Hyperphoria* (right or left): A tending of the right or left visual line in a direction above its fellow; this term does not imply that the line referred to is too high, but that it is higher than the other, without indicating which may be at fault. *Hyperesophoria*: A tending upward and inward. *Hyperexophoria*: A tending upward and outward. The designation "right" or "left" must be applied to these two terms.

The examination for heterophoria may be practiced by a number of methods.

Stevens' Phorometer (Fig. 26). In this test the patient, while holding the head erect, looks at a lighted candle at the distance of twenty feet, which should be nearly upon a level with the eyes. Then with the refractive error, if any, corrected, prisms of sufficient power to produce diplopia are placed with the base inward before each eye. The images thus produced are homonymous, and, if seen exactly on the same horizontal plane, there is no tendency to a vertical deviation. If, however, one image is higher than that of the other, there is absence of the vertical equilibrium, or *hyperphoria*. If the left image is higher than the right, it indicates that the visual line of the left eye is lower than that of the right, or that the visual line of the right eye has a tendency to rise above that of the left; this is *right hyperphoria*. If the right image is seen above that of the left, it is known as *left hyperphoria*. The degree of the deviation is shown by the prism, which, when placed with the base up or down before one eye, brings the two images exactly on the same horizontal plane. Diplopia is again induced by placing a prism with the base up or down before one eye, and, if the two images are now exactly vertical, no deviation in the horizontal

plane is shown. A prism of 7° is usually sufficient to cause vertical diplopia when placed with the base up or down before one eye. Say, with the base down before the right eye, if, now, the upper image appears more at the right than the lower, it indicates *esophoria*; but, if the upper image is to the left of the lower, *exophoria* is shown. The degree of the horizontal deviation is shown by the

FIG. 26.



Stevens' Phorometer.

degree of the prism which, when placed with the base in or out before either eye, brings and holds the images in a vertical line.

Examination should then be made in the same way at the distance of eighteen inches to determine the condition of the muscles in accommodation, and for this purpose a small white cross on a black background is used in the Stevens' phorometer.

The Prentice Phorometer is claimed by the inventor to be an improvement over that devised by Dr. Stevens, in that it detects the latent as well as the manifest heterophoria. It is a recognized fact that in many cases there is a latent insufficiency that can often only be determined after long or frequently repeated examinations. The Prentice instrument will show heterophoria in cases where Stevens' will show none, and a higher degree of trouble in the majority of those cases showing some heterophoria by Stevens' test.

In the examination with the Prentice phorometer a chart is used instead of the flame of a candle. The chart is made of card-board about two feet in length, divided in the centre by an arrow, on either side of which are five black lines two inches apart and numbered on one side of the arrow in black and the other in red numbers. In testing, the chart is fastened to the wall twenty feet away; for hyperphoria it is placed vertically, and by prisms, the same as in Stevens' test, with the base toward the nose, the subject is made to see two charts; if the arrow of one chart points directly to the arrow of the other, there is no manifest hyperphoria. A prism of three degrees, base down, is then placed before one eye, which raises the chart seen by that eye three degrees above its fellow, and the arrow of that chart will then point to one of the numbers above the arrow on the other. Now, by means of a switch, the three-degree prism, base down, is made to slide before the other eye, which lowers the chart to the same distance below its fellow, and if there is no hyperphoria the arrow will point to the same number below the arrow that it did above. The principle of the examination for esophoria or exophoria is, of course, the same.

The inventor claims by this method to do away with the unconscious or involuntary effort that is made to hold the two images on the same horizontal plane by the Stevens instrument. One objection to the Prentice phorometer is, that it has not the arm for testing the muscular equilibrium in accommodation, which we believe should always be done. Further from our experience with this phorometer, used in the manner advised by Dr. Prentice to bring out, or develop any latent heterophoria, it will, we believe, show in many cases, a greater deviation than really exists.

The Maddox Test is made by using a small glass rod, which may be mounted or held in the hand, and, for hyperphoria, is held exactly

vertical before one eye and a colored glass before the other. When looking at the lighted candle, a long horizontal line of light is seen by the eye in front of which the rod is held, while the other eye sees the natural light. Now, if the line of light passes exactly through the centre of the flame, as seen by the other eye, there is no hyperphoria present; but if above or below, then hyperphoria is shown, and the degree is represented by the prism which causes the line of light to pass directly through the centre of the flame. The rod is now turned horizontally in front of one eye, causing a vertical line of light which, if passing directly through the flame, shows orthophoria of the lateral muscles; if the line is to the same side as the eye before which the rod is held, it indicates esophoria; if to the opposite side, exophoria, and the prism which brings the vertical line of light directly through the flame indicates the degree of esophoria or exophoria. This we believe to be the most reliable test for muscular insufficiency at present devised.

The Savage Test for Insufficiency of the Oblique Muscles.—Occasionally cases of undoubted eye-strain are met with which are not relieved even after the most careful correction of the refractive error or of any of the already named forms of heterophoria. These cases may be due to an insufficiency of one of the oblique muscles, a condition easily detected by Savage's test; but if found, there has been at present no satisfactory suggestion offered as to treatment.

In testing, a double prism of six degrees each, base to base, is held with its axis vertical before one eye and the patient requested to look at a horizontal line on a card eighteen inches away. With the other eye covered, the line appears to be two, each parallel with the other; on uncovering the other eye, a third line is seen between the other two, with which it should be exactly parallel. If there is any loss of balance between the oblique muscles, this test will show a lack of parallelism of the middle line with the other two, the right end of the middle line will point to the lower line and the left end to the upper line, or *vice versa*.

With the double prism before the right eye, if the middle line is seen nearer the bottom, there is left hyperphoria; if it extends farther to the right than the other two, and not so far to the left, exophoria is present; or, if reversed, extending farther to the left and not so far to the right, esophoria is shown. If the right ends of the

middle and lower lines converge and the left ends diverge, insufficiency of the superior oblique of the left eye is shown.

Hyperphoria.—By this is meant the condition of the ocular muscles in which, with a minimum of tension, a deviation of one visual line above the other would result.

SYMPTOMS.—This condition is apt to cause far greater disturbance than any other variety of heterophoria. A greater or less degree of amblyopia is, according to Stevens, found in a large per cent. of the cases of hyperphoria, and is by him attributed to suppression of images, owing to the inability of the muscles which raise the eye up or down (and which in their most perfect condition have but a very limited action as compared with the other ocular muscles) to maintain the effort required to keep the two eyes on the same horizontal plane. Profuse lachrymation is sometimes found and relieved by the correction of the hyperphoria. Spasmodic closure of the lids and involuntary contractions of the muscles of the face may be present. The head is apt to be carried toward the shoulder. Constitutional effects, such as neuralgia, headache, persistent nausea, pain in the back, vertigo and neurasthenia have undoubtedly been caused, and relieved by the correction of an existing hyperphoria. Examination as to the power of the muscles in overcoming prisms with the base up or down should always be made. The usual strength in normal eyes will vary from 3° to 8° and I have found those who could fuse the images through a prism of 12° with the base up or down.

Esophoria.—Is a condition of insufficiency of the external recti muscles or a tendency to convergence of the visual lines. The method of determining esophoria has been already described, but quite frequently examination reveals an esophoria at the distant point and exophoria in accommodation. In such cases the presence of hyperphoria should always be suspected.

Esophoria as a cause of muscular asthenopia has received but very brief attention in text-books upon ophthalmology, and yet that it can and does cause many annoying cases of asthenopia is now being recognized by the advanced thinkers in this department. Noyes (*loc. cit.*), states that out of 100 consecutive cases of muscular asthenopia, 74 were cases of insufficiency of the external recti (esophoria).

Stevens states (*loc. cit.*): "In respect to the clinical importance of

esophoria, which occurs in the proportion of more than three to one of exophoria (this has been modified in a later article by Stevens to a proportion of two to one), it plays a much more important rôle than the latter as a predisposing cause to a variety of neuroses; and, as the immediate cause of asthenopia and kindred affections about the eyes, it is an element of great disturbance." My own experience, however, has shown a larger proportionate per cent. of cases of exophoria than has been found by the authorities quoted. This difference has probably been due to the fact, that it is our practice to base the diagnosis, in those cases frequently met with, in which there is found esophoria at the distant point and exophoria in accommodation, upon the condition which seems to be creating the most disturbance. That is, if the asthenopic symptoms are only caused upon use of the eyes at the near point, the case then, we believe, should be considered one of exophoria; and if the distress occurs after use of the eyes at distant vision, one of esophoria. We believe, oculists generally base the diagnosis upon the results found from examination at the distant point alone.

SYMPTOMS.—The disturbing effects from esophoria are more obscure and remote than in exophoria. The patient affected with esophoria is apt to suffer from headaches at the back of the head and neck, a general sense of illness, nausea, vertigo, etc., on the day following a visit to a picture gallery, an attendance at church or theatre, from driving or riding on the cars, in fact from any use of the eyes to maintain parallelism of the visual lines at distant objects. While in exophoria the patient is more apt to suffer with pains in the eyes or head immediately after one or two hours' use of the eyes for reading, sewing, etc. There is often a weakened power of accommodation, with dilatation of the pupil present. They often complain of the annoyance of seeing their nose, or of seeing a black spot before the eyes. Amblyopia is the rule in cases of esophoria exceeding 2° (Stevens). Esophoria is found to be almost invariably of a higher degree when the eyes are under atropine.

Examination as to the power of the external recti muscles in overcoming prisms base in shows the average strength to vary from 10° to 14° , yet an abduction of 6° may not be incompatible with orthophoria. In some cases of esophoria I have seen a power acquired of overcoming prisms of 24° base in, and still an examination would reveal esophoria.

Exophoria.—Insufficiency of the internal recti, or tendency of the eyes to divergence is, we believe, in spite of the experience of others, the most common form of muscular disturbance. This it would seem natural to expect, especially in the educated classes, from the constant over-use of the internal recti at the near point.

SYMPTOMS.—In exophoria we find the most characteristic symptoms on using the eyes, the pains are generally in the eyeballs, the patient wants to rub and press them for relief. Often a blurring of the vision; the letters seem to run together. The headaches occur especially after using the eyes for near work, and are more often frontal, but may be in any part of the head. The power of accommodation in exophoria, contrary to that in esophoria, is usually increased; this is owing to the relation existing between convergence and accommodation, the insufficiency of the internal recti demands and results in greater action of the accommodation. Examination of the power of the internal recti for overcoming prisms will, like the other muscles, give most variable results; in some cases orthophoria will be established when an adduction of 20° is reached, but usually an adduction of upward of 60° will readily be acquired by a little exercise. I have also seen an adduction of 70° or even 80° reached in many cases, and the tests still showed an exophoria.

HETEROPHORIA AND ITS TREATMENT.—The definition of heterophoria, as given by Stevens, of a tending of the visual lines in some other direction than parallelism, applies as well to strabismus, and the difference between the two conditions must be borne in mind. In heterophoria binocular vision is habitually maintained, but by the expenditure of a greater amount of force than is demanded in the perfect equilibrium of the ocular muscles. In strabismus there is, on the contrary, habitual diplopia, though, as a rule, the subject by long suppression of one image has become unconscious of it. Therefore, the dividing line between heterophoria and strabismus should rest on the habitual ability or failure to maintain binocular vision.

In no ophthalmic disorder has it been found so necessary to individualize the case as in muscular insufficiency. Sometimes the highest degrees of heterophoria may be present without asthenopic symptoms, headache or nervous disturbances, while, upon the other hand, the lowest degree may give rise to an aggravated train of symptoms.

It is suggested by Stevens that heterophoria and refractive errors, by causing a constant nervous perplexity and irritation, may result in inducing a state of hyperæmia or altered nutrition of parts supplied to a certain extent by branches of the same nerves which supply the imperfectly balanced muscles, and which may serve to create pathological changes in those parts, viz., the cornea, lens, etc., and claims to have checked the growth of cataract in many cases by correcting the heterophoria. Locomotor ataxia, chorea, epilèpsy, acute mania and other mental disorders are claimed to have been cured, by some enthusiasts, through correction of the heterophoria.

These subjects are merely mentioned because, when we come to consider the wide range of reflex disturbances, they may possibly become demonstrated facts in the future, although at present we are not prepared to accept them as such. But when we come to consider the delicate mechanism of the eye and the important part that the ocular muscles perform in the carrying out of the function of this organ, one must become convinced that any insufficiency on their part may serve to create various asthenopic symptoms, headaches, neuralgias and reflex nervous disturbances. We must, however, deery the tendency to attribute all ills that flesh is heir to, to heterophoria.

As regards the treatment of heterophoria we desire first to *most emphatically protest against the too prevalent operation of graduated tenotomies*. It is to be sure far more brilliant to give the sufferer relief by operative measures than by a more or less tedious course of treatment, but have we the right to permanently lame or weaken the power of any muscle so long as the desired end, relief of the patient, can be attained by any other method? In all forms of heterophoria there is either an insufficiency of one muscle or a preponderance of strength in its opposing muscle, and in order to secure relief the normal equilibrium between these two muscles must be restored. The theory of tenotomy is to weaken the action of the stronger muscle so that the normal balance between it and its opposing muscle may be re-established. The theory of treatment is to strengthen the weaker muscle and thereby re-establish the normal balance. In either method the proper equilibrium is restored; in the first plan by means of two weakened muscles and in the latter by two strong muscles. I have seen many cases where tenotomies

have given prompt and marked relief for a time, but in six months or a year later they have fallen back into an even worse state than at first. I do not wish to be understood as claiming that no case requires operative treatment, for some of them can only be relieved by operation; but *first* the weaker muscle should be strengthened to its *utmost* limit, and then, if relief is not given and the normal balance not restored, a graduated tenotomy may be made.

The operation of graduated tenotomy, as suggested and practiced by Stevens, is as follows: The eyelids being separated, a fold of conjunctiva exactly over the insertion of the muscle is seized, and with the scissors a transverse incision not exceeding one-half of a mm. in length is made through this membrane; with the forceps, pressing the outer cut edge of the conjunctiva backward, the tendon of the muscle is seized in its centre a little behind its insertion and divided with the scissors. The hook is then inserted through this opening in the centre of the tendon and the opening enlarged by careful division of the tendon toward the borders until the desired effect is acquired. Under cocaine the patient experiences no pain, and the extent of the operation is regulated by frequent examinations with the phorometer. If too extensive, it may be limited by a very fine suture inserted through the centre of the divided muscle and through the conjunctiva at the inner side of the wound and tying it only sufficiently tight to have the desired effect.

Dr. Stevens has also devised two other operations, *tendon resection* and *tendon contraction*, to take the place of the old operation of advancement, in these cases of heterophoria; both of them, from their extreme delicacy and slight reaction, are of much service and may be combined with a careful tenotomy of the stronger muscle. The instruments he has had made for all of these operations are much to be commended for their extreme delicacy.

As already stated, however, the operation, we believe, should be held as a *dernier ressort*, and treatment first directed toward increasing the power of the weaker muscle. This is best accomplished by the use of prisms to exercise and strengthen the muscle, precisely on the same theory as other voluntary muscles of the body are strengthened by the use of dumb bells, exercise in the gymnasium, etc.

In *hyperphoria* my practice is to give the patient prisms, set in spectacle frames, with the base up in one eye and down in the other

of sufficient strength to cause vertical diplopia with the images near together. These are to be worn daily for from ten to twenty minutes, after the double images are fused while looking at objects in the room and at greater distances. The strength of the prisms are increased from time to time, as the superior and inferior muscles gain power and are able to overcome stronger prisms. The degree of the hyperphoria should be tested frequently to learn when to stop the exercise, that it may not be overdone. I have found in some cases that an ability to overcome prisms of 12° (a prism of 6° base up in one eye, and of 6° base down in the other) can be acquired by this exercise, but usually they will be only able to overcome prisms of from 5° to 8° ; and oftentimes the hyperphoria will be corrected when even a power to overcome a weaker prism than this is acquired.

In *esophoria* precisely the same method is followed, but of course with the base of the prism set in, toward the nose, before each eye. In this exercise a power of overcoming prisms of from 12° to 16° (divided between the two eyes) is usually obtained, and as high as 24° has been acquired.

In *exophoria* my method of exercising with prisms is entirely different. For this, prisms one and a half to two inches square are used. The patient is seated from fifteen to twenty feet from a lighted candle, the prism is then held with the base out before one eye of sufficient strength to produce horizontal diplopia with the images near enough together to be readily fused by an effort of the patient, the lights are held one, for a moment, when this is removed and a stronger prism placed before the eye. This procedure is followed, using stronger and stronger prisms, so long as the eye can fuse the images; then the other eye is put through the same training, and the exercise should then cease for that sitting. My experience has been that the best results are gained in exercising the internal recti every other day; that they will usually gain from 2° to 10° at each sitting, and should always be exercised to the same degree at least as the previous sitting, in order to hold all gain that is made; that daily exercise or wearing the prisms, as described in hyperphoria, is apt to be too severe a strain upon the muscles in exophoria. The prisms should always be held so that the images are on the same level, else they cannot be fused. In some cases it is

necessary to use a red glass before one eye, so that the patient can more readily recognize the two images. In low degrees of exophoria the patient should always be exercised by the surgeon; but, where there is considerable exophoria, he may be ordered a set of prisms, shown how to use them and carry out the exercise at home, but always under the direction of the surgeon. My usual directions are to exercise up to a certain degree, when they are to report for examination; if exophoria is still present, they are allowed to go on to a still higher degree, and so on. The power of the internal recti to overcome prisms is readily increased in nearly every case to upward of 60° and in the majority to upward of 70° .

Results from exercising with prisms are always more prompt and satisfactory in cases of exophoria than in either hyperphoria or esophoria, as the internal recti, having much greater power normally, seem to respond more readily to the systematic exercise.

Prisms may also be used for another purpose, viz.: To correct the heterophoria. In this case they serve as a crutch to remove the strain from the weaker muscle. In prescribing prisms for this purpose it is better, as a rule, not to put on the full correction of the heterophoria, and they should not be ordered at all until after the prismatic exercise had been carried to its full extent without relief. They should, however, as a rule be worn in preference to an operation, for after their use for some time the muscles may regain their normal balance and the prisms be discarded. Very flattering results have followed the use of even a $\frac{1}{2}^{\circ}$ prism.

In all cases the refraction should be carefully examined, and frequently it is necessary to make a thorough examination under atropine. If any error is detected, it should be as carefully corrected. The muscular equilibrium should be especially examined *with the glasses to be used both at distance and in accommodation* before prescribing them, *because convex glasses will increase exophoria and diminish esophoria*. Many cases of esophoria associated with hyperopia will be wholly corrected by the use of the proper convex glass, which should be as nearly as possible the glass which causes orthophoria both in distance and in accommodation. On the contrary, in exophoria associated with hyperopia the weakest glass possible, or none at all, should be prescribed. Concave glasses will have an opposite effect on exophoria and esophoria to that of convex glasses.

Examination of hyperopic eyes under atropine will always show a much higher degree of hyperopia when esophoria is present than when there is exophoria, and hence stronger convex glasses should always be prescribed in hyperopia when esophoria is present than when there is exophoria.

It is, therefore, important to always test the muscles with the eyes in the state they are to be used, viz., with their glasses on.

The effect of glasses for refractive errors on heterophoria can be aided by either combining prisms or by decentering the lenses; the decentering of the lens gives the same effect as the combination with prisms without the annoyance of the additional weight.

Another method of toning up a weakened muscle which may be employed with benefit is forcible stretching of its antagonist in the following manner: After cocainizing the eye, take hold of the eyeball firmly with fixation forceps over the insertion of the impaired muscle; then force the eye strongly in the direction in which the muscle acts, carrying it also moderately in the opposite direction. Do this two or three times at one sitting. This can be repeated at intervals of from two days to a week.

Both faradism and galvanism have also proven of much value in the restoration of muscle power. Galvanism seems to have given the best results in my hands, and is now universally employed in all cases immediately after the prism exercise, using from six to ten cells, the positive pole applied to the temple and the negative, through a small ball electrode, to the lid directly over the insertion of the impaired muscle. Locally the patient is advised to apply to the closed eyelid three or four times each day a solution of equal parts of brandy and water or a weak solution of the remedy used, especially Ruta, Gels., or Senega.

Internal medication for the relief of asthenopic symptoms is of the first importance.

Aconite.—Asthenopia from over-use of the eyes. Lids spasmodically closed, with a heavy feeling in them; while the eyes *feel very hot and dry* after using. Conjunctiva may be hyperæmic. Cold water may relieve temporarily the heat in the eyes.

Agaricus.—Asthenopia, especially muscular, if accompanied by *sudden jerks of the ball*, twitching of the lids, etc.

Argentum nit.—Letters blur, and sight vanishes on reading or writing.

Calcarea.—Pale, flabby subjects, inclined to grow fat; with coldness of the extremities, and perspiration about the head. Eyes pain after using, and are generally worse in damp weather and from warmth. Burning and cutting pains in the lids, and sticking pains in the eyes on reading. Dim vision after fine work. Objects run together.

Cinnabar.—Asthenopia, with pain in the inner canthus, extending above or around the eye, worse in the evening and upon using the eyes. Soreness over exit of supra-orbital nerve.

Conium.—Letters run together on reading. Burning pain deep in the eye. *Great dread of light.*

Gelsemium.—Asthenopia, with weakness of the external recti, or if associated with blepharitis or hyperæmia of the conjunctiva. Soreness of the eyeballs. Drawing over the eyes. Diplopia which can be controlled by an effort of the will.

Kalmia.—Stiff, drawing sensation in the muscles upon moving the eyes (Nat. mur.).

Lachesis.—Asthenopic symptoms, especially in the left eye, with a variety of pains and sensations, worse upon thinking of them, using the eyes and on waking in the morning.

Lilium tig.—Burning, smarting and heat in the eyes after reading, relieved in the open air (Pulsat.). Photophobia.

Mercurialis peren.—Asthenopia, with a sensation of dryness of the eyes and heaviness of the lids. Mist before the eyes in the morning. Burning pain in the eyes in evening, and upon reading.

Natrum mur.—No remedy is more often indicated in asthenopia than this. The vision soon becomes dim and letters run together upon using the eyes for near vision and sometimes for distant vision. The internal recti are usually weak. *The muscles feel stiff and drawn and ache on moving the eye in any direction. Pain in the eye upon looking down.* Burning, smarting, itching and heat in the eyes upon reading or writing, with a variety of other sensations, even headache. Heaviness and drooping of the lids on use of the eyes for near vision. The eyes appear irritable, with some dread of light, so the patient desires to close them firmly.

Onosmodium.—*Heaviness and dullness of the eyes.* Dull, heavy pains and soreness of the eye-ball. Tense, drawing and tired feeling in the ocular muscles. Pain in and over left eye. *Pains in the left*

side of the head. Dull, heavy pain in the occiput with dizzy sensations, eyes feel as though they were wide open, vision blurred. *Great muscular prostration and tired feeling over the entire body.* The muscles feel unsteady and treacherous, as though you dare not trust them to move.

Phosphorus.—Mistiness and vanishing of vision, with pain and stiffness in the eyeball. Light aggravates, so the patient is better in the twilight. *Muscæ volitantes.* Photopsies.

Rhododendron.—Insufficiency of the internal recti muscles, with darting pains through the eyes and head, *always worse before a storm.*

Ruta grav.—*Aching in and over the eyes,* with blurring of the vision after using or straining the eyes at fine work. *The eyes feel hot like balls of fire,* appear irritable and run water, especially toward evening after working all day.

Senega.—Is a remedy of especial value in cases of asthenopia from hyperphoria. Confused feeling in the head. *Dullness of the head, with pressure and weakness of the eyes.* Tired, aching or pressing pains in or around the eye, smarting and burning of the eyes. The headache is of the whole head and not centered in any particular spot and is often relieved in the open air. Aggravation of all the symptoms upon use of the eyes.

Sepia.—Smarting in the eyes and a variety of other sensations may be experienced, as can be seen by reference to the verified symptomatology. *Aggravation of the symptoms morning and evening.*

Spigelia.—If accompanied by *sharp, stabbing pains* through the eye and around it, extending back into the head.

In addition to the above, many other remedies have been employed with success. Attention is particularly directed to the following: Ammon. carb., Apis, Arn., Asarum, Carb. veg., Caust., Crocus, Euph., Ignat., Kali carb., Ledum, Lith. carb., Macroton, Nux vom., Paris quad., Phos. ac., Pulsat., Santon and Sulphur.

CHAPTER V.

Diseases of the Conjunctiva.

Anatomy.—The conjunctiva is the delicate mucous membrane lining the inner surface of the eyelids; from the lids it is reflected upon the globe and covers the sclerotic as far as the cornea, with which it becomes continuous. The bulbous portion of the conjunctiva is formed of three layers—the external epithelial layer, the tissue proper and the subconjunctival tissue.

The epithelial layer is formed of cylindrical cells externally and a deeper layer of flattened circular cells. The tissue proper is a fine reticulated structure, containing nuclei, together with a few elastic elements. The subconjunctival tissue is loose and elastic, with fibres uniting it to the sclerotic. The conjunctiva, especially the portion covering the lid and forming the cul-de sac, contains numerous lymphatic follicles and acinous glands.

The nerve supply of the conjunctiva is very free and is derived from the fifth pair. The blood supply is also extremely abundant, especially in the region of the limbus and around the caruncle.

The function of the conjunctiva is to act as a lubricating surface.

Hyperæmia of the Conjunctiva—**SYMPTOMS.**—The vessels have the appearance of a coarse network. The transparency and smoothness of the conjunctiva is lost and the papillæ of the lids are more marked, giving it a velvety appearance. The eyes are red, feel hot and heavy, and as though there was sand in them; there is a smarting, itching and a tired feeling on using them, or from exposure to a bright light.

CAUSES.—The most frequent cause is a prolonged effort of the accommodation in those who have some uncorrected error of refraction, exposure to severe cold or heat, or from foreign bodies. Often seen in those living or working in a vitiated atmosphere. It is also frequently associated with nasal catarrh, hay fever, etc.

COURSE.—It may be either acute or chronic, and when chronic it may cause a blepharitis, or become a catarrhal conjunctivitis.

TREATMENT.—See *conjunctivitis catarrhalis*.

Conjunctivitis Catarrhalis is a hyperæmia of the conjunctiva plus a discharge from the membrane—a simple hypersecretion. The healthy conjunctiva secretes mucus mixed with effete epithelial cells, and, when abundant, it becomes tenacious, stringy and with it small masses of pus. The difference between catarrhal and purulent ophthalmia is simply one of degree; in catarrh the secretion contains elements of pus, but still is never really purulent, and is much less likely to destroy the corneal epithelium by maceration than does the purulent.

SYMPTOMS.—These are the same as found in hyperæmia, but of a higher degree; the itching, smarting and burning sensations, the photophobia, lachrymation and redness of the eye are all present, and, from the greater inflammation and infiltration, we have chemosis. The discharge from the eye may be more or less excessive, but of a bland or muco-purulent character. The amount of secretion varies, and at night it is apt to accumulate and cause crusts on the cilia. The patient often complains of a temporary blurring of vision and black spots before the eyes, due to small flakes of secretion passing in front of the pupil.

COURSE.—An acute attack does not usually last more than from one to three weeks, although it may run into the chronic form, especially in cachetic persons, or from unfavorable surroundings. In the chronic form the discharge is less contagious, and the disease is often associated with an inflammation of the lachrymal sac, especially if one eye only is affected.

CAUSES.—In the acute form, where there is a muco-purulent discharge, it is certainly contagious. It may appear as an extension of a nasal catarrh, from an affection of the eyelids, or from an inflammation of the lachrymal sac. Frequently occurs from an exposure to cold, from dust or smoke, from confinement in a close or vitiated atmosphere; often due to refractive errors, and is apt to occur with the exanthemata.

DIAGNOSIS.—As other diseases of the eye may very closely resemble a catarrhal conjunctivitis, the differential diagnostic points should be considered. The principal diseases usually mistaken for conjunctivitis are iritis, episcleritis and keratitis.

Conjunctivitis.	Iritis.	Episcleritis.	Keratitis.
<p>The redness of the conjunctiva is general, and on pressure through the lower lid the injected vessels are seen to move with the membrane over the sclerotic. There is always redness of the fornix conjunctivæ, and usually of the palpebral conjunctiva. There is a muco-purulent discharge, more or less profuse. The iris is clear and bright, the pupil reacts readily to light and the cornea is clear.</p>	<p>The redness is deep-seated, surrounds the cornea as a rosy zone, and is not accompanied by redness of the fornix or palpebral conjunctiva. The injected vessels are beneath the conjunctiva, and do not move with it. The iris is discolored, pupil sluggish and inactive and the vision is impaired. There is usually very severe pain in the eye and head, which is generally worse at night.</p>	<p>The redness is of a dusky-red color, is subconjunctival and localized; it is most often situated over the external rectus muscle, or over the internal.</p> <p>There is usually little or no pain, and the duration of the disease is much longer.</p>	<p>The redness is deep-seated, and usually most marked around the cornea. The transparency of the cornea is always more or less diminished.</p>

TREATMENT.—The first point in the treatment should be the removal of any exciting cause. To accomplish this the lids should first be everted and examined for the presence of a foreign body, which, if detected, should be removed. If the conjunctivitis depends upon any anomaly of refraction, this should be corrected. If due to straining of the eyes in reading, writing, etc. (especially in the evening), or to exposure to wind, dust or any bright light, as working over a fire, directions to abstain from over-use, or to protect the eyes from the injurious causes, should be given. Should the case be very severe, the patient may be confined to his room, though this is rarely required in pleasant weather. As a local remedy in acute inflammation of the conjunctiva, the use of *ice* is especially recommended. It may be used in rubber bags made for that purpose or by wrapping it in a towel. If prescribed it should be used *constantly* for twenty-four or forty-eight hours or longer, according to the benefit derived. Cleanliness especially should be required. To prevent the formation of crusts on the lids, the edges may be smeared at night with a little vaseline, simple cerate, cream or the like.

In conjunctivitis, after the acute symptoms have subsided, we sometimes find the inflammation will come to a standstill, notwithstanding our most careful selection of remedies. In these cases a mild astringent will be found advisable, and the two following prescriptions have proven of much value :

R. Sodæ biboratis,	ʒj
Aqua camphoratæ,	ʒiij
Misce.		
R. Zinci sulph.,	gr. ij
Sodium chlorid.,	gr. iv
Aqua dest.,	ʒi
Misce.		

Instil a few drops in the eye four times a day. Atropine should not be used unless there is iritic complication.

The attendants should be warned that the discharge is contagious, and that the sponges, towels, etc., used upon the patient should not be employed for any other purpose.

Aconite.—Is especially indicated in the *first stage of catarrhal inflammation*, prior to exudation, if the conjunctiva is intensely hyperæmic and œdematous, with severe pain in the eye, often so terrible that one wishes to die ; or, as is more frequently the case, a feeling of *burning and general heat in the eye, with great dryness*. There may also be an aching or bruised pain, or a feeling as if the ball were enlarged and protruding, making the lids tense. The eye is generally very sensitive, especially to air. This is the first remedy to be thought of for conjunctivitis dependent upon exposure to cold, dry air. For inflammatory conditions of the conjunctiva resulting from the *irritant action of foreign bodies* in that tissue there is no better remedye (It is in the Aconite stage that ice is most valuable).

Allium cepa.—Of use in acute catarrhal conjunctivitis associated with a similar condition of the air passages, as in hay fever ; the lachrymation is scalding, profuse and not excoriating, though the nasal discharge is so (reverse of Eúphrasia).

Alumina.—Inflammation of the conjunctiva, usually chronic and affecting chiefly the palpebral conjunctiva, always aggravated from over-use of the eyes and accompanied by a sensation of dryness in them, with moderate discharge and a heavy feeling in the lids.

Apis mel.—Especially called for in the acute form of conjunctivitis, when the conjunctiva is bright red and puffy, lachrymation hot and moderately profuse, and pains in the eye, burning, biting or stinging; sometimes the pains are very severe, darting through the eye, or possibly around the eye and in the brows. Photophobia may be present. The *oedematous condition of the lids*, especially the upper, which is usually present in the cases in which Apis is indicated, is an important symptom. There is generally aggravation in the evening and fore part of the night. Although the lachrymation is hot and burning, yet it does not excoriate the lids, as in cases in which Arsenicum is indicated. General symptoms of dropsy, absence of thirst, etc., would suggest this remedy to our minds.

Argentum nit.—Should be employed if the *discharge becomes profuse*, assuming the character of purulent ophthalmia. It may also be indicated in the chronic form of conjunctivitis, when the conjunctiva is scarlet-red and the papillæ hypertrophied. The inflammatory symptoms usually subside in the open air and are aggravated in a warm room.

Arnica.—In conjunctivitis resulting from blows and various injuries Arnica is often beneficial.

Arsenicum.—Occasionally useful in acute conjunctivitis with chemosis, much hot, scalding lachrymation, *burning pains, especially at night*, and oedematous condition of the lids, particularly the lower lid. It is also indicated in the chronic form, if the *lachrymation and discharge from the eyes are acrid*, excoriating the lids and cheek; the balls burn as if on fire, especially at night.

Warm applications generally relieve. The attacks of inflammation are frequently periodic and often alternate from one eye to the other.

Belladonna.—The remedy in the early stages of catarrhal conjunctivitis, if there is great dryness of the eyes, with a sense of dryness and stiffness in the thickened red lids and smarting, burning pains in the eyes. Photophobia is marked. Much dependence should be placed, however, upon the concomitant symptoms of headache, red face, etc.

Calcarea carb.—Occasionally useful in catarrhal conjunctivitis caused by working in water. Eyes hot with feeling of sand in them.

Causticum.—Conjunctivitis with a *feeling of sand in the eyes* and dull, aching pain.

Chamomilla.—Catarrhal conjunctivitis occurring in peevish children during dentition. Conjunctiva so congested that blood oozes out.

Cinnabaris.—May be called for in conjunctivitis, especially with the characteristic symptom of *pain above the eye, extending from the internal to the external canthus* (usually above, though sometimes below).

Duboisin.—*Chronic hypercæmia of the palpebral conjunctiva in hyperopes.*

Euphrasia.—In this drug, we have a very valuable remedy for both acute and chronic catarrhal conjunctivitis, especially acute. It is useful in catarrhal inflammation of the eyes caused by exposure to cold, and also in that of the eyes and nose found in the first stage of measles. In the selection of this drug we are guided chiefly by the objective symptoms as the subjective are not very definite, there being a variety of sensations. The conjunctiva is intensely red; even chemosis. The *lachrymation is profuse, acrid, burning, while the discharge from the eye, which is also quite profuse, is thick, yellow, muco-purulent and acrid, making the lids and cheek sore and excoriated.* (The secretion is also excoriating under Arsenic and Mercurius, but is thinner.) *Blurring of the vision relieved by winking,* dependent upon the secretion covering the cornea temporarily, is especially characteristic of this remedy.

Graphites.—Sometimes indicated, especially in the chronic form of catarrhal conjunctivitis, though it is more particularly the remedy for phlyctenular ophthalmia. The redness, photophobia and lachrymation are usually well marked, but may vary to a great extent. The discharges from the eye, if present, are thin and acrid, while the *nose is sore, excoriated* and often surrounded by thick, moist scabs. Dry scurfs are frequently found on the lids, while the *external canthi crack and bleed easily.*

Hepar sulph.—Another remedy more useful in strumous ophthalmia; though it is sometimes employed with benefit in the catarrhal form, as when the conjunctiva is much congested, even chemosis, with considerable photophobia and lachrymation, while the lids are much swollen and very sensitive to touch. The discharge is of

a muco-purulent character and often well marked. The pains are throbbing, aching or lancinating and relieved by warmth, so that one wishes to keep the eye covered most of the time.

Ignatia.—Has been successfully used in catarrhal ophthalmia in nervous, hysterical subjects, when there has been a sensation as if a grain of sand were rolling around under the lid, with great dryness and lachrymation only when exposed to the sunlight.

Merc. sol.—In Mercury we possess an important remedy for catarrhal conjunctivitis, and this preparation is most commonly required, though some other may be employed, if the concomitant symptoms so indicate. The redness and dread of light are usually well marked, especially in the evening, by artificial light. The *lachrymation is profuse, burning and excoriating and the muco-purulent discharges thin and acrid*, making the lids and cheek red and sore. The pains vary in character and are not confined to the eye, but extend into the forehead and temples, *are always worse at night*, especially before midnight, in extreme heat or cold and in damp weather, and are often temporarily ameliorated by cold water. It is especially indicated in syphilitic subjects, and when the concomitant symptoms of soreness of the head, excoriation of the nose, nocturnal pains, etc., are present.

Nux vomica.—Is not very often called for in this variety of conjunctivitis. It would be suggested to our minds if there were much dread of light, marked *morning aggravation* and accompanying gastric symptoms.

Pulsatilla.—This is another of our standard remedies for catarrhal conjunctivitis, especially the acute form, though it is also useful in the chronic. It is particularly to be thought of in conjunctivitis occurring in the colored race, as well as in the mild, tearful female. The redness is variable and may be accompanied by chemosis. The pains in the eye are burning, itching or lancinating, usually worse in the evening, when in the wind and after reading, but *relieved by the cool, open air*. The lachrymation is often profuse by day, with a purulent discharge at night; though generally a *moderately profuse muco purulent discharge of a white color and bland character*, which agglutinates the lids in the morning, is to be found. Gastric and other concomitant symptoms, if present, will influence our choice.

Rhus tox.—Is the chief remedy for conjunctivitis caused by *exposure in water* (Calc.), especially if there is much chemosis, with some photophobia, *profuse lachrymation* and *œdematous swelling of the lids*. A rheumatic diathesis would especially suggest this remedy.

Sanguinaria.—Benefit has been derived from its use in catarrhal conditions of the conjunctiva, with burning in the edges of the lids, worse in the afternoon. Hæmorrhages in the conjunctiva with tendency to trachoma; moderate discharge and pain.

Sepia.—Acute catarrhal conjunctivitis with drawing sensation in the external canthi and smarting in the eyes, ameliorated by bathing in cold water and *aggravated morning and evening*. Conjunctivitis with muco-purulent discharge from the eyes in the morning and great dryness in the evening.

Sulphur.—This is one of our chief remedies in both the acute and chronic forms of catarrhal conjunctivitis. The degree of redness may vary greatly; it may be confined to one eye or may involve both. The lids may be swollen or remain unaffected. The *sharp, darting pains, like pins piercing the eye*, occurring at any time of the day or night, will furnish our chief indication. A severe pain darting through the eye back into the head, from 1 to 3 A.M., waking the patient from sleep, is also an important indication. A variety of other sensations may be present; as pressing, tensive, cutting or burning pains, a feeling of sand in the eyes, etc. The patients are usually *feverish and restless at night*.

Terebinth.—Great redness of the conjunctiva, usually dark in color, with *severe pain in the eye and corresponding side of head*. Some pain in the back, and *urine dark in color*.

Zincum.—has been useful in conjunctivitis especially when confined to the *inner half of the eye*, with much discharge; worse toward evening and in the cool air. Generally there is *itching*, and perhaps pain, *in the internal canthus*.

The following remedies have also been used with benefit or may be indicated in occasional cases: Chelidonium, Cuprum sulph., Kali bichr., Natrum mur., Senega, Silicea and Thuja.

Conjunctivitis Purulenta.—(*Ophthalmia Neonatorum, Conjunctivitis Gonorrhœica*).—An inflammation of the conjunctiva with a purulent discharge may occur at any time of life, and bears essen-

tially the same features, whether occurring in the infant soon after birth, or in the adult as a result of infection from a gonorrhœal or other discharge. It is, however, more commonly spoken of under the heading of its two principal causes as ophthalmia neonatorum and conjunctivitis gonorrhœica; but, as the pathology, symptoms, course and treatment are practically the same, they will be generally described under the one heading, reserving for each a brief mention of its characteristic peculiarities.

PATHOLOGY.—No great changes take place in the conjunctiva. It simply becomes infiltrated with serum, together with a proliferation of cells and lymphoid elements; the blood vessels become dilated, the capillaries increased in number and there is also some thickening of the epithelium.

SYMPTOMS.—All those of catarrhal conjunctivitis are present in a much higher degree. The most prominent symptom is chemosis, which may be sufficient to overlap the cornea. This is due to serous engorgement, which also extends to the lids, causing a violet colored puffiness. The œdema of the lids is so great as to cause ptosis. The papillæ of the conjunctiva are elevated and form villi, which bleed easily and give a thick, swollen appearance to the conjunctiva of the lids. Another most prominent symptom is the discharge, which at first is thin, muco-purulent, but soon becomes distinctly purulent, a thick yellow secretion, and is so excessive that the eye and cheek become literally bathed in pus.

At first there is a feeling of heat and smarting, burning pains in the eye, then ciliary pains and shooting pains in the head set in. In some there is a distinct febrile movement. The swelling of the lids becomes hard and tense, of a dusky red color—the upper lid overhanging the lower.

These symptoms may gradually diminish and the conjunctiva return to the normal condition. The great danger is an involvement of the cornea, which may occur in three ways, viz.: First, small facets are formed by a loss of the epithelium, which, if seen and watched, may be prevented from extending; if not, they extend deeper, unite and form an ulcer, which may terminate by perforation. Second, there appear toward the centre of the cornea grayish points of infiltration, which increase in size, fuse and tend to form an abscess. Third, infiltration takes place at the margin of

the cornea in the form of a ring, and ; if this occupies more than a third of the cornea, it indicates an affection of the nutrition and becomes the starting point of a general necrosis, which almost inevitably causes loss of the eye. The cause of this participation of the cornea is due to either direct action of the infectious matter on the cornea, to direct continuity of inflammation to the substances of the cornea, or to the stoppage of the nutrition of the cornea by the chemosis.

CAUSES.—Contagion is undoubtedly the direct cause in nearly every case. In infants it usually results from a leucorrhœal discharge at the time of birth. In adults it is more often the result of infection from gonorrhœa. Girls have been affected from an ordinary leucorrhœal discharge. Secretions from a diphtheritic conjunctivitis, or an altered or decomposed discharge from a catarrhal conjunctivitis may cause a purulent ophthalmia.

PROGNOSIS is always serious if the cornea is affected, as permanent opacities, staphyloma of the cornea, or even complete destruction of the eye may ensue. Even when the cornea is not affected, do not give a too favorable prognosis, as corneal complications may arise at any time.

Ophthalmia Neonatorum.—The ophthalmia of the newly-born child is undoubtedly solely the result of inoculation from a leucorrhœal or gonorrhœal discharge from the vagina or cervix and occurs during birth, or later from the soiled linen or sponges. It is only in cases where the eyes are prematurely opened that they contract the contagion, when due to contact with the virus during labor, and it usually manifests itself on the third or fourth day after birth. When resulting from soiled linen, etc., it is usually later in presenting its appearance, and, when beginning later than the first week, is almost certainly due to some extraneous source of inoculation.

Statistics have shown that in former years a very large proportion of all cases of blindness has resulted from this disease, in different countries varying all the way from 20 to as high as 79 per cent. In late years the attention that has been paid to the prevention of this disease has very materially lowered the per cent. Still we are daily meeting cases of permanent blindness from this disease which should be attributed wholly to the ignorance of those attending these cases. Much of this fatality could be obviated by careful disinfection of the vagina at the time of parturition and in cleanliness in the linen and

the sponges used and the hands of those coming in contact with the child or mother. Careful cleansing of the eyes of the babe with carbolized water or by the instillation of a weak solution of the nitrate of silver (2 per cent.) should always be practiced in all cases where the mother is suffering from leucorrhœa.

Conjunctivitis Gonorrhœica.—This disease is always due to infection. Its onset is often accompanied by a severe arthritis. The inflammatory process is usually very intense and runs a rapid course. The lids are greatly swollen, as is also the palpebral conjunctiva. There is excessive chemosis and purulent secretion.

The disease usually develops in about forty-eight hours; it may occur in either acute or chronic gonorrhœa, and the more active the gonorrhœa is at the time of infection, the more severe will be the inflammation. The virus of gonorrhœa may also cause diphtheritic conjunctivitis.

The right eye is more often first affected, and it is more frequently found in males than in females. The physician must always handle all cases of purulent conjunctivitis with extreme care, on account of possible infection. This variety of purulent conjunctivitis is more severe than when due to any other cause, as about one-half of all eyes attacked with this disease are lost, while hardly one-third of the other forms of purulent conjunctivitis are fatal.

TREATMENT of *Conjunctivitis Purulenta.*—If the attack is very severe, the patient may be confined to a darkened room, or even to bed; if only one eye is affected, the other should be hermetically closed in order to prevent any of the matter coming in contact with that eye, for this discharge is very contagious, especially in the gonorrhœal form, and in that found in new-born children. The healthy eye is best protected by means of a watch-crystal held in place over the eye by strips of adhesive plaster. In this way the eye is hermetically sealed; the patient can use the eye for necessary vision, and it is always under the observation of the surgeon. Owing to the contagiousness of the secretions great care should be exercised both by the nurse and physician, to protect their own eyes and those of others, by providing that the sponges, towels, etc., are used only by the patient; also, that their hands are thoroughly cleansed before touching another eye, for often the physician and other patients have been inoculated and vision destroyed through carelessness on this

point. If, by accident, any of the discharge should have got into a healthy eye, lukewarm water should be at once injected under the lids to wash it away; after which, drop in a strong solution of chlorine-water, or a weak solution of nitrate of silver (gr. ij. ad ℥j). Fresh air and nourishing diet are important aids. But the special and primary point to be attended to in the treatment is *cleanliness*. To ensure this, the discharges should be often removed by dropping warm water into the inner canthus until all the pus has been washed away, or by cleansing with the palpebral syringe. This should be done at intervals of from fifteen minutes to an hour during the day, and occasionally through the night, according to the severity of the case. The use of peroxide of hydrogen is of great aid in the thorough cleansing of the eye, so essential in purulent affections.

In the inflammatory stage of purulent conjunctivitis, *ice compresses* will usually be found most valuable, often serving to abort an attack. Ice-bags may be used on the eye, or when the weight of the ice-bag is complained of, cold may be applied by means of four or five thicknesses of old linen, cut about three inches square and laid upon a large cake of ice; these pads are to be conveyed quickly from the ice to the eye and changed every one or two minutes so that the cold will be constant. Carbolic acid, a 1 to 200 solution, or other disinfectants, can be used in combination with the ice, by having a large piece of ice in a large vessel of the solution.

Caustics are directly efficacious by the irritation of the vascular walls, and indirectly by the contraction that follows a considerable discharge of serum, such as accompanies the shedding of the eschar. A 2 per cent. solution of the nitrate of silver applied once or twice a day is preferable to stronger solutions. The use of Chlorine water, Boracic acid and the like is frequently of great service. Astringents, especially a weak solution of nitrate of silver (2-5 grain to the ounce) may be required. If the patient is seen shortly after inoculation with gonorrhœal virus, it may be aborted by one application to the everted lid of a strong solution of nitrate of silver (gr. xxx. ad ℥j), washing it off with water. Scarification is sometimes needed. The incisions are not to be made deep, but long and parallel to each other, and may be repeated every twenty-four hours, if needed; promote the bleeding by warm water and by kneading the lid.

When the cornea becomes ulcerated, some operative measure, paracentesis or sclerotomy, or the use of Atropine or Eserine, may be required, according to the complication. Canthoplasty may be necessary to relieve the pressure upon the eyeball, if the lids are much swollen and very tense.

Aconite.—May be indicated in the first stage, according to the symptoms given under catarrhal conjunctivitis; or, if there is great redness, chemosis and profuse purulent discharge, with swelling and redness of the lids and *much burning heat in the eye*.

Apis mel.—Is useful in violent cases of purulent conjunctivitis and ophthalmia neonatorum, if there is *great swelling (œdematous) of the lids and adjacent cellular tissue*. The conjunctiva is also congested, puffy and full of dark red veins. The discharge is moderate, not profuse, though the lachrymation is well marked. The character of the pains, which are *stinging and shooting*, is an important indication. There is usually much photophobia, accompanied by hot lachrymation (Rhus). The symptoms are aggravated in the evening. Objectively the Rhus cases are similar to Apis; the character of the pains will usually serve to distinguish between the two.

Argentum nit.—This is the most frequently indicated remedy in the whole materia medica for any form of purulent inflammation of the conjunctiva. It is not always necessary to obtain its caustic effects, except in the gonorrhœal form of conjunctivitis, as the most intense chemosis with strangulated vessels, most profuse purulent discharge and commencing haziness of the cornea, with a tendency to slough, have been seen to subside rapidly under this remedy internally administered.

The subjective symptoms are almost none. Their very absence, with the profuse purulent discharge, and the swollen lids, swollen from being distended by a collection of pus in the eye, or from swelling of the sub-conjunctival tissues, and not from infiltration of the connective tissues of the lids themselves (as in Rhus or Apis), indicates the drug.

The use of a solution of five or ten grains of the first decimal trituration to two drachms of water, as a local application, after the very profuse discharge has subsided, is often of very great value.

Calcarea carb.—The discharges from the eye, under this drug, are often profuse, and therefore it has been used with advantage in some

cases of purulent or infantile ophthalmia, characterized by a profuse, yellowish-white discharge, œdema of the lids and ulceration of the cornea. It is specially indicated when the trouble arises from working in the water. It is, however, especially useful for the *results* of purulent ophthalmia, clearing up the opacities of the cornea, etc. In the selection of this drug, great reliance should be placed upon the general condition (cachexia) of the patient, as the eye symptoms are not very characteristic.

Calcareo hypophos.—Purulent conjunctivitis, with ulceration of the cornea, occurring in patients who are very much debilitated, and who have little vitality. In one case of gonorrhœal ophthalmia treated by Dr. George S. Norton¹ where there was a moderate discharge and no pain, but with excessive chemosis, tendency to perforation at periphery of the cornea, and, in fact, the whole cornea seemed to be sloughing, Eserine, 1 to 200 was instilled, and Calc. hypophos. 1 given with immediate and remarkable improvement of the whole condition.

Chamomilla.—Is often of service in ophthalmia neonatorum as an intercurrent remedy, even if it does not remove the whole trouble. It is indicated when the child is very fretful and wants to be carried all the time, and when the usual symptoms of the disease are present, even though the cornea has been invaded. Sometimes the conjunctiva is so much congested that blood may ooze out, drop by drop, from between the swollen lids, especially upon any attempt to open them (Nux).

Chlorine.—Aqua chlorinii, as an external application, has proved a very valuable remedy in the various forms of purulent ophthalmia. Cases have been relieved by it when used alone, as well as with the indicated remedy given at the same time internally (which has generally been the case). The strong solution is sometimes employed, though we usually dilute it one-half, one-third or still weaker.

Euphrasia.—Is useful especially in that form found in new-born children, more often in the later stages of the disease than at the beginning, as can well be understood by examining the symptoms already given under catarrhal conjunctivitis, where the indications have been stated.

¹ Transactions Hom. Med. Soc., State of New York, 1884.

Hepar sulph.—May be indicated in any form of this disease, particularly when the cornea has become implicated and ulceration has taken place. *The lids may be swollen, spasmodically closed, bleeding easily upon any attempt to open them and very sensitive to touch.* There is much redness, *chemosis*, and the *discharge is considerable*, of a yellowish-white color. The *photophobia is intense*, lachrymation profuse and pain severe, of a throbbing, aching character, relieved by warmth; any draught of air aggravates the symptoms. When the *ulceration is severe* and *hypopyon* has taken place, Hepar is especially the remedy.

Kreosote.—Blenorrhœa of the conjunctiva; the discharge is moderately profuse, with much smarting in the eyes.

Mercurius.—Has been employed with benefit, particularly in ophthalmia neonatorum when the *discharges were thin, excoriating and caused by syphilitic leucorrhœa.* It is also one of our best remedies for gonorrhœal ophthalmia and for purulent conjunctivitis found in syphilitic subjects, whether it be acquired or hereditary. The discharge, as has been said, is thin and excoriating, making the lids and cheek sore and raw. The lachrymation and photophobia are usually marked and the pains severe, though variable in character and always worse at night. Is more commonly called for late in the disease, especially if the cornea has become involved. The concomitant symptoms are important aids in the selection. Mercurius corr., Mercurius sol. and Mercurius præc. ruber have all been successfully used; though the eye symptoms, we believe, vary little in these preparations, except perhaps being more intense under the corrosivus.

Nitric acid.—Is especially advised for gonorrhœal ophthalmia. Lids much swollen, red, hard and painful, conjunctiva hyperæmic, chemosis, cornea ulcerated, great photophobia and lachrymation, copious discharge of yellow pus, which flows down the cheek, pressing and burning pain in the eye, worse at night. The cheeks are also usually much swollen and painful. A few drops of the first or third potency in water may be used locally at the same time it is given internally.

Pulsatilla.—This remedy stands high in the treatment of purulent conjunctivitis, when the *discharge is profuse and bland.* Benefit has been gained from its use in blenorrhœa of the conjunctiva,

caused by the gonorrhœal contagion. It is, however, most frequently useful in ophthalmia neonatorum, characterized by the usual well-marked symptoms. Many cases of this form of conjunctivitis have been cured by this drug alone, though we believe that it is particularly called for as an intercurrent remedy during the treatment by Argent. nit.; for, often when the improvement under the latter remedy is at a stand-still, a few doses of Pulsatilla will materially hasten the progress of the cure. The symptoms are usually worse in the evening and ameliorated in the open air.

Rhus tox.—Ophthalmia neonatorum and when the trouble arises from exposure in water. The *lids are red, œdematous* and spasmodically closed. The palpebral conjunctiva is especially inflamed, so that when the lids are opened a thick, red swelling appears, with a *copious, thick, yellow, purulent discharge*; or the discharge may be less and a *profuse gush of tears may take place*. The child is usually cachectic and restless; head hot. It has been used both externally and internally.

Sulphur.—Is not so useful in this variety of conjunctivitis as in the pustular or even the catarrhal form, though it has been of service more frequently in that form found in new-born children, especially when the trouble has become chronic and when not dependent upon syphilis. The symptoms observed are not characteristic, with the exception, perhaps, of the sharp sticking pains, as if pins were sticking in the eye. We rely, to a great extent, in selecting this drug, upon the general condition (scrofulous cachexia) of the patient.

Other remedies, as Cupr. al., Cupr. sulph., Eserine, Natrum mur. and Nux vom., may be required.

Conjunctivitis Diphtheritica is perhaps one of the worst diseases of the eye we have to deal with. It may exist alone or with diphtheria of the throat.

PATHOLOGY.—It is a fibrinous infiltration throughout the entire thickness of the mucous membrane which seriously interferes with the circulation.

SYMPTOMS.—It commences with acute pain (due to strangulation of the nerves and vessels by the infiltration), a feeling of heat and lachrymation. The upper lid becomes very much swollen and the skin of the lid is smooth, shining and of a pale, rosy or livid hue.

The upper lid falls down, overlapping the lower, and it is impossible for the patient to raise it. The conjunctiva becomes congested and chemosed, due to an infiltration of coagulated fibrine. There is a dryness of the eye, and on everting the upper lid we find it smooth and yellowish, and upon removing a portion of it we find that it has the same appearance all through, due to the infiltration. Owing to a constriction of the bloodvessels, a deep incision will produce no bleeding. The whole lid has a lardaceous appearance. Occasionally diphtheritic patches are found on the external angles of the lids. The secretion is sanious and contains flakes of diphtheritic matter.

The disease so far has been one of infiltration, lasting from one to ten days, and is the most dangerous stage, on account of corneal complications. Then begins the second stage, that of purulent discharge. The lids lose their hardness and there is set up a copious discharge of fibrinous masses. The vessels reappear at points and the infiltration looks like white patches here and there. The chemosis loses its yellow appearance and stiffness, and the whole disease now looks like an ordinary attack of purulent conjunctivitis, but, instead of ending here, it enters a stage of cicatrization, resulting in more or less adhesions between the lid and eyeball, and in some cases ends in xerophthalmia.

The great danger in this disease is the liability of corneal complications, due to the infiltration of the conjunctiva shutting off the nutrition of the cornea.

CAUSES.—Contagion is the principal cause, yet the disease must be looked upon as an expression of the general condition, for we find diphtheritic affections of other parts at the same time, and we may have the general symptoms of fever, exacerbations, weakness, loss of appetite, etc. The good eye, though protected, will often become affected. It is most frequently found from the first to the third years of life, but is rarely seen in adults.

PROGNOSIS depends upon the amount of infiltration, grayish chemosis and stiffness of the lids. It is, as a rule, more serious in adults than in children. The earlier the cornea is affected the more serious is the prognosis. Cases caused by direct contagion are always much more serious.

TREATMENT.—See *conjunctivitis crouposa*.

Conjunctivitis Crouposa.—In this disease there is the formation of a membrane, which may be thrown off as a cast of the sac. The swelling and injection is less than that of purulent ophthalmia. The membrane has an especial affinity for the cul-de-sac, while the tarsus and globe is least affected. The membrane is similar microscopically to that of tracheal croup. The disease is always acute, and the formation of a fibrinous layer is the essential feature, which is cast off with a slight purulent discharge and cure rapidly follows. It occurs particularly in the spring and autumn, when there is apt to be an epidemic form of diphtheria, and is found especially among children.

TREATMENT.—Although these two forms of inflammation are wholly distinct from each other, they will be considered under the same section, as the treatment is not dissimilar in many points. If only one eye is involved, endeavor to prevent the extension of the disease to the other eye by hermetically closing it, for the discharge is very contagious, though extension may take place through the general dyscrasia. *Cleanliness* is of the greatest importance, as in purulent conjunctivitis. It is better not to exercise any force in removing the false membrane, as it only leaves a raw surface, upon which a new membrane forms, thus doing more harm than good; though all loose shreds should be carefully removed whenever the eyes are washed.

The application of caustics or strong astringents, especially in diphtheritic conjunctivitis, is *always injurious*. In the early stages of either form of inflammation *ice compresses* seem to exert a beneficial influence over the course of the disease and should be used. As soon as the purulent stage appears, stop the cold and you may then use hot applications. A solution of *alcohol* and water (ʒj ad ʒij) has been employed locally with some benefit in diphtheritic inflammation; also a one per cent. solution of *Carbolic acid*. Lemon juice brushed over the surface of the conjunctiva every six hours is highly recommended by a number of physicians. In croupous inflammation *chlorine water* has been useful as an external application. Corneal complications require especial attention. Cold compresses must be discontinued as soon as the cornea becomes involved. In the cicatricial stage palliate the desiccation of the eye by instillations of milk, boroglycerine, or the carbonate of soda, gr. xxx. ad ʒi.

Acetic acid.—A remedy of the first importance in croupous conjunctivitis in which the *false membrane is dense, yellow-white, tough and so closely adherent* that removal is almost impossible. The lids are œdematously swollen and red. Although the membrane is closely adherent, it is not in the tissue and so does not correspond to diphtheritic conjunctivitis.

Aconite.—Of importance in the first stage. For indications refer to catarrhal conjunctivitis.

Apis mel.—Croupous conjunctivitis, or very early in the diphtheritic, before the lids have become firm and hard. Lids *red and œdematous*, especially the upper. Marked *chemosis* and severe pains, of a *stinging, shooting* character. Patient drowsy and thirstless.

Argentum nit.—Blennorrhœal stage of either form of inflammation. The discharge is profuse and purulent. Use both externally and internally.

Arsenicum.—Of service in weak cachectic children who are very restless and thirsty, especially after midnight. False membrane firmly attached in places, with ulceration of the cornea. Lids swollen, lachrymation and discharges excoriating and burning pain in the eyes.

Hepar sulph.—Blennorrhœal stage, or if the *cornea is ulcerating*. Pains severe and relieved by warmth.

Kali bichrom.—Both croupous and diphtheritic conjunctivitis. Especially indicated when the false membrane is present, if *shreds or strings of it float loose in the eye*. The discharge is of a *stringy character* and mixed with tears. Non-vascular ulceration of the cornea. General symptoms will confirm the above local indications.

Lachesis.—A great tendency to hæmorrhage upon removing any of the membrane or even without doing so.

Mercurius prot.—This form of Mercury will be more commonly called for than the other preparations. Indicated in all stages of the disease. Membrane on the conjunctiva and cornea ulcerated. Cornea more vascular, pains, photophobia and other symptoms of a higher degree than Kali bichr. The nocturnal aggravation and characteristic appearance of tongue and throat are present.

Phytolacca.—Should be valuable in diphtheritic conjunctivitis with *firm, hard swelling of the lids*.

Calc. c., Carbol. ac., Chlorine, Bromine, Iodine, Kali iod., Pulsat. and Rhus should be borne in mind.

Conjunctivitis Follicularis presents a very similar appearance to that met with in trachoma, and is often mistaken for it.

PATHOLOGY.—It is a simple hypertrophy of the lymph follicles, which microscopically are found to have a delicate reticular connective tissue, in the meshes of which are found lymph corpuscles and free nuclei, and are also permeated by fine capillaries.

SYMPTOMS.—The conjunctiva appears filled with small, round, pinkish prominences, occupying the cul-de-sacs especially of the lower lid, where they are first noticed and always more prominent. In advanced cases they are arranged in rows, running parallel with the margin of the lid. Occasionally they may be found on the tarsus, where they appear as small, whitish, slightly raised patches.

The condition comes on slowly and lasts for months or years. It is unaccompanied by any discharge, and has but slight photophobia, with occasional painful sensations, but no marked symptoms.

CAUSES.—Usually results from bad hygienic surroundings and is often endemic in schools, asylums and prisons. The use of atropine in some cases will cause it. This disease is often complicated by a catarrhal conjunctivitis, when we have the symptoms of irritation, discharge, etc. The disease is mostly met with in children and appears to be contagious. Follicular conjunctivitis never leads to subsequent shrinking and cicatrization.

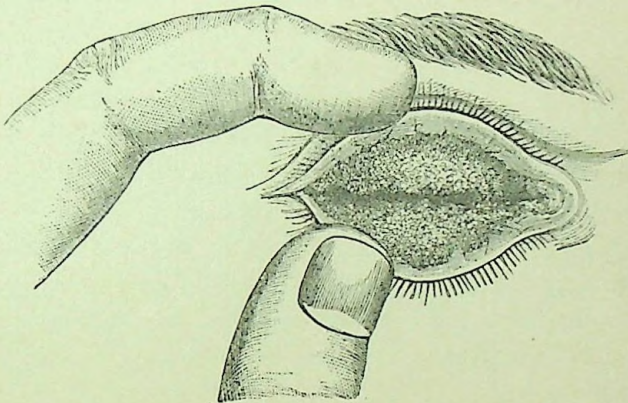
TREATMENT.—Fresh air, change of climate and proper hygienic surroundings will, in most cases, be sufficient to cure the trouble. Local applications, such as those used in trachoma, have not proved of much benefit, although mild astringents will in some cases be of help. Correct any errors of refraction that may be present. Pressing out the contents of the follicles between the thumb nails, or by Knapp's roller forceps, as described under trachoma, will cure the disease in a much shorter time than under any other method of treatment. We have seen a number of cases of follicular conjunctivitis promptly and quickly cured by the use of Knapp's forceps, with little or no reaction, and we believe this operation is the best treatment at present known for aggravated cases of this disease. The use of electricity is also of much value; but, as each follicle has to be punctured with the needle, the treatment is necessarily very tedious.

The use of homœopathic remedies is of prime importance in this disease, and those of especial value are *Natrum mur.*, *Euph.* and *Sepia*. For special indications see *trachoma*.

Conjunctivitis Trachomatosa.—(*Granular Lids, Trachoma*).

PATHOLOGY.—This has been the subject of much dispute and still does not seem to be definitely settled. Some claim it to be a circumscribed hyperplasia of the lymphatics normally found in the reticulated connective tissue of the conjunctiva, thus forming true lymphoid follicles; while others claim they are new growths. They consist of small rounded masses, made up of lymphoid and connective-tissue cells, surrounded by a fibrous capsule and traversed by

FIG. 27.



Everted Granular Lids.

blood vessels and connective-tissue fibres. They are imbedded in the adenoid tissue, which is in itself greatly hypertrophied. The granule may undergo fatty degeneration and its contents be pressed out, or the connective tissue of the granule may increase and, from ultimate contraction, result in entropium. De Wecker says: "A granulation lives and dies feeding on the parent that gave it life—it consumes the conjunctiva." Hence it is a malignant product, while follicles or purulent conjunctivitis are essentially benign.

SYMPTOMS.—They appear as yellow or reddish gray elevations, looking like frog-spawn (Fig. 27), and are generally found along the free border of the tarsus and at the angle of the lids in the earliest stages. As the disease advances they extend to the retro-tarsal folds, and, in the worst cases, over the ocular conjunctiva and even

upon the cornea. They are oval in shape and broader and less prominent than the hypertrophied follicles. There is some drooping and swelling of the lids and a slight secretion causing some agglutination of the lids in the morning. Pain, photophobia and lachrymation may be present and, during acute aggravations, become very severe.

COURSE.—The disease is usually very insidious in its course. As it progresses the granulations increase in size and become covered with fine capillaries, the conjunctiva becomes red and infiltrated and secretes a muco-purulent discharge, the papillæ swell, increase in size and blend with the granules. We have then the conjunctiva appearing as a fleshy mass, in which we are no longer able to distinguish the individual granules or papillæ. Sometimes the neoplasm appears as polypoid excrescences or condylomatous masses.

CAUSES.—Trachoma may appear at all ages, except in the very young. It may be either acute or chronic, and we may have acute exacerbations of an existing chronic trachoma. It is usually met with in places where the population is overcrowded, ill-fed and amid unfavorable hygienic surroundings. Negroes in this country seem to enjoy great immunity from trachoma. True trachoma is very rarely seen among the better classes, but is often endemic in public institutions, asylums, etc. Trachoma is undoubtedly contagious, and is said to have been caused in some cases from prolonged use of atropine and cocaine.

COMPLICATIONS.—The conjunctiva in long existing cases, undergoes fibroid degeneration, atrophies and appears as grayish white cicatricial bands, usually running parallel with the border of the lid. There may be also more or less dryness and shrivelling up of the conjunctiva, which sometimes goes on to complete destruction of the conjunctiva—*xerosis*. The roughened condition of the conjunctiva causes a superficial vascularity of the cornea, with a proliferation of the epithelial cells between the epithelium and Bowman's membrane, resulting in an opacity of the cornea called *pannus*. Later the whole cornea becomes softened, loses its resistance, yields to the intra-ocular pressure and bulges. Occasionally the granules extend and may even be found in the cornea. Ulcers and abscesses of the cornea or a catarrhal or purulent conjunctivitis are very frequently found associated with trachoma.

PROGNOSIS.—In the early stages, when under careful treatment, resolution may occur in a short time. Later, however, the disease is more stubborn, its duration almost unlimited and it leaves changes in the lid or cornea which may produce more or less serious disturbance of vision and even blindness.

Papillary Trachoma, as described by some, is a hyperæmia, inflammation and hypertrophy of the normal papillæ of the conjunctiva. These are mostly found near the canthi and the free border of the tarsus. There is also a proliferation of the epithelium. This gives the conjunctiva at first a red, roughened appearance, and later that of a swollen, bright red mass, studded with elevations. If uncomplicated, the inflammatory product may be absorbed and the conjunctiva restored to its normal condition.

DIFFERENTIAL DIAGNOSIS.

Conjunctivitis Trachomatosa.	Papillary Trachoma.	Conjunctivitis Follicularis.
<p>Affects especially the upper lid—particularly the upper portion and the free border of the tarsus. The granule is oval, reddish gray and more or less opaque; it is imbedded in the membrane, and is less prominent than the follicles, and it may be found on the ocular conjunctiva and even the cornea. In the granular variety, the affection, as a rule, soon takes on the mixed form, characterized by the presence of follicular and papillary hypertrophy in addition to the neoplasm. There is also general lymphoid infiltration of the conjunctiva and of the deeper tissues of the lid, including the tarsus, great proliferation of the epithelium and the formation of new vessels.</p>	<p>Its location is predominantly over the surface of the tarsus instead of its borders. The enlarged papillæ are of a bright red or bluish-red and injected appearance.</p>	<p>Affects especially the lower lid, particularly the cul-de-sacs. The follicle is round or elongated, pale and semi-transparent; it is more prominent and sharply raised above the surface of the conjunctiva, and can be removed or separated from it. Its general arrangement is in rows parallel to the free margin of the lid.</p>

TREATMENT.—As these form of conjunctivitis are usually found

among the lower classes or those who are constantly exposed to wind and dust, care should be taken that these exciting causes be removed as far as possible; cleanliness and proper hygienic measures being very important aids in the treatment of this affection.

It should be remembered that the discharges from granular lids are contagious, and that whole families or a whole school may be inoculated from one member by an indiscriminate use of towels, etc.; therefore, strict attention should be paid to the prevention of its extension.

There is no reason why trachoma should not be cured by the internal administration of medicines alone, but owing to the present inadequate knowledge of our drugs in this affection, a majority of the cases we meet proves so extremely obstinate to treatment that both the patient and doctor become discouraged. If a cure can be effected by internal medication it seems to be more permanent than if total reliance is placed upon local applications, but I do not hesitate to use local remedies if there is no particular indication for any special drug, or if the case proves very obstinate. In acute trachoma or acute aggravations of chronic granular lids, *ice compresses* will prove very agreeable to the patient and aid materially in controlling the intensity of the inflammatory process. In chronic granular inflammation of the conjunctiva, especially when complicated with pannus, which is usually present, local treatment will be found of the greatest service. The following topical applications have been followed by more favorable results in my hands than any others :

R. Carbolic acid,	gtt. vj
Glycerine,	ʒj
Misce.	
R. Tannin,	gr. xv
Glycerine,	ʒj
Misce.	

They should be applied with a camel's hair brush to the everted lids once a day. Other applications which have also proved beneficial in individual cases are alum, used as a powder, in a saturated solution with glycerine and in the crude stick; cuprum aluminatum and sulphuricum used in crystals; nitrate of silver in a weak solution (gr. ij — x ad. ʒj), and bichromate of potash in a saturated solution.

The local use of corrosive sublimate in solutions of varying strengths, from 1 to 500 to 1 to 200, gives extremely satisfactory results in some cases. It may be used by simply rubbing the lids energetically with absorbent cotton moistened in the solution, or by making slight scarifications with the Johnson grattage-knife (Fig. 28) and then applying the solution. Under the use of cocaine there

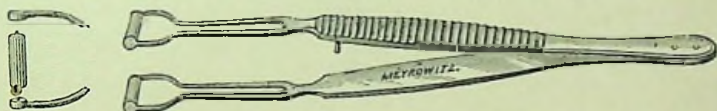
FIG. 28.



Johnson's Grattage Knife.

is but little if any pain, and but slight inflammatory reaction occurs except possibly from the stronger solutions. A number of operative measures have been suggested from time to time which have been credited with more or less success by different authorities. We shall, however, refer to but one operation in detail which, in our experience, seems to be the most satisfactory, and that is the following, which may be called *the operation of expression of the morbid substance with a roller-forceps*, and is described by Knapp.¹ He uses

FIG. 29.



Knapp's Roller Forceps.

the roller-forceps (Fig. 29) made by having two steel cylinders so inserted into the forked end of a small but strong pair of forceps that they roll upon each other.

As the operation is rather long and more or less painful, a general anæsthesia should be employed. The lower lid is everted and superficially scarified with the Johnson knife, although scarification is by no means indispensable. One roller of the forceps is then pushed deeply into the fornix, and the other applied to the anterior portion of the everted lid, the forceps are then compressed and drawn for-

¹ Archiv. Ophthal., vol. xxi, 1, 1892.

ward, so that the tissue between the cylinders is milked out. The instrument is reinserted and the neighboring portion treated in the same way. This manipulation is repeated until the cylinders roll easily and evenly over the evacuated conjunctiva. The upper lid is then treated in the same way. To reach the superior cul-de-sac, the tarsus may be drawn away from the eye with fixation forceps. Especial care should be taken to reach all parts of the conjunctiva at the fornix and commissures. The forceps should be frequently dipped into an antiseptic fluid in order to be kept clean and free from coagulated blood, which prevents the rollers from turning. Both lids of both eyes may be treated at the one operation, and but one operation is usually required. But slight reaction usually occurs, and the patient is not necessarily, though preferably, kept confined. The application of the corrosive sublimate solution, 1 to 1,000, or weaker, may be used immediately after the operation, if desired.

This method is of the greatest value in follicular conjunctivitis and in the cases of densely packed spawn-like granulations. When thoroughly done the conjunctiva is left perfectly smooth and assumes its normal appearance in from one to two months.

Excision of the retro-tarsal fold, as advised by Jacobson, has been extensively practiced. Treitel¹ reported its trial in 170 cases with satisfactory results. It has at the same time been praised and condemned by many other authorities. From our own observation it has not given as favorable results by far as the operation detailed above.

The once much-lauded Jequirity treatment seems now to be a thing of the past.

At the same time local treatment is employed the carefully selected internal remedy should be administered.

Aconite.—In the first stage of granular conjunctivitis, when the eyes are *inflamed, hot, burning and very painful*. There may be a sensation of great *dryness*, or moderate lachrymation. *Acute aggravation of granular lids and pannus, with excessive hypercæmia, heat and dryness*, especially if the aggravation be induced by overheating from violent exercise or by exposure to dry, cold air. Ice compresses are especially serviceable in Aconite cases.

¹ Therap. Monatshefte., 1889, 2 and 3.

Alumen exsiccatum.—This remedy may be of value in all forms of trachoma, whether complicated with pannus or not. It is employed by dusting the crude powder on the inner surface of the lids, allowing it to remain about a minute and then washing it off with pure water and, at the same time, giving the lower preparations internally.

Alumina.—Chronic granular lids in which there is marked dryness of the lids and eyes, especially in the evening, with burning, itching and pressure in the eyes; agglutination mornings; the upper lids are weak, and seem to hang down as if paralyzed. The symptoms of loss of power in the upper lids are often met with in old, dry cases of granulation; in these cases Alumina does good.

Argentum nit.—Especially serviceable in the early stages of acute granular conjunctivitis, if the conjunctiva is intensely pink or scarlet-red and the *discharge is profuse* and inclined to be mucopurulent.

Arsenicum.—Indicated in chronic granular lids, when the palpebral conjunctiva only is inflamed; the lids are painful, dry and rub against the ball; they burn and can scarcely be opened. Chiefly called for when the pains are intense, burning, and the lachrymation very excoriating.

Aurum met.—Is the appropriate remedy for many cases of trachoma, either with or without pannus (especially, however, when pannus is present); there is probably no other remedy which has only been employed internally that has cured more cases. Its use is highly recommended, though the local symptoms which lead us to its selection have not yet been found peculiar or characteristic. The pains may be burning or dull in character, compelling the patient to close the lids. They are usually worse in the morning and ameliorated by the application of cold water. For the corneal ulcerations found in pannus Aurum is of great value.

The *muriate of gold* is frequently employed, though the symptoms, as far as known, vary but slightly from those of the metal.

Belladonna.—As a temporary remedy in acute aggravations of granular lids may be beneficial. After taking cold the eyes become sensitive to air and light, with dryness and a gritty feeling in them.

Calcarea carb.—Conjunctivitis trachomatosa with pannus, caused

by working in the water, with much redness and lachrymation, has been relieved by this drug. The general condition of the patient will, to a great extent, lead to its selection.

Carbolic acid.—Chronic trachoma, especially with pannus. Can be given internally at the same time it is used locally.

Chelidonium.—Trachoma, with pain in and over the eye upon looking upward.

Chininum mur.—Marked improvement has been observed from the internal use of this drug in granular lids, with or without pannus.

Cuprum al.—The aluminate of copper has been successfully used to a great extent in trachoma, either with or without pannus. The results obtained are usually much more satisfactory than those from the sulphate of copper, which is the main reliance of the old school in the treatment of this disorder. It is employed locally by application of the crystals to the granulations, at the same time giving the remedy in the potencies internally.

Euphrasia.—Trachoma with or without pannus, if the eye is very red and irritable, with *profuse lachrymation and thick discharge, which excoriates the lids and cheek.*

Kali bichr.—Trachoma with pannus; much discharge; everything appears slightly red; usually not much photophobia or redness of conjunctiva, though ulceration of the cornea may be present; eyes seem to feel better when lying on the face. A saturated solution applied to the granulations is often beneficial.

Mercurius præc. rub.—In trachoma with pannus it is a valuable remedy; rarely of much use in acute cases, but especially adapted to old chronic cases, when the cornea is covered with pannus of a high degree, with considerable redness, discharge and photophobia. The granulations may be present or may have been already removed by caustics.

Mercurius prot.—Especially if pannus accompanies the trachoma and the eye is quite *red and painful, with photophobia* and acrid discharges. *Tongue coated yellow at the base.* Is the remedy for *ulceration of a pannoused cornea, particularly if superficial.*

Natrum mur.—Particularly useful in follicular conjunctivitis, in chronic cases and when the lids have been already treated by caustics (especially the nitrate of silver). The pannus or the irritable condi-

tion of the eye resulting from, or kept up by the scarred palpebral conjunctiva found after cauterization, is often greatly relieved by this drug. The lachrymation is acrid and excoriating, as well as the discharges which are thin, watery and make the cheek raw and sore. The pains are variable, though sometimes we have a sharp pain over the eye upon looking down, which is very marked. The skin of the face round the eye is often glossy and shining.

Nux vom.—Of service in old cases of trachoma that have had much treatment, especially when complicated with pannus. Nux is frequently of great benefit in commencing the treatment of granular lids with or without pannus; also as an intercurrent remedy for the morning aggravation, which is particularly marked under this drug and in the disease. It will rarely, however, effect a cure unassisted by any other remedy.

Pulsatilla.—The granulations are generally very fine (papillary trachoma); the eye is sometimes dry or there may be excessive secretion of bland mucus. There may also be soreness of the ball to touch and itching or pain in the eye, which is worse in the evening and better in cool air or by cold applications.

Rhus tox.—Of value in relieving the intensity of the symptoms found in conjunctivitis granulosa with pannus. The eye is quite red, with *much photophobia and profuse lachrymation*. No remedy acts so powerfully as Rhus tox. in diminishing the profuse secretion of tears.

Sepja.—Follicular or trachomatous conjunctivitis, which is only observed in or always made worse by hot weather.

Sulphur.—Trachoma, acute and chronic, with or without pannus, has been benefited by this drug, which is often called for as an intercurrent remedy, even if it does not complete the cure alone. It is especially indicated when the *pains are sharp and lacerating in character*, worse in the morning and when the lids are glued together by the secretion during the night. The application of water is not agreeable to the patient and it often aggravates the disease.

Thuja occid.—Favorable results have been gained by the use of this remedy in conjunctivitis trachomatosa, when the granulations have been large, like warts or blisters, with burning in the lids and eyes, worse at night; photophobia by day and suffusion of the eyes with tears.

The following remedies have also been employed with favorable results: Caust., Cinnab., Con., Cupr. sulph., Hepar, Merc., Petrol., Sang. and Zinc.

Conjunctivitis Phlyctenularis.—(*Pustular, Scrofulous, Strumous and Herpetic Conjunctivitis.*)

PATHOLOGY.—Consists of a slight sub-epithelial exudation, composed of a transparent fluid, holding a few leucocytes; or, again, there may be an exudation of white corpuscles and a small amount of serum. Lastly, there may be no appreciable amount of serum, but only lymphoid cells, which then form minute abscesses.

SYMPTOMS AND COURSE.—In the most simple form we find on the ocular conjunctiva a slight triangular-shaped injection, at the apex of which the phlyctenule is located. There may be several of these, which may become absorbed, leaving no trace behind them; or they may break down, forming an ulcer, which then heals very quickly. In another form there is a more extensive injection, with hyperæmia and localized infiltration in the form of rings around the cornea, on which we find a large number of small transparent phlyctenules, which usually disappear in a few days, the same as the first variety. Again we may find a very pronounced redness with the formation of a very large phlyctenule at the border of the cornea, which may encroach upon the cornea itself. There may be several of these at a time or they may form successively. They break down and form large ulcerations that may be some weeks in healing, or they may perforate and cause staphyloma. Sometimes this form may be accompanied by a yellowish infiltration or abscess of the cornea. Finally, very large phlyctenules may form on the ocular conjunctiva; the inflammation extends, grows deeper and involves the sclera. They often ulcerate, but usually only affect the superficial layers of the sclerotic and are of long duration.

There are sometimes no subjective symptoms, but usually excessive lachrymation, violent pain, intense photophobia and blepharospasmus. Frequently the child will lay with the eyes closed and the face buried in the pillow all day long. There is always a great tendency to relapses.

CAUSES.—Especially apt to occur in children and may be found in the perfectly healthy child as well as the weak and delicate ones.

It is, however, most frequently seen in children of a scrofulous diathesis. Any irritating influence may cause it, such as errors in refraction, etc. It is again frequently observed associated with or following the exanthematous diseases.

TREATMENT.—It has been thought best to include under this head the various forms of pustular inflammation of the eye, whether affecting the cornea or conjunctiva, as the ætiology, symptomatology, course and treatment vary little in either case; in fact, those remedies which have been found useful when the cornea is invaded are also our chief reliance in this form of inflammation of the conjunctiva.

The first points to be attended to are cleanliness and regulation of diet. The eyes should be bathed often in lukewarm water, and any little scabs which may have formed on the lids immediately removed, as they only prove a source of irritation. If there is considerable photophobia, and the child is rubbing the eyes constantly, a compress bandage will prevent this, and at the same time, by keeping the lids closed, will relieve the irritation to the eyeball occasioned by their constant opening and closing; it also excludes the light, relieving the photophobia, soaks up the tears and so prevents their running over the cheek, making it sore and excoriated. The bandage, if used, though it is not commonly necessary, should be removed every four or five hours and the eyes cleansed. External applications should not, as a rule, be employed, as we can usually cure better and quicker with internal remedies alone, if we are careful in the selection of our drugs, although sometimes they may be useful and necessary; thus, occasionally a case will be found which has proved very obstinate to treatment; ciliary injection great, photophobia intense, and pupil a little sluggish—in which a weak solution of *Atropine* dropped into the eye once or twice a day will be of great benefit. In some slow, indolent cases, the use of the following to stimulate into a more active condition, is of value:

R. Hydrarg. oxid. flav.,	gr. iv
Vaseline,	ʒj
Misce.	

Of this, a very small piece, not larger than the head of a pin, may be placed within the eye once or twice a day.

Antimonium crud.—Pustules on the cornea or conjunctiva, especially in cross children who are afflicted with pustules on the face and moist eruptions behind the ears. The lids are red, swollen and excoriated by the profuse mucous discharges and lachrymation. Excoriation of the nostrils, and swollen upper lip. (Similar to Graphites).

Apis mel.—Pustular keratitis, with dark, puffy conjunctiva and œdematous lids. This puffy condition of the conjunctiva and lids is very important, especially when accompanied by burning, *stinging*, or shooting pains in the eyes. The discharges are slight, with the exception of the tears, which are usually profuse and burning, with photophobia (Rhus). The aggravation is usually in the evening, and often concomitant symptoms, such as drowsiness and absence of thirst, are present. This remedy is not frequently called for, though useful when the above indications are present.

Arsenicum.—Especially useful when the cornea has become affected and the pustules have broken, leaving *superficial ulceration*. The *photophobia is usually intense* at all times, though it may be so relieved in the open air that the child will open its eyes easily. The lachrymation is profuse, *burning and excoriating, as are all the discharges from the eye*, which are also thin in character. The conjunctival redness is variable; chemosis. The pains are generally of a burning character, and may be very severe; the eye often feels very hot. The lids may be œdematous and spasmodically closed, or else red, inflamed and excoriated by the acrid discharges. The nostrils and upper lip are usually excoriated by the acrid coryza. It is especially indicated in low, cachectic conditions, and the ill-nourished, scrofulous children of the poor. Great restlessness and thirst for small quantities of water are commonly noticed.

Aurum met.—Scrofulous ophthalmia, with ulceration and vascularity of the cornea. Photophobia severe, lachrymation profuse and scalding; eyes very sensitive to the touch. The pains are from without inward, and worse upon touch (reverse of Asafœtida). The cervical glands are usually swollen; patient very irritable and sensitive to noise.

Baryta.—Both the carbonate and iodide have been employed in scrofulous ophthalmia, especially when complicated with *enlarged cervical glands*. We have obtained better results from the iodide than from the carbonate.

Belladonna.—Rarely useful, except in acute aggravations in which there is great photophobia.

Calcareæ carb.—Particularly indicated in phlyctenular keratitis, though it has also been successfully used in conjunctivitis. It is indicated when the disease can be traced to exposure to wet. We usually, though not always, find excessive photophobia and lachrymation (often acrid). The amount of redness is variable, as is also the character of the pain, though this is more commonly described as sticking than otherwise. The lids may be red, swollen and agglutinated in the morning. There is a general *aggravation of the eye symptoms during damp weather*, or from the least cold, to which the patient is very susceptible. It is especially the remedy for pustular inflammation occurring in *fat, unhealthy, strumous children* who have enlarged glands, distended abdomen, pale, flabby skin, eruptions on the head and body which burn and itch and cold sweat of the head. In fact, upon the concomitant symptoms we place our chief reliance, as the eye symptoms are not characteristic.

Calcareæ iod.—The indications are nearly the same as for Calcareæ carb., though it is preferable in cases in which we have considerable swelling of the tonsils and cervical glands.

Calendula.—Pustular conjunctivitis, with great redness, but no photophobia.

Cannabis ind.—Large pustules on the conjunctiva, with great vascularity.

Chamomilla.—Has proved very serviceable in scrofulous ophthalmia occurring in *cross, peevish children during dentition* and will often relieve the severity of the symptoms, even though it does not complete the cure. The cornea is usually invaded, and we have great intolerance of light, considerable redness and lachrymation.

Cinnabaris.—The cornea is generally implicated in the trouble, and the symptoms of photophobia, lachrymation, etc., are severe. *Pain from the inner canthus across the eyebrows*, or extending around the eye is a very marked indication for Cinnabaris.

Conium mac.—When the inflammation is chiefly confined to the cornea and we have *intense photophobia and profuse lachrymation* upon any attempt to open the spasmodically closed lids. The pains are various, but are generally worse at night. With all this intense

photophobia, there is *very slight or no redness of the conjunctiva*, not sufficient to account for the severity of the symptoms.

Croton tig.—Phlyctenular keratitis and conjunctivitis, associated with a vesicular eruption on the face and lids; the eyes and face feel hot and burning, especially at night; the photophobia is marked; ciliary injection like iritis often present, and considerable pain in and around the eye, usually worse at night.

Euphrasia.—Phlyctenular ophthalmia, in which the *lachrymation is excessive, acrid*, and burning, or if there is a profuse, *thick, acrid, muco-purulent discharge, which excoriates the lids*, making them red, inflamed and sore; from this discharge the cheek may look as if varnished. Intolerance of light is generally present, though not always, and the conjunctiva may be red; even chemosis. The pains are not marked, though usually of a smarting character from the nature of the discharges. *Blurring of the eyes, relieved by winking*, dependent upon the secretions temporarily covering the cornea especially indicates Euphrasia. Fluent, acrid coryza, often accompanies the above symptoms.

Graphites.—This is one of the most important remedies we possess for this disease, and its sphere of action is not limited to any special variety, for excellent results have been gained from its use in both the acute and chronic form, whether the cornea is involved or not; it is, perhaps, more often called for in phlyctenular keratitis of the chronic recurrent form. It is especially indicated in scrofulous subjects, covered with eczematous eruptions, chiefly on the head and behind the ears, which eruptions are glutinous, fissured and bleed easily. *The photophobia is usually intense* and the lachrymation profuse, though in some cases nearly or entirely absent; generally worse by daylight than gaslight and in the morning, so that often the child cannot open the eyes before 9 or 10 A.M. The redness of the eye is generally important (there may be pannus); the discharges are muco-purulent, constant, thin and excoriating. The pains are not important and vary; may be sticking, burning, aching or itching. The lids are red, sore and agglutinated in the morning, or else covered with dry scabs, while the *external canthi are cracked and bleed easily upon opening the eye*. We often notice a *thin, acrid discharge from the nose* accompanying the eye affection.

Hepar sulph.—Is most useful in the severer forms of pustular in-

flammation, especially when upon the cornea and when ulceration has already commenced. The intensity of the symptoms suggests its use, as *intense photophobia, lachrymation and great redness of the eye, even chemosis*. The pains are severe, generally of a *throbbing, stinging* character, *ameliorated by warmth* (so that one wishes to keep the eye covered) and aggravated by cold or uncovering the eye; also usually worse at night or in the evening. The lids are often swollen, spasmodically closed and very *sensitive to touch*; also may be *red, swollen and bleed easily upon opening*. Particularly indicated in scrofulous, outrageously cross children who have eruptions and boils on various portions of the body.

Ipecac.—It is one of the most frequently indicated remedies in pustules and ulcers of the cornea and conjunctiva. There is *much photophobia*. The redness and pain are variable. Nausea may be present.

Kali bichrom.—Is adapted to phlyctenules on the conjunctiva or to chronic cases of low grade. The chief characteristics are *absence of photophobia and of redness*, or much less of each than would be expected from the nature of the disease. The pains and lachrymation are also generally absent or nearly so. The eye is often quite sensitive to touch, and its secretions are of a stringy character. This form of potash has been more often employed than any other, though the iodide is also useful in similar cases.

Mercurius.—Mercury, in some form, is a frequent remedy for strumous ophthalmia, especially when the cornea has become involved. As the symptoms are similar in all the preparations, we shall first, under this general head, give those symptoms common to all forms and afterward give the special indications for each. This is the first remedy to be thought of when this form of inflammation occurs in *sypilitic subjects*, whether the taint is hereditary or acquired. Especially useful when the cornea is invaded and the vascularity is great, though sometimes there may be a well-marked grayish infiltration around the pustule or ulcer. The redness of the conjunctiva is usually great; the dread of light is generally marked and often intense, so that the patients cannot open their eyes even in a darkened room, and it is more often *aggravated by any artificial light*, as gaslight or the glare of a fire. The *lachrymation is profuse, burning and excoriating*, and the *muco-purulent discharges are thin and acrid*.

The *pains are generally severe*, varying in character, though more often tearing, burning, shooting or lancinating and are not confined to the eye, but extend to the forehead and temples, seeming to lie deep in the bones; they are *always aggravated at night*, especially before midnight, by heat, extreme cold and in damp weather and are temporarily relieved by cold water. The lids are often spasmodically closed, thick, red, swollen, excoriated from the acrid lachrymation and sensitive to heat or cold and also to contact. The concomitant symptoms of excoriation of the nose, condition of the tongue, eruption on the face, pain in the bones, etc., etc., are of the first importance in selecting this drug.

Mercurius corr.—Indicated in the erethistic form of inflammation occurring in strumous subjects. The pustules are usually found upon the cornea, and hence the severity of the symptoms so marked under this preparation of mercury, which is more useful than solubilis in severe cases; the pains are more severe, photophobia more marked, lachrymation more profuse and excoriating and all the symptoms more intense than under any preparation we have. Pustules on the cheek, enlarged cervical glands, coated tongue, excoriating coryza, etc., are usually present.

Mercurius dulc.—Calomel dusted into the eye has been employed for many years by the old school in serofulous ophthalmia and even now is considered one of their chief remedies. We also have found this remedy, given internally in the potencies, very useful in the severer forms of this inflammation occurring in pale, flabby, serofulous subjects. Nose sore and upper lips swollen.

Mercurius nit.—This remedy seems to be particularly adapted to this form of inflammation, and has been used, especially by Dr. Liebold, with remarkable success in a large number of cases. Severe as well as mild, chronic as well as acute cases, superficial as well as deep ulcers have yielded to its influence; in some cases there has been *much photophobia*, in others none at all, in some *severe pain*, in others none. We might thus go through a variety of symptoms differing as much as the above in which this drug has proved curative. It is commonly used externally and internally at the same time; the first potency, ten grains to two drachms of water (or even stronger) as an external application, to be used in the eye, two, three or more times a day, and the second or third potency to be taken internally.

Mercurius præc. rub.—This varies little from the general description given of mercury; it is used in strumous ophthalmia with great benefit.

Mercurius prot.—Not as often required as the other forms of mercury, unless there be quite extensive superficial ulceration of the cornea, with much photophobia and nocturnal aggravation. There is also, usually, swelling of the glands, and the tongue has a thick, yellow coating at the base.

Mercurius sol.—Is very often employed in scrofulous ophthalmia; the indications correspond very closely in all points to those found under the head of Mercurius.

Mezereum.—Pustular conjunctivitis, accompanied by eczema of the face and lids, especially if characterized by thick, hard scabs, from under which pus exudes on pressure.

Natrum mur.—The eye symptoms are not particularly characteristic; there may be itching, burning and feeling as of sand in the eyes, worse in the morning and forenoon; the pains are not severe, except perhaps the sharp pain over the eye upon looking down. The lachrymation is acrid and excoriating, making the lids red and sore; the discharges from the eye are also thin, watery and acrid. The photophobia is usually marked and the lids are spasmodically closed. The skin of the face, around the eyes, is often *glossy and shining*, while throbbing headache and other concomitant symptoms are generally present.

Nax vom.—Favorable results have been gained in *cases previously much medicated*, both externally and internally. Rarely of service when the conjunctiva only is affected, as the most characteristic indications are *excessive photophobia and morning aggravation of all symptoms*, which are indications that the cornea is implicated. The lachrymation is usually profuse and the pains vary as follows: Sharp, darting pains in the eye and over it, in some cases extending to the top of the head and always worse in the morning; burning pains in the eyes and lids; a sense of tearing in the eye at night on awaking from sleep; eye feels pressed out whenever she combs her hair; sensation as of hot water in the eye; pain in the lower lid as if something were cutting it, etc. Sometimes relief from the pain is obtained by bathing the eyes in cold water.

Psorinum.—Especially adapted to *chronic cases of recurrent scrofulous ophthalmia*.

Pulsatilla.—This is one of our sheet anchors in the treatment of this disease, especially when the *pustules are confined to the conjunctiva*. It is particularly indicated in persons, especially amenorrhœic females, of a mild temperament and fair complexion, and is also very suitable to this class of ailments occurring in the negro. When pain in the ear, otorrhœa and other aural symptoms accompany the eye disorder, this remedy would be suggested to our minds. The dread of light is often absent or quite moderate and the redness varies. The lachrymation is not acrid, but more abundant in the open air, while the other *discharges are generally profuse, thick, white or yellow and bland*. The pains vary greatly, but are more often of a pressing, stinging character. The lids may be swollen, are not excoriated, but very *subject to styes*. The eyes feel worse on getting warm from exercise or in a heated room and generally in the evening, but are *ameliorated in the open air* and by cold applications. The concomitant symptoms of stomach derangement, amenorrhœa, etc., must be taken into consideration.

Rhus tox.—Useful in pustular inflammation after it has progressed to superficial ulceration of the cornea; for then we have present the *intense photophobia and profuse lachrymation* so characteristic of this drug. The conjunctiva may be very red, even *chemosis*, and the lids *œdematous, particularly the upper, and spasmodically closed, so that we are compelled to open them by force, when a profuse gush of tears takes place*. The skin of the face, around the eyes, is often covered by a Rhus eruption, especially suitable in a rheumatic diathesis. The symptoms are usually worse at night, after midnight and in damp weather; the patients are restless at night and disturbed by bad dreams. *Rhus rad.* has been employed with excellent results in serofulous ophthalmia when the above symptoms were present. In what respect it differs from Rhus tox. remains to be shown.

Sepia.—Especially of value in pustular inflammation found in women, either *occurring with or dependent upon uterine troubles*. More often called for when the cornea is affected than when the inflammation is confined to the conjunctiva. The pains are usually of a drawing, aching, piercing character, aggravated by rubbing, pressing the lids together or pressing upon the eye. The light of day dazzles and causes the head to ache. The conjunctiva may be

swollen, with agglutination of the eyes morning and evening; considerable purulent discharge; edges of the lids raw and sore; feeling as if the lids were too tight and did not cover the ball; eruption on the face, etc. *All the symptoms are worse in the morning and evening and better in the middle of the day.*

Sulphur.—This is the remedy, *par excellence*, for pustular inflammation of the cornea or conjunctiva. Its sphere of action is very wide and adapts it to a great variety of cases, especially *chronic and occurring in scrofulous children covered with eruptions*. The pains vary, though are usually of a *sharp, lancinating character, as if a needle or splinter were piercing the eye*, and may occur at any time of the day or night; we may have a *sharp, shooting pain going through the eye back into the head from 1 to 3 A.M.* which disturbs the sleep of the patients; although, besides these, there may be a variety of other sensations, as smarting, itching and burning in the eyes, feeling of pressure as from a foreign body; burning, as from lime; stinging, burning in the eye, especially from light and in the morning; biting, as if salt were in the eye; sensations as if there were a number of little burning sparks on the lids which cause them to close spasmodically; painful dryness, as if the lids rubbed the eyeball, bruised pain, etc. The photophobia is generally very marked and the lachrymation profuse, though in some cases they may be almost or entirely absent. The redness varies greatly, but is usually considerable, especially at the angles; the secretions also vary both in quantity and quality, being often, however, acrid and corroding and sometimes tenacious. Agglutination in the morning is commonly present. The lids are often swollen, burn and smart as if bathed in some acrid fluid, or there is an itching sensation compelling the patient to rub them most of the time. They are frequently covered with an eruption as well as the surrounding integument of the head and face. All the symptoms are, as a rule, *aggravated by bathing the eyes, so that the child cannot bear to have any water touch them*; also usually worse in the open air.

Syphilinum.—Chronic recurrent phlyctenular inflammation in scrofulous, delicate children, especially if there is any taint of hereditary syphilis. The epithelial layer of the cornea will be abraded. The photophobia will be intense and lachrymation profuse.

Tellurium.—Has proved successful in phlyctenular conjunctivitis,

with eczema impetiginoides on the lids and much purulent discharge from the eyes, complicated with an offensive otorrhœa smelling like fish-brine.

Thuja.—Large phlyctenules which involve the subconjunctival tissue and are slow in yielding to usual remedies.

Zincum.—Favorable results have been obtained for the persistent redness of the eye remaining after pustular keratitis; especially if the redness is more marked at the inner angle and worse toward evening and in the open air.

The following remedies have also proved serviceable in scrofulous ophthalmia, though not so commonly called for as the above: Ant. tart., Arg. nit., Caust., Cupr. al., Kali mur., Kreosot., Lach., Petrol., Squilla, and Sulph. iod.

Conjunctivitis Vernalis.—This condition is sometimes called *spring catarrh*, but the name catarrh seems to us wrong, because there is no discharge in this disease. It is characterized by a phlyctenoid eruption on the conjunctival limbus, which becomes a swollen ring, more or less large, encircling the cornea. It is of a pinkish color and looks like gelatine. The swelling and redness are greater at the outer and inner sections of the conjunctiva. The inner surface of the lids is pale and its papillæ are swollen. It affects children especially from the seventh to the twentieth year. The great characteristic of this disease is that it comes on every spring, lasting through the warm weather, and goes off with the cool days of autumn and is entirely absent during the winter months. There is usually but slight photophobia, with occasionally some pain. The disease is rare, but usually is controlled after one or two seasons, without leaving any affection of the cornea behind.

TREATMENT.—See that given for *conjunctivitis phlyctenularis*.

Amyloid Degeneration of the Conjunctiva.—This is a very rare disease which is occasionally confounded with granulations. It consists of a hypertrophy of the mucous membrane, especially of the upper cul-de-sacs and semilunar folds, which become of so great a thickness as to often protrude between the lids. The conjunctiva appears like a yellow gelatinous-looking mass, in the substance of which are semi-transparent granules, which are usually larger and more transparent than the granules of trachoma. On everting the lid the tarsus appears as though covered with wax. The tarsus is

itself thickened and metamorphosed. This condition differs from granulations by being confined to one portion of the conjunctiva. We may frequently find effusions of blood in this disease from degeneration of the capillary walls.

TREATMENT.—Excision of the mass.

Xerosis Conjunctivæ is a dryness of the conjunctiva from atrophy, where the whole stroma of the conjunctiva is affected it is called *parenchymatous*, and where the atrophy is superficial it may be called *partial* or *epithelial*. When confined to only a part of the mucous membrane it is called *xerosis glabra*, and when it occupies the entire structure, *xerosis squamosa*, and in the latter the cornea is usually affected, when it is termed *xerophthalmia*. This condition is usually caused by inflammations that leave cicatrices, as in diphtheritic and granular conjunctivitis and burns of the conjunctiva. Idiopathic parenchymatous xerosis is extremely rare, but may occur as a sequelæ of the desquamative skin diseases, especially psoriasis and pemphigus.

Epithelial xerosis is more common, and is usually a sequelæ of conjunctivitis vernalis, although it may be idiopathic. In this form we may find grayish-white patches of a satin-like lustre on the conjunctiva and most often on that part of the ocular conjunctiva left uncovered when the lids are opened.

In complete xerosis the conjunctiva is pale and dry, with small scales; the cul-de-sacs and semi-lunar folds are obliterated and the palpebral conjunctiva is directly continuous with that of the eyeball. The cornea is opaque, atrophied and diminished in all of its diameters. The Meibomian glands are atrophied, the ducts of the lachrymal gland and the puncta lachrymalis are obliterated. The absence of secretion causes dryness of the eye and the movements are limited by the retraction of the mucous membrane and the adhesions.

TREATMENT.—Can only be palliative, that is, ameliorate the excessive dryness which gives rise to so much heat and pain. Milk answers the purpose very well, or a weak solution of glycerine and water, to which one per cent. of salt should be added. Artificial serum is perhaps better still. "Cold expressed castor-oil has also proved effectual."—*Thomas*.

Pterygium.—Is a vascular triangular thickening of a portion of

the conjunctiva. Its apex rests on the edge of the cornea. It may be movable or adherent to the globe, and its width varies. The most frequent location of a pterygium is over the internal rectus muscle, less frequently over the external rectus and still more rarely it may be found occurring above or below. It is called *membranous* when thin and not inflamed, and *sarcomatous* when thick and accompanied by more or less conjunctival catarrh. Pterygium has a tendency to spread over the cornea, though rarely seen to grow beyond the centre of the pupil.

CAUSES.—Arlt says that they are due to small ulcers at the corneal margin which, in cicatrization, draws the epithelium of the conjunctiva forward, which then folds upon itself and becomes inflamed and vascular. Horner says that it is the result of a pinguecula, forming a cavity between it and the corneal margin in which secretions and small foreign bodies become lodged; that these then cause ulcerations at the corneal border, which, in cicatrization, draws the pinguecula upon the cornea. It occurs mostly in individuals who are exposed to constant irritation of the conjunctiva, from dust, etc., and are usually found in adults.

PROGNOSIS.—Depends on the extent of the cornea involved and the tendency to progress. It is harmless so long as it does not extend to the pupil, although the cornea is infiltrated, or the constituency of its layers altered beyond the apparent apex of the growth. The cornea remains opaque after its removal and the growth may recur.

TREATMENT.—This disease, is said to have yielded to the proper homœopathic remedy, though as a rule operative measures will have to be resorted to. Numerous methods have been advocated, chief among which are excision, ligation and transplantation.

Excision is perhaps the best and most frequently performed. The pterygium is raised with the forceps, a narrow knife is passed under the growth and a cut made to the corneal border; then, with a strabismus hook, pull it off from the cornea and with the scissors cut off at the base with converging incisions and unite the edges of the membrane with sutures—usually three.

Ligation is performed with a thread having a needle at each end. Raise the growth with the forceps and pass one needle from above downward under the growth near the cornea and the other at the

base of the pterygium ; now cut off your needles and tie the sutures ; one takes in the base, the second the apex and the third detaches it from its posterior surface.

Transplantation is by detaching from the cornea and sclera so that it adheres only by the base, then make an incision in the conjunctiva below and parallel to the cornea and fasten the apex of the growth in this incision with sutures. When large it may be divided and inserted half above and half below the cornea.

Calcarea carb.—Especially indicated in *pterygium caused from exposure to wet and cold*.

Chimaphila.—This drug has been used in many cases in which no marked indications have been present with some success, though it has also often failed to improve.

Zincum.—Zinc has been more frequently employed and with greater satisfaction than any other remedy, especially in that form of pterygium which extends from the inner canthus (as it usually does), for the majority of the eye symptoms are found at the inner angle, as will be noticed by examination of the provings. The lachrymation is usually profuse and photophobia marked, especially by artificial light. The pains are pricking, with *itching and soreness in the inner angle* worse at night ; also itching and heat in the eyes, worse in the cold air and better in a warm room ; external canthi cracked ; green halo around the evening light. There may also be present great *pressure across the root of the nose* and supraorbital region.

The following remedies are also reported to have been employed with advantage in the treatment of pterygium when suggested by constitutional symptoms or certain general characteristic eye indications : Argent. nit., Arsen., Cannabis, Psor., Ratan., Spig. and Sulph.

Subconjunctival Effusions.—Often result from some inflammatory condition of the conjunctiva, but we may have the ocular conjunctiva chemosed from inflammations deep within the eye, as in purulent choroiditis, if there is stoppage of the venous circulation. May be from inflammation of the lids, as in hordeolum, from the same cause. Serum from the anterior chamber may have filtered through an old cicatrix or fistula and caused a chemosis ; also seen in old men or weak, anæmic women. Cardiac and renal disease may cause it.

Purulent effusions or abscesses are very rarely met with separate from inflammation. Most frequently found on the caruncle and it arises from spots of acne induced by retained secretions of the glands.

Ecchymosis, or effusions of blood, come from a blow, operations, or anything causing cranial congestions—the lifting of weights, coughing, vomiting, etc. May result from atheromata. Appears as a patch or a deep red ring around the cornea. Looks alarming, but is generally of no importance, gradually disappearing of its own accord and presenting various shades during the process of absorption.

TREATMENT.—Applications of cold water, ice compresses, or a solution of one of the following remedies are advised, unless due to some chemical injury.

A compress bandage sometimes seems to hasten the absorption of hæmorrhages into the conjunctiva.

Aconite.—There is no remedy more frequently useful than this in *inflammatory conditions of the eye resulting from the irritant action of foreign bodies*, as cinders, chips of steel, stone or coal, which produce a variable amount of redness and pain, with a sensation of *dryness, heat and burning* in the eye.

Arnica.—An important remedy for *traumatic conjunctivitis or keratitis, following blows and various injuries* of the eye. It is particularly called for *immediately* after the injury, before the inflammatory symptoms have really set in, though is also useful in the latter stages. Both spontaneous and traumatic hæmorrhages into the conjunctiva have been promptly absorbed under the use of Arnica. The relaxation of the bloodvessels and too fluid conditions of the blood, which predispose to these hæmorrhages in whooping cough, have seemed to be corrected by this drug.

Calendula.—Useful in traumatic inflammation of the conjunctiva or cornea *following any operation* or resulting from a cut wound of any description.

Cantharis.—*Ophthalmia traumatica caused from any burn*, as from the flame of a candle, explosion of fireworks, etc., especially if characterized by much *burning pain* in the eye.

Hamamelis virg.—Has proved very beneficial in traumatic conjunctivitis and keratitis consequent upon burns or other injuries. It

also seems to hasten the absorption of conjunctival hæmorrhages. "Pond's Extract" may be used locally.

Ledum pal.—Is more commonly called for in both *traumatic and spontaneous ecchymoses of the conjunctiva* than any other remedy. It also often seems to correct the tendency to hæmorrhage in these cases. Of value in inflammation of the conjunctiva in which extravasations of blood predominate.

Any of the above remedies, with perhaps the exception of *Cantharis*, should always be used locally as well as internally in the proportion of from ten to twenty drops of the tincture to the ounce of water. Compresses wet in this should be laid upon the eye.

Euph., *Hep.*, *Ign.*, *Nux.*, *Rhus.*, *Sil.* and other remedies may prove serviceable when special indications point to their use.

Subconjunctival Emphysema.—This is a puffy condition of the conjunctiva in which there is a sensation of crepitus on pressure and a swelling, which disappears on pressure. It is of diagnostic value in other diseases, as it may be due to fracture of the orbital wall, opening a communication between the subconjunctival tissue and the nasal fossa, the frontal sinus or the ethmoidal cells. It also may occur from rupture of the lachrymal sac or tear passage, which allows the air to enter the tissues on blowing the nose.

Tuberculosis Conjunctivæ.—This disease is of rare occurrence, but that it does occur has been demonstrated by microscopical investigation. Knapp¹ produced tuberculous disease in the eyes of rabbits by inoculation from a case of tuberculosis of the conjunctiva. The lymphatic glands of the neck on the same side as the affected eye are apt to be involved. The disease usually occurs in young subjects and is apt to affect but one eye. There is a thickening of the eyelids, the swelling is somewhat reddened and of a soft, elastic feeling. On everting the lid the conjunctiva appears covered with exuberant granulations of a grayish-red color which are somewhat flattened and of a nodular appearance. There may also be one or more ulcerations in the palpebral conjunctiva. These granulations seem to spring especially from the retro-tarsal fold and are accompanied by a profuse purulent secretion. The cornea may become affected by pannus. A positive diagnosis can only be made after a micro-

¹ *Archiv. Ophthalm.*, vol. xix., 1, 1890.

scopical examination. Swan M. Burnett¹ reports a case that was undoubtedly of primary origin, and argues that the condition is more often primary than secondary.

TREATMENT.—Fontan² advises seraping out the nodules and dusting iodoform upon them. The use of the galvano cautery, as well as the knife to destroy the local products, is recommended by Knapp (*loc. cit.*). Internal medication, such as is used in tuberculous conditions elsewhere, should be followed.

Lesions of the Conjunctiva.—*Foreign bodies* penetrate the conjunctiva and may cause irritation, if not removed early. They are mostly found in the superior cul-de-sacs or in the palpebral conjunctiva, and rarely in the ocular conjunctiva. If allowed to remain, they set up hyperæmia and catarrhal conjunctivitis. They should be removed.

Wounds from sharp instruments, so long as they do not involve other structures, are not important and readily heal. When extensive, clean the wound carefully, unite the edges with sutures and apply cold compresses.

From burns and cauterisms by chemical reagents there is caused thick, whitish patches that project above the mucous surface and may result in severe pain and inflammation. Danger depends on the size, their influence on the cornea and the amount of cicatrization causing symblepharon.

TREATMENT.—If dependent upon some foreign body which has lodged on the conjunctiva, the first point to be attended to is its removal, which is generally easily effected. After which, directions should be given to bathe the eye in cold water or a weak solution of *Aconite*, *Arnica* or *Calendula*. This will usually suffice, though in severe cases it may be advisable to drop a little olive oil into the eye after removing the foreign body.

Chemical injuries, especially from lime, are, unfortunately, of frequent occurrence and very dangerous in their nature on account of the formation of deep sloughs, which have a great tendency to result in symblepharon. If seen early, we should endeavor to remove as much as possible of the lime and then drop into the eye either a little olive oil, oil of sweet almonds, milk, weak solution of vinegar,

¹ Archiv. Ophthal., vol. xix., 2, 1890.

² Rec. d'ophth., No. 10, 1886.

or some substance which will unite with the lime and form an innocuous compound. Water should never be employed. Great care should be taken while the wound is healing that no adhesions between the lids and ball occur. If there is a tendency in this direction, the adhesions should be broken up once or twice a day by means of a probe.

When the injury is from strong acids, as sulphuric or nitric, the eye should be syringed out with a weak solution of carbonate of soda or potassa (℞j to ℥vi aq. destil.) in order to neutralize the acid; afterwards olive oil should be dropped in.

Tumors of the Conjunctiva.—Nearly all varieties of tumors, either benign or malignant, may occur in the conjunctiva, and will be but briefly referred to.

Pinguecula is a yellowish-white swelling, the size varying from that of a pin-head to a pea, situated usually on the nasal side and near to the cornea. It is formed of cellular tissue with elastic fibres and blood vessels, and is covered with a thick epithelial layer. It contains no fat as is usually considered from the appearance of the swelling. They are due to erosions from foreign bodies, are of no importance and need no treatment.

Dermoid Tumors are small, smooth and of a yellowish-gray appearance, of a size varying from a pea to a hazel nut and are located at the margin of, and growing some upon the cornea. They are especially apt to be found at the lower and outer border of the cornea and hairs are sometimes seen growing from them. They consist of non-nuclear cellular tissue, with elastic fibres, sometimes follicles and fat cells, and are covered by a thick layer of epithelium. They are congenital, have a tendency to increase in size and are apt to recur, if not all removed. They should be removed for cosmetic purposes and because they are liable to gradually encroach more and more upon the cornea. Remove with a cataract knife, first from the cornea and then from the sclerotic. They enter very deep into the substance of the cornea, but it suffices to remove on a level with the cornea.

Lipomata is another rare, congenital and benign tumor which is most frequently found to the outer side, either above or below the external rectus muscle. They appear as flat, yellow swellings, and are apparently extensions of the fatty tissue of the orbit. They do

not disfigure much or interfere with the movements of the eye and should not be touched.

Vascular Tumors.—These are very rare, but we do meet them occasionally as a small triangular-shaped elevation of the conjunctiva which causes deformity by their bright red appearance. They are most frequently found associated with vascular dilatations of the face or nose. They should be carefully removed by electrolysis.

Angiomata spring from the caruncle or cul-de-sacs, and are seldom large enough to require removal; but, when they do, may be removed by suture or electrolysis.

Fleshy Excrescences are usually from wounds or operations and should be removed.

Cysts are round, circumscribed, rose-colored tumors. They are semi-transparent and may take on a yellowish hue, sometimes grow to the size of a bean and contain a thick fluid. They are usually congenital, but may follow a blow on the eye, and should be either incised or removed entire.

Erectile Tumors are usually an extension from a similar tumor of the lid. They should be destroyed by excision, galvano-cautery or electrolysis.

Pigment Spots are quite frequent and harmless. May be excised for cosmetic effect.

Fibromata and *Osteomata* have been found.

Epitheliomata are usually found on the ocular conjunctiva and at first may be mistaken for phlyctenules, but their persistence and the age of the patient will be apt to cause suspicion. When well advanced, they appear usually at the corneal margin as a puffy, reddish lobulated mass and are sometimes ulcerated. Their course varies—they may invade the cornea slowly or rapidly, but will do so sooner or later. They should be removed, and, if they return, the eye must be enucleated.

Sarcoma and Melano-Sarcoma.—The former are generally pedunculated and may cover the cornea without penetrating it. The latter are generally close to the corneal border and are rarely found on the tarsus or in the cul-de-sacs. If they seem to be rapidly progressing, there should be a careful examination made for general infection, and, if convinced that general infection is not imminent, the eye may be enucleated. There is always great danger of the growth returning after an operation, or of metastasis.

Carcinoma are extremely rare; but, when found, should be removed.

Lupus generally spreads to the conjunctiva from other structures and rarely occurs in the conjunctiva primarily. They are usually found on the lid in the form of fungous granulations, a soft doughy mass broken by cicatrices. They should be scraped away thoroughly with a currette and cauterized with nitrate of silver, 1 to 10.

Entozoon or *Cysticercus* may occur under the conjunctiva.

Syphilitic Ulcerations are usually found on the palpebral conjunctiva and cul-de-sacs. They have the usual hard base and indurated edges and give the syphilitic history.

Gummata have also been seen under the conjunctiva. The treatment should be both general and local.

CHAPTER VI.

Diseases of the Cornea.

Anatomy.—The cornea is nearly circular in shape, though slightly more prominent in youth than in old age. It is perfectly transparent and this transparency is due to the arrangement as well as the individual transparency of each of its constituent elements. The cornea is composed of five layers which, taken from without inward, are the anterior epithelial layer, Bowman's membrane, the parenchyma, Descemet's membrane and the posterior endothelial layer.

The *anterior epithelial layer* is like the epithelium in other parts of the body, though in this location it is composed of from six to eight layers of cells, varying in size and shape, with nuclei and nucleoli, the innermost ones having offshoots. This epithelium is more transparent and thicker, but continuous with that of the conjunctiva.

Bowman's membrane is simply a layer of corneal cement containing fibrillæ and fasciculi, but with no lacunæ or lymph canals, and, therefore, has neither fixed cells nor movable corpuscles. It is closely adherent to the parenchyma and cannot be separated from it as a distinct layer.

The *parenchyma* is made up of extremely fine fibrillæ united into fasciculi, a cement substance which binds the fibres and fasciculi together, a system of canals which are a continuation of the lymphatic vessels and spaces and of cells which line these lacunæ or lymphatic canals.

The *fibrillæ* and *fasciculi of fibres* are disposed in layers one above the other, forming in this way a structure made up of lamellæ, about forty in number.

The *cement* is a homogeneous substance binding the fibres and fibrillæ together.

The *corneal canals* are hollowed out of the compact tissue formed by the cement and the fasciculi arranged in lamellæ and are composed of numerous lenticular-shaped shallow spaces communicating

together by offshoots or canaliculi. These canals have no proper lining and vary in size. They run from one layer to another and even penetrate between the fibres, thus forming a network throughout the parenchyma. The canals convey the lymph for the nourishment of the cornea and contain the cells of the cornea, which are of three varieties—the fixed cells or corneal corpuscles, the migratory and the pigment cells.

The *fixed cells* lie in the lacunæ, are flattened, have both nuclei and nucleoli and send prolongations into the canals.

The *migratory cells* are distinguished from the fixed by their large and variable size, their brilliancy and the power of motion. They correspond to leucocytes and increase in number during inflammation.

The *pigment cells* are similar to the fixed cells, found only at the periphery of the cornea and are especially present in negroes.

Descemet's membrane is the inner lining of the parenchyma. It is a structureless, homogeneous membrane, of a glossy appearance and highly refractive. It is firm and elastic, and is supposed to be a condensation of the cement substance of the cornea proper.

The *endothelial layer* consists of a single layer of endothelial cells lining the posterior surface of the membrane of Descemet. The cells are flat and of varying shape. At the periphery of the cornea this layer is reflected upon the ligamentum pectinatum iridis and thence upon the anterior surface of the iris.

Blood vessels are only found on the outskirts of the cornea and are derived from the anterior ciliary arteries.

The nerves of the cornea, about forty in number, penetrate its tissue, lose their neurilemma, become transparent and divide dichotomously to form large plexuses, especially in the anterior epithelial layer.

Inflammation of the Cornea may be either primary or secondary to inflammations of other tissues. It may induce inflammation of the adjacent structures, such as the conjunctiva, iris, ciliary body, etc., or it may exist with inflammations of these structures.

Inflammation of the cornea is diagnosed by increased ciliary injection, a decreased transparency, a loss of lustre of the cornea or by ulceration. Vision is more or less disturbed, according to the location of the inflammatory focus, by the dispersion, absorption or

irregular refraction of light. Keratitis is perhaps one of the most frequent diseases of the eye; it is also, considering the function of the eye, one of its most important affections. It endangers the function and also the form of the eye in many ways, viz.: by causing incurable opacities, by a permanent change in its convexity, by perforation and its sequelæ; by inducing iritis, irido-cyclitis, etc.; by destruction of a portion or the whole of the cornea; by destruction of the form of the entire globe, as in staphyloma, phthisis bulbi, etc.; or, again, keratitis may run its course, leaving no bad results.

Keratitis Phlyctenularis.—(*Eczema Corneæ*, *Scrofulous*, *Strumous*, or *Pustular Keratitis*.)

PATHOLOGY.—Consists of a circumscribed infiltration of leucocytes into Bowman's layer. This infiltration is always confined to the parts surrounding a nerve-branch as it pierces the epithelial layer. This simple local infiltration generally results in local purulent keratitis, with a loss of substance and the formation of a scar.

SYMPTOMS.—We will first notice small, grayish elevations upon some part of the cornea, usually the periphery, varying in size—perhaps, as a rule, about one-half the size of the head of a pin. There may be one such elevation or a row of them extending around the cornea. There will be a redness which may encircle the entire cornea, or more often, where there is but one phlyctenule, confined to the quadrant of the eye affected and assuming a more or less triangular-shaped injection, the apex of which will be at the point of infiltration. The conjunctiva is often more or less inflamed, may be swollen and secretes a muco-purulent discharge. The photophobia is often so intense that the child will bury its face away from the light and it will be found difficult to open the eye for examination. Again, other cases will be met with in which there is not the slightest photophobia. The appearance of the vesicle is generally preceded or accompanied by a sense of heat and itching in the eyelids, lachrymation and ciliary neuralgia. Sometimes the phlyctenules are very superficial and appear as small, transparent vesicles, whose epithelial covering is soon shed, leaving a small excoriation which may easily escape detection. Generally, however, the infiltration is more apparent and is surrounded by a zone of opaque and swollen cornea; the apex breaking down, it extends in circumference and depth and forms an ulcer which usually becomes covered with a layer of epi-

thelium and gradually fills up, the cornea regaining more or less of its transparency.

COURSE.—Is usually acute, though it may be very chronic, as there is a great tendency to relapses. Just as the symptoms of irritation and vascularity are subsiding, the phlyctenule disappearing and the disease seems to be almost cured, all the acute symptoms return, a fresh crop of pustules make their appearance and a severe relapse takes place. This may occur again and again and the affection assume a chronic character.

CAUSES.—It is most frequently found in children and young persons of a weakly, scrofulous constitution and those of a nervous, excitable temperament. It is often found after the exanthematous diseases or in eczema of the face, from confinement in close, dusty rooms, after exposure to cold or moisture.

PROGNOSIS.—Depends upon the course and extent of the disease. When due to scrofula, there will probably be relapses and more or less loss of sight will occur from macula, if the location be central. Each attack in itself should be promptly treated, when it will usually heal in a short time, as it yields readily to treatment.

TREATMENT.—As the treatment of this disease is precisely the same as that for conjunctivitis phlyctenularis, what is there said of treatment applies as well to keratitis phlyctenularis and avoids unnecessary repetition. (See *conjunctivitis phlyctenularis*, page 126.)

Keratitis Fascicularis.—This disease is very similar to and may occur with phlyctenular keratitis. It consists of a vascularized infiltration in which there is a narrow band of vessels running parallel to each other and extending into the cornea. At the end of this fasciculus of vessels there is a more or less crescentic-shaped infiltration, which is often ulcerated. There is usually but one such infiltration, although several may occur at the same time. There are the usual symptoms of pericorneal injection, photophobia and lachrymation. The affection is mostly found in scrofulous children and its treatment is the same as that for phlyctenular keratitis. The yellow oxide of mercury ointment is often of especial value in this form of keratitis.

Keratitis Pannosa is a vascular superficial inflammation of the cornea.

PATHOLOGY.—There is a formation of a neoplastic layer of cells

beneath the epithelium and also in the corneal layers just beneath Bowman's membrane. These cells develop into connective tissue and blood vessels with capillaries form in them. There are two sets of these vessels—one a venous set continuous with the conjunctival vessels, and a deeper arterial layer arising from the conjunctival and sub-conjunctival vessels. Where the cornea is very red, opaque and of a fleshy appearance, it is called *pannus crassus*; if the blood vessels are few and the cloudiness is slight, it is then called *pannus tenuis*.

SYMPTOMS AND COURSE.—In the acute form of the disease we may find photophobia, lachrymation, ciliary neuralgia and both conjunctival and sub-conjunctival injection. When it becomes chronic, the irritability is but slight. The cornea becomes opaque, rough and hypertrophied. The disease usually extends from the periphery to the centre, but it may be the reverse. Superficial and even deep ulcers may form in the pannus. The cornea may become bulged from a long-existing pannus, causing a thinning and weakening of the cornea; or the reverse, flattening and atrophy of the cornea may ensue from sclerosis and contraction of the new tissue within the corneal layers.

CAUSES.—In a large majority of the cases it is due to trachoma, and is produced by the friction of the roughened conjunctiva on the cornea. From this cause the disease is usually confined to the upper half of the cornea, or affects that portion first. Pannus may also result from phlyctenular or purulent ophthalmia; from the friction and irritation due to inverted eyelashes, entropium or chalazion, or from exposure to external irritants, as in lagophthalmos.

PROGNOSIS.—If the case is recent and inconsiderable and the cause remediable, the prognosis is favorable; but in chronic cases the normal transparency of the cornea can never be restored and the ultimate effect upon the vision will depend upon the extent of the corneal invasion.

TREATMENT.—This should, of course, be mainly directed to the cause of the pannus, as elsewhere described. The general health should be promoted and the eyes may be protected from all intense light. In some of the indolent cases, where the pannus is dense and does not clear up after the relief of the cause, the use of warm fomentations applied for about one-half hour at a time, two or three times a day, together with the yellow oxide ointment, may be of service. *Atropine* may be of service where the vascularity is exces-

sive and should be used when there is a tendency to iritic complications. *Eserine*, however, seems to have a directly beneficial result as an aid to the healing process; but in using *eserine* the iris must be carefully watched for pupillary adhesions. The operation of syn-
 dectomy, in all cases due to trachoma where the cornea remains opaque and vascular after the granular lids have passed over into the cicatricial stage, may sometimes be very serviceable. The operation consists in dissecting away a narrow strip of the conjunctiva close to the corneal border for either a portion or the entire circumference of the cornea.

The administration of the homœopathic remedy is, however, the most essential part of the treatment. *Acon.*, *Aurum*, *Hepar.*, *Merc. sol.*, *Rhus tox.* and *Sulphur* are perhaps the ones most often of value. For special indications for the use of these and other drugs, see treatment of *ulcus corneæ*.

Keratitis Vesiculosa (*Herpes Corneæ*).—Small, roundish vesicles filled with serum appear upon the surface of the cornea. There may be one or many of these vesicles grouped together and usually in but one eye. They are due to a circumscribed upraising of the epithelium, in which a thin layer of the cement substance takes part. The disease appears in paroxysms, with very severe pain, which is only relieved upon the shedding of the vesicular envelope and the formation of a slight excoriation.

CAUSE.—The cause of this affection is probably some inflammatory change in the fifth nerve, as evidenced by its frequent association with ophthalmic herpes zoster, and also by the fact that the severe neuralgic pain usually precedes and often continues after the vesicles are healed. The disease is periodic, subject to relapses and leads to no serious lesion. It is accompanied by little or no inflammatory symptoms and the presence of the vesicle from its small size and transparency is often difficult to recognize.

The *treatment* should be by the application of warm fomentations, instillations of cocaine, electricity and the removal of the epithelial covering of the vesicle with forceps.

Ulcus Corneæ.—The clinical sub-divisions of corneal ulcers are almost innumerable, it seeming from examination of the various text-books as though each author strove to find some new name for each differently located or shaped ulceration of the cornea. It has,

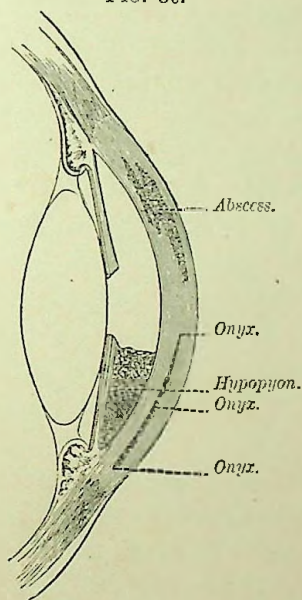
therefore, been thought best to place the general study of all ulcers under one heading, with brief mention of one or two of the more distinctive varieties to follow.

PATHOLOGY.—The pathological changes in an ulceration of the cornea are, of course, the same in all cases (irrespective of any clinical sub-divisions), with the exception or variation as to the extent or amount of tissue involved, and hence the following description is applicable to all forms of corneal ulcerations: There is at first an infiltration of leucocytes into the cornea lamellæ lying next to Bowman's membrane. The number of these cells increase and Bowman's layer, together with the epithelium, becomes raised and the latter begins to decay. The destruction is first noticed in the epithelial layer, then the lamellæ and Bowman's membrane become destroyed and an ulcer is formed. The base of the ulcer is covered with pus, its walls are ragged and the adjoining tissue is filled with round cells. The epithelium surrounding the ulcer is thickened from proliferation of its cells. The lamellæ, forming the base and walls of the ulcer, become bent toward the surface at an angle of about 45° . The ulcer from this stage may progress by the surrounding parts becoming more and more infiltrated and destroyed as described, or it may proceed to reparation, in which case the bottom of the ulcer cleanses itself and its margins lose their ragged appearance. This is followed by a marked and rapid proliferation of the epithelium extending from the sides over the walls and base of the ulcer, while at the same time a new and delicate connective-tissue formation is taking place upon the base of the ulcer beneath the epithelium and gradually pushing it forward until it has completely filled up the ulceration, so that the new epithelial layer becomes continuous with that of the healthy cornea. The new epithelial cells are mostly round, though sometimes cylindrical or spindle-shaped. This new formed tissue later becomes more dense and tough and assumes somewhat of a lamellar arrangement, but the lamellæ are smaller, more irregular and intersect at obtuse angles. This new tissue is translucent, and, although it may clear up somewhat, it never becomes perfectly transparent. If the ulceration extends, growing deeper and deeper, there is first a protrusion of Descemet's membrane (keratocele), due to the loss of substance, causing a diminished resistance to the intra-ocular pressure, and later a perforation of the cornea

with a prolapse of the iris into the corneal wound, where it may become attached.

SYMPTOMS.—The first objective symptom noticed is that the patient usually enters the room with the eyes wholly or partially closed from the dread of light, and, upon attempting to examine the eye, as we raise the lid the eye rolls upward in order to hide from the light and a flow of tears will result as the light strikes the eye. As a reverse to this, which may be called the usual occurrence, we may sometimes find cases with the eyes widely open and without the

FIG. 30.



Vertical Section Through Anterior Part of the Globe.

slightest photophobia. On opening the eye we are attracted to the redness of the eye, which is due to the injection of both the conjunctival and sub-conjunctival vessels and which varies greatly in degree. Then, upon examination of the cornea, we find at some point a loss of corneal substance, that is, instead of seeing the normal, smooth, glistening epithelial layer, we notice a depression which is opaque, saturated with pus and has ragged edges. The depression is usually irregular, though of a general circular shape. The corneal tissue is also opaque for a varying extent around the

ulcer from purulent infiltration of its lamellæ. Sometimes one or more blood vessels may be seen running to the ulcer from the corneal margin. There may also be present a collection of pus in the anterior chamber (hypopyon) or a burrowing of pus in the substance of the cornea (onyx) (Fig. 30) or a bulging of Descemet's membrane in the base of the ulcer (keratocele).

Subjectively the patient will usually complain of more or less intense photophobia, lachrymation and ciliary neuralgia, all due to an exposure of the terminal filaments of the corneal nerves from loss of substance, and from this we will sometimes find a slight superficial ulceration, creating more disturbance than will sometimes be present in a deeper and far more serious ulcer. When situated near the centre of the cornea the vision is much interfered with, and when more peripheral the vision is but slightly, if at all, affected.

COURSE.—In a majority of cases the course of an ulcer is acute and rapid, but in others it may be chronic and protracted, obstinately defying all treatment until perhaps perforation has taken place, when it will at once begin to heal. Occasionally there will be met cases of slight superficial ulceration, hardly more than abrasions of the epithelium, with but very little redness, yet the most intense photophobia (so much that the child will lay all day with the head buried from the light) which will last for months without in the least yielding to treatment.

CAUSES.—Corneal ulcers frequently occur from some form of conjunctivitis, and are apt to vary in degree, according to the severity of the conjunctival disease, from a superficial abrasion to a slough of the entire cornea. Injuries may lead to ulcerations of the cornea in various ways. A foreign body removed by inflammation and suppuration leaves an ulcer. Wounds or operations may result in ulcerations when the healing by first intention is prevented by impurities, by re-opening, or by bad adaptation of the wound. Chemical agents may produce a slough. Friction of the cornea, from inverted eyelashes, from calcareous concretions or foreign bodies in the tarsal conjunctiva or colds, may cause either an ulcer or an abscess. Paralysis of the orbicularis palpebrarum, ectropium, exophthalmic goitre, etc., cause ulcerations from exposure of the cornea to external irritants. Deficient nutrition in children, and the exanthematous diseases are very common causes of ulcers.

PROGNOSIS.—This depends upon the condition of the ulcer, and upon the age and general condition of the patient. Ulcers that have advanced as far as Descemet's membrane always leave an opacity. Superficial ulcerations are far more favorable as to the resulting opacities than are deep ones. Ulcers that heal with vascularization of the cornea leave opacities. In children and youth there is always a more complete regeneration than in advanced age. Ulcerations from ophthalmic neonatorum may heal with only a slight opacity. In old or debilitated persons there is often a more extensive opacity than would be expected from appearance. Irritants, such as dust, smoke, etc., increase the density of an opacity.

RESULTS.—If an ulceration extends and causes a perforation of the cornea, a long train of results may follow. When the perforation occurs, the aqueous flows off and the iris and lens come forward into apposition with the cornea. If the perforation is small, as the anterior chamber refills, the iris may be forced backward into place and the cornea heal with no synechia, but, in larger perforations, the iris falls into its margins, or bulges through, and, the cornea healing, it is held there as a synechia or prolapsed iris; the latter, exposed to external irritants, may become purulently inflamed and be the starting point of a purulent irido-choroiditis. If the entire cornea is destroyed there is a total adhesion of the iris to the cornea (*leucoma adherens*) and the new cicatricial tissue may not withstand the intraocular pressure, and staphyloma, either partial or total, results. Instead of staphyloma resulting from the cicatricial tissue, it may flatten and atrophy of the globe follow. If the rupture of the cornea is extensive and sudden, from a fit of coughing, sneezing, etc., there may occur a dislocation of the lens, a prolapse of the vitreous, or an intraocular hæmorrhage. Occasionally a perforation will not heal, leaving a fistula of the cornea. An anterior capsular cataract may result from a central perforation.

TREATMENT.—Superficial ulcerations of the cornea will not usually require local treatment, unless caused by granular lids (see *conjunctivitis trachomatosa*, page 117), or by entropium, inverted lashes, etc., in which case the cause must, of course, be first removed. Severe cases, not dependent upon granular lids or traumatic causes, will be greatly improved by the use of a *bandage*. *Atropine* may be of service in rare cases, with much photophobia and deep ciliary

injection, though it is not commonly necessary under appropriate homœopathic treatment. If the palpebral aperture is much shortened and the eyelids thus press upon the eyeball, the outer canthns may be divided (canthoplasty) so as to relieve the increased pressure on the cornea.

In the treatment of ulcers and abscesses of the cornea, local and dietetic measures are of great importance. If the ulcer is extensive, the patient should be directed to remain quiet in the house (in bed, if possible), that absolute rest may be obtained. As this disease is more often found in weak, debilitated subjects, a very nutritious diet should be prescribed, and it may even be necessary to use stimulants ; in these cases, the concentrated tincture of *avena sativa*, ten-drop doses four times a day, or the use of *cod-liver oil*, will be found of great service.

As a rule, *cold applications* are injurious, except occasionally in the first or inflammatory stage of superficial keratitis, or in ulceration of the cornea occurring during the course of pannus. *Hot poultices* also are not advised, except in indolent ulcers which are deep, non-vascular and have no tendency to heal, in which they may often be employed with advantage.

Bandaging, upon the other hand, is of the utmost importance in the treatment, even, in some cases, producing a cure alone. In all cases in which the ulcer or abscess is deep, or obstinate to treatment, a protective bandage should be immediately applied. It is usually sufficient to bandage only the affected eye (if one be healthy), unless the ulcer be very deep and extensive, when both eyes should be covered. The objects of the bandage are: to keep the eye quiet and protected by its natural coverings, the lids, from all irritating causes, such as wind, dust, etc., and to keep the eye warm, in order to promote local nutrition. The bandage is also of much value when the ulcer is deep and shows a tendency to perforate; it then serves to support the thinned portion of the cornea against the intraocular pressure.

Atropine is not usually required in ulcers or abscesses of the cornea, unless the ulcer is central and has a tendency to perforate, or if iritis complicates the corneal trouble; then Atropine should be employed until full dilatation of the pupil is produced, which should be maintained. It may also be of service in relieving the great irri-

tability and intense photophobia observed in some obstinate forms of corneal inflammation.

Eserine should be instilled if the ulcer tends toward perforation at the periphery, or if the intraocular tension becomes increased.

External applications are rarely necessary, though sometimes good results have followed the external use of the same drug that is prescribed internally. *Aqua chlorinii* used locally has proved beneficial in some cases, especially in the crescentic form and when the discharge of pus has been profuse. It may be used pure, or diluted one-half, one-third, or even more. The peroxide of hydrogen and pyoktanin may also prove of much service in cases where the ulcer is accompanied by a considerable purulent discharge.

In those cases in which the ulcer is deep, with a great tendency to perforate, *Sæmisch's incision* is recommended. It consists in cutting through the base of the ulcer into the anterior chamber with a Graefe cataract knife, which is entered in the healthy tissue on one side and brought out in the healthy tissue on the other side of the ulceration, which is then divided by a sawing movement of the knife, after which Atropine is instilled and a compress bandage applied. The wound can be kept open by the aid of a spatula or Daviel's spoon, for two or three days if desirable.

Paracentesis may also be resorted to in the above cases, though it has been nearly supplanted by Sæmisch's incision, which, in the majority of instances, is far preferable. The puncture should be made with a fine needle, through the deepest portion of the ulcer, the aqueous allowed to flow off as gently as possible and a compress bandage applied. It is not necessary to wait too long before making a paracentesis, as it aids repair by relieving the pressure from intraocular tension and may be repeated several times, if necessary. Feilchenfeld¹ claims good results from scratching out superficial corneal ulcers with a gouge or needle and then applying an antiseptic dressing. All ulcers should be closely watched, that we may detect any hernia of the cornea or prolapse of the iris as soon as they occur. If a prolapse has taken place and is of recent origin, we should endeavor to replace it, either by dilating or contracting the pupil according to its situation; if this proves inadequate, the protruding

¹ Zehender's klin. Monatsbl. f. Augenheilk., vol. xxviii., p. 502.

iris should be snipped off with a pair of scissors, Atropine instilled and a pressure bandage applied.

Aconite.—Superficial ulceration of the cornea of *traumatic origin*. First stage of ulceration caused from exposure in the open air. Conjunctiva very red, chemosis, photophobia and lachrymation; or, more commonly, the eye is *dry, hot, burning* and very sensitive to air. Patient restless, feverish and thirsty.

Apis.—Ulcerations of the cornea, vascular, with photophobia, hot lachrymation and burning, *stinging pains*; sometimes the pains are very severe and *shoot* through the eye, with swollen, *œdematous condition of the lids* and conjunctiva. Patient drowsy and thirstless.

Argent. nit.—*Ulceration of the cornea in new-born infants, or from any form of purulent ophthalmia, with profuse discharge from the eyes.* Ulceration with pains like darts through the eye morning and evening. The pains are usually better in the cool, open air and aggravated in a warm room. The lids are generally red, thick and swollen; conjunctiva œdematous and there is a *profuse discharge of yellowish-white pus*.

Arnica.—Traumatic ulceration with much *hæmorrhage into the anterior chamber*. (Superficial traumatic ulcerations generally yield more readily to Aconite).

Arsenicum.—Especially when found in scrofulous, anæmic, restless children. The ulceration is chiefly superficial and has a tendency to recur first in one eye and then in the other.

The *photophobia is usually excessive* and the *lachrymation hot, burning, acrid and profuse*. The pains are *burning, sticking*; there may be throbbing, pulsating, or tearing, around the eye, *worse at night*. The *burning pains* predominate and are worse *at night, especially after midnight*, when the child becomes very restless and cross. Bathing in cold water often aggravates, while warm water may relieve. Eyeballs sore to touch. Conjunctiva quite red; chemosis. *Marked soreness on the internal surface of the lids*, which are swollen externally (œdematous), spasmodically closed and often *excoriated by the acrid discharges*.

Asafœtida.—Ulceration, accompanied by iritic pains which *extend from within outward, and are relieved by rest and pressure*.

Aurum.—Ulceration of the cornea, especially occurring during the course of *pannus* or scrofulous ophthalmia. Cornea quite vas-

ular, and the patient very irritable and sensitive to noise. Cervical glands often enlarged and inflamed. The *photophobia* is marked, *lachrymation profuse and scalding and the eyes very sensitive to touch*. The pains extend from without inward and are worse on touch (reverse of *Asaf.*).

Belladonna.—Superficial ulceration of the cornea, with intense photophobia and some throbbing pain, aggravated afternoon and evening.

Calcareæ carb.—Particularly valuable for *corneal ulcerations found in fat, unhealthy children* with large abdomens, who sweat much, especially about the head and are very susceptible to cold air; also in deep, sloughing ulcers, found in weak, cachectic individuals. The pains, redness, photophobia and lachrymation are variable, and, though it is a prominent remedy for this disorder, there are no characteristic eye symptoms and we are guided in its selection chiefly by concomitant indications.

Calc. hypophos.—This preparation of lime is most commonly called for in *deep sloughing ulcers* or abscesses found in weak, debilitated individuals. Especially indicated in *crescentic ulcers* following purulent conjunctivitis.

Calc. iod.—Ulcerations in strumous subjects, with enlargement of the tonsils and cervical glands.

Cantharis.—Superficial ulceration caused by burns, with burning pain and lachrymation.

Chamomilla.—Ulceration occurring in cross, peevish children during dentition.

Chinin. mur.—Ulceration of the cornea of *malarial origin* or dependent upon *anæmic conditions*, especially if the iris has become affected and there are *severe pains*, either in or above the eye, *periodic in character* and accompanied by chills. Ulcers found in the course of pannus, with much pain in the morning.

Cimicifuga.—Ulcers with *sharp, neuralgic pains through the eye into the head*.

Cinnabaris.—When accompanied by that characteristic *pain above the eye, extending from the internal to the external canthus or running around the eye*. This pain varies greatly both in intensity and character. Photophobia and lachrymation are usually present.

Conium.—An important remedy in superficial ulceration in which the *surface* of the cornea only is abraded. Thus, owing to the exposure of the terminal filaments of the nerves or to hyperæsthesia, there is *intense photophobia* and much lachrymation. On account of the great photophobia, the lids are spasmodically closed, and when opened a profuse gush of tears occurs (Rhus). The discharges are usually slight and the pains variable, though aggravated by any light. But, notwithstanding all this photophobia, pain and lachrymation, we find upon examination *very little or no redness of the conjunctiva*, not sufficient to account for the great photophobia, which is out of all proportion to the amount of trouble. Strumous conditions, enlarged glands, etc., would assist us.

(Conium¹ has sometimes cured when the high potencies have failed.)

Croton tig.—Ulceration, with marked pain in the supraciliary region at night, especially if accompanied by a *vesicular eruption on the face and lids*.

Cundurango.—Superficial ulceration, with sores or cracks at the corners of the mouth.

Duboisin.—Low form of ulceration, more or less deep, *without photophobia and lachrymation*.

Eserine.—Sloughing ulceration of the cornea, with tendency to increased intra-ocular tension.

Euphrasia.—Superficial ulceration (sometimes with pannus) may be relieved, though it rarely affects beneficially any extensive ulceration, except to palliate the symptoms in the first stage.

Photophobia is generally present, as well as *profuse, acrid, burning lachrymation*, together with *profuse, acrid, yellowish-white, muco-purulent discharge from the eyes*, which makes the lids red and excoriated, giving them and the cheek an appearance as if varnished. The conjunctiva is quite red and the eyes smart and burn. *Blurring of the eyes, relieved by winking*.

Graphites.—A very valuable remedy in ulceration of the cornea, especially occurring in scrofulous children who are covered with eczematous eruptions, particularly on the head and *behind the ears*; eruptions are *moist, fissured and glutinous*. Is especially adapted to *superficial ulcerations resulting from pustules*, though it has also been useful in deep ulcers even with hypopyon. The cornea is more fre-

quently found quite vascular and conjunctiva much injected, though both may be slight in degree. The *photophobia* is usually intense and the lachrymation profuse, but may be very moderate in amount. The pains are variable and the discharges generally thin and exoriating. The lids are sometimes covered with *dry scales* (the edges), though they are more commonly red and sore, with *cracking and bleeding of the external canthi* upon any attempt to open the eyes. Generally accompanying the above symptoms we find an acrid discharge from the nose, which makes the nostrils sore and covered with scabs.

Hamamelis.—When dependent upon a blow or burn, especially when complicated with hæmorrhage into the anterior chamber (*hypæmia*).

Hepar.—This is one of the most frequently indicated remedies for ulcers and abscesses of the cornea, especially for the *deep, sloughing form and when hypopyon is present*. Also useful in acute aggravations of pannus tending toward ulceration.

Some torpid forms of ulcers and abscesses have been benefited, though usually the symptoms are well pronounced when this drug is indicated. There is *intense photophobia*, profuse lachrymation and *great redness of the cornea and conjunctiva*, even chemosis. The *pains are severe and of a throbbing, aching, stinging character, ameliorated by warmth and aggravated by cold or uncovering the eye* and in the evening. There is marked *sensitiveness of the eye to touch*. The lids may be red, swollen, spasmodically closed and *bleed easily upon opening them*. For the absorption of pus in the anterior chamber (*hypopyon*) there is no better remedy than *Hepar*. Cases found in strumous, outrageously cross children, should suggest this drug. Generally symptoms of chilliness, etc., are important.

Ipecac.—Vascular ulceration of the cornea, with *much photophobia*.

Kali bichrom.—Especially of value in those cases of *indolent ulceration*, which prove so intractable to treatment; cases in which there is no active inflammatory process, only a low grade of chronic inflammation, therefore marked by *no photophobia and no redness*. The pains are generally slight and variable and the discharge, if any, of a *stringy* character. Ulcers which have a tendency to bore in, without extending laterally.

Mercurius sol.—Mercury in some one of its preparations is a common prescription for ulcers and abscesses, and as the soluble mercury of Hahnemann is perhaps more commonly employed than any other, we shall describe this more in detail and afterward give simply the variations found in the other forms.

Is adapted to both superficial and deep ulceration, especially in *syphilitic* or strumous subjects. The cornea, at the point of ulceration, is usually quite vascular, though may be surrounded by a grayish opacity, due to infiltration between its layers; the conjunctival redness is also marked. The *dread of light* is generally great, especially of artificial light, and the *lachrymation is profuse, burning and excoriating, while the discharges are thin and acrid* in character. The pains are often severe and vary in character, but are *always aggravated at night*, by damp weather or extreme cold and ameliorated temporarily by cold water. The lids are thick, *red, swollen and excoriated by the acrid discharges*, sensitive to extreme heat or cold and to contact and are forcibly closed. The concomitant symptoms of excoriation of the nostrils, flabby tongue, night-sweats, pain at night, etc., are usually present.

Mercurius corr.—Called for when the above mercurial symptoms are especially severe, particularly if the iris has become involved. The *photophobia, acrid lachrymation, discharges, pains, burning and excoriation of the lids, are excessive* (which are more often found in the serofulous diathesis).

Mercurius dulc.—Deep or superficial ulcers or abscesses found in *pale flabby, strumous children*, with enlarged glands and general serofulous cachexia. Other symptoms vary little from Merc. sol.

Mercurius nitr.—Has been used empirically with excellent success in all kinds of ulceration, both in the acute and chronic, superficial and deep forms, whether accompanied by hypopyon or not, in cases in which there has been much photophobia, and in cases in which there has been none, where there has been much pain and where there has been no pain. In fact, it has been successfully employed in all imaginable forms of the disease, but it seems to act better in those cases in which there is a tendency to the formation of pustules. It is generally prescribed both externally and internally at the same time and in the lower potencies; the first potency in water externally and the third internally.

Mercurius præc. rub.—Ulceration of a cornea covered with pannus, lids granular and usual eye-symptoms of mercury. Aggravation from working over a fire.

Mercurius prot.—*Serpiginous ulceration* of the cornea that commences at the margin and *extends over the whole cornea, or a portion of it, especially the upper part, involving only the superficial layers.* This form of ulceration is more commonly found during the course of *trachoma and pannus*, in which the proto-iodide of mercury has often proved its value. The *vascularity of the cornea and conjunctiva* is usually great, while the *photophobia is excessive.* The pains are the same as those given under *Mercurius sol.* Non-vascular central ulcer of the cornea with pain at night. *A thick yellow coating at the base of the tongue is generally present.*

Natrum mur.—Ulcers that appear *after the use of caustics*, particularly the nitrate of silver. Photophobia usually marked, so that a child will lie with the head buried in the pillows, *lachrymation acrid*, discharges thin and excoriating, lids swollen, eruption around the eye on face which is often *shining*, pains various, though often *sharp and piercing above the eye on looking down*, are the most prominent eye indications. Concomitants will decide our choice.

Nux vom.—*Superficial ulceration* of the cornea characterized by *excessive photophobia, especially in the morning*; during the day is often comparatively free from it. The amount of redness is not usually excessive, though it varies, as does also the character of the pains. Lachrymation is profuse. To be thought of in cases that have been previously over-dosed with medicine, both externally and internally. Neuro-paralytic inflammation of the cornea has been benefited.

Pulsatilla.—Superficial ulcers following phlyctenulæ, especially in females of a mild temperament. *Thick, bland, white or yellow discharge from the eyes and general amelioration of the symptoms in open air.* Small ulcers on the centre of the cornea, with no vascularity and only moderate irritation of the eye.

Rhus tox.—*Superficial keratitis, with excessive photophobia and lachrymation, so that the tears gush out upon opening the spasmodically closed lids*; if a child, will often lie with its face buried in the pillows all day. *Profuse flow of tears* is a very important symptom under this drug, and benefit is frequently derived from its use in

superficial ulceration of the cornea with granular lids in which this symptom is prominent. Keratitis caused from *exposure in the water* often calls for Rhus (Calc.).

The redness of the eye is generally marked, with *chemosis*. *The lids are œdematously swollen, especially the upper*. An eruption may frequently be found around the eye, characteristic of the drug. The symptoms are *generally worse in damp weather and at night after midnight*, therefore the patients are restless at night and disturbed by bad dreams. A rheumatic diathesis would also influence our choice.

Silicea.—Adapted to *sloughing ulcers* of the cornea and the crescentic form of ulceration; also to *small, round ulcers* which have a tendency to perforate, especially if situated near the centre of the cornea and having no blood vessels running to them. Pain, photophobia, lachrymation, redness and discharges vary, though the latter are generally profuse in the sloughing form of the disease. Hypopyon may be present. The Silicea patient is usually *very sensitive to cold* and therefore wishes to keep wrapped up warm, especially about the head.

Spigelia.—Ulcers with sharp, shooting pains through the eye and into the head.

Sulphur.—Beneficial results have followed the use of this drug in all varieties of ulcers and abscesses, from the simple abrasion of the epithelial layer following the disappearance of a phlyctenule, to the most severe sloughing form of ulcers or abscesses we may see. Both acute and chronic cases have been relieved, though it is more often to be thought of in the latter form, even in cases in which the destruction of tissue is great and *pus is present in the anterior chamber*, especially if the inflammation be indolent in nature, with no photophobia and but slight vascularity. Ulcerations occurring in or dependent upon a *scrofulous diathesis*, as shown by eruptions, etc., suggest this remedy. The most prominent eye indications which would lead us to its selection are the pains which are usually *sharp and sticking as if a needle or splinter were sticking in the eye, or there may be sharp, shooting pains through the eye into the head from one to three A.M.* (These severe pains through the eye into the head, during the day or evening, rarely call for Sulphur, but for Spig., Bry., Cimicif., or the like). Again we may have a great variety of other sensations. *The intolerance of light is generally great* and the *lachrymation profuse*, though both are variable.

All the symptoms are, as a rule, *aggravated by bathing the eyes*, so that a child cannot bear to have any water touch them.

Thuja.—Ulcerations of a syphilitic origin, even when hypopyon is present, suffusion of the eyes and burning in them. Pain over the eye as if a nail were being driven in.

The following remedies have also been followed by favorable results in occasional cases: Alumina, Baryta carb. and jod., Cannabis, Caust., Chin. ars., Kali carb., Kali mur. and jod., Kreos., Nit. ac., Petrol., Sang., Secale, Seneg., Sepia and Vaccin.

Hypopyon Keratitis (*Ulcus Corneæ Serpens, Serpigenous, Infecting or Rodent Ulcer*).—Many of the deeper ulcers of the cornea just described, as well as abscesses, are accompanied by a deposition of pus in the anterior chamber (hypopyon) and hence are apt to be diagnosed as hypopyon keratitis. This, however, is wrong and such cases should be diagnosed as *ulcus corneæ, cum hypopyon*. True hypopyon keratitis is a much more serious condition than the preceding, as shown by the fact that formerly many eyes were completely lost from this disease. In the clinic of Schmidt-Rimpler¹ the proportion of disastrous cases being as high as 19.2 per cent. The progressive course of this ulcer, from which it derives the name of rodent or serpigenous, is by infection. Its infectious origin is proven by the fact that it may be produced in animals by introducing putrid or fermenting substances into wounds made in the cornea.

SYMPTOMS AND COURSE.—In the inflammatory or active cases there is very severe pain and photophobia, with redness of the conjunctiva and some muco-purulent discharge. The ulcer may be developed at either the margin or the centre of the cornea as a slight loss of substance, usually oblong in shape, its base appears grayish, its edges raised and mottled or streaked with white. In the very early stage careful examination shows a deposit upon the membrane of Descemet, giving the base of the ulcer an appearance as though coated with mud, and often a small quantity of pus may be seen in the bottom of the anterior chamber. The hypopyon increases as the ulcer spreads and gives the base of the ulcer a yellow color, as though due to suppurating corneal tissue. The rapidity of the ulceration is such that the entire cornea may be eaten away in two or three days. The ulcer always extends from its border steadily

¹ Lucanus, "Ulcus Corneæ Serpens," inaug. dissert., Marburg, 1832.

and rapidly either directly across or around the entire cornea. In this way the nourishment of the cornea is cut off and slough of the entire cornea may ensue. Increase in the amount of the hypopyon is always an evidence that the destruction of the cornea is still going on. When a large perforation takes place, allowing of the escape of the hypopyon, repair may then set in. In the early stages of this disease there is usually excessive pain, but later on, owing to the cutting off of the corneal nerves by the ulceration, pain may be wholly absent. The disease may occasionally make its appearance in a far less acute attack, in which the inflammatory symptoms and pain may be so moderate that the subject will allow the condition to go on for several days before seeking advice, when we may find a considerable portion of the cornea affected, and the anterior chamber may be half full of pus. On watching these cases two processes may sometimes be seen going on at the same time, viz.: An extension of the destruction at one extremity of the ulceration and repair at the other end or seat of original infection.

Hypopyon.—The occurrence of pus in the anterior chamber may be accounted for in several ways, viz.: by direct passage through the corneal canals, which communicate in the ligamentum pectinatum (through Fontana's canals) with the contents of the anterior chamber; in cases where the abscess or ulcer is deep and near Descemet's membrane it becomes affected together with the endothelial layer, the cells of which proliferate, become detached and fall into the anterior chamber; again, if the ulcer or abscess is situated near the corneoscleral margin, the iris and ciliary body may become inflamed and through this inflammation hypopyon may form. Verdesse¹ made a microscopic examination of an eye affected with hypopyon keratitis in its incipiency and found a small rupture of Descemet's membrane. The ulcer had penetrated but one-third of the thickness of the cornea, but the layers beneath were infiltrated with leucocytes and otherwise unaltered; the iris was normal. From this he concludes that hypopyon is due to a bursting of Descemet's membrane and the entrance of leucocytes from the ulcer.

CAUSES.—Being due to infection, it is most generally found in the poorer classes, where, from want of care, decomposed matter is

¹ Ann. di Ottalm., vol. xvii., 1, p. 67.

allowed to sojourn in the conjunctival sac. In the better classes the septic material is usually the outcome of an inflamed lachrymal sac, the secretion being retained and decomposed. Any abrasion from chips of stone or metal, or simple epiphora, by maceration of the epithelium, gives an opportunity for the infection. The disease nearly always occurs in adults over forty years of age.

TREATMENT.—For many years the treatment of this disease was the *bête noire* of all ophthalmic surgeons. Local and medicinal measures seemed to fail, iridectomy and paracentesis were tried without avail, when Saemisch advised the slitting up of the ulcer, and to him is due the credit of suggesting the operation which is to-day most generally employed. Of late years the use of the actual cautery, or of either the galvano or thermo-cautery, has to some extent supplanted or been used together with, the Saemisch operation. Gruening¹ advises using the point of a delicate platinum probe, brought to a red heat in a spirit lamp, held behind the patient. The lids are separated and the eye steadied by the fingers of the left hand of the operator, while with the right hand the red hot point is applied to the arc or zone of propagation. The eye having been previously cocainized, the patient suffers no pain. Under the compress bandage the eschar is thrown off in twenty-four hours, leaving a clean ulcer which heals rapidly. He advises in the more advanced stages of the disease, where the floor of the ulcer is thin and infiltrated and the anterior chamber partly filled with septic material, that the actual cautery be combined with Saemisch's operation; the cautery destroying the septic material of the cornea, while the Saemisch incision removes the septic material from the anterior chamber. The operation of Saemisch and other treatment, both local and medicinal, will be found under treatment of *ulcus corneæ*, page 155.

Asthenic Ulcer (*Non-Inflammatory or Clear Ulcer*).—This form of ulceration differs, as its names imply, somewhat from those already described, and hence is briefly mentioned. It is but rarely seen, generally appears suddenly and most often in the central part of the cornea. The edges are jagged and outlines irregular, though more or less circular. The depth of the ulcer is often de-

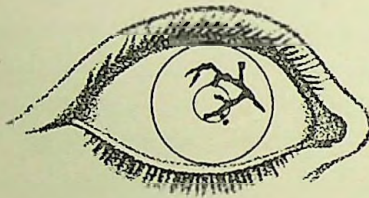
¹ Archiv. Ophthal., vol. xiv., 1, 1885.

ceptive, owing to the bulging forward of its thin base (keratocele). This ulcer may remain stationary for weeks or months, then the edges may become vascular, the margins rounded off and the loss of substance be restored. Repair is often more or less incomplete and a slight facet may remain. It is usually found in adults and sometimes is seen symmetrically in both eyes and may go on to perforation. There is no infiltration either at the base or margins of the ulcer and no pericorneal injection. The only subjective symptom is more or less interference with vision, according to its site.

TREATMENT.—Warm applications and a compress bandage may be applied and local irritants may be used to stimulate the ulcer. For remedies, see indications under *Ulcer Corneae*, especially *Con.*, *Kali bich.* and *Nux vom.*

Keratitis Dendritica (*Malarial, Mycotic and Furrow Keratitis*).—

FIG. 31.



Malarial Keratitis (Kipp).

Under these various headings have been described a superficial ulceration of the cornea, all of which have the one general appearance of narrow furrows with offshoots or ramifications which follow a crooked or zigzag course over the cornea (Fig. 31). In these cases there may be very intense photophobia, lachrymation and neuralgic pains in the eye, with but little inflammation or infiltration. It is generally considered to be due to some particular microbe and is apt to be rather chronic in its course. Emmert¹ found in two cases a peculiar bacillus in or on the epithelial cells. Kipp² describes the disease as malarial keratitis, and claims that, out of 120 cases that he had seen, all but about twelve were suffering from malarial poisoning.

¹ Hirschberg's *Centralblatt für Augenheilkunde*, October, 1885.

² *Trans. Amer. Ophthalm. Soc.*, 1889, p. 331.

Abscessus Corneæ.—By corneal abscess we mean a circumscribed collection of pus within the layers of the cornea.

PATHOLOGY.—There is at first an infiltration of round cells into the corneal tissue. The pressure from these cells upon the parenchyma of the cornea causes a mortification and fatty degeneration of the parts involved, and thus a pus cavity is formed which is generally the shape of a flattened globe or ovoid. Trabeculæ are sometimes found extending from one wall to the other. The cavity is filled with round cells and a fatty, cheesy detritus. The surrounding corneal tissue is also infiltrated. The abscess *may* heal at this stage without further destruction. If so, it begins by the formation of new blood vessels, the cells and detritus become absorbed and the walls of the cavity heal together; or the cavity may be partially or totally filled with connective tissue, and then the blood vessels either atrophy and disappear or remain persistent. As a rule, however, the abscess does not heal at this stage, but, instead, more cells immigrate and are at the same time formed within the cavity and thus more and more of the parenchyma is destroyed. This ulceration usually extends until the outer surface is reached and an ulcer is formed. More rarely the destructive process extends inward, through Descemet's membrane, into the anterior chamber. Lastly, the abscess may extend in both directions at the same time and result in perforation of the cornea. The further progress of the disease from this point has been described under ulcers.

SYMPTOMS AND COURSE.—The beginning of this affection is in the deeper layers and usually at about the centre of the cornea. There appears a round, circumscribed, gray opacity, in which may be seen short, gray striæ. The superficial layers are apt to be diffusely clouded, and there are many small defects and irregularities of the epithelium. Photophobia, lachrymation and ciliary neuralgia are usually quite severe. There is a bright, rosy zone surrounding the cornea and chemosis is very apt to be present. The pupils are contracted, and hypopyon is usually found. The disease as a rule is a most painful one; the terrible pains often radiate to the occiput and teeth, causing sleepless nights, etc.; in fact, in some cases, the pain seems to equal that of acute glaucoma or cyclitis. The intense pain is evidently occasioned by implication of the uveal tract and coincides with the appearance of hypopyon. Sometimes there are several

superficial infiltrations close to each other, which may extend in circumference and depth, coalesce and give rise to a large abscess which may leave a dense opacity or lead to an extensive slough of the cornea. The disease usually shows a tendency to extend in depth rather than breadth. Relapses may occur and the affection thus becomes chronic in character.

CAUSES.—It is found almost exclusively in adults or senile persons who generally belong to the laboring classes and are often poorly nourished. It is frequently caused by mechanical or chemical injuries and may follow operations on the eye, especially cataract. Abscess frequently results from a pustular or blenorrhœal conjunctivitis and is due to migration of the conjunctival pus. It is further frequently seen in debilitating, exhaustive diseases, such as variola, typhus, typhoid, etc.

PROGNOSIS is, as a rule, unfavorable, as a permanent opacity, more or less extensive, always remains. Where there has been no perforation, the convexity may appear normal; but, after the escape of the aqueous, we may have any of the conditions following perforation as described under ulcers.

TREATMENT.—(See *Ulcus Corneæ*, p. 155).

Keratitis Neuro-Paralytica.—The cause of this fortunately rare disease is a paralysis of the fifth nerve, which results in a loss of sensibility of both the cornea and conjunctiva, thus allowing external irritants which, under normal conditions, are rapidly removed by winking, to remain in contact with the cornea and create a traumatic inflammation. It is further claimed by some that the paralysis also causes an interference with the trophic fibres which preside over the nutrition of the cornea. In consequence, there appears upon the cornea, generally at its centre, a gray clouding, followed by an abscess which quickly leads to ulceration. Owing to the total anæsthesia of the cornea, pain is, of course, absent in this disease, although there may have been severe neuralgia preceding the anæsthesia. The paralysis of the nerve may result from injury, tumors, syphilis, etc.

The *prognosis* in all these cases is necessarily bad.

TREATMENT should be to protect the eye from external irritants; hence, a compress bandage should be applied. The use of electricity to stimulate the nutrition of the nerve is of great value. Otherwise, the treatment should be that of ulcers in general.

Keratitis Parenchymatosa (*Interstitial, Diffuse, Syphilitic and Strumous Keratitis*).

PATHOLOGY.—In this form of keratitis there is first an infiltration of round cells into the affected portion of the cornea, with, a little later, proliferation of the corneal fixed cells. The infiltration is usually in the innermost layers of the corneal lamellæ, and, when confined there, the epithelium remains unaltered; but if the outer layers, adjoining Bowman's membrane, become involved, the epithelium becomes irregular, thickened and loses its normal lustre and smoothness. This infiltration usually heals by absorption, either with or without the formation of new blood vessels, which, when present, disappear during the process of recovery, except in rare cases. When absorption does not take place, the infiltration produces sclerosis of the involved part, which is the result of new formation of translucent connective tissue between the normal transparent lamellæ with subsequent obliteration of the corneal canals.

SYMPTOMS.—The characteristic appearance of the cornea is that of a deep-seated grayish opacity, which, commencing at some portion, usually toward the periphery, gradually extends until the whole cornea becomes infiltrated. The density of the infiltration is apt to vary in different portions of the cornea, and is usually thickest at the centre over the pupil. The color of the opacity also depends upon its density, assuming a decidedly yellow hue at the thickest part and from that shading to white at the thinner spots. The extent of the irritation and inflammation varies so much in this disease that some authors speak of it as of two forms—the vascular and non-vascular—but as the amount of the inflammation is the only distinguishing feature of the two varieties, we shall consider it simply as one disease.

We find the majority of the cases of this disease without any vascularity of the cornea and occasionally without any congestion of the conjunctiva; but, as a rule, there is more or less pericorneal injection together with photophobia and lachrymation, while in some cases we will find a number of fine blood vessels running upon the cornea, which, being derived from the anterior ciliary arteries (that form the episcleral plexus), are easily distinguished from the new vessels found in pannus, which, coming from the conjunctival vessels, are more superficial.

Occasionally the vascularity of the cornea will be so great that the appearance will be that of an extravasation of blood into the corneal layers. As the opacity clears up, these new vessels gradually disappear. The vision is always impaired if the centre of the cornea is involved and often to such an extent that only shadows are discernible. The photophobia, lachrymation and ciliary neuralgia may be excessive or entirely absent.

COURSE.—Both eyes are usually affected in this disease, commencing generally in one eye first, and when this is well advanced the second will become inflamed, or sometimes the second eye will not be involved until long after the first has recovered.

The course of the disease is very slow and protracted; in fact it may last from three months to as many years, although as a rule the majority of cases will recover in from two to ten months. In most cases the infiltration will seem to steadily increase, regardless of all treatment, for one to three months before it reaches its height, where it will seem to remain nearly stationary for a like period and then begin gradually to clear up, the central portion over the pupil being the last to clear.

CAUSES.—It is most frequently found from the fifth to the twentieth year and is more often met with in feeble, delicate children, due, perhaps, to want and privation, or from close confinement in a vitiated atmosphere. The most frequent predisposing cause is inherited syphilis or scrofula, and some authors attribute as high as 90 per cent. of the cases to these causes. It is certainly the fact that in the large majority of cases of parenchymatous keratitis, if the teeth are examined, one can find the deformities to which attention was first called by Mr. Jonathan Hutchinson and by him considered a manifestation of inherited syphilis. The so-called Hutchinson teeth consist essentially of a single broad notch in the cutting-edge of the tooth, especially found in the upper central incisors, and in addition to this characteristic peculiarity they will sometimes diverge or slant toward each other.

PROGNOSIS.—In the majority of cases the recovery will be nearly or entirely complete; that is, the haziness will disappear and vision will be restored to normal or nearly so. Cases accompanied by vascularity of the cornea are less favorable than those where no vessels appear in the cornea. Where the disease is complicated by inflam-

mation of some of the adjoining tissues of the eye the prognosis should be more guarded, dependent upon the existing disease.

COMPLICATIONS.—There is a great tendency for the iris to become inflamed, and when it is, it is often overlooked on account of the haziness of the cornea. Cyclitis is a more dangerous but fortunately a less frequent complication. Choroiditis and opacities of the vitreous may also occur as a complication of this disease, while in extremely rare cases shrinking of the cornea and even phthisis of the eyeball have occurred. An extension of the inflammatory process would be suspected if there was noticed an increased vascularity, lachrymation, photophobia and ciliary neuralgia, if the sight should be diminished more than the opacity of the cornea would indicate and if the field of vision became contracted and the eye sensitive to touch.

TREATMENT.—In a large majority of cases the use of the homœopathic remedy is all sufficient and gives decidedly better results than any other mode of treatment. Here homœopathy shows its great advantage over the old school, for we can often check the progress of the disease in a speedy manner by the careful selection and administration of our drugs.

As the disease is nearly always found in those of an enfeebled, debilitated constitution, the diet should be nutritious and easily digestible, while the use of tonics and stimulants may be advisable. The eye should be protected from the light and wind. During repair fresh air and out-door exercise should be advised. In those cases where the infiltration is so dense that the iris cannot readily be watched, *Atropine* should be instilled to prevent involvement of the iris. In some extremely indolent cases good effect is obtained from the use of the *yellow precipitate* ointment. Hot fomentations have sometimes seemed beneficial in causing the development of new blood vessels to hasten the absorption, and also in preventing the lymphoid infiltration.

In regard to remedies the following have proven of the greatest value in this disease.

Apis.—Cornea densely infiltrated, with moderate redness and photophobia. History of hereditary syphilis, with exostoses, swelling of the joints, high fever, drowsiness and thirstlessness may be present.

Arsenicum.—Interstitial keratitis, cornea hazy with commencing vascularity. *Intense photophobia and profuse lachrymation, with burning pain in and around the eye, worse after midnight.*

Aurum mur.—The muriate of gold has been most commonly used, and in the lower potencies. It is especially important in all those cases in which the cause can be traced to *hereditary syphilis*, and as the majority of cases of genuine interstitial keratitis are of this origin, it can readily be seen how common a remedy this may be. It is also valuable in diffuse keratitis of strumous origin. We have seen it act speedily and permanently in both the vascular and non-vascular variety of the disease, though generally marked symptoms of an hereditary taint have been present, as shown by the character of the teeth, described by Hutchinson, as well as by the history of the case. The subjective symptoms are not prominent and may be absent, though usually there is some photophobia, irritable condition of the eye and dull pain in and around the eye, which often seems deep in the bone.

Baryta iod.—Interstitial keratitis occurring in scrofulous subjects, *with great enlargement of the cervical glands*, which are hard and painful on pressure.

Calcarea phos.—Parenchymatous inflammation of the cornea of strumous origin. The infiltration into the cornea may be dense. Photophobia is usually present. Enlargement of the tonsils and other Calcarea symptoms will be found.

Cannabis.—Interstitial inflammation of the cornea from hereditary syphilis. Cornea densely opaque and *vascular*. The photophobia is intense, and lachrymation profuse.

Hepar.—Keratitis parenchymatosa in scrofulous subjects. Cornea opaque and vascular, with deep ciliary injection, severe iritic pains, excessive photophobia, profuse lachrymation and great sensitiveness of the eyeball to touch. Of service in clearing the cornea after the inflammatory process has been checked.

Kali mur.—Diffuse infiltration of the cornea, with some pain, moderate photophobia and redness.

Merc. sol.—Especially indicated if the cause can be traced to either acquired or hereditary syphilis. The ciliary injection, pain and iritic complication are well marked, as well as the nocturnal aggravation and general concomitant symptoms. The inflammation is more active than under Aurum.

Sepia.—Keratitis parenchymatosa complicated with uterine disturbances.

Sulphur.—Indicated in strumous subjects, even if the inflammation is in an active stage. Especially useful, however, in promoting the absorption of the infiltration into the cornea, after the inflammation has been allayed by proper remedies.

Other preparations of Calcareo, Kali and Mercurius may prove of service in the treatment of this disease.

Keratitis Bullosa.—This is characterized by an elevation of the epithelium, and, according to Landesberg,¹ of some of the corneal layers as well, from an effusion of slightly cloudy fluid. The elevation is of considerable size and of a sacciform appearance. Its approach is accompanied by a severe attack of periorbital neuralgia, photophobia and acute congestion of the eye. After rupture of the bullæ a more or less deep ulceration remains, which finally heals as described under ulcers. The pain in this affection is usually very severe, paroxysmal in character and ceases after the breaking of the covering. The disease usually follows upon other diseases of the eye, such as irido-cyclitis and glaucoma. There seems to be a tendency to recurrence of these attacks, and, from this fact, together with a case seen by Tangeman,² in which there was a distinct malarial history, with a cure from large doses of quinine, he suggests the possibility of its cause being malaria.

TREATMENT.—To relieve the pain, remove the envelope of the bullæ and then treat as an ordinary ulcer.

Descemetitis (*Keratitis Punctata*, *Keratitis Postica*).—An inflammation of the membrane of Descemet pure and simple is of rare occurrence. This disease is most frequently described as a *punctate keratitis* and the whole subject is so thoroughly mixed up with serous iritis in ophthalmological literature that a clear understanding of the two conditions is somewhat difficult.

SYMPTOMS.—Pain, photophobia, lachrymation, ciliary injection, dilatation of pupil and hypersecretion of aqueous humor are all of a low degree, and may or may not be present. There is, however, *on the posterior surface of the cornea more or less numerous small, grayish or dirty white points*, especially found over the pupil. These

¹ Archiv. Ophthalm. and Otol., vol. vi., p. 135, 1877.

² Archiv. Ophthalm., vol. xvii, p. 92, 1888.

points may extend into the parenchyma and may result in a sclerosis of that tissue. Its course is always long-lasting and obstinate to treatment. It has a great tendency to recur, and periodical aggravations are frequent.

CAUSES.—Women seem to be more subject to this affection than are men or children. It is often ascribed to some constitutional dyscrasia, such as syphilis, scrofula, etc. The condition described is very frequently associated with a serous inflammation of the iris or uveal tract, but that it can occur primarily I am convinced.

PROGNOSIS.—Entire recovery may take place and the cornea resume its normal characteristics, or the opaque spots may remain permanent, and especially so if the cornea proper has been involved.

DIAGNOSIS.—As this disease so closely resembles serous iritis, we will contrast the differential diagnostic points :

Descemetitis.	Iritis Serosa.
<p>May occur alone. Hypersecretion of aqueous with little if any cloudiness. Punctate spots on the posterior surface of the cornea, which are not triangular in shape, do not change position on movement of the head, but are permanent and more often at the centre of the cornea over the pupil. Anterior chamber normal. No discoloration of iris. Tension is not increased.</p>	<p>Usually follows upon some intraocular inflammation. Hypersecretion of aqueous, which is cloudy. Deposits of lymph on the posterior surface of the cornea, taking a pyramidal shape, with the base at the lowest point, changing with the position of the head, and due to gravity. Anterior chamber deeper. Iris somewhat discolored. Tension may be slightly increased.</p>

TREATMENT.—The patient should be ordered a good, plain, nourishing diet, together with plenty of exercise in the open air. The eyes may be protected with smoked glasses when there is much photophobia. The chief dependence is upon the use of the homœopathic remedy. *Kali bich.* has proven in our hands to be the remedy in this disease. Others, such as Gels., Aurum, Calc., Ars., Hep. and Merc., may be of service. For special indications, refer to keratitis and iritis.

Opacities of the Cornea.—These are often classified according to their density as leucoma, macula, nebula, etc.—the leucoma being the most dense or non-transparent. This subdivision is of no exact

value or practical importance, as the impairment in vision will be oftentimes surprisingly great from an almost imperceptible nebula over the pupil, while a dense leucoma at the periphery of the cornea will cause no loss of vision. Very sharp, careful scrutiny of the cornea with the oblique illumination is often necessary to recognize a very faint opacity, which may be the cause of more or less loss of vision. We have frequently seen our students make a protracted examination of an eye both with glasses and with the ophthalmoscope in order to determine the cause of the impaired vision, which was due to a very faint opacity that had been overlooked. Distant vision is always more affected by a faint opacity than is near vision.

Congenital opacity is sometimes met with, and in these some gradual spontaneous clearing up may be expected.

Arcus senilis or *gerontoxon* is a light gray arc or oval ring at the periphery of the cornea. It is perfectly smooth and more intense toward the limbus, from which it is separated by a narrow, transparent strip. It appears first above and then below and is due to a deposit of fat granules in the parenchyma.

Opacities are most frequently caused by corneal ulcers, which, when recent, are of a gray, dull appearance, but later become smooth and bluish-white. They also may result from deposits of lead or lime in corneal cicatrices. Pannus, inverted eyelashes, etc., cause opacity.

Sclerosis of the cornea is another form of opacity resulting from an infiltration of the cornea. It is produced by a damming up of the corneal canals with a dilatation of the lacunæ, and from this pressure upon the corneal tissue its transparency is changed to resemble more the tissue of the sclerotic, and it is sometimes difficult to determine where the sclera ends and the cornea begins. This condition generally results from keratitis, episcleritis, etc.

PROGNOSIS.—In recent opacities a gradual absorption may be expected, especially if occurring in a young subject. Central opacities may cause strabismus, or, if semi-transparent, may simulate myopia, as the patient will hold objects nearer to the eyes in order to obtain a clearer retinal image. Bilateral corneal opacities in young children may cause nystagmus. The prognosis of opacities of the cornea varies according to their duration and character. If they are dependent upon infiltration into the cornea, proper treat-

ment will usually cause their absorption; but if they result from new scar tissue, a sin extensive ulceration, the prognosis is not favorable. Time will, however, do considerable in clearing the cornea, especially in the opacities of children.

TREATMENT.—The application of irritants to the cornea to promote the dispersion of opacities is often of great advantage if there is no vascularity of the cornea nor other symptoms of irritation. The following have been found most efficacious and should be applied directly to the opacity: Sulphate of soda, aluminate of copper, bichromate of potash, or carbolic acid and glycerine (gtt. vi. ad ʒj).

In order to cut off the irregularly refracted rays of light in some forms of opacities, stenopaic spectacles, either with or without convex or concave glasses, may be of advantage.

The use of electricity may be of some value to clear up a recent opacity of the cornea. Electro-therapeutists have claimed beneficial results from its use, but no accurate data (so far as we have been able to find) warrants a very strong belief in its efficacy.

Various operative procedures have been used in appropriate cases. In an old, dense and large central opacity, an iridectomy opposite a transparent portion of the cornea is frequently advisable. In cases of a deposit upon the cornea from lead, lime or other substance, it may be removed by *scraping* or *excision* of the superficial layers containing the deposit. Oil and a wet compress should then be applied. When the opacity is very dense and disfiguring, it may, for cosmetic effect, be covered by *tattooing* with India ink. In this operation care must be taken not to do too much at one sitting on account of possible disagreeable reaction. The eye is cocainized and the opacity covered with a paste of the finest quality of India ink, a needle or bundle of needles then pricks the epithelium obliquely and forces the ink under the epithelium. Care must be taken that a flow of tears does not spread the ink into any wound of the conjunctiva made by the fixation forceps.

As there is usually a total lack of eye symptoms in these cases, we must chiefly rely upon the general condition of the patient, though the following are the drugs which have been found more commonly indicated: Aurum, *Calc. carb.* and *iod.*, Cannabis, *Cuprum al.*, *Hepar*, *Kali bichr.*, *Nat. sulph.*, Sil. and Sulphur.

Staphyloma Corneæ is a bulging forward of the cornea, either in part or of the whole, and is due to perforation of the cornea with a prolapse of the iris and a large adhesion to the cornea. A central perforation, with no adhesion of the iris, will not cause staphyloma. Total staphylomas result from larger perforations, such as are apt to be found in purulent or diphtheritic conjunctivitis or hypopyon keratitis, while the partial staphyloma is more apt to result in cases of pustular keratitis in children. Staphyloma is directly due to the glaucomatous symptoms resulting from the adhesions of the iris and cornea, which blocks up the filtration passages or excretory channels of the eye. Thus, excretion being partially or totally prevented and secretion constantly going on, something must give, and the cornea, weakened by inflammatory changes, bulges. The tension in staphyloma is usually slightly increased, and a glaucomatous cupping of the nerve has been demonstrated. A partial staphyloma may increase to an involvement of the entire cornea or total. When the bulging has increased so as to protrude between the lids, its exposure is apt to produce inflammatory exacerbations, which cause a still greater increase in the staphyloma. Its shape is usually spherical and the sclera or whole anterior part of the eyeball may be involved. The lens may have escaped at the time of the perforation, or, if it remains, is usually cataractous. The appearance of a staphyloma is usually densely white or bluish and with large vessels coursing over it, or it may appear thinner and darker in color.

TREATMENT.—In partial staphyloma paracentesis, frequently repeated, may prevent its increasing, although, as a rule, iridectomy, which acts by diminishing the intraocular pressure, is better. When complete, and the vision destroyed, our aim should be to improve the appearance and relieve the pain by a removal of the protrusion. This may be done in several ways. *Abscission* is the operation which has given the best results in our hands, and is made after the method proposed by Mr. Critchett, who passes three needles vertically through the globe behind the point where abscission is to be practiced. The protrusion is then cut off by transfixing it through the middle, and cutting outward, then seizing the end of the flap thus formed and removing the rest with scissors. The sutures are then tied and the eye closed without much loss of its contents or risk

of bleeding. This operation is preferable to enucleation, because it furnishes a much better stump for the wearing of an artificial eye. The objections to it are the danger of setting up a severe inflammatory reaction or of causing a sympathetic inflammation of the other eye. It therefore, perhaps, should not be made where the staphyloma is subject to inflammatory attacks or where the other eye shows any evidence of sympathetic irritation.

Enucleation of the Eye.—In this operation a pair of curved blunt-pointed scissors, speculum, fixation forceps and a squint hook are necessary. An anæsthetic should always be used, unless some general condition renders it dangerous. The conjunctiva is to be separated from the globe close to the cornea all around, and the capsule of Tenon dissected back. Then the superior rectus muscle is taken up on the squint hook and severed close to the globe; the other recti muscles may be divided as most convenient and it is my practice to pick up and sever the obliques before cutting the optic nerve. Many operators, however, prefer to extrude the eye from the orbit by pressing between it and the orbital rim, then dividing the nerve and the oblique muscles afterward. To divide the optic nerve the scissors should be inserted closed at the inner side and pushed back until coming in contact with it, when the blades are opened and the nerve severed. The eye should then be pushed forward with the scissors and the numerous small bands of adhesions which are usually found cut away. Immediately after cutting the nerve more or less hæmorrhage is apt to occur, but usually is readily controlled, after which a *firm, tight* compress bandage should be applied.

Exenteration of the eye, as removal of its contents is called, is done by excising the cornea at the limbus and removing the entire contents of the globe down to the sclerotic either with a spatula, or, as performed by the Late Dr. Liebold, with balls of picked lint, wiping out the vitreous, retina and choroid until perfectly clean. This operation has been highly commended of late years by Alfred Graefe, Bunge and others as a substitute for enucleation, but to Liebold should belong the credit of having first practiced it. The principal value of this operation over enucleation is that it leaves a larger and better stump for the wearing of an artificial eye.

Artificial eyes are made of both glass and celluloid and are of various sizes and colors. The eye should not be worn until from six

to eight weeks after the removal of the globe, and then not worn continuously at first and always should be removed at night. The insertion of an eye is very easy and readily acquired by the patient. It is to be pushed beneath the upper lid and held there while the lower lid is brought over its lower edge. In its removal the lower lid is depressed and a probe inserted beneath the eye, which is brought forward and slips out from its own weight.

Keratoconus (*Cornea Conica, Staphyloma Pellucidum*).—Conical cornea is easily overlooked when but slight. In a marked case we notice that the centre of the cornea appears unusually bright and glistening, as though from a tear drop; but from a side view a decided prominence is at once seen. The conicity is usually in the centre, but may be found at the margin of the cornea. On examination with the ophthalmoscope by the direct method there is seen a central bright red spot, surrounding which is a dark zone, and again outside of this a red ring. The dark zone is due to a diffusion and reflection of the light at the base of the cone. The vessels of the fundus appear distorted and broken and the optic disc seems elongated—due to irregular refraction. The vision is often greatly impaired, even in the slighter cases, owing to the eye having become myopic from lengthening of the anterior-posterior axis and from the astigmatism caused by the irregular curvature of the cornea. This astigmatism is too irregular to be corrected with glasses. The bulging is due to a thinning or diminution in the power of resistance of the cornea. It is non-inflammatory and probably results from atrophy or some degenerative change in the corneal tissue. The condition usually commences between the ages of ten and thirty, generally attacks both eyes and is most often found in delicate people. Its course is very slow and may become stationary at any point. Often the apex of the conical cornea is more or less opaque.

TREATMENT.—Glasses, either spherical or cylindrical, will usually give but little improvement, although, when they do, they should be used. Stenopaic aperture or slit may sometimes be added with some further improvement in the vision. Operations of various kinds have been tried with more or less success. When there is a central opacity of the cone, an iridectomy will often be of value. Despagne¹ recommends the excision of a crescentic bit of the cornea.

¹ Soc. d. Ophth. de Paris, November 4, 1890.

The use of the galvano-cautery has been tried in numerous cases and with benefit in some. We have seen a case treated by Dr. Knapp with decided flattening of the conicity and some improvement of vision. He applies an electrode of about the size of the head of a pin to the apex of the cone and burns away a portion of the external surface of the cornea. Under antiseptic dressings there is but little reaction and the resulting opacity is but slight.

The progress of conical cornea can often be checked by the employment of the proper homœopathic remedy, though it is impossible to diminish the conicity of the cornea without instrumental interference.

The remedy must be chosen according to both local and constitutional symptoms, though *Calc. iod.*, *Eserine* and *Pulsat.* have thus far proved most serviceable. Suitable hygienic measures are of great importance, as this affection may be dependent upon a debilitated condition of the health. A pressure bandage may sometimes be used with advantage.

Kerato-Globus (*Hydrops of the Anterior Chamber, Globular Cornea*).—In this disease there is a general spherical distension of the cornea in all its diameters. The sclerotic is often involved in the same process. Sometimes the protrusion becomes so great as to extend between the lids, which cannot close over it, giving a peculiarly staring appearance to the eye (buphthalmos). The cornea may either remain transparent or become opaque. The sclera is thinned and of a bluish tint, due to the shining through of the choroid. The anterior chamber increases in depth and circumference, and the aqueous remains clear. The iris is enlarged, stretched and somewhat tremulous from lack of support; the pupil is dilated and sluggish. The iris may be bulged forward or cupped back. Vision is usually greatly impaired. The condition may be congenital or result from inflammatory changes of the cornea, such as pannus, etc. The disease is fortunately quite rare and its treatment of but little value. The use of *Eserine* and the compress bandage in the early stages may somewhat tend to check its progress. Iridectomy may also be of some value, and, in advanced cases, the operations for staphyloma may be needed.

Injuries of the Cornea from Foreign Bodies, such as chips of iron, steel, wood, glass, etc., are of very frequent occurrence. When

imbedded in the cornea they generally excite considerable reaction—the eye becomes red and painful, there is photophobia and lachrymation and the pupil may be somewhat contracted. They are as a rule readily seen, but in some cases of very small particles it is with difficulty that they can be recognized even with the use of an oblique illumination and of atropine to give a dark background. They may set up an inflammation of the cornea or even the iris, and, in old, enfeebled subjects, may result in considerable ulceration or slough of the cornea. Again, they may cause no irritation. Knapp reports a piece of steel imbedded in the cornea for two years without causing any irritation.

TREATMENT.—Foreign bodies in the cornea can usually be easily removed, after the instillation of cocaine, by the aid of a spud without fixation of the eye, though if the patient be very nervous and the foreign body be deeply imbedded in the cornea it is better to use a stop speculum and fix the eye with a pair of forceps or employ an anæsthetic. If the foreign body has penetrated the cornea and lies partly in the anterior chamber, a broad needle should be introduced behind it in order to prevent its being pushed backward in the attempt to extract it. Pieces of steel may often be removed with a magnet. After the removal, if much inflammation, use Acon. and cold compresses.

Injuries from lime, lead and chemical agents are apt to cause more or less extensive sloughing of the cornea. The conjunctiva is usually affected, together with the cornea, and their treatment has already been referred to under the conjunctiva.

Wounds of the Cornea.—Small, clean cuts or perforations usually soon heal, with no trace of the injury remaining. The chief danger of penetrating wounds of the cornea is from injury or prolapse of the iris, or from injury to the lens, and, from either of these accidents, lead to a general inflammation of the whole eye (panophthalmitis). Bruises are very apt to excite suppuration.

TREATMENT.—The treatment of wounds of the cornea varies according to the complications which may arise. Our first endeavor should be to subdue the inflammatory symptoms, if seen early, by the use of *ice bags*; especially is this true if the iris and other tissues have also been injured. Cold compresses of *Aconite*, *Arnica*, *Calendula* or *Hamamelis* may be employed locally; at the same time

administering one or an other, *usually Aconite*, internally. *Atropine* should be instilled into the eye if the injury is near the centre of the cornea or if the iris is involved. If the perforation is near the periphery of the cornea *Eserine* should be substituted for the *Atropine*. Perfect rest should be insisted upon if the injury is extensive. If a fistulous opening should remain, a compress bandage may be necessary, or even the introduction of a suture.

Tumors of the Cornea.—Various forms of tumors, such as dermoid cysts, fibroma, sarcoma, melano-sarcoma, epithelioma, etc., may involve the cornea; but, as their seat primarily is on the conjunctiva, or the deeper structures of the eye, their consideration is taken up in other places. (See *tumors of the conjunctiva*).

CHAPTER VII.

Diseases of the Sclera.

Anatomy.—The sclerotic is a dense, tough, fibrous structure, continuous with the cornea, and, by its strength, serves to maintain the form of the eyeball.

Its structure is similar to that of the cornea, excepting that it possesses blood vessels and its fibres are coarser and less uniformly arranged. It also contains lymph channels, fixed and wandering cells, together with some pigment cells. The thickest portion of the sclera is at the posterior pole and the thinnest just behind the insertion of the muscles. In front it is covered by a loose episcleral connective tissue, and over that by the conjunctiva. Posteriorly, about 2.5 mm. to the inner side of the antero-posterior axis of the globe, it is perforated by the optic nerve, whose sheath joins with the sclera. The place of entrance constitutes a sieve-like perforation called the lamina cribrosa. Surrounding the optic nerve the sclera is perforated by blood vessels and nerves known as the posterior or short ciliary, which go to the choroid, ciliary body and iris, and in front it is pierced by the anterior ciliary vessels.

Episcleritis.—Inflammation of the episcleral tissue may occur alone or with scleritis. It appears as a swelling near the edge of the cornea and close to the insertions of the muscles. The bulging is of a dusky red or a dull purple hue. The most frequent situation of episcleritis is over the external rectus muscle, although it may occur at the inner side or either above or below. It may be accompanied by both conjunctival and sub-conjunctival injection, which is apt to be localized. There is usually photophobia, lachrymation and ciliary neuralgia, with some dull heavy pains around the eye.

Episcleritis frequently resembles very closely a large phlyctenule of the conjunctiva; but overlaying the swelling of episcleritis are seen the conjunctival vessels, which are movable on pressure, while in a phlyctenule the conjunctival vessels do not run over the nodule.

Episcleritis has a larger base, its color is darker and shows no tendency to ulceration. The course of an episcleritis is long, usually lasting for weeks and is apt to recur again and again. It is most frequently found in adult females, and has often been found in those of a rheumatic diathesis, and, DeWecker¹ says, "especially in the articular form, affecting the knees." A slight cloudiness of the cornea near the elevation of the sclera is sometimes seen.

The treatment of episcleritis and scleritis are practically the same and will be detailed after a few words upon the latter disease.

Scleritis (*Sclerotitis*).—This condition appears as a general faint pinkish tint, due to injection of the superficial vessels of the sclera. There may also be present a conjunctival injection, which is distinguished from that of the sclera by being of a deeper red and movable over the pinkish hue of the scleral injection. As the inflammation increases the sclerotic assumes a deeper color—more of a bluish tint. In the early stages of scleritis it resembles somewhat both iritis and conjunctivitis, and is differentiated from iritis by clearness of the aqueous and absence of adhesions, and from conjunctivitis by absence of secretion. There is apt to be quite severe pain in scleritis and it is undoubtedly of a rheumatic or gouty origin. Inflammation of the sclera may lead, from ultimate thinning and weakening of its tissue, to staphyloma of the sclera.

TREATMENT.—The local symptoms of this disease being usually few and indefinite, we are often obliged to derive our indications for remedies from the general symptoms of the patient.

If there is great ciliary injection and pain, a solution of Atropine may be employed, but it is rarely necessary.

Aconite.—In the acute stage, if there is violent, aching, dragging, tearing, or *burning* pains in the eyeball with contracted pupil, photophobia and the characteristic reddish-blue circle around the cornea. The eye is usually quite *sensitive to touch* and feels *hot and dry*. Especially useful if caused from cold or exposure to dry cold air.

Aurum.—Low forms of scleritis in which the infiltration has extended into the parenchyma of the cornea. Moderate pain, redness and photophobia. Syphilitic dyscrasia.

¹ Ocular Therapeutics.

Cinnabaris.—Inflammation of the sclera, with *pain over the eye*, usually aggravated at night.

Kalmia.—Sclero-choroiditis anterior. Sclera inflamed, vitreous filled with opacities, glimmering of light below one eye, especially on reading with the other, were indications present in one case in which Kalmia was of great service.

Mercurius.—Inflammation of the sclerotic, which is thinned so that the choroid shines through. *Steady aching pain in the eye all the time, but worse at night*; also usually some pain around the eye, especially if the iris has become involved. Particularly to be thought of if of syphilitic origin. Concomitant symptoms of flabby tongue, offensive breath, night pains, etc., are of great importance. The solubis and corrosivus have been most commonly employed, though the other preparations may be indicated.

Nux mosch.—Nodules over external recti, very large and painful. Patient very drowsy, with sleepy expression of eyes.

Silicea.—Sclerotic inflamed, with or without choroideal complication. The pains may be severe and extend from the eyes to the head and are *relieved by warmth*. Aching in the occiput corresponding to the eye affected.

Terebinth.—Inflammation of the superficial layers of the sclera, with a considerable redness and *intense pain in the eye and corresponding side of the head*. *Urine dark and scanty*.

Thuja.—This is a very valuable remedy in all forms of inflammation of the sclera, even if no characteristic symptoms are present. It should be the first remedy suggested to our minds in the treatment of scleritis, sclero-choroiditis or any of its complications, as clinical experience has often verified its usefulness in these cases. In most instances there has been great tenderness of the globe, intolerance of light and active inflammation, with a general cachectic condition, occurring in persons badly nourished, either scrofulous or syphilitic, and those for a long time deprived of fresh air.

The following have also been used and are recommended: *Puls.*, Spig. and Sulph.

Staphyloma Scleræ.—Bulging of the sclera may be either partial or complete. When partial, it is usually at the ciliary region, and between the insertion of the muscles, because of less resistance at these points. Staphyloma usually results from an irido-choroiditis, accom-

panied by an increase of the intraocular tension; or, it may result from simply thinning of the sclera from inflammation, without increased tension. If its course is very acute, we find conjunctival and sub-conjunctival injection, chemosis and intense ciliary neuralgia. The ciliary region is extremely sensitive to touch, the cornea and aqueous are hazy, the iris discolored and adhered to the lens, the vitreous is clouded with large shreds, tension increased, the vision and field of vision impaired. As the bulging increases it assumes a dusky, dirty gray or bluish hue, due to the choroid shining through. The progress of the staphyloma is very slow and gradual. The curvature of the sclerotic will first be noticed to be slightly altered after an irido-choroiditis; the protrusion slowly increases, changing its white color for a bluish tint and will often assume a mulberry appearance, due to trabeculæ forming a framework to the darker spots. Inflammatory exacerbations come and go, each time increasing the staphyloma. When the bulging extends all around the sclera it is called *annular* staphyloma, and, when complete, may protrude so far as to be called *buphthalmos*. Both partial and complete staphyloma may remain stationary, go on to atrophy from inflammation, or, the bulging give way with escape of the contents of the eye, followed by subsequent inflammation and atrophy.

TREATMENT.—We should endeavor to prevent this result by the use of those remedies given under scleritis, but if it seems to progress in spite of our remedies, an *iridectomy* must be made.

If the staphyloma has existed for some time, it may be abscised according to one of the various methods advised; if it be extensive, and sight is lost, enucleation is to be preferred.

Injuries of the Sclera.—In penetrating wounds there is diminished tension, and, if extensive, there may be prolapse of the iris, ciliary body or vitreous. Wounds accompanied by a prolapse of the iris are especially dangerous from their liability to cause an iridocyclitis and even sympathetic ophthalmia of the other eye. Wounds further back, causing escape of the vitreous, if slight, may heal without any serious consequences; but, if extensive, may result in inflammatory changes in the choroid, detachment of the retina, or an atrophy of the globe. Rupture of the sclera from a severe blow usually takes place parallel with the cornea and from two to five mm. posterior to it. There is usually a dislocation of the lens, which may

be through the rupture and found underneath the conjunctiva, or, if the conjunctiva is also ruptured, it may be expelled wholly from the eye.

TREATMENT.—The treatment of wounds of the sclerotic varies according to their extent and situation. If any protrusion of the contents of the globe has occurred, it should be cut off and the edges of the wound approximated as closely as possible by the aid of a bandage or the introduction of a fine suture. The patient should be kept quiet in bed and *ice-compresses*, with or without applications of Arnica or Calendula solutions, employed as may be most applicable from the nature of the injury, whether contused or incised. *Aconite* should be given internally.

If the wound, however, is extensive, especially if in the ciliary region, even though the vision is not wholly lost, enucleation is far the safer method of proceeding in order that all danger of sympathetic trouble in the other (healthy) eye may be taken away. In all cases in which a large portion of the globe has escaped and sight is irretrievably lost enucleation is necessary.

If there is a foreign body in the sclerotic, it should be removed, but if it has penetrated the sclerotic and is within the eye, it is usually necessary to enucleate, although its extraction may be attempted if there has not been too much injury to the ciliary body. The magnet has, of late, been highly recommended for the removal of steel or iron from the interior of the eyeball.

CHAPTER VIII.

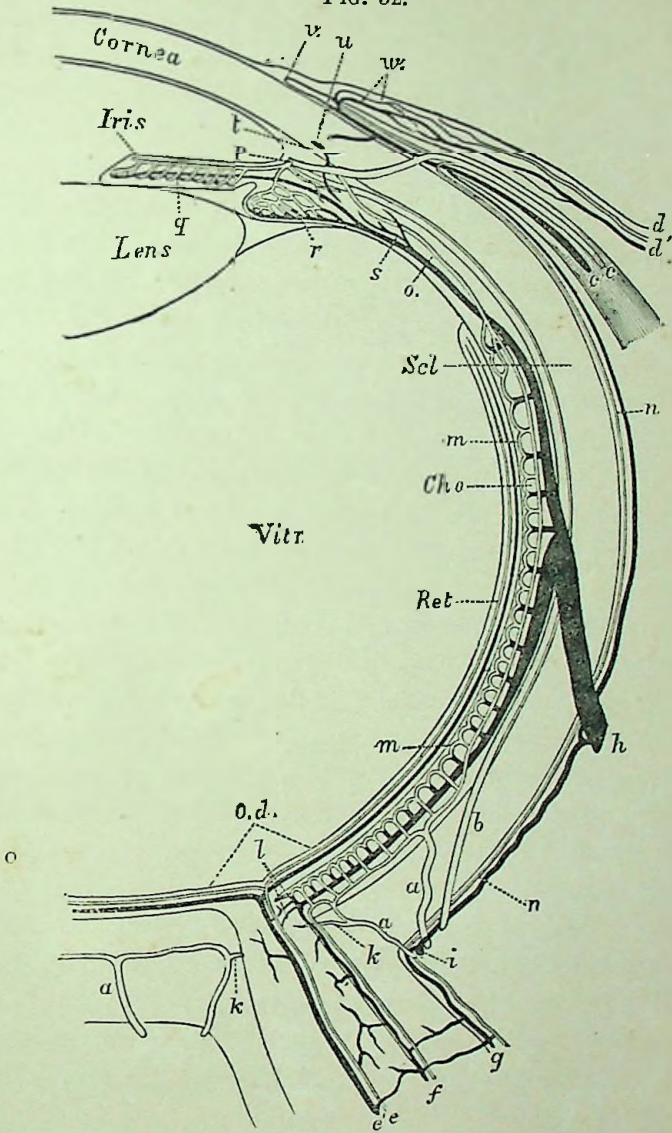
Diseases of the Iris.

Anatomy.—The iris is the beautifully colored and contractile membrane which is seen through the transparent cornea. It is attached at its periphery to the sclera through the fibres of the ligamentum pectinatum, and is perforated at about its centre by a round opening, the pupil. It rests posteriorly on the capsule of the lens, while its anterior surface is free. The iris is continuous with the ciliary body and choroid, and together they form the vascular tissue of the eye known as the *uveal tract*, upon which the aqueous humor, the lens and the vitreous depend for their nourishment. Between the iris and lens is a circular space known as the posterior chamber, while between the iris and cornea is found the anterior chamber. Both the anterior and posterior chambers contain the aqueous humor, in which fluid floats the iris. The anterior surface of the iris is lined with a layer of endothelial cells which is continuous with that on the posterior surface of the cornea. On the back of the iris is a much thicker layer of endothelium containing much pigment and which is continuous with that of the ciliary body and choroid. The *substantia propria* consists of connective tissue fibres and cells, many of which, in dark eyes, contain pigment, and within this stroma are found the muscular fibres, blood vessels, lymphatics and nerves. The *muscular fibres* are flat, found in bundles and are of the unstriped variety. Some are arranged in curves about the pupil, nearer the posterior than the anterior surface, and constitute the *sphincter pupillæ*, while others, more deeply situated, run in a radial direction from the centre to the circumference and are called the *dilator pupillæ*.

The blood supply of the iris is derived from the *circulus iridis major*, which is formed by two long posterior ciliary arteries uniting at the ciliary region with the branches of the anterior ciliary arteries, these then give off branches that pass radially toward the pupil, where they form by anastomosis another ring called the *circulus*

iridis minor (Fig. 32). Capillary networks are given off that ter-

FIG. 32.



Diagrammatic Representation of the Ocular Vessels. The veins are represented black, the arteries clear. *a*, short posterior ciliary arteries; *b*, long posterior ciliary arteries; *cc*, anterior ciliary artery and vein; *cd'*, posterior conjunctival artery and vein; *ce*, central artery and vein of the retina; *f*, vessels of the internal, and *g*, of the external optic sheath; *h* vein vorticosæ; *i*, short posterior ciliary vein; *k*, branch of the posterior short ciliary artery to the optic nerve; *l*, anastomoses of the choroidal and optic nerve vessels; *m*, chorio-capillaris; *n*, episcleral branches; *o*, arteria recurrens choroidalis; *p*, circulus arteriosus iridis major; *q*, vessels of iris; *r*, of the ciliary processes; *s*, branch from the ciliary muscle to the vein vorticosæ; *u*, circulus venosus; *v*, marginal loop plexus of the cornea; *u*, anterior conjunctival artery and vein.



minate in veins, which return the blood in a similar course to that followed by the arteries. The iris contains no lymphatic vessels, the lymph being conveyed in sinuses in the sheaths of blood vessels. The nerves of the iris are very numerous and follow the same course as the vessels. The action of the pupil is controlled by two antagonistic mechanisms—the sphincter muscle supplied by the third nerve and the dilator muscle, by the sympathetic system. Hence, in division of the third nerve, contraction ceases and dilatation results from the unopposed action of the sympathetic. On the other hand, division of the sympathetic causes contraction from an unopposed action of the third nerve. Stimulation of the third nerve causes contraction by overcoming the dilating action of the sympathetic, and, when the sympathetic is stimulated, any contracting influence of the third nerve is overcome and dilatation follows.

PHYSIOLOGY.—The eyes of newly born children are always blue—pigmentation taking place after birth. The iris serves as a curtain to shut off peripheral rays, to regulate the amount of light entering the eye and acts as an aid to accommodation. Contraction of the pupil occurs, from stimulation of the retina by bright light or electricity; when the eyes are accommodated for near vision; in poisoning by morphia, eserine, etc., in deep sleep and after the local application of eserine or other myotics. Dilatation of the pupil occurs when going from a bright into a dim light, when the eye is adjusted for distant vision, in violent muscular efforts, in poisoning by Atropia and other drugs, and after the local application of Atropine or other mydriatics. In examining the mobility of the pupil the eye should be shielded from the light, when a gradual dilatation ensues, then a bright light is suddenly thrown into the eye, when, if normal, the pupil will quickly contract, followed by a very slight dilatation. The pupil is usually larger in children than in adults or old age. Myopes often have large pupils. The pupil is frequently large in nervous, excitable people.

Hyperæmia Iridis.—Congestion of the vessels in the iris is frequently a symptom of other irritation or inflammations of the eye. It is met with as a result of the irritation from overuse of the eyes or from a foreign body lodged in the cornea. It is also found in inflammations of other coats of the eye, the cornea, sclera, choroid, etc., and it is, of course, the first change in either a primary or sec-

ondary inflammation of the iris itself. It is diagnosed by the ciliary injection, a fine pinkish or rosy zone surrounding the cornea; by a change in the color of the iris, it loses its normal lustre and brilliance becoming of a dull hazy appearance; from the reddish tinge, due to the congestion, combined with the normal color of the iris, we find a blue iris assuming a greenish hue, a black appears of a reddish brown color, etc., and by a sluggish contracted pupil, there are no adhesions, but it is simply slow of action.

Iritis.—Inflammation of the iris, of whatever form or variety, presents certain characteristic features which are found in varying degrees in the different pathological or clinical classifications of iritis, and hence it is thought best to make a general study of the disease as a whole, with brief allusions to the different subdivisions.

PATHOLOGY.—Iritis may be divided pathologically into three classes, viz.: Plastic, parenchymatous or purulent, and serous. In *plastic* iritis there is first a hyperæmia, followed by an increase of the stroma cells, which become swollen and turbid, together with a fibrinous exudation. This exudation first appears at the pupillary edge and later upon the posterior surface of the iris, but is very rarely found on the anterior surface. The exudation consists of an amorphous, fibrinous coagulum containing some pigment and round cells. The process may be arrested at this period with an absorption of the fibrine. If not arrested at this stage, the fibrinous exudation becomes changed into a delicate membrane, and later into tough, fibrous, connective tissue (containing blood vessels), which forms the adhesions between the iris and the lens capsule.

In *purulent* iritis the hyperæmia is at once followed by a considerable immigration of round cells and proliferation of the stroma cells. The iris becomes rapidly swollen and pus cells wander into the anterior chamber. If the disease progresses, all the tissues of the iris become gradually destroyed and the condition is apt to extend, resulting in purulent panophthalmitis.

In *serous* iritis, following the hyperæmia, there is an immigration of leucocytes and an infiltration of serous fluid into the tissue of the iris and upon the surfaces. This serous exudate is glutinous in character and serves to cause adhesions between the iris and lens capsule, but does not contain the cellular elements found in plastic iritis—the adhesions are much less firm. A variety of serous iritis

is the *sero-fibrinous iritis*. In this the characteristics are numerous hæmorrhages into the stroma of the iris, the fluid parts of the blood transude into the anterior chamber and the cellular elements remaining in the iris undergo fatty degeneration.

SYMPTOMS.—Subjectively ciliary neuralgia is the most characteristic symptom, for in acute iritis the pain is always considerable; it is not confined wholly to the eye, but extends into the forehead and temples as well and frequently patients complain of shooting pains through the whole head. The pain of iritis is always worse at night and in damp weather. It is often increased by cold and relieved by warmth. There is usually but little sensitiveness to pressure, except when complicated by cyclitis. The amount of the pain as a rule indicates the severity of the inflammation, increasing with the exacerbations of the inflammation and subsiding as the inflammation becomes less severe. In chronic or serous iritis there is sometimes almost complete absence of pain. Photophobia and lachrymation are usually well marked. Dimness of vision will often be complained of, and, when present, may be due to the exudation, cloudiness of the aqueous or to a congestion of the optic nerve or retina.

Objectively the lids may be red and puffy, and, on opening the eye, we will find marked ciliary injection, which should always direct one's attention to iritis or some deeper inflammation of the eye. The cornea will appear surrounded by a violet red ring of sub-conjunctival vessels; together with this there is an engorgement of the conjunctival vessels which in some cases amounts to a chemosis.

In the ciliary or sub-conjunctival injection there are numerous very fine, deep vessels extending from the corneal margin in an almost straight course directly backward and giving the appearance often described as a rosy zone; while in the conjunctival injection the vessels are far less numerous, more superficial, larger and more tortuous in their course. The breadth and intensity of the pericorneal injection is, like the amount of pain, a good indication as to the severity of the iritis. Discoloration of the iris is always present and is due to the addition of the reddish-yellow color resulting from the congestion and infiltration to the normal color of the iris; a blue or gray iris changing to a green and a black or brown iris to a reddish-brown color. The iris loses its lustre, assuming a dull, heavy look, instead of its normal, glossy, shining appearance. The pupil

is sluggish and contracted. Posterior synechiæ are usually present and are recognized by irregularities of the pupil seen when attempting dilatation with a mydriatic. The pupil may be partially or completely closed by the exudation, in this way forming exclusion or occlusion of the pupil. These adhesions or posterior synechiæ form one of the chief and most serious complications of iritis. They interfere with the mobility of the pupil and render subsequent attacks more liable, with greater probability of further adhesions. The haziness of the aqueous is due to the cellular elements thrown off from the iris and suspended in the anterior chamber and may vary from a fine opacity to a hypopyon. A slight increase in intraocular tension is sometimes detected.

COURSE.—Iritis may be either acute or chronic in its course. In the acute variety, according to our old-school authorities, "they run their course in about four to six weeks;" but we should say two to six weeks, for under homœopathic treatment we find a very large per cent. of cases are entirely cured in from two to three weeks.

The chronic form of iritis lasts much longer and is apt to be overlooked, as the inflammatory symptoms and pain are very slight and in some cases almost entirely absent. In this form, frequently, the only indications of iritis will be a very slight pericorneal redness, lachrymation, dimness of vision and posterior synechia. Recurrent attacks of iritis are very frequent, especially in the syphilitic and the rheumatic form where other rheumatic affections exist. The tendency to recurrence is probably greatly increased by the presence of old adhesions.

CAUSES.—Iritis is rather rare in childhood, being usually found in adults from the 20th to the 45th year. It may occur in one or both eyes and seems to be found more frequently in men than in women. It comes on from colds and from over-use of the eyes. Scrofula and syphilis are most frequent causes (60 to 70 per cent. of the cases of iritis being due to syphilis alone, according to some authorities). Rheumatism and gout may cause iritis. It may occur after injuries, such as cataract operations, foreign bodies penetrating into the anterior chamber, etc. It may be secondary to other diseases of the eye, especially from the cornea and conjunctiva. Iritis frequently follows after severe constitutional diseases, such as variola, typhoid fever, etc., and is not infrequently seen as a sympathetic affection.

PROGNOSIS.—This depends upon the stage of the disease and the treatment followed. If iritis is seen early, before adhesions have formed, it should be conducted to a perfect resolution; if, however, posterior synechiæ are present, there will be more or less interference with vision, depending upon the size and strength of the adhesions. Relapses are very apt to occur in iritis, and are rendered more liable when posterior synechiæ remain, owing to the constant traction upon the iris from the adhesions during pupillary movements.

COMPLICATIONS.—Corneal affections may result from an iritis, but more frequently affection of the iris follows that of the cornea and is usually due to direct continuity of tissue through the ligamentum pectinatum. More important, however, are the secondary affections of the ciliary body and choroid. This complication would be suspected, if impairment of the vision increased; if the eye became extremely sensitive to touch, or if there was increased episcleral redness and most characteristic of all would be opacities of the vitreous, as revealed by ophthalmoscopic examination. The tension should also be watched in suspected involvement of the uveal tract, as in irido-choroiditis it is apt to be increased, while in irido-cyclitis it is the reverse. Glaucoma is liable to occur, especially where there has been total posterior synechiæ, and is due to the accumulation of fluid in the vitreous chamber, resulting from the closure of the passage between the anterior and posterior chambers of the eye. Cataract, especially capsular, results from the adhesions of the iris to the lens capsule.

Iritis Syphilitica is one of the most frequent varieties of iritis. It occurs as a secondary manifestation of acquired syphilis and in inherited syphilis as well. When occurring as a secondary manifestation, it is usually one of the latest symptoms to appear, although it may be one of the earliest. When the result of inherited syphilis, it most generally occurs about puberty, although it may occur in early infancy. The diagnosis as due to syphilis cannot be determined from the appearance of the eye alone, except when we find more or less prominent yellowish red or dirty brown nodules (gummata) in the iris; but, when these gummy tumors are present, it is almost invariably due to syphilis. These gummata vary from about the size of the head of a pin to sometimes of sufficient size to entirely fill the anterior chamber and may even involve the cornea and

break through at the corneo-scleral junction and become external. The usual size is about that of a millet seed. They are most frequently found at either the pupillary or peripheral edge of the iris and may undergo fatty degeneration or become absorbed. Syphilitic iritis has all the characteristic symptoms already described and is apt to be more tedious in its course.

Iritis Rheumatica.—Rheumatism as a cause of iritis is considered by some to be far more frequent than any other. Berry¹ says, “the rheumatic form is decidedly the most common.” In our own experience, however, syphilitic iritis has been very much more frequently met with. Rheumatic iritis is chiefly found in adults—from twenty to fifty years of age. Attacks of this form of iritis are apt to be more severe and of a much longer duration. The symptoms are the same as already described and the diagnosis is based on a distinct rheumatic diathesis.

Iritis Spongiosa.—This clinical division of iritis is applied where there is found in the anterior chamber a yellowish-white, spongy looking mass, which may completely fill the anterior chamber. This condition is due to hæmorrhages into the stroma of the iris, the fluid part of the blood transuding into the anterior chamber. The absorption of this peculiar exudation always begins in the parts nearest the cornea, and, in the progress of absorption, may sometimes appear like an opaque lens dislocated into the anterior chamber, for which it has been mistaken.

Iritis Parenchymatosa.—In this we have all the previous symptoms of iritis, together with greater swelling of the iris, exudation on the surfaces and the circulation impeded so that large blood vessels may be seen coursing across the iris; there may be extravasation of blood into the iris and occlusion of the pupil forms rapidly. This form of iritis is usually complicated with an inflammation of the ciliary body or choroid.

Iritis Traumatica (*Purulent Iritis*).—Occurs especially after operations on the eye, as in cataract extractions. It commences with considerable œdema of the lids, profuse lachrymation, chemosis and hypopyon. The iris is very much swollen and there may be a layer of pus on the anterior surface or large drops of pus on

¹ Diseases of the Eye.

the pupil. The severity of the attack depends upon whether or not septic matter or any foreign body has remained in the eye. Some of the vessels of the iris may give way, causing hæmorrhage. Purulent iritis often forms a part only of a general suppurative destruction of the eye.

Iritis Serosa consists of a serous exudation which deposits on the posterior surface of the cornea an amorphous fibrinous exudate, which may be mixed with some cell elements. These spots of exudation soon fall off into the anterior chamber and are either absorbed or remain and form hypopyon. There may be infiltration into the stroma of the cornea, which may result in a sclerosis of the corneal fibres.

SYMPTOMS.—There is a hypersecretion of the aqueous humor, which becomes slightly cloudy. Deposits of lymph attach themselves to the posterior surface of the cornea or settle to the bottom of the anterior chamber. These deposits on the posterior surface of the cornea generally take a pyramidal shape, the base of the triangle at the periphery and the apex at the centre. By changing the position of the head the triangular-shaped mass will also change, thus proving that the deposit is on the posterior surface of the cornea and that the pyramidal form is due to gravity. The increased secretion causes a slight increase in the tension, and, as a result, the pupil becomes moderately dilated and sluggish. The anterior chamber may also be visibly deeper from the same cause. The iris is only slightly discolored. The photophobia, lachrymation, pain and pericorneal injection are very moderate and, as a rule, much less than in other forms of iritis. If the inflammation is severe and of long duration, it may result in a descemetitis or a parenchymatous keratitis. The disease is usually found complicated with some inflammatory process of the deeper structures, particularly chronic irido-choroiditis, though isolated cases uncomplicated by other diseases occasionally arise. It is much more frequently found in women than in men.

TREATMENT OF IRITIS.—Under this heading will be included all varieties of iritis, idiopathic, rheumatic, syphilitic, traumatic, sympathetic, purulent, spongy and serous, also descemetitis.

The first point that demands our attention is the removal of any exciting cause, as, for instance, a foreign body in the conjunctiva,

cornea or interior of the eye. If it be due to swelling or dislocation of the lens forward, or to a portion of the lens substance lying against the iris, an incision should be made and the irritating object removed. When dependent upon sympathetic irritation from the other eye, which has already been destroyed, enucleation of the injured eye should be performed as early as possible. If previous synchiæ are the exciting causes, an iridectomy frequently becomes necessary.

We are sometimes compelled to treat quite severe cases of this disease as out-patients and often with excellent results, though it is far better and safer in all cases to confine the patient to the house. If they are allowed to leave the house the eyes must be carefully guarded by bandaging the affected eye and protecting the other by a shade or colored glass. We should, however, in all cases, especially if severe, most positively insist upon the patient remaining in a darkened room and in bed, in order that perfect rest may be obtained both from the irritation of light and from muscular movements. A low or milk diet usually proves most beneficial, unless the patient is too much debilitated.

The use of *cold applications* in all forms of iritis, excepting the traumatic iritis, has always been condemned by the best authorities until quite recently, when Helfrich¹ reported its use in cases of iritis of the rheumatic form, in which there was an unusual amount of conjunctivitis, or what he says might appropriately be termed an irido-conjunctivitis. Schenck also reports in the same transactions its use in cases of syphilitic iritis. The results from the use of ice in these cases was extremely satisfactory and affords another means of combating certain intractable forms of iritis. The best method of application is the ice-bag, and in its use it is necessary to keep the patient under close supervision, as the continuous use of ice may affect the nutrition of the cornea and must be discontinued as soon as any haziness of the cornea appears.

In traumatic iritis, ice compresses may be used with great advantage.

Warmth is one of our most important aids in the treatment. It may be employed in various ways, though I would especially advise

¹ Trans. Hom. Med. Soc., State of New York, vol. xxvi., p. 167, 1891.

dry warmth, covering the eye and corresponding side of the head with a large, thick cotton pad, for by this the heat may be kept more uniform than by the application of moisture. Small bags, partially filled with fine table salt, applied hot to the eye will often relieve the severe iritic pain experienced at night.

The next point in the treatment of iritis is one of great importance and should always be attended to, viz., *complete dilatation of the pupil as early as possible by the use of Atropine*. As soon as the nature of the disease has been detected a solution of Atropine should be instilled strong enough to produce the desired result, and when the dilatation is complete we should endeavor to keep it so by a continued application of the mydriatic. In severe cases of iritis it may be necessary to use the Atropine every hour. Dryness of the throat or flushing of the face will indicate that it must be used at longer intervals or perhaps discontinued entirely. If the pupil is already bound down by adhesions which cannot be readily torn, it is sometimes better to discontinue the mydriatic until the inflammatory symptoms have subsided, when it may again be tried to break up the adhesions. A solution of Atropine, four grains to the ounce of water, is most commonly employed, though a weaker solution, even one-eighth of a grain to the ounce, may be used in mild cases, if the required effect can be accomplished with it, *but the pupils must be dilated* if possible, even if we have to employ the crude substance. These remarks regarding Atropine will apply to the various forms of iritis, with the exception of the serous variety, in which dilatation must be carefully watched, as glaucomatous symptoms may arise, when the use of Atropine must be stopped and possibly Eserine employed. If Atropine should act as an irritant or the eye shows a great antipathy to its use, some other mydriatic, as Duboisine, Daturine, or Homatropine, may be substituted.

An *iridectomy* may be made in the later stages or if other treatment fails. It may also be indicated in serous iritis, if glaucomatous symptoms supervene, though frequent *paracentesis* of the cornea may relieve without causing the disfigurement from an iridectomy.

Aconite.—In the *very first stage*, or, in a sudden reappearance, this remedy is often of the greatest value, especially if occurring in young, full-blooded patients and when the cause can be traced to an *exposure to a cold draught of air*. It is the most commonly in-

dicated remedy in *traumatic iritis*. The ciliary injection is usually marked, pupils contracted and pains often severe, beating and throbbing, especially at night. There is a sensation of *great heat, burning* and dryness in the eyes. The eye symptoms are often accompanied by general febrile excitement.

Arnica.—Rheumatic iritis has been benefited, though its special sphere of action is in the *traumatic variety*, in which it may be employed with advantage.

Arsenicum.—Iritis, with *periodic burning pains, worse at night, after midnight*, ameliorated by warm applications. Frequently indicated in serous iritis.

Asafœtida.—*Especially indicated in the syphilitic variety and after the abuse of mercury.* The pains are severe in the eye, above it and in the temples, of a *throbbing, pulsating*, pressing, *burning* or sticking character and tend to become periodic; they extend usually from *within outward* and are *relieved by rest and pressure* (reverse of Aurum).

Aurum.—Chiefly serviceable in *syphilitic iritis* and after overdosing with mercury or potash. There is much *pain, which seems to be deep in the bones* surrounding the eye, of a tearing, pressing nature, often extending down into the eyeball, with burning heat, especially on trying to open the eyes; the pressing pain is usually from *above downward* and from *without inward*, aggravated on touch. The vision is clouded, as by a dark veil. The mental condition of the patient is that of great depression; this, together with the bone pains in other portions, aid us materially in our choice.

Belladonna.—Early stages of iritis, caused from a cold; or chronic plastic iritis, following cataract extraction, with much redness and severe *throbbing pain* in the eye and head, worse at night. Sensitiveness of the eyeball to touch, congestion of the face, etc.

Bryonia.—Iritis resulting from exposure to cold not unfrequently calls for this drug, especially if occurring with a rheumatic diathesis. The pains may be sharp and *shooting* in the eyes, *extending through into the head, or down into the face*, or there may be a sensation of *soreness and aching* in and around the ball, especially behind it, extending through to occiput; the patient also sometimes describes the pain "*as if the eye was being forced out of the socket.*" All the pains are generally *aggravated by moving the eyes in their sockets, or*

upon any exertion of them, and at night. The seat of pain often becomes sore to touch. In the serous form it also proves serviceable.

Cedron.—This remedy is particularly of value in relieving the severe *ciliary neuralgia* observed in iritis, if *supra-orbital*, seeming to follow the course of the supra-orbital nerve, especially if there is marked periodicity.

China.—Iritis dependent upon the *loss of vital fluids*, or malaria. The pains are variable, but have a marked *periodicity*. The *muriate of Quinine*, in appreciable doses, will often relieve the *severity of the pains*, especially when of an *intermittent type and accompanied by chills and fever*.

Cinnabaris.—Of great value in the treatment of iritis, particularly syphilitic and if gummata are present in the iris. The characteristic *pain commences at the inner canthus and extends across the brow or even passes around the eye*, though there may be shooting pains through the eye into the head, especially at the inner canthus. Sharp pain over the eye, or soreness along the course of the supra-orbital nerve and corresponding side of the head. Like mercury, the *nocturnal aggravation* is usually marked and the symptoms intermit in severity.

Clematis.—By some, this drug is considered to be as frequently called for as mercury, in iritis and kerato-iritis, though we have never used it to the same extent. Chronic syphilitic iritis, with very little pain. The pains are similar to those of Mercurius, but there is usually much heat and dryness in the eye and great *sensitiveness to cold air*, to light and bathing.

Conium.—Descemetitis, with *excessive photophobia* and but little redness or apparent inflammation.

Euphrasia.—Rheumatic iritis, with constant aching and occasional darting pain in the eye, always worse at night; ciliary injection and photophobia great; aqueous cloudy; iris discolored and bound down by adhesions.

Gelsemium.—In *serous iritis* alone or complicated with choroideal inflammation, Gelsemium is the most prominent remedy. There is hypersecretion and cloudiness of the aqueous, with moderate ciliary injection and pain.

Hamamelis.—Iritis traumatica, or other forms in which *hæmorrhage has taken place into the iris or anterior chamber*.

Hepar.—Especially serviceable if the inflammation has extended to the neighboring tissues, cornea (kerato-iritis) and ciliary body (irido-cyclitis) or after gummata have ruptured, and if there is *pus in the anterior chamber (hypopyon)*. As hypopyon is an important symptom under Hepar, we should think of this remedy in parenchymatous or suppurative inflammation of the iris, in which this condition is present. It is also of value in *purulent irido-capsulitis* after cataract extraction. The pains are pressing, boring or *throbbing* in the eye, *ameliorated by warmth* and aggravated by motion. *The eye is very tender to touch*. There is usually much photophobia and great redness of the conjunctiva, even chemosis, while the lids may be red, swollen, spasmodically closed and sore to touch. The patient feels chilly and wants to keep warmly covered.

Kali bichrom.—It is *the* remedy for true *desцемetitis* characterized by fine punctate spots on the posterior surface of the cornea, especially over the pupil, with moderate redness and very little photophobia. May be required in syphilitic iritis.

Kali iod.—An important remedy in *syphilitic iritis*, especially after mercurialization and if the secondary eruption on the skin is present. The special indications are not marked, *though the inflammation is usually of high degree*. It has been given upon general principles in many instances with excellent success. It often relieves when given in large doses when the potencies have failed.

Mercurius.—Mercury in its various combinations is our “sheet anchor” in the treatment of *all forms of iritis*, especially the syphilitic, and the cases which call for its use present a great variety of symptoms, differing widely both in character and intensity. *The pains are usually severe, of a tearing, boring, cutting, burning nature, chiefly around the eyes, in the forehead and temples* and accompanied by throbbing, shooting, sticking pains in the eye, though in rare cases they may be almost or entirely absent. These pains, as well as all the symptoms of the mercurials, are *always worse at night after going to bed and in damp weather*, in this respect corresponding very closely to the disease. There is generally much heat both in and around the eye and soreness of the corresponding side of the head to touch. *Great sensitiveness to heat or cold may be found; also to light, especially the glare of a fire*. Acrid lachrymation may be present. *The pupil is contracted and overspread by a thin, bluish*

film, while there is great tendency to the formation of adhesions (posterior synechiæ). The iris is discolored, aqueous cloudy and ciliary injection marked. Hypopyon may be present or not. Gummata may also be found on the iris. The lids may be red, swollen and spasmodically closed, or even normal in appearance. The concomitant symptoms of *nocturnal pains* in different portions of the body, perspiration at night, condition of tongue, mouth and throat and eruptions on the skin, are of great importance in selecting this drug and in choosing between the different preparations.

The *Corrosivus* is most frequently employed and proves most beneficial, as the *intensity of the symptoms* is more marked under this than any other form.

The *Solubis* comes next in order of usefulness and should be given if the above symptoms are present and if the inflammation is of medium intensity or lower grade and if certain characteristic general symptoms are observed.

The *Dulcis* is to be thought of when iritis is found in very scrofulous subjects, especially children with pale, flabby skin, and when associated with corneal ulceration.

The *Protoiodide* should be chosen from concomitant symptoms, as *thick yellow coating on the base of the tongue*, enlarged glands, etc., and when *superficial ulceration of the cornea* complicates the difficulty, especially if found during the course of pannus.

Natrum salicyl.—Iritis with intense ciliary neuralgia, especially resulting from operations on the eye.

Nitric acid.—Chronic syphilitic iritis of a low degree, with very little or no nightly pain. The pains may be worse during the day and are of a pressing, stinging character. Posterior synechiæ will be found.

Nux vom.—May be useful at the beginning of the disease or as an intercurrent, especially in the syphilitic form, if there is much photophobia, lachrymation, etc., *in the morning*.

Petroleum.—Syphilitic iritis accompanied by *occipital headache*. Pain in eyes pressing or stitching and skin around the eyes dry and scurfy.

Rhus tox.—Idiopathic or rheumatic iritis, if caused by *exposure to wet*, or if found in a rheumatic patient. *Suppurative iritis, particularly if of traumatic origin, as after cataract extraction*, more often

calls for Rhus than any other remedy. Also useful in kerato-iritis. *The lids are oedematously swollen, spasmodically closed, and, upon opening them, a profuse gush of tears takes place. There is chemosis, the photophobia is marked and the pains are various, both in and around the eye, worse at night, especially after midnight, and in damp weather. The swelling of the lids often involves the corresponding side of the face and may be covered by a vesicular eruption. Concomitants must be taken into consideration.*

Spigelia.—Rheumatic iritis, if the pains are *sharp and shooting both in and around the eye, especially if they seem to radiate from one point.*

Sulphur.—Iritis, particularly if chronic and found in strumous subjects, may find its remedy in Sulph., also if *hypopyon* complicates the trouble. May be of service as an intercurrent, even if it does not complete the cure. The pains are usually of a *sharp, sticking character*, worse at night and toward morning. General indications will decide our choice.

Terebinth.—Rheumatic *iritis with intense pains in the eye and head*, especially if resulting from suppressed perspiration of the feet. Pain in the back and dark urine will be present.

Thuja.—*Syphilitic iritis, with gummata on the iris. Large wart-like excrescences on the iris, with severe, sharp, sticking pains in the eye, aggravated at night and ameliorated by warmth.* Usually accompanying the above we find *much heat* above and around the eye and in the corresponding side of the head; there may also be tearing, dull, aching pains in the brow, or a pain above the eye (left) as if a nail were being driven in. *Ciliary injection* decided, even in some cases amounting to inflammation of the sclera. Lids may be indurated, noises in the head, etc.

The following remedies have also been employed in occasional cases with favorable results. Their meagre indications can be found by reference to Part II. Arg. nit., Crot. tig., Prunus sp., Puls., Sil., Staph. and Zinc.

Tumors of the Iris.—Both simple and malignant tumors are met with in the iris.

Cysts, both *epidermoid* and *serous*, are in the large majority of instances due to traumatism. The *epidermoid* is usually the result of a penetrating wound, by which one of the cilia is carried into the

iris and is found to consist of cells covered with pavement epithelium and sometimes surrounded by a thin connective-tissue membrane. The appearance is that of a yellow, opaque tumor, and it may undergo fatty degeneration. The *serous* cyst is merely distended iris tissue, which may become so thin as to be simply a structureless membrane. The appearance is that of a grayish-white or translucent tumor and its contents are similar to the aqueous tumor.

The *treatment* consists of excising them as early as possible, and care should be taken not to rupture the cyst wall during removal.

Melanoma is an extremely rare form of tumor affecting the iris. It is merely a hyperplasia of the pigmented cells of the stroma of the iris and appears as a small black tumor. They are benign, usually congenital, more or less stationary and produce no irritation. Rarely they have been seen to develop into a melano-sarcoma.

Granuloma may very rarely appear in children as a pale red or yellow vascular tumor, which may gradually increase, involve the cornea and perforate, when it appears like a spongy mass, bleeding easily and resembling a sarcoma. They may also occur from a prolapse of the iris or after operations. They have been found to consist of numerous small, round, irregular or spindle-shaped cells, with a few large nucleated cells and may be covered by epithelium.

Sarcoma are very rarely found occurring primarily in the iris. One reported by Andrews¹ was first excised with a piece of the iris and one week later the eye enucleated. They are usually an extension from the choroid or ciliary body and are most frequently of the pigmented variety. Limbourg² reports a case of leucosarcoma with complete details of the microscopical examination. The eye should be enucleated.

Tubercles appear chiefly in children as grayish-red, irregular nodules, most frequently at the periphery of the iris and are accompanied by more or less inflammation. They may increase in size and number and should be either excised or the eye enucleated.

Mydriasis.—Dilatation of the pupil may occur in one eye or both, and may result from various causes—from simple colds or draughts of air; from injuries, as a blow on the globe; after diphtheria, from

¹ N. Y. Med. Journ., June 1, 1889.

² Archiv. Ophthal., vol. xix., p. 239, 1890.

local paralysis; from intestinal irritation, as in worms; from spinal or cerebral irritation, as in hyperæmia or new growths and in acute mania or melancholia. It is also found in hysteria, sexual irritation, apoplexy and in diseased conditions of the eye, as when the retina or optic nerve are so far diseased as to have lost the normal sensitiveness to light, in glaucoma, etc.

The mydriasis occurs as a paralytic affection of the third nerve or as a result of some irritation of the sympathetic. It causes a dimness of vision from too much light and an increase of the circles of diffusion.

This functional disturbance of the pupil is, therefore, usually merely a symptom of deeper and more serious trouble and requires remedies adapted to that condition. It is, however, sometimes found uncomplicated with other disorders, being dependent upon cold, trauma, etc., in which case, Arnica, Bell., Caust. and a score of remedies may be indicated. The instillation of sulphate of eserine is also often of great service. As mydriasis is generally associated with paralysis of one or more of the ocular muscles, refer for treatment to paralysis of the muscles.

Myosis.—Contraction of the pupil is, physiologically, greater in infants and old age than in middle life; is greater in hyperops than in myops and in those who use the eyes steadily at fine work.

Spastic myosis or contraction of the pupil due to spasm of the third nerve may be dependent upon some irritation or inflammation of the eye, as in hyperæmia of the iris, or from some irritation of the cerebral centre, as in meningitis, apoplexy, intracranial tumors, in tobacco or alcoholic amblyopia, at the commencement of an hysterical or epileptic attack, etc.

Paralytic myosis or contraction due to paralysis of the sympathetic is very rare and is accompanied by contraction of the palpebral fissure and redness of the corresponding side of the face, which becomes warm and moist with perspiration. This form of myosis results from wounds or injuries of the sympathetic.

Spinal myosis is nearly always bilateral and may be preceded or accompanied by atrophy of the optic nerve and contraction of the field of vision. This form of myosis is seen in tabes dorsalis, and, from the peculiarity of the contraction of the pupil, it is called the Argyll Robertson pupil, as he first called attention to it in

1869. In this, the pupil is contracted, and, while not responding at all or very feebly to light, responds actively to convergence and is always indicative of a serious central lesion.

Contraction of the pupil unassociated with more serious disturbance is of rare occurrence; the cause, therefore, usually demands our attention. Atropine instilled into the eye may be employed, though it generally gives only temporary relief.

Jaborandi and *Physostigma ven.* are especially recommended for this condition, though various remedies which produce contraction of the pupil may be thought of.

Hippus.—Irregular contraction and dilatation of pupil has been seen in nystagmus, in multiple sclerosis, after epileptic attacks, in hysterical spasms, etc.

Iridodonesis.—Tremulousness of the iris is dependent upon loss of support of the iris and is usually the result of a partial or total dislocation or absence of the lens. It may also occur in hydrophthalmus, or, when there is an increased amount of fluid in the posterior chamber. There is nothing to be done for it.

Iridoncosis.—Atrophy of the iris is the result of inflammation, usually a chronic parenchymatous iritis, and sometimes occurs after perforation of the cornea where the anterior synechiæ have kept up the inflammation. It consists of a fatty degeneration.

Hypæmia.—Blood in the anterior chamber is usually of traumatic origin, although may be spontaneous, as a result of some intraocular inflammation, as iritis. It may be but slight, or sufficient to entirely fill the anterior chamber, and is usually rapidly absorbed by the application of a compress-bandage and the internal administration of Arn., Aurum, Ham. or Ledum.

Iridodialysis.—A separation of the iris from its peripheral attachment is usually traumatic, as from a blow on the eye, which spreads the cornea at the corneo-scleral junction, causing a separation, or from operation, as in iridectomy.

Coloboma Iridis.—Congenital absence of a part of the iris, of either one or both eyes, is not uncommon. It is usually complicated with other congenital anomalies, especially of the choroid, or may be of the lens, or optic nerve, or in microphthalmos. It may extend to the periphery or not, and is usually downward, or downward

and inward, and may be of various shapes. Pollak¹ reports three cases and gives the literature upon coloboma of the iris.

Aniridia (*Irideræmia*).—Absence of the iris may be total or partial, but is usually total and in both eyes. When complete, we may be able to see the ciliary processes, unless small or atrophied. The lens usually becomes opaque, vision is decreased and nystagmus often accompanies it. Stenopaic glasses may improve.

Membrana Pupillaris Persistans consists of the presence of two or three fibres running across the pupil which are attached on the anterior surface of the iris and external to the sphincter. During the greater part of intra-uterine life the pupillary membrane stretches across the pupil, and in normal eyes it remains permanent after birth only in that part which covers the iris, whose endothelial layer it becomes; but occasionally small shreds will remain and are called persistent pupillary membrane.

Heterochroma is the term applied to variations in the color of the iris. In one eye the iris may be black or brown and in the other blue, or the two colors may exist in different sections of the same iris.

Corectopia, an anomalous position of the pupil; *Diplokorìa*, double pupil, and *Polycorìa*, many pupils, are all congenital anomalies which are sometimes met with.

Operations on the Iris—*Iridectomy*.—This operation, consisting in the excision of a portion of the iris, is the one most frequently made for both therapeutic and optical measures. It is indicated for therapeutic purposes in glaucoma, staphyloma, posterior synechiæ and sometimes may be of value in obstinate cases of recurrent iritis, or in keratitis, with deep ulceration or hypopyon. It is also indicated in tumors of the iris or for foreign bodies in the iris and is frequently performed preliminary to cataract extraction. For optical purposes it may be indicated in opacity of the cornea, occlusion of the pupil, central opacity or dislocation of the lens and in cataract extraction. Iridectomy, when made for visual purposes, should of course be made where there is the least opacity of the cornea and lens, preferably below and a little to the inner side, if possible. When made for therapeutical purposes it is preferably above, that the upper lid may cover the deformity as much as possible. The size of the

¹ Archiv. Ophthal., vol. xx., p. 410, 1891.

iridectomy, when made for optical purposes, should be small and large when made as a therapeutical measure.

The instruments needed for this operation are a speculum (see Fig. 19), fixation forceps (see Fig. 20), an angular or straight keratome (Fig. 33), or Graefe cataract knife; either curved or straight iris forceps (Fig. 34) and a pair of iris scissors (Fig. 35). Cocaine

FIG. 33.


Angular and
Straight Keratomes.

FIG. 34.



Curved and Straight
Iris Forceps.

FIG. 35.

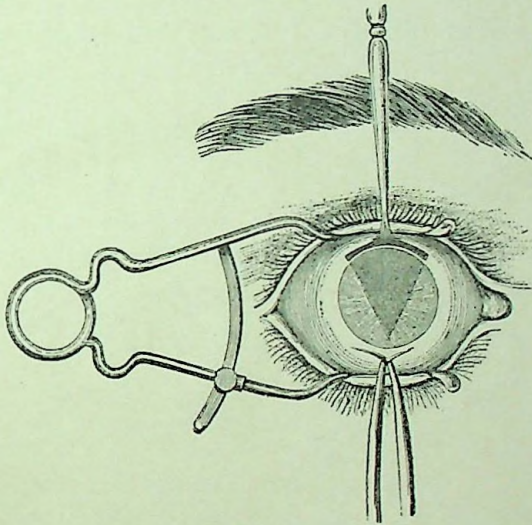


Curved Iris Scissors.

anæsthesia is usually sufficient in all cases, excepting, possibly, in glaucoma or an especially nervous subject, when ether should be administered. The eyelids are kept open with the speculum and the eye steadied by a firm hold with the fixation forceps directly opposite the point at which the incision is to be made. The keratome is then inserted in the sclerotic at the corneo-scleral margin

(except when made for therapeutical purposes, when it should be from one to two mm. from the edge of the cornea) obliquely and in such a direction that, if continued, it would wound the iris and lens; but, as soon as the point is seen in the anterior chamber, the handle is depressed so as to bring the blade into a plane anterior and parallel to that of the iris and the blade is pushed forward into the anterior chamber until an external wound of sufficient size has been attained. The keratome is now to be slowly withdrawn, with its apex toward the cornea and well away from the iris and lens. The aqueous escapes with the withdrawal of the knife and should be allowed to

FIG. 36.



Iridectomy—The Incision.

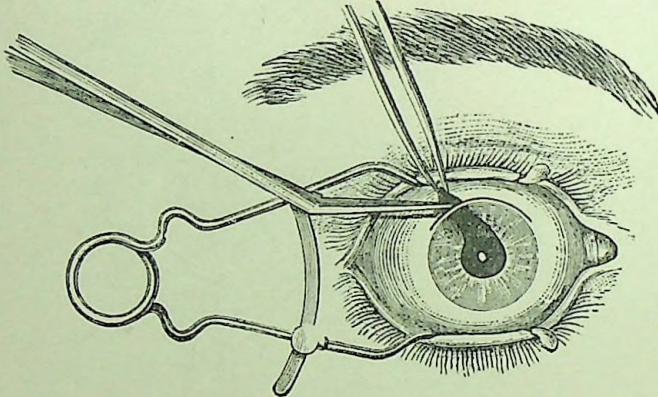
pass off slowly. The iris forceps are now entered, closed, into the anterior chamber, opened, and the iris seized near its pupillary edge, drawn out and cut off at one cut of the scissors, or, as some prefer, drawing it to one side of the wound and partially snip it off and then drawn to the other angle, where the excision is completed (Figs. 36 and 37). Care should be taken that the cut edges of the iris go back into place and that none of the iris remains in the wound. The eye is then closed and a compress bandage applied.

The accidents from iridectomy are first, from an injury of the lens by the keratome. This is a very serious accident which will be followed by partial or complete cataract and possibly glaucoma from swell-

ing of the lens. Sometimes the keratome will enter the layers of the cornea instead of the anterior chamber when making the incision, due to its being held too obliquely. When this is discovered, the instrument should be withdrawn and a fresh incision made. Hæmorrhage into the anterior chamber, if occurring after the excision of the iris, requires no attention, as it will be rapidly absorbed, and, if it occurs before the iris is cut, the blood can usually be made to flow out by depressing the edge of the wound. Hæmorrhage into the fundus of the eye is apt to occur during iridectomy for glaucoma and is of serious import. It results from a too rapid escape of the aqueous on the withdrawal of the keratome.

Iridotomy (Iritomy) consists in the formation of an artificial pupil by simple incision of the iris. It is only occasionally adopted, and

FIG. 37.



Iridectomy—Cutting the Iris.

that in cases of absence of the lens, when the pupil is closed and the iris adherent to the lens-capsule, as may sometimes occur after cataract operation, where the iris has been put on the stretch by being drawn upward by the cicatrix. It is made by entering the narrow Graefe knife in the cornea about 2 mm. from the corneo-scleral margin, the blade then penetrates the iris and by a sawing movement, with the back of the blade against the cornea, an opening in the iris or capsule is made with little loss of aqueous, the tension of the iris causing the opening to gap. Other forms of knives and scissors have been used for this purpose.

Iridodialysis is a tearing away of the periphery of the iris. This operation is rarely done and only when the extreme margin of the cornea is the only clear portion.

Iridavulsion.—Removal of the entire iris by tearing it from its periphery has been performed with remarkable effect by Noyes in cases of hydrophthalmus. The iris should be seized by the forceps or hook at its periphery opposite to the point of opening of the cornea and drawn out. Care must be taken not to injure the lens.

Corelysis.—The breaking of pupillary adhesions by the hook or toothless forceps has not proved a great success, owing to their tendency to re-form and the danger of wounding the lens.

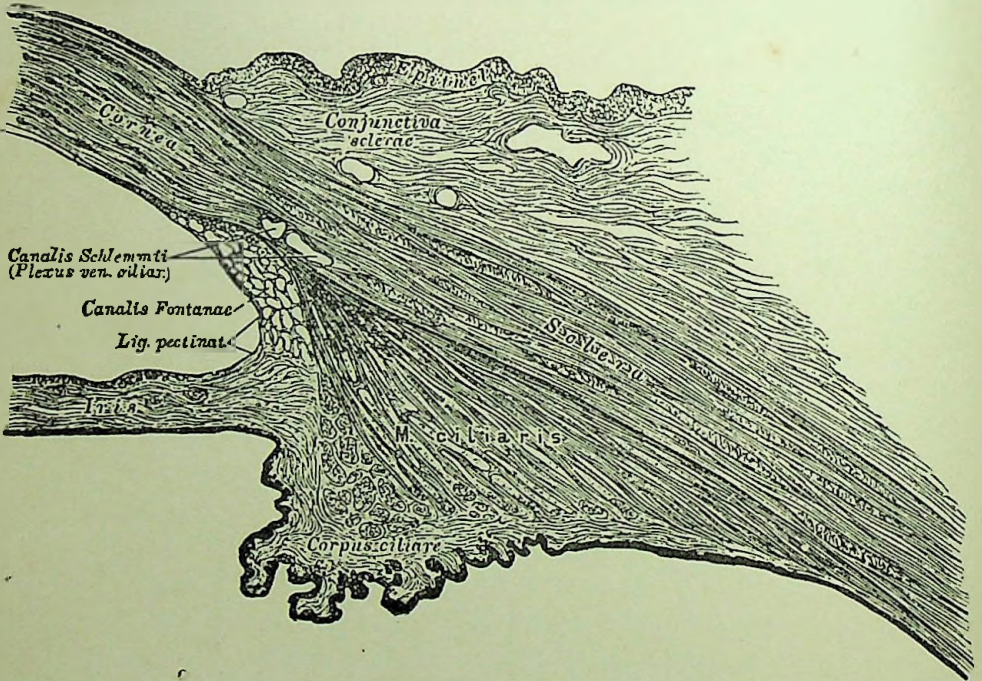
Iridodesis consists in drawing the pupillary edge of the iris through a small opening in the margin of the cornea and securing it by a fine silk suture on the outside. This operation was formerly practiced by Critchett and others, but has rather fallen into disuse from the possible danger of sympathetic ophthalmia.

CHAPTER IX.

Diseases of the Ciliary Body.

Anatomy.—The ciliary body is that part of the uveal tract extending from the periphery of the iris to the choroid, and consists of the ciliary processes and the ciliary muscles.

FIG. 38.



A Section Through the Ciliary Region.

The *ciliary processes*, some seventy or eighty in number, are composed of a connective tissue stroma, continuous with that of the iris and ligamentum pectinatum, of blood vessels arranged in convolutions or folds and overlaying these folds is a densely pigmented layer. The tips of the ciliary processes lay a little in front of the edge of the lens, but are not in contact with it. From the posterior surface of the processes extends a transparent structure called the

zonule of Zinn or suspensory ligament of the lens. This is derived from the hyaline layer on the inner surface of the ciliary body, and, as it passes to the border of the lens, it splits up to go to each surface of the lens, leaving a small triangular space called the canal of Petit. Through this structure transfusion from the vitreous to the aqueous humor takes place. The ciliary processes, while not erectile, enlarge or shrink with variations of blood pressure.

The *ciliary muscle* is composed of three sets of unstriped fibres: The meridional, running parallel to the sclerotic; the circular, forming a ring parallel to the cornea; and the radiating fibres. Iwanoff has shown that, in certain myopic eyes, the circular fibres may be entirely lacking, and, on the contrary, in hyperopic eyes are so highly developed that they form one-third of the ciliary muscle.

As to the action of this muscle Heinrich Müller ascribes a different action to each set of fibres:

1. "The circular fibres of the ciliary muscle exert a pressure upon the edge of the lens, by means of which the latter becomes thicker."

2. "The longitudinal fibres of the muscle cause an increase of tension in the vitreous humor, on account of which the posterior surface of the lens is prevented from shifting and the action of the peripheral pressure is chiefly confined to the anterior surface," and also, that, "The arching forward of the centre of the anterior surface of the lens is rendered possible and favored by the recession of the peripheral portion of the iris, which is accompanied by a contraction of the deeper (circular) layer of the ciliary muscle and the iris." Thus we see that the circular fibres of the ciliary muscle are the ones by which the act of accommodation is chiefly caused, and, further, that these circular fibres are especially developed in hyperopic eyes.

The vessels supplying the ciliary body are the posterior and anterior ciliary. The nerves are from the ciliary, forming a network in which are multipolar ganglion cells containing sensitive, motor and sympathetic filaments. From this plexus fibres pass to supply the ciliary body, iris and the cornea.

Cyclitis.—Inflammation of the ciliary body is very rarely found uncomplicated with other diseases and usually, except when caused by wounds, is an extension of a choroiditis or iritis, and when the

inflammation commences in the ciliary body it usually extends to these other parts. The recognition of cyclitis as independent of a primary inflammation of the iris is indicated by the fact that the relative integrity of the iris, in relation to its nutrition and functional disturbances, is not as much affected as when the inflammation commences in the iris. There is also a disturbance in the nutrition of the lens without the deposit on the capsule from the iris and there is at the same time a more rapid loss of vision. Cyclitis may occur as either a plastic, serous or purulent inflammation.

Cyclitis Plastica—**PATHOLOGY**.—The pathological changes are the same as those found in plastic inflammation of the iris, viz.: Hyperæmia, swelling of the stroma cells, accumulation of wandering cells and an exudation of an amorphous mass, especially on the inner surface of the ciliary body. The exudation may extend forward upon the posterior surface of the iris and may fill the whole of the posterior chamber. It may be deposited on the posterior surface of the cornea, floating about in the aqueous, or be found in the iritic angle. There is also an exudation into the vitreous, especially in its anterior portion, causing it to become hazy, which, as it gradually absorbs, leaves opacities floating in the vitreous that may become membranous. If the disease goes on, the retina and choroid become affected and the retina detached and filled with a sero-albuminous fluid. In the late stages the ciliary processes may become detached from the sclera. The exudation is the same, only more extensive than in iritis.

SYMPTOMS.—There is ciliary injection and often chemosis. The iris may be discolored and the pupil contracted, but there are no synechiæ, unless the iris is involved. The veins of the iris are engorged, owing to the swelling of the ciliary body preventing a return of the blood from the iris. Pain is usually a prominent symptom; it is generally quite severe in and around the eye and often extending into the head—in fact, about the same as that in iritis. The most characteristic symptom is the *extreme sensitiveness of the eye to touch*. There may or may not be haziness of the aqueous, but the haziness of the vitreous is almost invariably present in the early stages, appearing on weak illumination like fine dust floating in the anterior part of the vitreous. The anterior chamber may be deepened in the earlier stages, and later it may be shallow from

fluid or exudation behind the iris or lens pressing it forward. There is a rapid loss of vision and the accommodation is impaired. The tension may be either increased, decreased, or normal.

Cyclitis Serosa.—In this we have the same pathological changes as in serous iritis and it is almost invariably accompanied by serous infiltration of other parts of the uveal tract. The symptoms are the same as just described, but less severe. The tension, however, in serous cyclitis is apt to be increased and the pupil is usually dilated.

Cyclitis Purulenta.—In this there is a very marked lymphoid infiltration. The pus will extend into the aqueous humor and the disease, as a rule, passes over into panophthalmitis. In subacute cases we may find a diminished tension, but there is generally increased tension. All the symptoms of the plastic form are present in this, and even of a higher degree.

CAUSES.—Cyclitis, when not dependent upon other inflammations, most frequently results from some form of injury, as in contusions of the eye or penetrating wounds in the ciliary region; after cataract operations where the incision was far back in the sclera, from dislocation or swelling of the lens from rupture of its capsule. It may occur from a prolapse of the vitreous through a scleral wound, or from a contraction of scars in the ciliary region. It may, however, be spontaneous so far as any direct cause can be determined, and is often from sympathetic inflammation. It chiefly occurs as secondary to inflammations of the iris or choroid.

PROGNOSIS is most unfavorable in the purulent form, as it generally leads to suppuration of the entire eye. In the plastic form the prognosis is also unfavorable, because, from its pathological changes, the vitreous loses its nutrition, becomes fluid, the retina detached, lens cataractous and the eyeball becomes atrophied.

TREATMENT should first be directed to the cause. If dependent upon a foreign body, it may be removed by the magnet; if due to a dislocation or swelling of the lens, remove it; if there is a wound with a prolapse of the iris, it should be drawn out and cut off and a compress bandage applied.

The treatment of inflammation in this portion of the uveal tract will depend almost exclusively upon internal medication. The eye must be kept warm, as in iritis, and Atropine may be necessary, as

the iris is liable to become involved. Special indications for remedies are to be found under iritis.

Injuries Implicating the Ciliary Region are not only dangerous on account of inflammatory complications, but as a cause of sympathetic ophthalmia. Simple incised wounds may readily unite by keeping the eye at rest, or it may be necessary to use a fine suture, which should be inserted from within outward in both edges of the wound. Extensive injuries in this region will usually necessitate enucleation, though under certain circumstances the eye may be preserved, providing the patient is intelligent and will attend to the first unfavorable symptoms which may arise. Foreign bodies must be removed, if it is possible, without too much injury to the tissues, or the eye must be sacrificed.

Paresis Musculus Ciliaris—*Paralysis of the Accommodation*.—This may be either partial or complete and the cause may be either local or general. If but one eye is affected, the cause is more apt to be local, affecting the third nerve in some part of its course, and the primary cause may be syphilis. Some injury of the eye or orbit may cause it, through some reflex influence, as may also some irritation of the fifth nerve, as in decayed teeth, etc. Exposure to draughts of air may also cause a one-sided paralysis of the accommodation. When the paresis affects the ciliary muscle of both eyes the cause is more apt to be general and often from some constitutional disorder. The most frequent cause is diphtheria and comes on usually during convalescence or some time after. Paralysis of the accommodation is also seen after fevers, such as typhoid and recurrent fever. It also occurs in diabetes, articular rheumatism, locomotor ataxia, after debilitating excesses, as masturbation, sexual indulgence, etc. It is sometimes found due to uterine disease and from syphilis. Exposure to draught is a very frequent cause, and it has often been seen following la grippe. It is also present with paralysis of the external muscles in total paralysis of the third nerve.

The diagnosis of paralysis of the ciliary muscle depends upon the one constant symptom, viz., the diminution or complete abolition of the amplitude of accommodation from a recession of the near point. This will always be suspected in subjects who formerly had good vision for near objects, but find they can now only see well at a distance. The pupil will usually, at the same time, be dilated, though

frequently there will be a paresis of the accommodation without mydriasis.

PROGNOSIS is, as a rule, in these cases favorable, for as the majority of cases result from diphtheria, fevers, etc., the proper treatment will effect a relief. It must be borne in mind, however, that the paralysis of the accommodation may be the forerunner of some grave general condition which may be of serious import to the life of the patient, as, for example, when due to diabetes, to some obscure cerebral or spinal disease, etc. Hence the prognosis always depends upon a correct diagnosis as to the cause of the malady.

TREATMENT.—The cause of the paralysis must be sought out and be given due consideration in the treatment. As precautionary measures, all convalescents should be carefully warned of the danger of overtaxing the eyes. The use locally of Eserine or Pilocarpine of sufficient strength to contract slightly the pupil and stimulate the accommodation is of great value. Eserine is the most active of the two, and the best results are had from a weak solution of the sulphate. A one-tenth to one-half grain to the ounce solution, instilled once or twice a day, is sufficient and usually better than a more concentrated solution. Pilocarpine is less energetic, and a solution of from two to four grains of the muriate to the ounce may be instilled once or twice a day if any unpleasantness is experienced from the Eserine.

Galvanism should also be employed, using from eight to twelve cells, with the positive pole applied to the base of the occiput and the negative over the closed lids. The current should be applied for two or three minutes daily. Patients may also be allowed moderate use of the eyes for necessary work with the proper convex glass.

The use of the appropriate remedy will also be of much service, and attention is especially directed to Acon., Argent. nit., *Caut.*, *Gels.*, Opium, Paris quad. and Physostig. See indications under *Paralysis of the Ocular Muscles.*

Spasmus Musculus Ciliaris.—*Spasm of the Accommodation.*—This may be *clonic*, when existing only during convergence, or during fixation for distinct vision and ceases when the eye is in repose; or *tonic*, when it is permanent and only yielding to mydriatics. Spasm usually affects both eyes in an equal degree, but may exist in

one eye alone, or be of a greater degree in one eye than in the other. Spasm of the ciliary muscle may occur in normal eyes or in any refractive error of the eyes. It causes a decrease of the hypermetropia and an increase of the existing myopia. It may produce an apparent astigmatism or conceal a real one. Patients will usually complain of an indistinctness of distant objects, while near objects are held closer to the eye than they should be, and they will have tired, strained feelings of the eyes together, with headaches upon using the eyes.

There may be in some cases a tendency to convergence of the eyes, owing to the intimate relation between accommodation and convergence. Spasm of the accommodation is frequently found in children, with hypermetropia from the strain occasioned by use of the eyes; it may be produced in emmetropes from prolonged use of the eyes and in myopes from the use of too strong glasses. As other local causes we find it in injuries of the eye, in inflammation of the cornea, conjunctiva, sclera or lids. It may occur as symptomatic of affections of the central nervous system, as in epilepsy and hysteria. Spasm of the ciliary muscle may or may not be associated with contraction of the pupil. The condition occurs most frequently among asthenic subjects and more especially among young girls. The diagnosis of spasm depends upon a comparison of the apparent refraction with that which is real, as determined by an examination under the influence of a mydriatic.

TREATMENT.—In aggravated cases of spasm of the ciliary muscle the regular and prolonged use of Atropine or the constant use of convex glasses may be necessary, but usually internal medication, with rest of the eyes for near work, will suffice to diminish the spasm; after which any anomaly of refraction may be corrected.

Agaricus.—In spasm of the ciliary muscle especially if associated with spasm of the lids or general chorea. *Twitchings of the eyelids.*

Eserine.—Dr. N. L. Macbride has pointed out the value of this drug in spasm of the accommodation, and has found it of much value in young hyperopes of slight degree, associated with headache and general asthenopic symptoms. The physiological action of Eserine is to produce an almost perfect picture of spasm of the accommodation.

Jaborandi.—In *spasm of the accommodation, or irritability of the*

ciliary muscle, there is no remedy so frequently useful as this. Many cases of simulated myopia have yielded to its use. *Everything at a distance is blurred without concave glasses, though near objects are seen distinctly. The vision may be constantly changing. Nausea or vertigo on using the eyes. Eyes tire easily and are irritable, especially on sewing. Twitching of the lids and pain in the balls. Spasm of the internal recti muscles.*

Lilium tig.—Spasm of the accommodation in low degrees of myopic astigmatism, when the cylindrical glasses are not worn with comfort.

Physostigma ven.—In its proving there has been developed marked spasmodic action of the ciliary muscle and muscles of the lid. It has, therefore, been used with manifest advantage in these conditions, particularly the former, and, as spasm of the ciliary muscle is frequently found in myopia, it should be thought of in this anomaly of refraction. The patient cannot read long on account of this spasm and must bring the book near the eyes. There is also generally to be seen *twitchings in the lids and around the eyes* when *Physostigma* is required. The pupil is contracted.

Nux, *Puls.* and *Sulph.* have also been used with benefit, as may any of that class of remedies denominated as antispasmodics.

Irido-choroiditis (*Irido-cyclitis*).—Owing to the fact that the iris, ciliary body and choroid form one continuous tissue, any inflammation involving one structure is prone to extend through the whole uveal tract. There are in irido-choroiditis, as in both iritis and cyclitis, three pathological changes that may occur, viz.: Plastic, serous and suppurative, each taking on the same changes as have already been detailed under the iris. Clinically the disease may be divided into two forms.

The first form is the result of an iritis in which there has been posterior synechiæ, with exclusion of the pupil. In this the pupil may remain clear, but there is soon noticed a gradual bulging forward of the iris, in one portion, in knob-like protuberances which may be confined there or extend, involving nearly the whole iris. The bulging is due to an accumulation of fluid in the posterior chamber and occurs in spots, because the inflammation of the iris has weakened the tissue at these points. The iris is discolored, its fibrillæ appear stretched and its veins are enlarged and tortuous

in their course. The tension soon becomes increased, but, as the disease advances toward an atrophied ball, becomes diminished. The vitreous is diffusely clouded, there is ciliary injection, considerable pain, which is usually worse at night; the eyeball very sensitive to touch and the anterior chamber is shallow, due to the bulging of the iris.

The second form of irido-choroiditis may be called a parenchymatous variety, as there is a considerable swelling and proliferation of the connective tissue, with an engorgement of the vessels throughout the whole uveal tract. There is occlusion of the pupil and gummata may be found. A false membrane, tough and tenacious, forms behind the iris and may extend back over the ciliary processes and choroid. This membrane becomes organized, adheres closely to the capsule of the lens and may undergo secondary contraction, causing possibly a rupture of the capsule of the lens or detachment of the ciliary body. In the later stages the retina may be detached and the plastic exudation on the choroid may become cartilaginous or bony.

In this form there is no bulging. The iris is perfectly straight, though it may be pressed forward, with occlusion of the pupil. The anterior chamber is shallow. The iris is discolored, appearing of a dirty red; its tissue is stretched, and large vessels are seen coursing across it. The tension is increased at first and later diminished. The vision is destroyed, and, when it is lost early in the disease, the choroid is probably the seat of the original inflammation, as when the disease commences in the iris the loss of vision does not come on as rapidly.

COURSE.—Irido-choroiditis is usually chronic in its course and the disease generally terminates in an atrophy of the eyeball. In rare cases it may, however, come to a standstill, the form of the eye be saved and still more rarely some vision be restored.

CAUSES.—The most frequent causes are the adhesions between the iris and lens, which result in frequent recurring attacks of iritis with more and stronger adhesions until there becomes an occlusion of the pupil, and, if then another attack of iritis occurs, it will almost inevitably lead to an involvement of the ciliary body and choroid. Trousseau¹ describes a peculiar form of irido-choroiditis

¹ Soc. d'Ophth. de Paris, June 3, 1890.

with hypopyon recurring regularly a few days before the menses and disappearing in a few days. The condition lasted for a long time, extending through the period of one pregnancy, ceasing with the menses during gestation and returning again after pregnancy. Similar cases were reported by others. Irido-choroiditis may also arise from injuries or wounds of the eye, as from foreign bodies, after operations, especially cataract extractions. It also is apt to occur as sympathetic ophthalmia in consequence of an injury to the other eye.

PROGNOSIS.—As a rule the prognosis in irido-choroiditis is unfavorable, but depends somewhat upon the extent of the intraocular changes. If seen early, before the vision and field of vision have become much impaired and there are but slight changes in the iris, it may be more favorable.

TREATMENT.—Our first object should be to prevent the disease, if possible, by properly treating every case of iritis, so that no posterior synechiæ may remain to cause inflammation. In order to do this and also to prevent or break up adhesions which may tend to form between the iris and lens, Atropine should be energetically employed as early as possible and continued during the course of the disease, unless there is exclusion or occlusion of the pupil, where it will be of little service. Leplat¹ reports several cases of iridocyclitis in elderly people and cautions against the use of Atropine in such cases when the tension is increased, and claims better results are to be had from using Eserine, and, if necessary, puncture, combined with subcutaneous injections of Pilocarpine. If we have to deal with that form of irido-choroiditis in which the iris is bulged forward in knob-like protuberances, with complete adhesion of the pupillary edge of the iris to the lens, an *iridectomy* is indicated; but if it is the parenchymatous variety, with adhesion of the whole of the posterior surface of the iris to the lens, iridectomy will do more harm than good. If a foreign body should be the cause of the inflammation, it must be removed if possible, though when the injury in the ciliary region is very great, it is better to enucleate the eye in order to prevent trouble in the other. If the inflammation of the uveal tract is caused by sympathetic irritation

¹ Ann. de la Soc. méd.-chir., de Liège, 1889.

from an injured eye—and this is the most common form of sympathetic ophthalmia—the injured eye, especially if sight is lost, should be removed upon the first symptoms of irritation or as early as possible, unless the inflammatory process is very severe, when it may be better to wait until it has subsided in some degree. If there is some sight in the injured eye, it is often difficult to decide whether enucleation is advisable or not. As a rule, an eye that has been lost from any cause and which remains painful, even if there are no symptoms of irritation in the healthy eye, should be removed. The irritation being probably transmitted by the ciliary nerves, division of these nerves (optico-ciliary neurotomy) has been recently proposed as a substitute for enucleation. It may be adapted to rare cases.

In old cases, in which the lens has become cataractous, it should be removed.

In the treatment of all forms of inflammation of the uveal tract *complete rest* of the eye for a long period must be insisted upon. In acute cases the patient should be confined to the house and treated as for iritis. In chronic cases it is better to allow moderate exercise in the open air, with the eyes protected by a bandage or colored glasses. The diet should be nutritious and generous, especially if the patient is feeble and ill-nourished.

The chief reliance must be placed upon internal medication, but for special indications refer to the therapeutics of iritis and choroiditis. The following remedies, however, have been more commonly used with advantage and would be among the first suggested to our minds: *Apis*, *Ars.*, *Asaf.*, *Aur.*, *Bell.*, *Bry.*, *Gels.*, *Hepar*, *Kali iod.*, *Merc. corr. and iod.*, *Prunus spin.*, *Rhus*, *Sil.*, *Sulph.* and *Thuja*.

CHAPTER X.

Sympathetic Ophthalmia.

Numerous affections of the eye are supposed to be due to a pre-existing inflammatory condition of the other eye and hence are called *sympathetic*. The most frequent form of sympathetic inflammation is that of irido-cyclitis, or irido-choroiditis, although we may have a sympathetic iritis, keratitis, choroiditis, neuritis, retinitis, etc. Glaucoma even has been considered by some as possibly occurring from sympathetic irritation, although this is now disputed by the best authorities. As the disease may assume so many varying forms and may result in pathological changes in nearly all the structures of the eye, a special study of its pathology is therefore too complex to be undertaken here. We will, consequently, content ourselves with simply referring to the pathological processes detailed under the study of the other diseases and especially those of the uveal tract. This disease, in its more serious forms, is of the greatest importance, for, if not cut short in its earlier stages, it almost inevitably leads to blindness.

The disease has what may be termed a prodromal stage, during which it is called *sympathetic irritation*. At this time the patient complains that the eye soon grows tired on using it. There is more or less sensitiveness to light, lachrymation and slight pericorneal redness. The most important symptom at this period is a diminution in the range of accommodation, owing to the affection commencing usually in the ciliary body. During this stage there is also apt to be found a more or less sensitive spot in the diseased eye. These symptoms of slight irritation of the eye may exist for a long period, or possibly might never lead to the dreaded sympathetic inflammation. Sympathetic ophthalmia may also set in without any of the previous symptoms of sympathetic irritation.

SYMPTOMS.—There is a loss of vision, due to haziness of the vitreous, which in the early stages is diffuse, but later we find large opacities floating about. Photophobia, lachrymation and ciliary

neuralgia are present in varying degrees in different cases. The ciliary region is sensitive to touch. The range of accommodation, when it can be tested, is much diminished. There may be ciliary injection, or chemosis and the lids may be red and swollen. On examination of the eye we find the aqueous is hazy, due to the exudation into the aqueous from the ciliary processes, and this exudation may be deposited in masses on the endothelial layer of the cornea. The exudation extends into the iris and we have posterior synechiæ, which form very rapidly, even resulting in complete exclusion within twenty-four hours, but may be more gradual. As the exudation goes on the iris becomes very much swollen, a false membrane forms attaching it to the lens throughout its entire extent, resulting in complete occlusion of the pupil. There is a venous engorgement of the iris, and its entire structure becomes degenerated. The anterior chamber becomes shallow, the opacities in the vitreous increase all the time, the choroid becomes affected and we have an inflammation of both the choroid and retina. The periphery of the iris is drawn back and its pupillary edge, together with the lens, is pushed forward. Vision at last becomes entirely lost. The tension is increased during the early stages, but later becomes diminished. The field of vision becomes contracted very early in the course of the disease.

The foregoing describes a marked or severe form of sympathetic inflammation, but we may have a more mild type of the disease, which assumes a serous rather than a plastic form of inflammation. In this there will be some pericorneal injection, the iris somewhat discolored, with a few slight adhesions and the sight slightly reduced. In some cases there may be a papillitis or a neuro-retinitis, and in these light cases the eye may entirely recover. Other more rare conditions, such as conjunctivitis, keratitis, etc., have been reported as due to sympathetic irritation and have been relieved upon removal of the diseased or exciting eye.

CAUSES.—The most frequent causes of sympathetic inflammation are foreign bodies and injuries, especially when occurring in the ciliary region; operations at the corneo-scleral junction, as in cataract extractions, contraction of scars, or rupture of the sclera at the ciliary region, previous inflammations of the eye where the eye has become atrophied and especially when accompanied by chalky or bony for-

mations within the eye, intra-ocular hæmorrhages or contusions of the eye, prolapse of the iris and anterior synechiæ, external irritation of an atrophied ball, as when an artificial eye is worn upon a shrunken stump, and in fact any eye that has been lost and is painful may awaken a dormant tendency to sympathetic inflammation.

The period during which there is a danger of transmission of sympathetic inflammation varies from two weeks to thirty years; the most frequent period, however, seems to be from four to eight weeks. There is, then, practically no period during which an injured or diseased eye may not be the cause of sympathetic irritation of its fellow. From the statistics of this disease by Gunn and others there seems to be no difference in the result or severity of the sympathetic inflammation, whether there is a short or a long interval between the primary lesion and the onset of the sympathetic disease of the other eye. According to some there is a greater tendency to sympathetic ophthalmia in young individuals, while others hold that there is less. It is also claimed by some that it never occurs unless there is a perforating lesion of the exciting eye; or, at any rate, that it is extremely rare.

As to the method of transmission of the sympathetic irritation very much has been written and many experiments made, still the exact mode is far from being definitely settled. The condition, it seems to us, from the experiments of the various investigators of this subject, may be transmitted either through the ciliary or the optic nerves, with the weight of the evidence in favor of the former.

Mackenzie in 1840, and followed later by Alt, Leber and Deutschmann, by means of experiments and microscopic examinations, have argued in favor of the optic nerve being the path along which the affection extends. Deutschmann¹ made experiments upon rabbits, first by injections of spores of the *aspergillus fumigatus* into the vitreous, with the result of causing choroido-iritis in the injected eye, and four weeks later the same condition, together with opacities in the vitreous, was found in the other eye. Microscopic examination revealed an interstitial neuritis extending up to the chiasm and down to the other eye by the way of the optic nerve. Later he resorted to the pus organisms for the inoculating material and made

¹ v. Graefe's Archiv. für Ophthalmologie, xxviii., 2; xxix., 4; xxx., 4.

injections of a suspension of staphylococcus pyrogenes aureus. Subsequent microscopic examination reveals purulent infiltration of the optic nerve, with diminishing intensity up to the chiasm, and then with increasing intensity down to the other eye. He therefore concludes that sympathetic ophthalmia is propagated through the optic nerve. A few years later Deutschmann¹ published his views in a very complete paper and claims that the disease is a process of microphytic origin, passing from one eye to the other through the optic nerve apparatus and suggests that the name *ophthalmia migratoria* better expresses the character of the disease than does sympathetic ophthalmia. He also claims that it should be kept separate from an affection of the other eye dependent upon an irritation of the ciliary nerves of the first eye, and which should be called reflex irritation. In opposition to these theories of optic nerve transmission we find H. Muller² pronouncing in favor of the ciliary nerves. Randolph³ details numerous exhaustive experiments upon both dogs and rabbits, made with the expectancy of confirming Deutschmann's results, but in no instance was sympathetic ophthalmia a sequel of the operation, and hence his results were entirely negative so far as confirming those obtained by Deutschmann. Galezowski⁴ thinks the inflammation is carried from one eye to the other through the ciliary nerves and their lymph channels and not through the optic nerve. Further, the fact that sympathetic ophthalmia is most frequently apt to occur after wounds in the ciliary region, and also that it never, or very rarely, occurs in suppurative diseases of the eye, such as panophthalmitis, where the ciliary nerves are destroyed, leads us to think that the most frequent path of the transmission is through the ciliary nerves.

PROGNOSIS.—In the prodromal stage, or that of sympathetic irritation, the prognosis may always be considered favorable; but if later, after exudation has taken place, it is unfavorable. The prognosis is always more favorable when the course of the disease is slow, rather than rapid, and more favorable in the serous than in the plastic form.

¹ On Ophthalmia Migratoria (sympathetic ophthalmia) Hamburg and Leipzig, 1889.

² Archiv. Ophthal. (Graefe) vol. iv., 1, 1858.

³ Archiv. Ophthal., June, 1888, p. 188.

⁴ Soc. d'Ophth. de Paris, October 7, 1890.

TREATMENT.—Our attention should first be directed to the exciting eye, and if we find it at all irritable, sensitive to touch and the vision lost, an enucleation of that eye should at once be made. If the affected eye is only in the stage of prodromal irritation, the removal of the eye which is creating the sympathetic irritation will usually result in at once checking the disease and restoring the eye to its normal condition. If the exciting eye contains a foreign body and is itself undergoing inflammatory changes, it should be removed, even though possessing more or less vision, as that eye will probably be lost, and, by its removal, the other may be saved. The advisability of removing an exciting eye when it has a certain amount of vision, in a plastic form of sympathetic ophthalmia, is a decidedly delicate question, because there is a very grave probability of losing the sympathetic eye, while the eye originally causing the irritation may come out with the best vision.

Enucleation should always be practiced in the irritative stage, if possible, as often, if delayed until the sympathetic eye has become actively inflamed, its removal then will not serve to check the progress of the disease. In all cases where one eye has become lost, and especially when from injuries or wounds in the ciliary region, the patient should be thoroughly cautioned as to the possibility of its serving *at any time* to cause destruction of the other eye from sympathetic ophthalmia and its removal advised. If enucleation is not submitted to at this time, they should be warned of the importance of immediate attention upon the slightest sign of any pain or irritation.

Optico-Ciliary Neurectomy.—The operation of division of the optic and ciliary nerves behind the eyeball has been advised and practiced by some. Its only claimed value is in the retention of the eye. Schweigger and others recommend it as a preventive measure; but, as a remedy in the inflammatory type, it is untrustworthy, and even in the stage of irritation it ranks below enucleation. The operation may be performed without division of the muscles, by incising the conjunctiva between the superior and internal rectus, and dissecting back with the blunt scissors to the vicinity of the optic nerve. Then, by rotating the globe downward and outward, insert a strabismus hook, with which you catch up the optic nerve and drag out as far as possible. The scissors are now inserted over the hook and

the nerve severed as near to the apex of the orbit as possible ; the nerve is then drawn out, and, with the forceps and seissors, cut off all the nerve tissue possible close to the eye. The eye is then restored to its place and the conjunctival wound closed with sutures. Profuse hæmorrhage and reaction are apt to follow from this operation.

In addition to the operative measures when an eye is sympathetically inflamed it should be given the same treatment as that for irido-choroiditis. The use of Atropine to dilate the pupil and relieve the pain may be tried, if there is not an exclusion of the pupil, when it had better not be used. The patient should be kept at rest in a darkened room. Hot fomentations or the cotton pad may be applied. Ice has been employed in some cases, though as a rule it is not advisable. Iridectomy has been recommended, but sclerotomy is better, if the tension is increased and the eye painful. The remedies most apt to be of value are Bell., Merc., Sil., Kali iod., Rhus tox. and Bry. For special indications see Part II.

CHAPTER XI.

Diseases of the Choroid.

Anatomy.—The choroid is that portion of the uveal tract extending from the ciliary body backward to the optic nerve. It lies between the retina and the sclera and is principally composed of blood vessels and pigment. The choroid may be considered the nutrient membrane for the interior structure of the eyeball, and consists of four layers. The outermost layer is composed of loose connective tissue and of irregular shaped pigment cells; these connective-tissue fibres extend into, and are derived from, the sclerotic, and the meshes of these fibres form spaces conveying lymph. This lymph-space is held to be in direct communication with that of the capsule of Tenon and the other lymph-spaces of the eyeball. In separating the choroid from the sclera, these fibres are necessarily torn, and that portion remaining adherent to the choroid has been termed the lamina supra-choroidea, and that part remaining attached to the sclerotic, the lamina fusca. The next layer is that of the tunica vasculosa—a layer of large blood vessels which forms a large portion of the parenchyma of the choroid. The third layer, known as the chorio-capillaris, is made up of the finer branches or capillaries of the arteries and veins of the tunica vasculosa. These two layers, together with a small amount of connective tissue, some elastic fibrillæ, and cells, both pigmented and unpigmented, form the parenchyma of the choroid. The blood supply of the choroid (see Fig. 32) is chiefly derived from the short posterior ciliary arteries, which pierce the sclerotic obliquely and enter the choroid and branch off, anastomosing with the long posterior and the anterior ciliary arteries. The veins, beginning as capillaries in the chorio-capillaris, take, in the tunica vasculosa, a whorl-like form and uniting into from four to six large trunks called the *venæ vorticosæ*, pass obliquely through the sclera at about the equatorial region of the eye and empty in the ophthalmic vein, a small amount of the blood from the anterior part of the

choroid passing out through the anterior ciliary veins. The parenchyma of the choroid also contains a great many nerves coming from the short and long ciliary nerves and which form in the choroid fine plexuses of nerves with many ganglionic cells. The most internal layer of the choroid is called the lamina vitrea or elastica. It is an elastic and perfectly transparent membrane, upon which the (uveal) pigmented epithelium lies. This pigmented epithelium, lying between the choroid and retina, has been claimed by different authorities to belong both to the retina and the choroid; it, however, remains attached to the choroid when the retina is removed from the eye. Nearly every pathological condition of the choroid exerts an influence upon this layer of pigment, while important changes are apt to occur in the retina without any alteration in these pigmented epithelial cells. As it is generally considered to be anatomically a part of the retina, we will consider its further description under the retina.

Hyperæmia of the Choroid.—Owing to the general continuity of tissue with the ciliary body and iris, and to its excessive vascularity, the choroid is necessarily very apt to become hyperæmic from almost any inflammatory changes of the eye. In fact, hyperæmia of the choroid undoubtedly is present more often than is generally recognized. The diagnosis is difficult to make on account of the pigment layer in front of it, and is especially so in dark people. In blondes and albinos the choroidal vessels may be seen and the diagnosis aided. The only symptom, however, of diagnostic value is a diffuse hyperæmia of the optic disc. Hyperæmia of the choroid is distinguished from a hyperæmia of the optic nerve and retina by the fact that in the former the redness of the disc is diffuse and its outlines are sharp and well defined, while in hyperæmia of the nerve and retina the outlines of the disc are ill-defined and the redness has more of a striated appearance. The treatment is detailed under that of choroiditis in general.

Choroiditis.—The appearance of the healthy choroid must first be carefully studied before one can fully appreciate changes, whether inflammatory or otherwise, of its structure. The color of the fundus of the eye, when examined with the ophthalmoscope, varies in different individuals according to the amount of pigment granules contained within the pigment or uveal layer. In fair per-

sons we find the fundus appearing of a yellowish-red color and the vessels of the choroid can usually be plainly seen (see Plate I., Fig. 1); in darker persons and negroes the color varies from a brownish red to a slate-color and the choroidal vessels are entirely hidden by the pigment layer. The color and intensity of the light used and the extent of the dilatation of the pupil also serve to affect somewhat the color of the fundus.

Great alteration may take place in the choroid and nothing be discernible; in fact, in some cases it is only when the retinal pigment-cells have become affected by the pathological process that ophthalmoscopic changes are observed. Hence, characteristic appearances of choroiditis are only seen when the retina has become affected as well; that is, when the disease has become a choroido-retinitis. Clinically, however, the disease is still a choroiditis, even though the outer layer of the retina has become secondarily affected. Inflammation of the choroid may be the same as in other divisions of the uveal tract, of a serous, plastic or purulent type.

Choroiditis Serosa.—Is considered by some authorities as a form of glaucoma.

PATHOLOGY.—There is at first a general or localized hyperæmia, especially affecting the veins of the choroid. Following the hyperæmia there is either a serous or sero-fibrinous exudation, which is found extending inward either into the pigment layer of the retina, between the retina and vitreous, or into the vitreous body itself. The exudation may result in causing a detachment of the retina from the choroid, or of the vitreous body from the retina. In either case there must be first some alteration in the consistency of the vitreous, and there may be sometimes a liquefaction of the vitreous without any detachment. The increased secretion of a serous fluid within the eye may, when the channels of excretion have become altered or obliterated, result in glaucomatous symptoms.

SYMPTOMS.—There may be slight ciliary injection and the dotted appearance of the cornea, as in serous iritis. The aqueous and vitreous humors are slightly hazy, causing a general indistinct and hazy appearance of the fundus. Fine floating opacities may be discovered in the vitreous and vision is impaired in proportion to the opacity of the media. The tension should always be examined, as it is very liable to become increased and glaucomatous symptoms

set in. Serous choroiditis seems often to be associated with syphilis, rheumatism or gout, and generally occurs as a complication of serous iritis.

The *treatment* is the same as with other inflammations of the choroid, but the use of remedies, especially Gels. and Bry., is very essential.

Choroiditis Disseminata Simplex.—Simple disseminated choroiditis is of the plastic form of inflammation.

PATHOLOGY.—Plastic choroiditis never attacks the whole choroid, but takes place in small patches, which may coalesce and grow larger. The hyperæmia in this form is followed by a fibro-cellular exudation into the stroma of the choroid, and we find numerous small nodules composed of a fibrinous substance and round cells. The retina and pigment layer at this stage are normal, or only slightly elevated by the underlying infiltration. Absorption may take place at this stage, leaving the stroma of the choroid normal. If the process goes on, there is a proliferation of the pigment layer over the nodules, the exudation presses more and more upon the retina, the layer of rods and cones become involved and the tissue of the retina is affected. The proliferation of pigment extends into the external granular layer, and, when the exudation extends deeply into the retina, the radial fibres of the retina run into the exudation and become united with the fibrillated structure of the nodule. In the later stages the cell elements gradually disappear and the fibres retract, leaving a depressed retinal scar. The cells covering the exudation lose their pigment and may be totally destroyed. Their pigment, having thus been freed, is taken up by the cells at the periphery of the patch of exudation, and then we have the characteristic white atrophic spot surrounded by a dark pigmented border.

SYMPTOMS.—The subjective symptoms of this disease are not at all prominent or characteristic. They will simply complain that their eyes feel a little weak and that the vision does not seem quite as clear as formerly. Very frequently we find, upon ophthalmoscopic examination, extensive choroidal changes with little or no loss of the visual acuity. Randolph¹ reports two cases of very pronounced disseminate choroiditis with preservation of normal acute-

¹ Archiv. Ophthal., vol. xviii., 4, 1889.

ness of vision. Often there is some night-blindness in those cases of marked choroidal changes, even when the vision is good. Slight scotoma are frequently complained of, especially in the later stages, and upon testing the field of vision we are apt to find it somewhat contracted. All the subjective symptoms are apt to be more marked during the stage of exudation than in the atrophic stages of the disease. The extent of the visual disturbances and the other symptoms depend, in a great measure, upon the location of the disease—if near the periphery, the effect is of course much less than when occurring at or near the macula. As the disease advances toward the macula the patient may complain that objects looked at appear distorted (*metamorphopsia*). This is due to the exudation causing a change in the relative position of the percipient elements of the retina. Again, all objects may appear diminished in size (*micropsia*) or unnaturally enlarged (*macropsia*). In the *micropsia* there is, owing to a fresh exudation, a separation of the retinal elements at the point of such an exudation, and the image of any object falling on such a point affects a smaller number of retinal elements than normal and the object appears smaller. In *macropsia*, on the other hand, there is a greater approximation of the retinal elements, due to the contraction of an old exudation or some other atrophic change, and objects appear enlarged. *Hyperæmia* of the disc and haziness of the vitreous may sometimes be present when the disease has reached the neighborhood of the optic disc; or, on the other hand, if the disease extends far forward, it may result in some affection of the ciliary body or iris.

The most characteristic indications of choroiditis are, however, only to be determined by an ophthalmoscopic examination. In the early stages, if occurring in dark persons, it is difficult or impossible, owing to the greater amount of normal pigment, to recognize the first changes. If, however, the patient is a blonde, there is first seen a slight injection of the choroid in spots. Following this, in the stage of exudation, there may be seen numerous yellowish-red nodules, of a more or less circular shape, varying in size, scattered about through the equator of the eye. When the disease is acute, there may be slight haziness of the retina around the optic nerve, and possibly slight haziness of the vitreous. After a longer or shorter period the color of these plaques of exudation changes to a

yellow and later to a white, or a bluish white appearance, and, owing to the pigment proliferation around their borders, become surrounded by black masses of pigment. (See Plate I., Fig. 4). The stage of the disease is determined by the appearances of these patches, which are, in the atrophic stages, white in color—due to the showing through of the sclera and to the cicatricial tissue itself, they have irregular margins, are more or less surrounded by pigment, and choroidal vessels may be seen here and there passing through the white spot. In the stage of exudation the choroidal vessels are entirely hidden and the color of the patches are of a yellowish red, with no pigment. In atrophy there is a depression or sinking of the patch, while in exudation there is an elevation. Frequently there may be even in the same eye all stages of the disease.

Choroiditis Areolaris.—This is only a variety of the disseminate form just described, in which the nodules have more of an areolar structure and with greater proliferation of the pigment over the nodule. The patches in areolar choroiditis are usually larger, of a round or oval shape, and their location is especially around the optic nerve and the macula. The recent patches appear as very dark masses of pigment. As they grow older they gradually lose their dark color and finally appear white, surrounded by a black ring. In this form the pigment spots and exudation bear a certain relation to each other; the pigment spots are first noticed, and, as it progresses, the centre of the patch becomes lighter, of a yellowish-white appearance, and gradually goes on to a clear white spot surrounded by pigment. The choroid between the patches remains perfectly healthy, and, although the location of the disease is all around the macula, it is usually last affected; but when it is involved, it often becomes affected suddenly. This form is especially found in young persons and will exist for a long time with good vision—the macula rarely being involved before middle life.

Choroiditis Circumscripta, or *Choroido-retinitis Centralis*, is simply another form of disseminate choroiditis occurring in and near the macula. There is in this usually the development of a single nodule, but very rarely there may be two or three, consisting of a connective tissue frame-work, with cells and agglomerations of pigment. It arises in the choroid, but extends into the layers of the retina, which is raised at the point of the nodule, but is perfectly

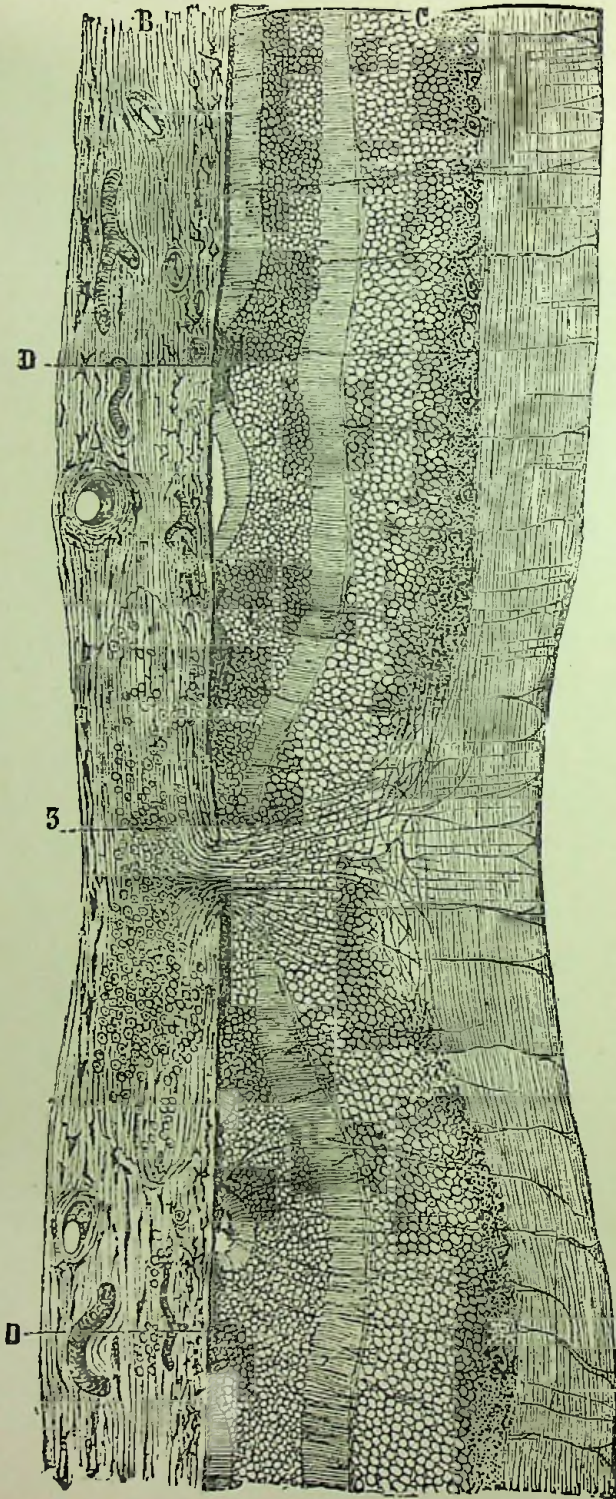
normal and healthy around it, thus proving the affection of the retina to be due merely to pressure and not to inflammation of its own tissue. It goes on to atrophy with shrinking of the cicatrix, which draws the retina back along with it. (Fig. 39.)

The disease is always uniform in that scattered nodules are never found, and, while there may be more than one nodule, they are always closely arranged around the macula. An ophthalmoscopic examination shows at first a reddish-yellow, or later a bright yellow, round or oval spot at the macula. It is in the earlier stages elevated, well defined and may be vascular, while in the later stages it becomes whiter as it goes over into atrophy and then a depression occurs. This form of choroiditis affects vision by causing a very pronounced scotoma, which is persistent and especially annoying in the earlier stages; metamorphopsia is also usually complained of.

Choroiditis Syphilitica, or *Choroido-retinitis Syphilitica*, is still another form of plastic choroiditis, the pathological changes in which are the same as already described under choroiditis disseminata and choroiditis circumscripta (Fig. 39). This form of choroidal affection, if not invariably, is, in a large majority of cases, a manifestation of syphilis, and generally appears in the late secondary or early tertiary stage of syphilis. It seems to be most apt to occur in cases where syphilis has been acquired late in life, is most frequently found affecting both eyes and is sometimes preceded by an attack of iritis.

SYMPTOMS.—The characteristic symptoms of this affection are the fine, dust-like opacities of the vitreous, seen upon an examination by the direct method, with a weak illumination (after causing the eye to move rapidly upward and downward), to rise like dust before the wind. The opacities in some cases may form flakes or filaments, which, however, are seen to float up and down in a medium full of the characteristic dust. In certain cases these coarser opacities may increase greatly in size, but the peculiar dust appearance is always present and remains throughout the whole course of the disease. Another peculiarity of this dust-like haziness of the vitreous is that it varies considerably in amount from time to time during the course of the affection, and, owing to this, the vision will improve or diminish often within a few hours. When the vitreous dust is not sufficiently dense to obscure a view of the fundus, we will often

FIG. 39.



Choroido-retinitis. *B.* choroid; *C.* retina; *3.* choroidal nodule, to which the retina is attached by its radial fibres, cicatricial contraction well advanced. *DD.* points showing a reunion of the choroid and retina.

see a hyperæmic condition of the disc, an indistinctness of its outlines and a slight haziness of the retina.

Hemeralopia, or night-blindness, is almost universally present among patients suffering from double specific choroiditis, and, in all cases where but one eye is affected, the size of objects seen with the diseased eye, when compared with the healthy, appear small (micropsia). Another characteristic sign is the subjective perception of luminosities (phosphenes), generally seen as sparkling scotoma and are always seen upon entering a bright light.

COURSE.—This form of choroiditis may run an acute course, recovering with nearly perfect vision and leaving no trace behind. More frequently, however, there remains some impairment of vision due to the persistence of vitreous opacities, which may be very dense, or to the changes in the choroid, similar to those in the disseminate form, which may develop gradually in the later stages of the disease.

CAUSES.—Choroiditis of all forms, in a very large proportion of cases, is due to syphilis, and in those cases not resulting from that disease there seems to be a decided hereditary trait. Other cases are connected with, or extend from, a progressive posterior staphyloma. The disseminate and central forms of choroiditis may occur spontaneously, so far as any direct cause can be determined, while the areolar form seems to occur frequently in tutors, governesses and others of whom it may be said their occupation requires what might be called an intelligent use of the eyes. Gould¹ reports cases of central choroido-retinitis, which he attributes to ametropia, believing that chronic uncorrected ametropia may result in permanent lesion in the region of the macula, with pigmentary changes, which he thinks may result from straining of the retina in an effort to secure a clear image.

TREATMENT.—Under this heading we shall consider the treatment of the several forms of choroiditis already described.

Rest in a darkened room for a long period has been recommended for inflammation of the choroid. This, together with bandaging of the eye, will answer in some cases of acute serous inflammation, but its tendency to impair the general health usually renders it unsafe, especially in chronic cases and in the disseminate form of inflamma-

¹ Archiv. Ophthal., vol. xix., 1, 1890.

tion, in which it is far wiser to allow moderate exercise in the open air, with the eyes protected from the bright light by smoked or blue glasses. *Complete rest* of the eyes from all work should always be required. Atropine may be useful in some cases, as it paralyzes the tensor choroidea, thus preventing any movement of the inflamed tissue upon change of light. In the serous variety, if the intraocular tension becomes increased, frequent paracentesis may be performed, or if this does not suffice an iridectomy must be made. Abstinence from all stimulants and proper hygienic measures are necessary.

Aurum.—Choroiditis, with or without retinal complication, especially if there is *exudation into the choroid and retina or into the vitreous*, causing haziness of the vitreous. We may have sensitiveness to light and touch, ciliary injection and some pressive pain in the eye from above downward or from without inward, aggravated on touch, or pain in the bones around the eye. A general feeling of malaise and depression of spirits is often present.

Belladonna.—An important remedy in *hypercemia* or acute inflammatory conditions of the choroid, particularly of the disseminate variety and accompanied by congestive headaches. The optic disc is of a deep red color and the retinal vessels enlarged, especially the veins. The pupil is slightly dilated, ciliary injection usually marked and eyes sensitive to light, with full feeling as if pressed out of the head. Disturbances of vision are often present, as halo around the light and various flashes of light and sparks. The headache and constitutional symptoms decide our choice.

Bryonia.—*Serous choroiditis*, or inflammation of the uveal tract, following rheumatic iritis. From *serous* infiltration into the vitreous the haziness is often so great as to seriously interfere with our view of the fundus. The vessels of the fundus are congested; the pupils may be somewhat dilated and the tension increased. *The eyeball feels sore to touch and motion, while darting pains through the eye into the head* are usually present.

Gelsemium.—It may be of service in the plastic forms of choroiditis, but its grand sphere of action is in *serous inflammation of the uveal tract*, especially if anterior to the equator, with great haziness of the humors. The impairment of vision will be great; may be slow and gradual or subject to sudden changes. The haziness of the vitreous is usually fine; the tension may be increased and pupil di-

lated. The iris may be involved, with tendency to posterior synechiæ. Transparent sensitive points or vesicles may be found on the surface of the cornea, which come and go suddenly. The pain is dull, aching, pressing, in and over the eyes; may extend to occiput and be relieved by hot applications. Eyeball sore to touch. Heaviness of the lids. Headache, general depression, loss of muscular tone, fever and thirstlessness.

Kali iod.—It is the remedy for *syphilitic chorio-retinitis* characterized by great haziness and exudation into the vitreous, which may vary from day to day; also for *syphilitic disseminate choroiditis*, with little or no haziness of vitreous. Much benefit has been derived from its use in simple disseminate choroiditis even when the atrophic changes in the choroid are far advanced or when the whole uveal tract has become involved.

Kali mur.—The benefit derived from its use in the absorption of exudations has been demonstrated in exudative choroiditis.

Mercurius.—The various preparations are used, according to special indications, though the corrosivus or solubis is more often needed. Mercury is of great value in choroiditis, especially *disseminate*, and when the *iris is also involved* (irido-choroiditis). The syphilitic dyscrasia would particularly point to its use, though it is indicated in non-syphilitic cases. The tendency to the formation of adhesions of the iris to the lens is marked. *The pains are usually intense both in and around the eye*, varying to a great extent in character. The *nocturnal aggravation* of all the symptoms is of importance in the selection of this remedy, as well as the general condition of the patient.

Nux vom.—In disseminate choroiditis occurring in persons addicted to the use of stimulants, also when atrophic changes are even far advanced, Nux often seems to materially improve the degree of vision. The eyes are especially weak and *sensitive to light in the morning*. Gastric derangements and other constitutional symptoms are of great importance in selecting this drug.

Phosphorus.—Both serous and disseminate choroiditis have been benefited, especially when accompanied by *photopsies and chromopsies of various shapes and colors (red predominating)*. We find in the proving of Phosphorus, that it has produced *hypercæmia of the choroid*, and experience shows that it is often adapted to this condi-

tion. When sexual excesses seem to be the cause of the trouble this remedy is indicated. The optic nerve and even retina may show decided hyperæmia. Black spots pass before the vision. There may be some dread of light. The eyes seem *better in the twilight*. Particularly suitable to Men, slender persons, and especially if complicated with cough, etc.

Prunus spin.—Inflammation of the choroid, either with or without iritic or retinal complication. Haziness of the vitreous and other common symptoms of the disease are present, but the characteristic indication will be found in the *pain, which is usually severe, as if the eyeball were being pressed asunder, or else sharp, shooting and cutting through the eye and corresponding side of the head, or crushing in character.*

Pulsatilla.—Hyperæmia of the choroid or sub-acute cases of choroiditis occurring in women of a mild, tearful, yielding disposition and when accompanied by amenorrhœa; also in tea drinkers who are subject to neuralgic headaches. Eye symptoms not characteristic.

Sulphur.—Chronic cases of choroiditis, especially if occurring in a strumous subject. *Sharp darting pains* are usually present. Often assists in clearing the vitreous and completing a cure after other remedies have been used with advantage. The hemeralopia found in some cases may be relieved.

Verat. vir.—Choroiditis, especially in women with much vasomotor disturbance. Aching pains in the eyes, becoming sharp in the evening. Photopsies. Painful menstruation and aggravation of eye symptoms at that time.

In addition to the above, the following remedies have been employed with favorable results: Acon., Arsen., Duboisin, Hepar, Jaborandi, Psor., Ruta, Sil.

Choroiditis Metastatica, or, as it perhaps should be more properly termed, an *Irido-choroiditis Metastatica*, is a purulent inflammation of the choroid which generally affects the whole uveal tract, and may lead to inflammation of all the tissues of the eye, or *Panophthalmitis*.

PATHOLOGY.—The characteristic feature of purulent choroiditis is an infiltration and new formation of cells in the parenchyma of the choroid, and, as the disease advances, the whole structure of the

choroid and uveal tract becomes filled with round cells; its innermost layers become perforated and both the retina and vitreous are infiltrated with pus cells. The purulent inflammation may also extend outward, involving the sclerotic, and thus may finally result in a purulent infiltration of all the membranes of the eye.

SYMPTOMS.—There is usually more or less chemosis, the eyelids may be red and puffy, the eye sensitive to touch and a varying degree of pain. In the acute stages the eyeball may be protruded from the infiltration into Tenon's space and the movements of the eye are impaired. The anterior chamber is shallow from the pushing forward of the iris and lens and the vision is rapidly destroyed.

On examination of the eye we find the iris discolored, irregular or atrophied, and, instead of the normal red reflex from the fundus, we have a decided white appearance, due to the purulent exudation into the choroid and vitreous. The tension of the eye is diminished and it rapidly passes over into an atrophy of the eyeball.

This affection, when occurring in young children, as it frequently does following meningitis, may be confounded with glioma of the retina, in which there is the white reflex from the fundus, but in glioma the reflex is more white, it is usually not all over the fundus, the pupil is apt to be somewhat dilated and the tension is increased.

COURSE AND CAUSES.—Metastatic choroiditis may occur in two ways. First, where it is found in connection with pyæmia, puerperal fever, typhoid, variola, malignant pustule, phlegmonous erysipelas, suppurative endocarditis, acute rheumatism, etc., the immediate cause in these cases is an embolus affecting the choroidal vessels, and this embolus undoubtedly conveys the infecting micro-organism. The choroiditis, when resulting in this way, is usually confined to but one eye, although it sometimes has been found occurring in both eyes. This form is also apt to be very rapid and acute in its destructive course. The purulent infiltration occurs first between the retina and choroid and rapidly extends, involving the whole eyeball.

The second method of choroidal infection is that found following meningitis or cerebro-spinal meningitis, and in these cases it is due to the communication between the sub-arachnoid cavity of the brain and the intervaginal space of the optic nerve, forming a direct channel for the transmission of the inflammatory products to the eye.

One or both eyes may be affected, although more frequently but one. In this variety the course is not usually as acute or as purulent as in the preceding form. Thrombosis of the cerebral sinuses, associated with a thrombosis of the ophthalmic veins, may also give rise to a suppurative choroiditis.

PROGNOSIS.—In all forms of metastatic choroiditis, from whatever cause it may arise, the prognosis is always unfavorable, and but very little can be done for its treatment, because the more severe existing disease demands the attention. Its treatment will be included under that of suppurative choroiditis.

Choroiditis Suppurativa (*Panophthalmitis, Traumatic Purulent Choroiditis*).—This form of purulent choroiditis has, of course, the same pathological changes as described under the preceding disease. Schöbl¹ describes the pathological anatomy in twenty-seven cases of panophthalmitis, and concludes that, from whatever cause it occurs, it commences as a fulminating purulent retinitis or choroiditis, or both together, and from this rapidly extends to the other coats.

SYMPTOMS AND COURSE.—The lids are œdematously swollen, the conjunctiva chemosed, and, from the inflammation of the capsule of Tenon, there is exophthalmos, with limitations in the movements of the eye. The cornea is hazy, the aqueous cloudy and hypopyon rapidly forms. There are posterior synechiæ, the anterior chamber shallow and the tension is liable to be increased. The white reflex from the fundus is present and indicates the formation of pus within the eye. In this form of choroiditis the pain in and around the eye is usually very severe and the eye is sensitive to touch. The rapid onset and course is apt to be accompanied by high fever, vomiting and other general manifestations. Destruction of vision takes place early and the suppurative process quickly results in perforation and atrophy of the eyeball.

CAUSES.—It most frequently develops after some injury of the eyeball, where a foreign body has become lodged within the eye, or may occur from a slight perforation or incision in which possibly some infectious matter has been conveyed into the eye. Thus it may be set up by operations—after the removal of cataracts or any open-

¹ Archiv. Ophthal., vol. xx. 1, 1891.

ing of the bulbus, in cases of purulent or infectious conditions of the eye, as in dacryocystitis. It is most often found in old people and the prognosis is always unfavorable.

TREATMENT.—Our first endeavor should be to save the eye if possible, and with this end in view any exciting cause must be removed. If it is due to a swollen, cataractous lens, this must be extracted; if to an orbital abscess, this must be opened; or if a foreign body is found to be the cause, as is frequently the case, we must try to remove it, unless it is too deep within the eye, when it is far better to enucleate. Enucleation should not be performed while the inflammatory process is very pronounced, as experience has shown that it is advisable to wait until the severity of the symptoms has subsided before we undertake the operation; but if a foreign body is present within the ball, enucleation of the eye is strongly recommended after the inflammation has been subdued, for there is always danger of sympathetic irritation of the other eye.

Enucleation during panophthalmitis has been practiced and recommended by some. Rolland¹ has enucleated in eighty cases without a death. He, however, does not enucleate when phosphenes indicate that the lymph sheaths of the optic nerve have become affected or cerebral symptoms have manifested themselves. Andrews² reported twelve enucleations with no unfavorable symptoms. He also gives the statistics of thirty fatal cases, but believes the danger can be diminished by strict antiseptic precautions and care.

For the disease itself, in the first stage, cold or ice compresses may be used with advantage, but if the pain becomes very severe in and around the eye, especially if suppuration has commenced, more benefit will be gained from warm applications, either dry or moist. Atropine may be of advantage, early, in palliating the pain.

If the pain is very severe and the tension increased, paracentesis or an iridectomy will be found of service. If, however, suppuration has far advanced so as to destroy the eye and the pain is intense, it is best to make a deep incision at once and employ hot fomentations.

A nourishing diet, even stimulants, becomes necessary to sustain the patient's strength after suppuration has taken place.

¹ *Rec. d'ophth.*, 1888, No. 7.

² *N. Y. Med. Journ.*, Dec. 29, 1888.

Aconite.—*First stage*, accompanied by high fever and much thirst. *Eyelids red, swollen, hot and dry*, with much pain in the eye.

Apis.—*Lids œdematous, chemosis, stinging pains* through the eye. Drowsiness and absence of thirst usually accompany the local indications.

Arsenic.—If the patient is very *restless and thirsty*, with œdema of the lids and conjunctiva, and severe *burning pain*. Arsenicum cases are similar to Rhus, though the former does not compare with the latter in degree of usefulness.

Hepar.—*After suppuration has begun. Eye very sensitive to touch and the pains severe and throbbing, ameliorated by warm applications.*

Phytolacca.—Panophthalmitis, especially if traumatic. *Lids very hard, red and swollen*; chemosis and pus in the interior of the eye. Pains quite severe.

Rhus tox.—The most commonly indicated remedy in panophthalmitis, whether it be of traumatic origin or not. It is useful in nearly every stage of the disease, though is particularly adapted to the first. The *lids are œdematously swollen*, spasmodically closed, and upon opening them a profuse gush of tears pours out. The *conjunctiva is œdematous*, forming a wall around the cornea, which may be slightly hazy. The iris may be swollen, pupil contracted and aqueous cloudy, while the pain in and around the eye is often severe, *especially at night* and upon any change in the weather.

Asafoet., Bell., Merc., Sil., Sulph. and other remedies may in certain cases and stages be useful.

Sclerotico-Choroiditis, Anterior.—In this form of choroiditis there is a participation of the sclera in the inflammatory process. The disease is generally circumscribed to a portion of the sclera and choroid in the vicinity of the iris, although it may entirely surround the cornea. It is usually chronic in its nature, the most acute cases often lasting for months, while others will run for years. The appearance resembles very closely that described under episcleritis, although the pain is apt to be more severe and the inflammation and swelling of the conjunctival tissues is more general. The inflammation may extend to the iris, causing synechiæ; or to the cornea, causing what has been called a sclerotising keratitis.

In the chronic form, staphyloma frequently results from a weakening of the sclera, due to the inflammation; it becomes thinned,

presenting then a bluish or grayish-blue color. The staphyloma may be of varying size or shape, and occur either at the sclero-corneal margin or as far back as behind the ciliary region. This gradual bulging is a very slow process, extending often over a period of years and is usually unaccompanied by much pain. It seems to occur more frequently in women than in men and is most liable to occur before adult life.

The *prognosis* is always unfavorable, especially in the more chronic cases, as treatment seems to be of little value. See *Scleritis*.

Sclerotico-Choroiditis Posterior (*Sclerectasia Posterior, Staphyloma Posticum*).

PATHOLOGY.—The pathological changes present in posterior staphyloma are those of an atrophic choroiditis, with a gradual thinning and atrophy of the sclera. It may have small points of exudation, especially near the macula, which have a tendency to coalesce and go on gradually to atrophy. Pigment proliferations are usually present around the edges of the crescent, especially when the condition is progressive. There may also be found opacities in the vitreous and changes in the retina.

SYMPTOMS.—The disease is always found existing in myopic eyes, the eyeball is apt to appear prominent and its movements may be somewhat impaired. Patients will sometimes complain of a feeling of tension in the eyes and there may be some pain in or around the eye, and a tired, strained aching of the eyes when using them. In the progressive stage metamorphopsia is a most frequent symptom, and often times complaint is made of black spots floating before the vision (*muscæ volitantes*), of cloudy vision and subjective light sensations. An ophthalmoscopic examination will show the presence of a white crescent around the optic nerve, usually at its outer side (See Plate I., Fig. 3); the size and shape of the crescent may vary greatly from a small, narrow rim at one side to a spot several times the diameter of the optic nerve.

The optic nerve will have a pinkish appearance, from contrast with the whiteness of the staphyloma, due to the sclerotic shining through the atrophied choroid. The retina is detached somewhat from the choroid and the retinal vessels may be seen passing across the staphyloma. Vision becomes affected by enlargement of the blind spot and there is usually some amblyopia, which may be due

to the reflection of light from the white surface and to the congestion of the retina.

If the disease becomes progressive, the myopia increases, the vision is more and more impaired, the black spots before the eye increase and the optic nerve and retina becomes more irritable. The edges of the crescent show signs of inflammation, appear more irregular and congested; there is slight proliferation of pigment in small spots surrounding the borders of the staphyloma, which increase more and more as the disease advances, and extending especially toward the macula. These spots of pigment gradually coalesce and the centres undergo a gradual change in color until they form one large, white, atrophic spot with a narrow border of pigment surrounding it, similar to the changes found in disseminated choroiditis.

CAUSES.—Posterior staphyloma is considered to be mechanical in its origin. The predisposing cause being congenital and hereditary, the insertion of the optic nerve being obliquely, and to the inner side of the posterior pole of the eye, would render the outer side where the staphyloma occurs weaker, and any abnormality in this direction would increase the weakness at that point. The exciting causes are first an insufficiency of the internal recti, causing a dragging upon the eye from prolonged efforts of convergence, and results in an elongation from an increased pressure upon the eyeball. The use of the accommodation in myopic eyes is another factor in the causation of posterior staphyloma. In myopia the longitudinal fibres of the ciliary muscle are especially developed, and in the effort of accommodation there is a drawing forward of the choroid through the fibres of the tensor choroidea, which results in an increased vascularity of the choroid at its attachment around the optic nerve. In this way there is created a low form of choroiditis at that point which causes a softening and bulging of the tissue. The sclera is more vascular around the optic nerve, and any congestion there would serve to soften its tissue. An increased vascularity would tend to increase the tension, but, owing to the weakness of the sclera, it bulges instead. Bending the head forward, as is so frequently seen in myopic children, seems to increase the vascularity and so increases the staphyloma. Myopia is especially liable to increase from ten to twenty years of age, because at this time the sclera is more pliable and the child is using the eyes more at that period.

COMPLICATIONS.—As a result of posterior staphyloma, we frequently find opacities of the vitreous and pigmentation of the retina from the traction upon it.

The majority of cases of detachment of the retina are dependent upon the posterior staphyloma. Posterior polar cataract is also apt to result from disturbances of nutrition.

PROGNOSIS.—The prognosis should always be guarded, especially if the patient is obliged to use the eyes.

TREATMENT.—As myopia always accompanies this disorder of the fundus, the proper selection of glasses should receive our first attention, the greatest care being taken that they are not too strong. We should next warn the patient against over-use of the eyes for near objects, and also to always avoid stooping or bending forward when using the eyes at near work, as this tends to increase the venous congestion, thus serving to accelerate the progress of the disease. It is injurious to read in the recumbent position. These patients should, therefore, sit upright, with head erect, when reading, and with the back to the light, so that the page will be illuminated and the eyes not subjected to the bright glare of the light. The work or book should not be brought nearer as the eye becomes fatigued, but be laid aside until the eyes are thoroughly rested. If the patient complains of dazzling from the bright light, as is often the case, either blue or smoked glasses may be allowed. In aggravated cases they should be required to abstain from all near work. An effort should also be made to overcome the insufficiency of the internal recti by exercising with prisms, as by increasing the power of convergence we remove somewhat the strain upon the accommodation.

The constant and continued use of *Atropine* for a long time has been found advantageous in some instances.

Belladonna.—Sclero-choroiditis posterior, with *flushed face and throbbing congestive headaches*. The eye appears hyperæmic externally as well as internally. *The optic nerve and whole fundus are seen congested*. Opacities may be present in the vitreous; photopsies and chromopsies are sometimes observed. The eyes are *quite sensitive to light*.

Phosphorus.—Fundus hyperæmic. *Muscæ volitantes* and flashes of light before the vision. Everything looks red.

Prunus spin.—Staphyloma posticum, accompanied by *pains in*

ball, as if pressed asunder, or sharp and shooting in and around the eye. Vitreous hazy and vessels of the fundus injected.

Spigelia.—When accompanied by *sharp stabbing pains* through the eye and around it, often commencing at one point and then seeming to radiate in every direction.

Thuja.—An important remedy in all *inflammatory conditions of the sclera*, especially in *strumous or syphilitic subjects*. The globe may be quite sensitive to touch and the photophobia is usually marked.

Carbo veg, Croc., Jaborandi, Lyco., Kali iod., Merc., Physos., Ruta and Sulph. are also remedies to be borne in mind. Compare remedies for choroiditis.

Senile Changes of the Choroid.—A rare form of colloid degeneration is sometimes met with in old people. There arises at the periphery from the lamina elastica, small, yellowish-white nodules which press forward into the retina, pushing aside the pigment layer. These nodules are irregularly scattered through the periphery and may be irregularly surrounded by pigment. They gradually extend toward the posterior pole of the eye. They resemble somewhat the spots of disseminate choroiditis, and are practically of little importance, as the vision is but very slightly, if any, disturbed.

Another form described by Berry (*loc. cit.*) as *senile central choroiditis* shows in the early stages a reddish-yellow, irregularly-oval shaped patch which later assumes more of an atrophic appearance, the edges become more irregular and bordered by pigment. The patch generally appears in both eyes and varies in size. The condition causes metamorphopsia and a central scotoma, so that central vision is very greatly impaired. There is no tendency for the condition to extend to other parts of the fundus and hence vision is never entirely destroyed.

Albinism.—General absence of pigment in the tissues is a congenital defect which may affect the entire uveal tract, and, when it does, the iris is of a very pale blue, the pupil is small and there is a constant effort to avoid the light. Nystagmus is usually present, the lens may be ill-developed and there is always amblyopia. A pinkish glare is seen from the pupil, and with the ophthalmoscope the choroidal vessels are brilliantly outlined. Albinos always bring objects very close to the eyes to compensate for their amblyopia and

to abate the nystagmus by strong convergence. Slight relief is obtained by the use of dark glasses to moderate the light.

Tumors of the Choroid.—*Tubercles, or choroiditis tuberculosis* is dependent upon a tubercular diathesis and is especially found in cases of acute miliary tuberculosis, particularly when the meninges are affected. They are very rarely found in local tuberculosis of the lungs or intestines. Both eyes are generally involved and their special location is around the optic nerve. There are comparatively few usually, but may vary in number and size and are most frequently found in children. Pathologically they are the same as miliary tubercles elsewhere, composed of an accumulation of granular cells, going over into a cheesy degeneration; they contain no blood vessels and the pigment is rarely involved. They are difficult to detect, because the pigment is never involved until the very late stages. They appear as small, round, elevated spots, of a pale-yellow color, which are usually isolated, but may be confluent, and lack the brightness of spots of choroiditis. They cause no impairment of the vision, except when accompanied by neuritis or general choroiditis and have been found in the eye before any symptoms of general tuberculosis could be discovered.

Sarcoma.—Nearly all varieties of the sarcomata may be found occurring in the choroid, although the pigmented or melano-sarcoma are by far the most frequent. Sarcomas are especially found between the ciliary and equatorial regions of the choroid. Their growth is tolerably rapid and the iris soon becomes involved and is bulged forward. From their location in the fore part of the fundus it is often difficult to recognize them, but upon dilatation of the pupil they can be seen as a grayish-brown or black mass. Absence of pain or inflammatory symptoms is noticeable in the early stages. The growth gradually increases in size and color, with no change in the fundus beyond the tumor and with no change in the vision, excepting a contraction in the field of vision corresponding to the tumor. Later on it causes a detachment of the retina and the diagnosis of a tumor behind the detachment may present some difficulties. If a tumor is present, the color appears darker than in a simple detachment and the tension is increased, while, in simple detachment, the tension is diminished, the detached part of the retina has a wavy appearance on movement of the eye; it generally occurs at the posterior pole of the eye and usually settles to the bot-

tom. Glaucomatous symptoms in a detachment of the retina generally indicate the presence of a tumor. The origin of the growth in some cases may be traced to an injury of the eye, although more often it is a primary condition with no traceable cause. Knapp¹ divides the symptoms and progress of choroidal sarcoma into four stages: First, the origin and commencing growth without symptoms of irritation of the eye; Second, the appearance of inflammatory symptoms in the eyeball, which are generally glaucomatous in character; Third, the stage of extension to the surrounding coats of the eyeball, and Fourth, the stage of metastasis to remote organs. The several stages seem to have a progressively shorter duration, so that the tumor may be very slow in its early growth, but, after perforation of the eye, it becomes very rapid in its progress. Sarcomas occurring at the posterior pole of the eye, while rare, have been found, and Griffith² reports a case seen by himself and gives the records of six other cases. Sarcoma appears especially in old age, is very rarely seen under forty, and rarely affects but one eye. The prognosis depends somewhat upon the character of the tumor and the stage of its growth. The pigmented variety are more malignant and more liable to return, especially when they have reached the glaucomatous stage prior to removal. About two-thirds of all sarcomas return after removal. Microscopical examination may show the tumor to be any one of the following varieties: Melano-sarcoma, leuco-sarcoma, fibro-sarcoma, myo-sarcoma, chondro-sarcoma, osteo-sarcoma, cysto-sarcoma, glio-sarcoma, or sarcoma-cavernosum. The *treatment* should always be an early enucleation and care should be taken to sever the optic nerve as far back as possible.

Ossification of the Choroid.—True bone may, in the course of time, be formed in the choroid. It is usually found in the inner layers of atrophied balls and more especially in eyes that have been lost by irido-choroiditis. The plate of bone generally assumes a more or less spherical shape, although some spiculæ or growths may be found upon it. The diagnosis is made by feeling a hard body which ends at the ciliary region, as ossification never takes place in the ciliary body. The principal danger seems to be that of exciting sympathetic irritation and the treatment should be enucleation.

¹ A Treatise on Intraocular Tumors.

² Archiv. Ophthal., vol. xvii., 2, 1888.

Hæmorrhages in the Choroid are the result of some diseased condition of the blood vessels. The exciting cause may be from injuries, operations, coughing, etc. The hæmorrhage may be slight or extensive and it may extend forward between the choroid and retina, producing detachment of the retina, or more frequently it will extend outward between the choroid and sclera and may cause a separation of the choroid from the sclera. The diagnosis between hæmorrhage in the choroid and hæmorrhage in the retina is uncertain, when occurring in the outer layers of the retina; but, when in the inner, or nerve fibre, layer of the retina, the hæmorrhage has a striated or flame-shaped appearance, while that in the outer layer of the retina or in the choroid is not striated. Hæmorrhage into the retina usually corresponds to the retinal vessels—that is, it usually occurs along the course of the vessels and is apt to cover the vessels slightly. If there is no retinal vessels near the hæmorrhage, it is more likely to be in the choroid. If the hæmorrhage is in the retina, its color is more of a bright red and its outlines are well defined; while if in the choroid it appears of a darker red and the outlines are ill-defined. Choroidal hæmorrhages interfere somewhat with the vision by causing scotoma. On absorption of a hæmorrhage there is left behind an atrophic spot surrounded by pigment.

TREATMENT.—Hæmorrhage is the most common symptom that demands our attention in the treatment of a rupture of the choroid, though we may have hæmorrhages arising spontaneously or from inflammatory changes, etc.

The remedies chiefly called for will be *Arn.*, *Bell*, *China*, *Crotal.*, *Ham.*, *Lach.*, *Merc. corr.*, or *Phosph.*

For special indications refer to *Retinitis Hæmorrhagica*.

If there is hyperæmia or inflammation of the choroid present, our treatment will be guided by the rules laid down under choroiditis.

Detachment of the Choroid from the sclera may occur from an injury, from an effusion of blood or serum, or from a tumor. Its diagnosis is always difficult and uncertain. The ophthalmoscopic examination gives an appearance similar to that of a tumor—a dark mass, like that seen in sarcoma, but more often at the lower part of the eyeball. Groenouw¹ reports two cases of detachment of the choroid, after cataract extraction, with spontaneous recovery. As

¹ *Archiv. Ophthal.*, vol. xviii., 3, 1889.

these simulate choroidal tumor, he cautions against enucleation until after watching the case for two weeks at least, as the apparent tumor may disappear spontaneously. Eyes have been enucleated for choroidal tumor which have proven to have been a detachment of the choroid. The tension is, however, diminished and it differs from retinal detachment by having none of the wavy appearance on moving the eye, and it has a dark red or black appearance instead of the bluish-green color of a detached retina.

Rupture of the Choroid.—This condition is of comparatively frequent occurrence. It is usually found after a blow on the eye, and we may find associated with it, from the same injury, a rupture of the retina, a separation of the iris, or a dislocation of the lens, but often the rupture of the choroid occurs alone. It is generally accompanied by a hæmorrhage that often conceals the rupture at first. The location of the rupture is almost always at the posterior pole of the eye, and is more frequently seen between the optic nerve and the macula. It is generally vertical and in the shape of a curved line, the concavity being directed toward the optic nerve; it is most frequently a single line, with occasionally one or more bifurcations, although two distinct ruptures may occur.

The ophthalmoscopic appearances vary. In the early stage it may be completely obscured by the hæmorrhage. Later it is seen as a yellowish-red line, and, as the blood becomes absorbed and the swelling and haziness of the retina pass off, it gradually assumes a more and more white appearance, until it finally looks like a clear white line, possibly bordered by a little pigment. The pigment layer of the retina is always ruptured, and usually the layer of rods and cones is also involved. The loss of vision depends upon the amount of destruction in the retina and its nearness to the macula. It causes a scotoma, more or less large, according to the size of the rupture.

PROGNOSIS.—Should be guarded, because, in the atrophic stage, the vision may decrease after it has first improved. When the retina is involved we never find the retinal vessels passing over the ruptured choroid as they may in an uncomplicated case.

CAUSE.—Rupture results from a sudden blow on the anterior portion of the eyeball, and Becker claims that the mechanism of the rupture is a pressing in of the optic nerve toward the middle of the eye, producing a fold or a series of folds in the coats immediately surrounding the nerve. That the retina and choroid are

both stretched, but the retina, being more elastic and less firmly fixed, yields; while the choroid, from the nature of its attachments, gives way.

Coloboma of the Choroid.—This is a congenital anomaly, due to an arrest of development in foetal life and is usually associated with a coloboma of the iris, but may be found alone and may be present in one or both eyes. Other evidences of arrested development, such as harelip and cleft palate, are sometimes met with, together with the ocular defect. The usual location of a coloboma of the choroid is downward or downward and inward, and may extend from the iris through the ciliary body and choroid to the optic nerve, which may also be involved. Coloboma may vary greatly in shape in different cases. It is, however, generally more pointed or narrow at the optic nerve, becoming wider toward the equator. The appearance with the ophthalmoscope is that of a white, glistening patch, with the retinal vessels seen coursing over it and occasionally masses of pigment may be found here and there upon it; the edges of the coloboma appear distinct, clear cut and often pigmented. In all cases the retina is either imperfectly developed or absent, and, in consequence, a scotoma corresponding to the coloboma is usually present. The sclera may also be to some extent affected; that is, it is thinned and may be staphylomatous. In place of the choroid over the region of the coloboma there is to be found a connective tissue membrane which corresponds to both the choroid and retina, as the vessels of both are found in it. Cases of so-called coloboma, in which the defect is confined to the region of the macula alone, have been rarely reported, but these may possibly have been the result of degenerative changes following some inflammatory condition in intra-uterine life. Johnson¹ gives a thorough description of extra papillary colobomata, illustrated by drawings and chromolithographs. He believes that coloboma may occur in any part of the fundus and are more frequent than generally diagnosed. They differ from atrophic changes due to disease in that their margins are always sharply defined, they are always surrounded by healthy tissue, the pigment is in front and never behind the retinal vessels, the appearance of the coloboma always remains the same, and that the floor of the coloboma is of a dazzling whiteness, or sometimes covered by a layer of connective tissue looking like mother-of-pearl.

¹ Archiv. Ophthal., vol. xix., 1, 1890.

CHAPTER XII.

Diseases of the Retina.

Anatomy.—The retina is the delicate membrane lying between the choroid and the vitreous and extending from the optic nerve to the ciliary processes, where it terminates in a finely indented border called the *ora serrata*. Microscopically the retina is divided into ten layers which are, from within outward: 1. The internal limiting membrane; 2. The nerve fibre layer; 3. The layer of ganglion cells; 4. The internal molecular layer; 5. The internal granular layer; 6. The external molecular layer; 7. The external granular layer; 8. The external limiting membrane; 9. The layer of rods and cones; 10. The pigment layer.

The *internal limiting membrane* is a very thin, imperfect membrane, serving to separate the nerve fibre layer from the vitreous. The fibres of Müller terminate in this layer.

The *nerve-fibre layer* consists of the axis cylinders of the optic nerve fibres, which run in a radiating direction to the *ora serrata*, where they terminate. At the macula lutea these fibres are bent into arches and are so arranged that a larger number of them reach the yellow spot than could if they approached it in a radiating direction.

The *layer of ganglion cells* forms, excepting in the region of the macula, several layers of multipolar cells, having both a nucleus and a nucleolus. A nerve fibre enters each of these cells and one or more prolongations extend outward into the inner molecular layer. These ganglionic cells are arranged more closely to each other near the optic nerve than at the *ora serrata*.

The *internal molecular layer* consists of the fine fibres from the layer of ganglion cells irregularly arranged, with an amorphous molecular substance.

The *internal granular layer* is composed of two kinds of cells with nuclei. The larger of these are nerve cells, similar to those in the layer of ganglion cells, and having two offsets, one passing into the

inner granular layer to anastomose with the offsets from the ganglionic cells and the other passing outward into the external molecular layer, where, it is claimed by some, they anastomose with fibres from the layer of rods and cones. The smaller cells of this layer are connected with the fibres of Müller.

The *external molecular layer* is very thin and is made up of the fibres just mentioned, together with a molecular substance similar to that of the internal molecular layer.

The *external granular layer*, like the internal, is composed of both nerve and connective-tissue elements. The former consists of bi-polar cells, from which offsets pass outward to the layer of rods and cones and inward to the internal granular layer.

The *external limiting membrane* is the expansion formed by the terminal extremities of the fibres of Müller.

The *layer of rods and cones* is the most important part of the retina. The rods, commencing as fine fibres in the outer molecular layer, pass through the outer granular layer and, just beneath the

external limiting membrane, begin to increase in size, forming the rod granule, and some distance after passing through this membrane they taper down into cylindrical shaped rods, which extend outward to the pigment layer. The cones also commence as a cone-shaped swelling in the outer

FIG. 40.

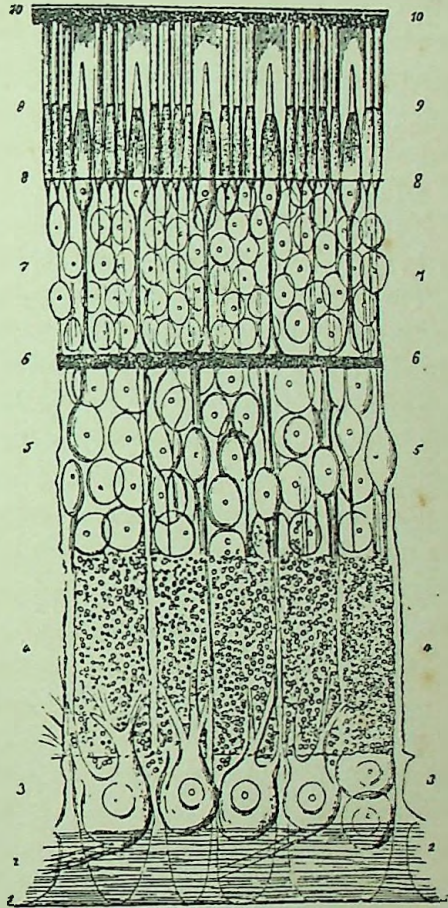


Diagram Showing Minute Anatomical Structure of Retina.

direct communication with the fibres from the internal granular layer. The cone-fibre becomes thinner until, just underneath the external limiting membrane, it again swells rapidly and there forms the cone itself, which contains a large oval nucleus and nucleolus. The cones are shorter and thicker than the rods and are of a bottle-shaped appearance. The rods and cones are arranged perpendicularly to the plane of the retina and may be divided into an inner and outer part. The inner segment is thicker than the outer and appears granulated; the outer part is broken up into fine, highly refracting lamellæ, appearing like superposed circular discs or a pile of coins.

The *pigment layer* consists of a single layer of hexagonal nucleated cells, the inner surface of which is loaded with pigment granules.

The *fibres of Müller* form the connective-tissue framework of the retina which traverses its various layers from the internal to the external limiting membranes and spreads out in these membranes.

The *macula lutea* or *yellow spot* is about 1.25 mm. in diameter and is the most sensitive portion of the whole retina. It lies to the outer side of the optic disc 2.25 mm. from it and 1 mm. to the outer side of the antero-posterior axis of the eyeball. The shape of the macula has been almost universally described in text-books as oval; the error of this has been pointed out by Johnson,¹ who claims that: "The macula is invariably circular, and probably corresponds to the extreme limit of the macula region," and that it is best seen with a very weak illumination and by the direct method; that by this method of examination the macula ring can be seen in its entire circumference in nearly every person under thirty-five years of age and frequently over that age. He concludes that the mistake of all authors who have seen the macula as oval is that they have examined by the indirect method. The color of the macula has also been variously described, usually as of a somewhat yellowish appearance, from which it was called the yellow spot, but Johnson (*loc. cit.*), by means of sixteen colored drawings, shows that "in normal eyes of Europeans the inner portion of the macula appears of a more intense or brighter red than the fundus generally, the color deepening as it approaches the fovea centralis, where it is almost always masked by the bright foveal reflex, varying in shape and intensity."

¹ Archiv. Ophthal., vol. xxi., 1, 1892.

Anatomically the macula differs from other parts of the retina in that there are no rods, and the cones are longer and narrower than in other parts of the fundus. At the centre all the other layers of the retina are thinner, forming a depression called the fovea centralis, but toward the margin the retinal layers, especially the layer of ganglionic cells, are for the most part thicker than elsewhere.

The *vascular supply of the retina* is derived from the arteria centralis retinæ, which divides on the optic disc into an upper and lower branch. These branches then turn outward, forming a large ellipse around the macular region, none of its capillaries extending into the fovea; other branches are given off to supply the inner and other parts of the retina. Each artery is generally accompanied by a vein.

The appearance of the healthy retina is that of perfect transparency. The retinal vessels are easily distinguished from those of the choroid by being more clear and well-defined and by their taking a more radiating course and branching dichotomously. Pulsation of the retinal veins and still more rarely of the arteries may occasionally be seen in normal eyes; both may be produced by pressure of the finger upon the globe during an ophthalmoscopic examination. Usually, however, pulsation of the retinal vessels is indicative of some pathological change.

Hyperæmia Retinæ.—It is always difficult to state in any given case whether the congestion exceeds that which is physiological or not, and in making the diagnosis the relative sizes of the arteries and veins should be considered. Normally the retinal arteries are about three-quarters the size of the corresponding vein. Hyperæmia may be either active or passive. Active hyperæmia usually results from some straining of the eyes, such as a prolonged use of the eyes at fine work or by a poor light. It is very often associated with or caused by some refractive error and is, of course, present in the first stage of retinitis, or may be present with inflammation of other parts of the eye. The relative size of the vessels in active hyperæmia is usually well maintained and the diagnosis rests upon the congestion of the optic disc, which becomes more pinkish, with less contrast between it and the surrounding fundus. Passive hyperæmia results from some circulatory interference which may take place in the eye, as in glaucoma, or external to the eye, as in

pressure upon the optic nerve. In this form the relative normal proportions between the arteries and veins becomes lost and we find the veins tortuous and increased in size, while the arteries may either remain normal or become diminished. In hyperæmia the only symptoms complained of by the patient will be some dimness of vision, or of flashes of light before the eyes.

TREATMENT.—Hyperæmia frequently depends upon some refractive error, which should be corrected by suitable glasses. Rest of the eyes is of great importance, and hence the patient should be instructed to abstain from all use of the eyes. The remedies most frequently found of service are Dubois., Bell., Phos., Conium, Puls. or Bry. The special indications will be found under retinitis.

Retinitis Simplex.—(*Retinitis Serosa, Retinitis Diffusa, Œdema of the Retina.*)

PATHOLOGY.—There is a hyperæmia of the retinal vessels followed by an infiltration of serous fluid into all the layers of the retina. The membrane, especially in the neighborhood of the disc, becomes somewhat swollen and thickened. In addition to the serous infiltration, some lymph cells and slight parenchymatous changes may be found in the later stages.

SYMPTOMS.—Patients will complain of a diminution of vision, as though looking through a mist, and the field of vision may be somewhat impaired. The ophthalmoscope will show a hyperæmia of the retina and optic papilla, together with a diffuse grayish appearance of the retina, especially in the vicinity of the optic disc, the outlines of which are very much blurred and indistinct. In other cases it will appear simply as a slight cloudiness, especially in the vicinity of the disc, although it may occur at the macula or at the periphery. The vessels may be slightly covered, as with a veil, or appear perfectly distinct. In retinitis simplex the cloudiness is circumscribed, affecting only a certain portion of the retina, and this fact forms the essential diagnostic point between this disease and a slight, diffuse haziness of the vitreous or cornea which would cause a general cloudiness of the whole fundus.

CAUSES.—This form of inflammation may precede or extend into other types of retinitis. It has also been attributed to exposure to cold, heat or strong light, and as a result of overuse of the eyes by poor light especially when there is some refractive error, and in many cases it is impossible to assign a distinct cause.

PROGNOSIS.—If the disease leads to no more serious form of inflammation, recovery, with perfect restoration of vision, is the rule. Neuro-retinitis is a more common diagnosis, as the optic nerve and retina are usually inflamed at the same time.

TREATMENT.—Hyperæmia of the retina frequently depends upon some anomaly in the accommodation or refraction of the eye, which should be corrected by suitable glasses, and after this is done the retina often returns to its normal condition.

Rest is a most important aid in all cases whether inflammatory or only hyperæmic, and the more complete it is, especially in neuritis or retinitis, the better for the patients. They should be instructed to abstain from all use of the eyes, particularly by artificial light. Some authors, Stellwag and others, recommend the confinement of the patient in a darkened room and the employment of a bandage, thus keeping all light away from the eye for some time, when they are allowed to gradually become accustomed to bright light. Such severe measures are, however, not required except in extreme cases. It is better to allow moderate exercise in the open air, taking care that the eyes are properly protected from the irritating influence of bright light by the use of either blue or smoked glasses.

Proper hygienic rules, according to the nature of the case, demand our most careful attention.

Belladonna.—One of the most frequently indicated remedies for both hyperæmia and inflammation of the optic nerve and retina. *The retinal vessels will be found enlarged and tortuous*, particularly the veins, while a *blue or bluish-gray film* may seem to overspread the fundus (œdema). *Extravasations of blood* may be numerous or few in number. *The optic disc is swollen* and its outlines ill-defined. The vision is, of course, deteriorated. The pains are usually of an *aching*, dull character, though may be *throbbing* and severe, accompanied by *throbbing, congestive headaches* with visibly beating carotids and flushed face. Phosphenes of every shape and hue, especially red, may be observed by the patient. *Decided sensitiveness to light.* The eyes feel *worse in the afternoon* and evening, when all the symptoms are aggravated. Externally the eye may present no abnormal appearance, though generally seems weak, is injected and irritable.

Bryonia.—Serous retinitis or hyperæmia, with a bluish haze

before the vision and severe *sharp pain through the eye* and over it. Eyes feel full and *sore on motion* or to touch. Great heat in the head, aggravated by stooping.

Cactus.—Retinal congestions, especially if heart trouble is present.

Conium.—Fundus congested, with *much photophobia*; ciliary muscle weak.

Duboisia.—Of great value in the treatment of both hyperæmia and inflammation of the optic nerve and retina. *Retinal vessels large and tortuous*, especially the veins. *Optic papilla swollen* and outlines ill-defined (engorged papilla). Hæmorrhages in the retina, aching in the eyes and *pain through the upper part of the eyeball* just beneath the brow, which may be very severe. Chronic hyperæmia of the conjunctiva.

Mercurius.—Retinitis with marked nocturnal aggravation and *sensitiveness of the eyes to the glare of a fire*. Congested conditions of the fundus found in those who work at a forge or over fires. Degeneration of the blood vessels, with hæmorrhages into the retina. Concomitant symptoms will assist us in the selection.

Nux vom.—Retinitis occurring with gastric disturbances, especially in drunkards. The eye indications vary, but are usually *aggravated* in the morning.

Phosphorus.—Hyperæmia or inflammation of the optic nerve and retina, especially with *extravasations of blood*. Degeneration of the coats of the blood vessels. The eye may be sensitive to light and vision improved in twilight. Vision impaired, *muscæ volitantes*, photopsies and chromopsies are present, halo around the light. The eyeballs may be sore on motion and pain may extend from eyes to top of head.

Pulsatilla.—*Hyperæmia and inflammation of the optic nerve and retina accompanied by more or less severe pains in the head always relieved in the open air*. Sensation as if a veil were before the eyes, or the vision may be nearly lost. All the ophthalmoscopic appearances of engorged papilla or simple hyperæmia may be present, if dependent upon menstrual difficulties or associated with acne of the face or disorders of the stomach.

Veratrum viride.—*Engorged disc*, with severe pain at menses and general vaso-motor disturbances.

In addition to the above, the following remedies may be of benefit in rare cases or as intercurrents: Acon., Ars., Aurum, Chin. sulph., Gels., Kali iod., Kali mur., Lach., Spig. and Sulph.

Retinitis Nyctalopica.—(*Solar Retinitis, Dazzling of the Retina*).—Under this heading we shall class all those cases accompanied by a dazzling sensation, due to exposure to the bright glare of the sun, upon snow or water, to the electric light, etc. These conditions may produce a diffuse retinitis or neuro-retinitis, or, again, such exposure may be followed by amblyopia, with no ophthalmoscopic signs. Widmark¹ considers the trouble as produced by direct irritation of the part affected and that this irritation is caused almost exclusively by the ultra-violet rays which exert a similar influence upon the skin. The patients complain of a dazzling, a central scotoma and slight impairment of the vision. Objects appear in a mist and the air seems to flicker. Cases of retinitis have also been reported as the result of a single intense flash of light. The treatment of these cases consists in the prevention of all use of the eyes and in protection from the light.

Retinitis Albuminurica.—(*Renal Retinitis, Papillo-retinitis, Retinitis of Bright's Disease*).

PATHOLOGY.—The pathological changes in albuminuric retinitis are numerous and variable in the different stages of the disease. Weeks² describes the microscopical changes in the eyes of six different individuals who suffered from disease of the kidneys. In this article he details the changes found in all the structures of the eye, but we shall confine ourselves to the pathological changes occurring in the retina.

There is first an exudation into the optic papilla and the surrounding portions of the retina; this exudation is usually granular in character, though there may be more or less round cells and lymphoid corpuscles; there is a hyperplasia of the connective tissue, the fibres of Müller becoming thickened and elongated. The nerve-fibres become remarkably swollen (a so-called sclerosis); these swellings are club-shaped and highly refracting and the whole layer is much thickened. This sclerotic swelling of the nerve-fibres was formerly considered a swelling of the ganglion cells, which may undergo a

¹ Revue générale d'ophtalmologie, Paris, Aug., 1890.

² Archiv. Ophthalm., vol. xvii., 3, 1888.

similar degeneration, although as a rule they remain unaltered. The granular layers become thickened and thrown into folds, especially in the neighborhood of the optic disc; there is also an infiltration of fat cells into the granular layer, and, in severe cases, into other layers of the retina as well, which results in a circumscribed fatty degeneration. The retinal vessels undergo extensive changes, becoming thickened, distended, sclerosed and ruptured; hæmorrhages are found to be the most numerous in the nerve-fibre layer, although may take place elsewhere. There may be a moderate proliferation of pigment. According to Weeks, we may divide this disease into two classes of cases—those occurring in all forms of acute disease of the kidneys, such as pregnancy, scarlet fever, etc., in which the kidney disease precedes the changes in the retina, and, in the other class, he places those dependent upon a general diseased condition of the vessels in which the eye symptoms precede those of the kidney. In the first form, which is by far the most frequent, œdema and white patches appear first, to be followed by hæmorrhages; while in the second class a slight hæmorrhage near the macula and a few bright dots are the first evidence, followed later by the œdema and white patches.

SYMPTOMS.—The only subjective symptom noticed by the patient is that of impairment of vision, which may vary from a slight cloudiness to complete blindness. The field of vision and also the color vision usually remains good. Frequently the disease is diagnosed by the ophthalmoscope before the patient is aware that there is any kidney lesion whatever. With the ophthalmoscope there is seen swelling and hyperæmia of the disc; the retinal arteries are somewhat diminished and the veins increased in size; there is a diffuse haziness of the retina, together with hæmorrhage and the formation of white patches.

In a well-marked case there is in the macula or its immediate vicinity numerous variously shaped white spots, which are, in the early stages, small and separate, but later on, or in a truly typical case, form a star-shaped figure, the lines radiating out from the macula lutea. This central stellate spot is usually much larger in size than the optic disc and is surrounded by numerous smaller white spots. Other of these spots and somewhat larger in size are usually seen around the papilla, and in this locality they will often

coalesce into a broad zone around the optic nerve entrance, giving it the appearance usually designated as surrounded by a snow bank. These peculiar white spots of the retina are due to a fatty degeneration of the nerve fibre and granular layers, and, when seen, may be considered almost pathognomonic of albuminuria, particularly so when assuming the star-shaped arrangement at the macula.

The white patches occur mostly in the deeper layers of the retina, as proven by the fact that the retinal vessels may usually be seen passing over them, but may be partially or completely covered by the patch at some places.

Hæmorrhages are almost universally found in albuminuric retinitis, but, unlike the white patches just described, are not especially pathognomonic of this disease. They may occur in great numbers and of various sizes and shapes, from large, dark-red extravasations to small, round or linear-shaped spots scattered throughout the fundus. The extent of the hæmorrhages is considered to be somewhat indicative of the severity of the disease.

COURSE.—Albuminuric retinitis may either gradually or suddenly pass into a neuro-retinitis resembling very closely the choked disc from cerebral causes. The ophthalmoscopic picture of retinitis albuminurica (see Fig. 6, Plate I.) may remain unaltered for a long time, the hæmorrhages and white patches slowly disappearing, while new ones at the same time may make their appearance. The white plaques at the macula are always the last to disappear, and, according to some authorities, may never disappear. As the secondary changes go on the optic disc becomes discolored and atrophied, the retinal vessels become contracted and pigment changes in the retina results.

CAUSES.—Renal retinitis may occur with any form of kidney disease, but is especially found with the contracted kidney. It is also quite frequently seen associated with the albuminuria of pregnancy, and more rarely with post scarlatinal nephritis. A few cases have also been reported associated with functional albuminuria. Both eyes are as a rule involved, although it may occur in but one.

DIAGNOSIS.—The ophthalmoscopic appearances are always quite characteristic of this disease, and the presence of albumin in the urine would at once confirm the diagnosis. Diabetic and leucocythæmic retinitis both present appearances of the fundus very similar

to those found in this disease, and an examination of the urine will be necessary to clear up the diagnosis. A neuro-retinitis resulting from intracranial disease, especially if it be complicated by albuminuria, would present great difficulty in the differential diagnosis and a very careful study of the general symptoms would be required. The white spots in choroidal affections would differ from this by the presence of more or less pigment and by the different location and shape of the white patches. Opaque optic nerve fibres resemble somewhat closely the snow-bank appearance around the papilla, but in opaque nerve fibres the white patches extend out from the disc in a fan-shaped manner and it is unaccompanied by any change in the macula or œdema of the retina.

PROGNOSIS.—In albuminuric retinitis the prognosis must necessarily cover two points: first, as to vision, which should always be unfavorable, excepting in the slighter cases and particularly those occurring in pregnancy. The appearance of albuminuric retinitis in all cases, excepting when associated with pregnancy, is always a most unfavorable symptom as regards the life of the patient. It is extremely rare for recovery to take place in cases of kidney disease after the retina has become involved, and in the majority of cases a fatal termination will ensue inside of two years.

In the retinitis albuminurica of pregnancy the prognosis depends chiefly upon the period of gestation, and secondly upon the extent of the disease. Some cases of very extensive hæmorrhages, with marked patches of infiltration of the retina and almost complete loss of vision, when only occurring in the last weeks of pregnancy, may recover, after confinement at full term, with almost complete restoration of vision. On the other hand, slight changes in the earlier months of pregnancy, which have a tendency to increase in spite of treatment, may prove very serious both to the vision and the life of the patient as well if allowed to go on to full term. The longer the disease exists, the greater are the degenerative changes which may take place, and it is on this account that the appearance of the disease in the last weeks of pregnancy proves far less serious than when occurring early. Induction of premature delivery in these cases becomes then a question of grave importance. The presence of albuminuric retinitis, when of a high degree and accompanied by loss of sight, denoting advanced degeneration of the kidneys,

together with the fact that the uræmic condition of the blood, threatens the life of both mother and fœtus, to us argues in favor of interference. Howe draws the conclusion that "The induction of labor is warrantable when the retinitis appears in the early stage of pregnancy and persists in spite of proper treatment, but is not warrantable in the last few weeks, in spite of the greater ease with which it is accomplished, unless the inflammation is unusually severe."

COMPLICATIONS.—Detachment of the retina and hæmorrhage into the vitreous are the most frequently seen complications, although other conditions, such as glaucoma, extravasations into the choroid and embolism have been recorded as occurring with this disease.

TREATMENT.—The principal treatment should be directed to the kidneys, the seat of the primary disease, and such hygienic and dietetic measures adopted as are recommended for Bright's disease. Benefit has sometimes been derived from keeping the patient quiet in bed and upon a low or skim-milk diet.

Apis.—If associated with œdematous swelling of the lids and general dropsical condition. Patient very drowsy, with little thirst and scanty urine.

Arsenicum.—If the patient is restless, especially at night after midnight, with great thirst for small quantities. Urine scanty and albuminous.

Gelsemium.—Retinitis albuminurica occurring during pregnancy. White patches and extravasations of blood in the retina. Dimness of vision appears suddenly. Serous infiltration into the vitreous, making it hazy, may be observed. The patient is thirstless, and albumen is found in the urine.

Kalmia.—Nephritic retinitis accompanied by much pain in the back, as if it would break.

Merc. corr.—Has been more extensively used in *albuminuric retinitis* than any other remedy. The fatty degeneration, extravasation of blood from the weakened vessels and all the pathological changes in the eye as well as in the kidney point to mercury as a remedy, even though no characteristic subjective symptoms are present. The results are especially favorable when pregnancy appears to be the exciting cause of the difficulty.

As hæmorrhages are usually found in the retina in this form of inflammation, compare the remedies recommended for *retinitis hæmorrhagica*.

Hepar, Kali acet., Plumb. and Phosph. have either been used or are highly recommended for this condition of the eye. In fact, any remedy applicable to the disease of the kidney will often prove of service in the eye complication.

Retinitis Diabetica (*Retinitis Glycosurica*).—The appearance and general features of this form of retinitis are practically the same as already described under albuminuric retinitis, with the exception that in diabetic retinitis there is, as a rule, less exudation or white patches and usually more hæmorrhage. The white spots are apt to be smaller in size and not grouped at the macula or around the disc in the manner so characteristic of albuminuric retinitis, although cases have been reported in which the appearance was absolutely identical. Retinitis occurring with diabetes is quite rare and usually makes its appearance only after the diabetes has existed for a long while. It is more frequently found existing in both eyes, although it may occur in one eye alone, and may be accompanied by the same complications as found in the retinitis of Bright's disease.

As this form of retinitis is especially characterized by hæmorrhages into the retina, compare the remedies recommended for *retinitis hæmorrhagica* and *albuminurica*. In addition to which, *Secale* is suggested, though the chief attention must be directed to the diabetes.

Retinitis Leucocythæmica (*Splenic Retinitis*).—This is an extremely rare form of retinal inflammation, which, in its earlier stages, resembles a simple retinitis, but later it develops a characteristic appearance, the essential features of which are the peculiar color of the fundus and of the blood in the retinal vessels. The fundus becomes of a peculiar orange hue, due to an alteration in the elements of the blood of the choroidal vessels, and presumably the same changes in the blood exists in all the vessels of the body. Loring¹ says this orange tint is by no means constant and that he has more frequently seen the color as a pale grayish-pink, and in some cases there is no deviation from the normal color of the fundus. The retinal veins are of a bluish-pink, while the arteries have the same orange color; the veins are enormously distended; the arteries are less distended, so that the normal proportionate relation between the vessels seems exaggerated. The optic disc may be somewhat paler

¹ Text-Book of Ophthalmoscopy, Part II., p. 154.

than normal, and its outlines slightly ill-defined. Hæmorrhages are especially prone to occur in this disease, and are generally found in the anterior half of the retina. They are usually more or less circular in shape and of varying size. When large, they often have a white centre, due to a collection of lymph corpuscles with a hypertrophy and fatty degeneration of the nerve-fibres. These hæmorrhages may disappear rapidly and fresh ones appear in different parts of the fundus. The treatment should of course be directed to the general disease, as the retinal complication may be looked upon as merely a symptom of the disease.

Retinitis Hæmorrhagica (*Hæmorrhages into the Retina, Retinitis Apoplectica*).—Under this heading we class all hæmorrhages into the retina, whether accompanied by inflammation or not, excepting those occurring in the characteristic or distinct forms of retinitis elsewhere described. Hæmorrhage into the retina is common to nearly all forms of retinal inflammation and perhaps should be considered a symptom rather than a disease, but they are certainly met with in cases independent of local inflammatory changes. When unaccompanied by inflammation, hæmorrhages may occur in any layer of the retina, and may extend into the vitreous or backward, causing detachment of the retina. They are especially apt to occur along the course of some of the larger vessels, and the macular region seems to be a favorite site. The immediate cause of the hæmorrhage seems to be usually the result of a disease of the walls of the vessels, allowing of diapedesis, rather than from rupture, as the ophthalmoscopic examination would indicate, although rupture no doubt does occur in many cases, especially when following traumatism or after operations.

The location of the hæmorrhage, as to the layers of the retina involved, can usually be determined by the appearance of the extravasation. (See Fig. 7, Plate II.) If occurring in the nerve-fibre layer, as is more often the case, because it is in this layer that the larger retinal vessels course, the hæmorrhage assumes a flame-like appearance, elongated and sharply defined borders, with radiating extremities. This peculiar shape of the extravasation is due to the direction of the nerve-fibres between which the blood settles. If occurring deeper in the retina, the hæmorrhage is more irregular or circular in shape, although this appearance may be seen in an exten-

sive hæmorrhage in the nerve-fibre layer by causing a rupture or pushing aside of the nerve-fibres.

SYMPTOMS.—The subjective symptoms of retinal hæmorrhages, when unaccompanied by inflammation, are, when in the posterior pole, a positive scotoma, together with sometimes a colored vision; that is, in some rare cases the patient will complain of a reddish mist before the eyes after a fresh hæmorrhage. If the hæmorrhage has occurred at the periphery, there will be found a defect in the field of vision corresponding to the extravasation. Metamorphopsia or distortion of objects seen by the portion of the retina affected may also be present. If signs of inflammation are added to hæmorrhages in the retina, we will then have a swollen appearance of the disc, its outlines are clouded and indistinct, the retina is hazy, its veins engorged and tortuous and the arteries are small. When the signs of retinitis are present, they may be secondary and due to the irritation caused by the blood-clots, which may lead to fatty degeneration, to hypertrophy of the nerve-fibres, and, rarely, to attacks of acute glaucoma.

In the so-called *retinitis apoplectica*, the fundus is spattered with small hæmorrhages, with here and there larger, irregular patches of blood. These hæmorrhages are usually along the side of the vessels, and many of the smaller ones appear as short lines running parallel to the vessels. This form of retinitis always comes on suddenly and chiefly among elderly people. The vessels are affected with atheroma or syphilitic degeneration, and cardiac or chronic renal disease are usually present. The occurrence of apoplexy of the retina is always indicative of serious cerebral hæmorrhage.

CAUSES.—Hæmorrhage into the retina may occur from numerous causes; as from disturbances in the circulation we find it frequently in cardiac lesions, such as hypertrophy or valvular stenosis, in embolism or thrombosis of the central vessels of the retina and in menstrual disturbances. It may also be caused by general conditions or diseases resulting in changes in the composition of the blood or in the walls of the vessels, as found in septicæmia or pyæmia; in diseases of the kidney, spleen or liver; in anæmia, hæmophilia, purpura and scurvy; in diabetes, gout, etc. It also often results from traumatism and from sudden reduction of the intraocular tension, as in iridectomy for glaucoma. Many other causes have been assigned

in reports of individual cases of retinal hæmorrhage. Lang¹ records a hæmorrhage at the macula of three times the diameter of the disc in size occurring after an action of the bowels in a healthy boy, twenty years of age, subject to constipation. Four months later the hæmorrhage had disappeared and vision was perfect.

PROGNOSIS.—This depends upon the cause, together with the size and location of the hæmorrhage. Many cases recover with partial or complete restoration of vision when occurring in young, robust individuals and when not the result of some organic lesion elsewhere. As a rule, however, the prognosis is unfavorable, not only so far as the ocular condition is concerned, but to life as well, for, as we have already seen, retinal hæmorrhage is frequently the forerunner of cerebral extravasation, or occurs merely as a symptom of some serious disease of other organs.

COMPLICATIONS.—Secondary changes in the retina and optic nerve frequently follow. Glaucoma, either acute or hæmorrhagic, detachment of the retina and vitreous opacities, not infrequently result from hæmorrhage into the retina.

TREATMENT.—Rest for the eyes must be enforced. All undue mental or physical exertion and the use of stimulants must be strictly prohibited. Change of scene and quiet and cheerful surroundings, with suspension of business cares or literary labor, are often important. If dependent upon general disturbances, these will require our attention.

Arnica.—Retinal hæmorrhages of traumatic origin.

Belladonna.—Apoplexy of the retina, especially when arising from or accompanied by congestive headaches. Suppressed menstruation may be the cause of the difficulty. The retina and optic nerve will be found inflamed and congested.

Crotalus.—In the snake poisons we possess our chief agents for hastening the absorption of extravasations of blood into the retina. Crotalus has been used with great advantage, especially if the hæmorrhage is unaccompanied by inflammation.

Lachesis.—From its use, hæmorrhages into the retina have been seen to speedily disappear and the accompanying inflammation rapidly diminished. It is very commonly called for when no characteristic symptoms are present with the exception of the pathological

¹ Trans. Ophth. Soc. Unit. Kingd., vol. viii., p. 155.

changes. The retina, and perhaps optic nerve, are inflamed and congested, while throughout the swollen retina may be observed extravasations of blood of various ages and sizes. General indications determine its selection.

Merc. corr.—Of great benefit in hæmorrhages into the retina dependent upon pronounced degenerative changes in the coats of the blood vessels, with or without inflammation. It not only hastens their absorption, but serves to restore tone to the vessels themselves.

Phosphorus.—In a hæmorrhagic diathesis, when the concomitant indications point to its selection.

Duboisia and *Pulsatilla* may also render valuable service.

Retinitis Syphilitica.—Retinitis due to syphilitic infection may be either hereditary or acquired. In the acquired form it generally occurs with the secondary lesions and rarely with the tertiary.

SYMPTOMS.—One eye may, at first, be alone affected, though usually the second will become involved later. It is often associated with choroiditis, as already described under choroiditis syphilitica, and may be found associated with an inflammation of the optic nerve, forming a neuro-retinitis. It may be either diffused or circumscribed, usually the former, when it appears as a grayish opacity, especially around the optic disc and extending in lines along the vessels. There may be slight congestion of the disc, and, quite rarely, slight hæmorrhages. The vitreous is especially apt to be involved and we find a diffuse, dust-like opacity, with now and then some thin floating shreds.

Syphilitic retinitis often passes into a chorio-retinitis, when we may have the following appearances, as described by Hirschberg,¹ based upon an examination of about three hundred cases: Opacities in the vitreous, usually like a cloud of fine dust, some haziness and congestion of the retina with numerous small white spots throughout the fundus which are free from pigment, sharply outlined, and with no tendency to coalesce. Patients complain of a persistent dazzling and night-blindness, with scotomas and possibly blindness following. Nearly all parts of the eye, cornea, iris, lens and vitreous, may become involved and undergo changes.

COURSE AND PROGNOSIS.—Syphilitic retinitis will often come on

¹ Berliner klin. Wochenschr., No. 46, 1888, and Centralbl. f. Augenhk., vol. xii., p. 369.

quite rapidly, and run an exceedingly chronic course. The prognosis should always be guarded, for, even under the most active treatment and the most favorable general conditions, the improvement may be but slight and relapses are apt to occur. In spite of all treatment it may result in atrophic changes in the retina, choroid or optic nerve.

TREATMENT.—The general indications mentioned under other varieties of retinitis are, of course, applicable in this form of retinal inflammation.

Asafœtida.—When accompanied by *severe boring, burning pains above the brows*, especially at night; also, if there is pain in the balls from within outward, ameliorated by pressure (reverse of Aurum).

Aurum.—Especially after *over-dosing with iodide of potassium or mercury*, and if accompanied by detachment of the retina. Eye sensitive to touch, with pain in and around, seeming to be deep in the bones. A general syphilitic dyscrasia is perceptible in the constitutional symptoms which govern our selection of Aurum.

Kali iod.—For syphilitic retinitis this should be one of the first remedies thought of, especially if there is choroidal complication, though the chief indications for its use will be furnished by the general condition of the patient.

Mercurius.—Especially the remedy for this form of inflammation of the retina. The solubis or corrosivus have been more commonly employed, though the other preparations are also useful when special indications point to their use. The retina will be found hazy, congested and often complicated with an inflammatory condition of the choroid or neighboring tissues. The eye is particularly sensitive to artificial light. *Nocturnal aggravation of all the symptoms* is always present. More or less pain is experienced both in and around the eye, especially during the evening and after going to bed. The syphilitic taint will be perceptible in various ways that will indicate Merc.

Other anti-syphilitic remedies may be useful, given according to general indications, or we may find a remedy recommended for the other forms of retinitis, serviceable in this variety when particular indications are present.

Retinitis Punctata Albescens (*Central Punctate Retinitis*).—This is a circumscribed form of retinitis to which Mooren gave the name of *punctata albescens*.

Its essential features consist of numerous small white dots, closely packed together, giving a stippled appearance to that part of the fundus involved. In one case under my observation, a few years ago, the entire fundus was filled with these small white dots, and yet the patient had nearly perfect central vision. These white spots, though generally very small and round, are sometimes large and more of an oval shape.

The usual location of this disease is in the posterior pole of the eye in the vicinity of the macula lutea.

In this form of retinitis there is usually but slight if any inflammatory symptoms—merely an increased tortuosity of the retinal veins and possibly a few small hæmorrhages. No especial cause has been assigned for this form of retinitis, which usually occurs in those of middle age. Burnett¹ reports one case under his own observation and gives an abstract of five other recorded cases, from which he concludes that the prognosis is, as a rule, good—some cases going on to complete recovery, while none seem to lead to destruction of vision.

Retinitis Proliferans.—A proliferation of the connective tissue of the retina may occur at any part of the fundus and appears as a shred-like or membranous formation. These masses are of a bluish-white appearance and often extend into the vitreous, hiding the optic disc and covering the fundus to quite an extent. They sometimes seem to follow the course of some of the larger vessels, which are in some parts covered by the formation and again are seen passing over it. The formation of these patches may have resulted from a previous retinitis or neuritis, although Loring (*loc. cit.*), has seen cases which he believed were either congenital or acquired in very early life. Leber² attributes the cause of these formations to repeated hæmorrhages, which gradually become organized.

Retinitis Pigmentosa (*Sclerosis of the Retina, Pigment Degeneration of the Retina*).—The name retinitis pigmentosa is according to Frost³ a misnomer, because the disease is much more of a degenerative change than it is an inflammatory condition.

PATHOLOGY.—This consists of a hypertrophy of the connective

¹ Archiv. Ophthal., vol. xii., 1, p. 22.

² Graefe und Saemisch, vol. v., p. 666.

³ Brit. Med. Journ., Dec. 14, 1889.

tissue throughout the retina, with atrophy of the nervous elements, and the migration of pigment. There is also a new formation of pigment cells which are very rich in pigment, and at some points an atrophy of the pigment occurs. The changes commence first in the outer layers of the retina, and later the granular layers are affected, then the layer of rods and cones is destroyed and the entire retina becomes changed and sometimes adherent to the choroid in spots. At these spots of adhesion between the retina and choroid there is a great proliferation of pigment which is apt to extend in a parallel course along the retinal vessels. There is a considerable thickening of the walls of the vessels, with a corresponding diminution in their calibre, and a colloid thickening of the vitreous membrane of the choroid, which extends into the retina and becomes covered with pigment. The disease begins at the periphery of the fundus and gradually extends toward the posterior pole.

SYMPTOMS.—Central vision is but slightly affected in the earlier stages of the degeneration and only becomes materially diminished when the process has involved the region of the macula lutea. The field of vision becomes concentrically contracted, extending as the disease advances until often there is such extreme narrowing of the field that the patient is only able to read by fixing a single word at a time. In extreme cases the contraction progresses to complete blindness. Hemeralopia or night blindness is usually one of the earliest symptoms and often the first to attract the patients' attention.—they noticing that on approach of dusk their movements become uncertain and that they are apt to stumble over objects.

Ophthalmoscopic examination presents a striking and characteristic appearance. (See Fig. 5, Plate I.) The entire periphery of the fundus will generally show beautifully arranged masses of pigment, which assume the shape and appearance of bone corpuscles, the processes from which extending off to unite with each other form a network which encircles the periphery of the fundus. The pigmentation will often extend farther toward the macula on the temporal than on the nasal side and is frequently seen extending farther backward along the course of the vessels. The retinal vessels, both arteries and veins, become greatly contracted, and, in advanced cases, are diminished to such an extent as to appear of thread-like dimensions. The optic disc becomes of a creamy white appearance,

at the same time the vessels are gradually narrowing, owing to the loss of its capillary circulation.

COURSE.—This condition commencing either congenitally or in early childhood, may remain stationary at some period, but usually advances steadily, with increasing contraction of the field, until finally, at about middle life, vision has become nearly destroyed. Both eyes are almost invariably affected.

CAUSES.—It is undoubtedly of hereditary origin in nearly all cases and consanguinity seems to be an important factor, as intermarriage, one or two generations remote, can generally be found. Congenital deaf-mutism, epilepsy and idiocy are frequently seen in cases of retinitis pigmentosa. This disease is more frequently found in men than in women. The prognosis is unfavorable.

DIAGNOSIS.—Retinitis pigmentosa may be confounded with disseminated choroiditis, but in the latter the shape and arrangement of the pigment is decidedly different, the patches are more or less circular, are isolated and present signs of exudation with atrophy and corresponding white patches with irregularly pigmented borders. In retinitis there are no choroidal spots, the pigment is stellate and is more apt to be along the vessels or covering them in spots.

COMPLICATIONS.—Nystagmus is frequently present and more especially so in those cases that have become far advanced in very early life. Posterior polar cataract may also be found and very rarely vitreous opacities.

TREATMENT.—Over use of the eyes and exposure to bright light must be avoided. Much attention must be given to the general health for a long period. Lyco., Nux vom. and Phos. are suggested as remedies.

Detachment of the Retina.—(*Amotio Retinæ, Sublatio Retinæ*).

PATHOLOGY.—In simple or idiopathic cases the fluid behind the detachment is found to be albuminous in character and contains blood and lymph corpuscles, fat cells, pigment, epithelium, etc. The vitreous is usually liquid and the retinal changes consist in a destruction of the rods and cones; fibrous tissue may be formed in the retina and atrophy of the nerve elements ensues. When detachment occurs as a result of morbid conditions of other structures, such as cyclitis and choroiditis, there is, of course, the added pathological changes of those diseases.

SYMPTOMS.—There is more or less loss of vision, which may come on suddenly. This is usually the first symptom to attract the patient's attention to the eyes, although sometimes black spots floating before the eyes or flashes and rays of light have been noticed as preceding a detachment. Vision is not wholly lost, unless the region of the macula is involved in the detachment. The field of vision is contracted in that portion corresponding to the detached part. This restriction in the field often escapes observation in fresh detachments, because the retina retains its functions to a certain extent, unless the examination be made carefully and with a weak light. When the detachment is due to a tumor, the defect in the field of vision is more sharply defined than when the result of an exudation and the central vision may remain unaffected. If the detachment be of the lower part of the retina, the upper portion of the field of vision is lost, and, if above, the lower, and so on. Patients complain of a distortion of objects, of black spots floating before the vision—due to opacities of the vitreous and of various light sensations and phosphenes. Night blindness may or may not be present.

The objective appearances with the ophthalmoscope are best seen by an examination by the direct method and there is then noticed, in place of the normal red reflex from the fundus, a green or bluish-gray (see Fig. 8, Plate II.) membrane which is thrown up into folds and extending forward into the vitreous. The detached retina as a rule is seen to oscillate on movement of the eye and the vessels on the surface of the detached part appear darker and often smaller than normal. Movements of the detached retina are seen when the underlying substance is fluid and the amount of motion depends upon the consistency of the vitreous and is not seen when there is a solid substance, as a tumor, beneath. At the borders of the detachment, which are usually sharply defined from the normal fundus, the retinal vessels pass out of focus and a change of focus is always necessary on passing from a normal to a detached portion of the retina.

The retinal vessels, as they rise over the separated portion, lose their light streak and appear dark and tortuous as they course up and down over the furrows of the detachment. In some rare cases, owing to the absence of turbidity of the fluid behind the detached portion, the retina remains clear and the diagnosis then depends upon find-

ing an area which, in order to be distinctly seen, requires an alteration in the focus. The detachment, bringing that part of the retina further forward, renders it more hyperopic when occurring in a hyperopic eye and less myopic when found in myopia. There may often be seen a rupture at some portion of the detached retina. The size and position of these rents vary in different cases. Diminished tension is usually found in all cases that existed for some time and when not due to a tumor. The detachment may occur in any part of the fundus, though usually below, and, if above, is apt to extend to the lower part of the fundus from a sinking of the fluid. Detachments may be complete or only partial, and, when the latter, may appear as a small line or furrow or may be more or less circular in shape.

COURSE.—Detachment often develops within a few hours, but it may gradually take place during one or two weeks. There is usually no pain and the patient is often unaware of when it occurred. Idiopathic detachment is frequently found in both eyes, but rarely occurs in both eyes simultaneously, the second eye being involved often only after many years.

CAUSES.—Separation of the retina is most frequently found in myopic eyes, and is more apt to occur in very high degrees of myopia. Statistics, based upon the German clinics, show that myopia exists in upward of 60 per cent. of the cases. In this country, however, where myopia is not so common as in Germany, we believe the proportion is much smaller. In Horner's clinic 48 per cent. occurred in myopic eyes and 16 per cent. were due to injury and one-half of the cases were in persons of upward of fifty years of age. It seems to occur more frequently in men than in women. It results from traumatism, hæmorrhages, intraocular tumors, cysticerci and from diseased conditions of the eye, such as retinitis, cyclitis, iridocyclitis, etc.

The mechanism of a detachment has been the subject of extended investigation, and the researches of Leber and Nordenson would indicate that it is due to a shrinking of the anterior portion of the vitreous, which, by dragging upon the retina, causes a rupture and that the fluid of the vitreous passes in behind the retina through the rupture and fills up the space left by the membrane. The primary cause, therefore, seems to be due to some change in the vit-

reous which may perhaps be due to some senile change or to some disease of the choroid or ciliary body whereby the nutrition of the vitreous has become altered.

DIAGNOSIS—In the majority of cases the ophthalmoscopic appearances present such a perfect picture that no trouble is found in recognizing a detachment. The only difficulty occurs in small or transparent detachments, and these will usually be revealed by a careful examination with the aid of a mydriatic. The most important point in the diagnosis is to determine whether it is due to an intra-ocular tumor, and the most valuable sign rests on the tension, which is plus in tumor and minus in simple detachment.

PROGNOSIS.—This, as a rule, is unfavorable, for the detachment, when of any size, will often extend and become total, no matter what care or treatment is followed. A detachment of the upper part of the fundus will usually extend to the lower, from a sinking of the sub-retinal fluid. Cataract frequently occurs in cases of detached retina. Spontaneous re-attachment may take place after a longer or shorter interval, and, when it occurs early, the vision may be greatly restored and no ophthalmoscopic signs be seen that any detachment has taken place.

TREATMENT.—If the patient comes under treatment a short time after the detachment has occurred, or even six months afterward, he should be confined to his bed, chiefly upon his back, with the eyes bandaged. This is of great importance in aiding recovery. If it is impossible to confine the patient to his room, he must be warned to avoid all use of the eyes and to keep as quiet as possible. If he must be out in the light the eyes should be protected by darkly colored glasses. In many cases, the constant use of Atropine is of advantage, as it prevents accommodation and thus keeps the eye and tissues more quiet.

Operations to allow the escape of the fluids have been reported with some success. Sutphen¹ reports three cases of detachment of the retina treated by puncture, with one success and two failures. Bull² reports five cases treated by Schoeller's method of injecting an irritating fluid into the vitreous, to tear the shrinking or contracting bands in the vitreous and to produce an adhesive retinitis. In all

¹ Trans. Amer. Ophthal. Soc., 1888.

² Trans. Amer. Ophthal. Soc., 1891.

of these cases the results were unfavorable. They may, however, be advisable in some instances, especially if the detachment is above.

Apis.—Fluid beneath the retina. Pressive pain in the lower part of the ball, with flushed face and head. Stinging pains through the eye. Œdematous swelling of the lids.

Arnica.—*Traumatic detachment of the retina.*

Aurum.—Has been used successfully in amotio retinae. It is especially adapted to those cases which follow over-dosing with potash or mercury. The symptom under Aurum which suggests its use is as follows: "Upper half of vision as if covered by a black body, lower half visible." The choroid, or retina, is usually inflamed, and opacities are seen in the vitreous, giving rise to the "blacks" complained of by the patient.

Digitalis.—Adapted to the general pathological condition and has this common symptom of detachment of the retina: "As if the upper half of the vision were covered by a dark cloud evenings, on walking." Benefit has been seen from its use.

Gelsemium.—One of the most prominent remedies for *serous infiltration beneath the retina* dependent upon injury, myopia, or ciliary neuralgia. Especially indicated if accompanied by choroiditis, with haziness of the vitreous and some pain. A bluish haze, or wavering, is often observed.

Ars., Bry., Hep., Kali iod., Merc. and *Rhus* may also be thought of for this condition.

Ischæmia Retinæ (*Anæmia of the Retina*).—This term has been applied to a peculiar condition of the retinal circulation which has been seen or recorded but a few times.

It consists in a great reduction in the size of the retinal vessels, especially the arteries, which appear as very fine threads, and in one case recorded by Knapp¹ could not be found at all in one eye. This was a case of sudden blindness during whooping cough, the optic nerves were white and the vessels were all very fine and thread-like, while no arteries could be discerned in the right eye. No other lesions were present. Vision improved and there was an increase in the size of the vessels after paracentesis was made.

The reduction in the size of the arteries, as a rule, is the only oph-

¹ Archiv. Ophthalm., vol. iv., p. 448, 1875.

thalmoscopic appearance present, although the optic disc may be pale and its outlines indistinct. There is usually total blindness, and the attack may last from a single moment to several weeks. The trouble has been supposed to be due to reduced heart's action, and, by von Graefe, attributed to some obstructive cause within the optic sheath.

TREATMENT.—When the anæmic condition of the retina is complete (vision entirely lost), paracentesis or iridectomy, to diminish the intraocular tension, becomes necessary. Inhalation of nitrite of amyl will be of service. We sometimes observe a partial anæmia of the optic nerve and retina associated with and dependent upon general anæmia. These cases should be treated by the administration of those medicines indicated by the general condition of the patient, as Calc., China, Ferrum, Phos., Puls., etc.

Agaricus has cured cases accompanied by a tendency toward chorea.

Embolia Arteria Centralis Retinæ.—An embolus may become lodged in the central artery of the retina, or in any of its branches. It is only rarely that the circulation becomes completely stopped.

SYMPTOMS.—There is nearly always sudden loss of sight, without pain or external symptoms. Occasionally there is slight giddiness and headache, flashes of light and some uncertainty of vision preceding the sudden onset of blindness. The field of vision, in complete obstruction, is lost in all directions, as there may be even no perception of light in these cases. If one of the branches is involved, there may be simply a loss of the field of vision in one direction. The pupil may be somewhat dilated and will not respond to light. The tension may be either increased, decreased or normal.

The optic nerve becomes paler and of a grayish-white appearance from a diminished amount of blood in its capillaries. The retinal vessels appear thin and contracted, the arteries can only be traced for a short distance into the retina, while the veins present a contraction as they pass from the disc, but become fuller again toward the periphery of the fundus. Very rarely an occasional small hæmorrhage may be seen along the course of the vessel, which, if present, indicates that the obstruction is either not complete or that it is due to a venous thrombosis. There is a whitish opacity of the retina, especially in the region of the macula and around the disc. This

opacity may come on within a few hours or it may be delayed a week and after a time it begins to disappear. The opacity of the retina probably occurs in the inner layers, which receive their blood supply from the retinal arteries. In connection with the appearance of the opacity around the macula there is seen a cherry red spot corresponding to the position of the fovea centralis. This bright red spot is due to the red color of the choroid shining through the thinned retina and is less likely to form when the stoppage is in some of the retinal branches. After some weeks the optic disc undergoes atrophy, the retinal opacity subsides, the arteries show a white streak and may become converted into white threads; if hæmorrhages have occurred they undergo degenerative changes.

When the embolus becomes lodged in one of the branches it may sometimes be seen with the ophthalmoscope, but as a rule the diagnosis is made on account of a swelling in the artery at some point with an obliteration of the vessel beyond.

Thrombosis of the central vein will present appearances very similar to those of an embolus of the artery, but with more inflammatory symptoms, simulating to some extent retinitis hæmorrhagica. In complete stoppage of the vein the optic disc will be nearly obliterated by hæmorrhage, there will be numerous hæmorrhages throughout the retina and especially along the course of the vessels, and, together with these, yellowish patches of exudation. The veins will be enlarged and tortuous and the arteries small and straight, and there may be a diffuse opacity of the retina.

In partial plugging of the vein there will be less opacity of the retina and fewer hæmorrhages, the veins will be enlarged and the arteries contracted. Vision is wholly or partially destroyed, and there may be recurrences of the hæmorrhage. Interesting cases of thrombosis of the central vessels were reported by Loring¹ which he had previously reported to the American Ophthalmological Society as cases of embolism. Later Angelucci gave the following differential diagnostic points:

Embolism.—Normal course of vessels, arteries narrowed, veins gradually increasing in calibre toward the periphery, no venous pulsation, absence of retinal hæmorrhages.

Thrombosis.—Tortuosity of vessels, arteries of normal calibre or

¹ Amer. Journ. Med. Sci., April, 1874.

nearly so, veins gorged with blood and here and there interrupted, venous pulsation and retinal hæmorrhages."

CAUSES.—Valvular disease of the heart, especially when complicated by an acute endocarditis, is the most frequent cause of embolism. It occurs also in diseases of the kidney and aneurisms. While a thrombus generally results from a phlebitis and also in cardiac diseases, embolism may occur at any age and usually affects but one eye.

PROGNOSIS.—This is always unfavorable, as embolism of the central artery, when complete, almost invariably leads to blindness. In some cases there will at first apparently be some improvement, but even in these cases optic nerve atrophy is apt to follow. When, however, a branch, instead of the main trunk, is involved, the prognosis is, of course, more favorable.

TREATMENT.—But little if anything of value can be done for this condition. Operations to reduce the intraocular tension, in hopes of restoring the circulation, such as sclerotomy, iridectomy and frequently repeated paracentesis, have been practiced. Inhalations of the Nitrite of Amyl has been credited with curing some cases of embolism.

Vision may, in exceptional cases, return without any treatment, though it is better to give those remedies which seem to be constitutionally required.

By reference to *Opium* a case will be found described in which a cure was effected. Whether or not this was due to the Opium administered is a question.

Hyperæsthesia Retinæ.—Over-sensitiveness of the retina to light may be a symptom of inflammation, but it also results from close application of the eyes at fine work. It may also be found in neurotic or hysterical subjects and may or may not be associated with refractive errors.

SYMPTOMS.—There is a dread of light, which may be so intense that the subjects will shield their eyes from all light, and it often results in a blepharospasm. There is frequently lachrymation and more or less neuralgic pains around the eyes and head. The vision is not at all affected, but we find many of the asthenopic symptoms so often present in refractive errors, such as fatigue upon using the eyes, with some blurring of near objects, and sometimes dizziness

and nausea are complained of. Upon ophthalmoscopic examination we may find slight congestion of the disc and retina. In the higher degrees of irritation the outlines of the disc become ill-defined. Loring believes that atrophy of the optic nerve may be excited by a chronic condition of irritation. Recent researches in the line of reflex irritation have shown that frequently troubles in the nasal passages will give rise to irritation of the eyes.

TREATMENT.—If dependent upon any anomaly of refraction, the proper glass must first be prescribed.

In rare, severe cases it may be necessary to confine the patient in complete darkness for a week or more and then gradually accustom him to the light. Though usually it is better to advise *exercise in the open air*, having the eyes protected by smoked or blue glasses or a shade. Especial attention must be paid to the general health of the patient.

Belladonna.—*Hyperæsthesia of the retina*, particularly if dependent upon some anomaly of refraction or reflex irritation. *Eyes very sensitive to light*; cannot bear it, as it produces severe aching and pain in the eye and even *headache*. Flashes of light and sparks observed before the vision. The eye symptoms as well as the headache are usually aggravated in the afternoon and evening.

Conium.—*Over-sensitiveness of the retina to light*, especially if accompanied with asthenopic symptoms, so that one cannot read long without the letters running together; with pain deep in the eye. Excessive photopsies, but fundus normal in appearance. Photophobia. Everything looks white.

Ignatia.—*Hyperæsthesia of the retina* in nervous, hysterical patients. Great dread of light and severe pain around the eye.

Lactic acid.—*Hyperæsthesia of the retina*, with steady aching pain in and behind the eyeball.

Macrotin.—Angell considers Macrotin more widely serviceable than any other one remedy. The ciliary neuralgia is usually marked.

Merc. sol.—Eyes more sensitive to artificial light, and in the evening.

Natrum mur.—*Hyperæsthesia of the retina*, especially from reflex irritation in chlorotic females; there is great photophobia, with muscular asthenopia; some conjunctival injection; *eyes feel stiff and ache*

on moving them or on reading; letters run together on attempting to read; sticking, throbbing headache in the temples.

Nux vomica.—When the *photophobia is excessive in the morning* and better as the day advances.

A large number of remedies which produce marked photophobia may be indicated by the general symptoms and cachexia of the patient, as Acon., Antimon. tart., Ars., China, Gels., Hep., Hyos., Puls., Rhus., Sep., Sulph., etc.

Commotio Retinæ.—This term is applied to sudden loss of vision from blows or concussion of the eyeball. Such injuries may cause an affection of almost any structure of the eye—the cornea, iris, lens, sclera, etc. An injury from a blow upon the eye may result in an almost complete loss of vision without any immediate evidence of damage having been done; although, after a time, there may be signs of atrophy of the nerve. In more moderate injuries, such as from the cork of a bottle, there may be slight ciliary injection, some contraction and sluggishness of the iris and a grayish haziness of the retina, especially in the region of the macula. This opacity of the retina is of considerable size and is due to an acute œdema of the retina, which comes on within a few hours and disappears after two or three days. There may be a decrease in the size of the arteries and an enlargement of the veins. Vision may be more or less affected and is not perfectly regained until long after the opacity of the retina has disappeared.

Glioma Retinæ (*Fungus Hæmatodes of the Eye, Encephaloid of the Retina*).—Gliomata are the only tumors arising from the retina, and they take their origin from the connective tissue or neuroglia of the retina.

PATHOLOGY.—It consists of small round cells, similar to those of the granular layers of the retina, numerous blood vessels and a small amount of fibrous tissue. A glioma most often originates from the external granular layer, although it may have its starting point in any of the other layers of the retina; it may extend either outward or inward from its place of origin and its especial path of extension is along the optic nerve. Its histological features are identical with small, round-celled sarcoma and is often called a glio-sarcoma.

SYMPTOMS AND COURSE.—The condition generally first noticed is a bright reflex from the interior of the eye. There is no pain or

redness and the anterior part of the eye is normal. When seen early there is noticed, with the ophthalmoscope, a white or yellowish-red tumor, with either a nodulated or smooth surface, and usually blood vessels are seen coursing over its surface. The retina is generally detached and the lens and vitreous are clear. As the tumor increases, the iris and lens become pushed forward and the anterior chamber shallow. The growth continues to increase, causing distension of the eye; pain sets in, the coats of the eye give way and the tumor appears externally. It becomes ulcerated, bleeds easily and exudes a bloody, foetid discharge. Its growth is rapid and soon involves the orbit and temporal regions and presents a huge vascular mass. The choroid and optic nerve become involved—first the medullary portion of the nerve and then the sheath. This causes a thickening of the nerve, and, in this way, extension to the brain. Metastasis may take place to other parts of the body, the patient becomes cachectic and death from exhaustion or brain-disease is the final result.

CAUSES.—Glioma of the retina is either congenital or occurs in infants. It usually appears under the age of ten, and no cases are on record where it occurred after the sixteenth year. Usually but one eye is involved, although both may be implicated simultaneously or in succession.

DIAGNOSIS.—Purulent choroiditis so closely simulates glioma as to be spoken of sometimes as *psuedo-glioma*. The differential diagnosis depends on the history and local appearances. In choroiditis there is the history of previous illness, and often an inflammation of the eye will have been noticed. These two symptoms are the essential diagnostic points, although in choroiditis the mass is apt to be more yellowish in appearance and the tension minus; while in glioma the tension is rarely low and may be increased even before glaucomatous symptoms become evident.

PROGNOSIS.—In glioma the prognosis is always bad, although numerous cases are recorded where the eye has been removed early with no recurrence of the growth, but it is altogether hopeless, if left to its own course. The most common method of death is by an extension along the optic nerve to the brain. If a relapse occurs after enucleation a fatal issue is most certain. Noyes (*loc. cit.*) says: "A single case is given in which the patient survived after removal

of a secondary tumor." To this may be added a case reported by Dr. Geo. S. Norton,¹ where the secondary growth appeared about two and one-half months after the enucleation, with the previous symptoms of constitutional disturbance. This was removed and the fluid extract of Red Clover blossoms (*Ceanothus Americana*) administered. This patient was last seen by the writer over four years later, at which time she was in perfect health and with no signs of any return of the growth.

TREATMENT.—This should always be by operation, and, if the enucleation is made in the very early stage, there is a fair chance of eradicating the disease, which is at this time purely local. In enucleation for glioma it is always best to remove as long a portion of the optic nerve as possible. If the operation is made in the glaucomatous or later stages of the disease, all the contents of the orbit should be removed. After the growth has perforated the eyeball and becomes of a fungus appearance, operation can only be considered for relief of the pain, as it is then too late to offer any hope of preserving the life.

The use of Red Clover blossoms to prevent the recurrence of glioma, after operation, seems from the cases reported by French² and Norton (*loc. cit.*) to be worthy of a trial in all cases of this malignant disease. So far as we have been able to find, no other medication has ever proved of any value.

¹ Journ. Ophthal., Otol. and Laryngol., vol. 2, April, 1890.

² Trans. Amer. Inst. Hom., 1884.

CHAPTER XIII.

Diseases of the Optic Nerve.

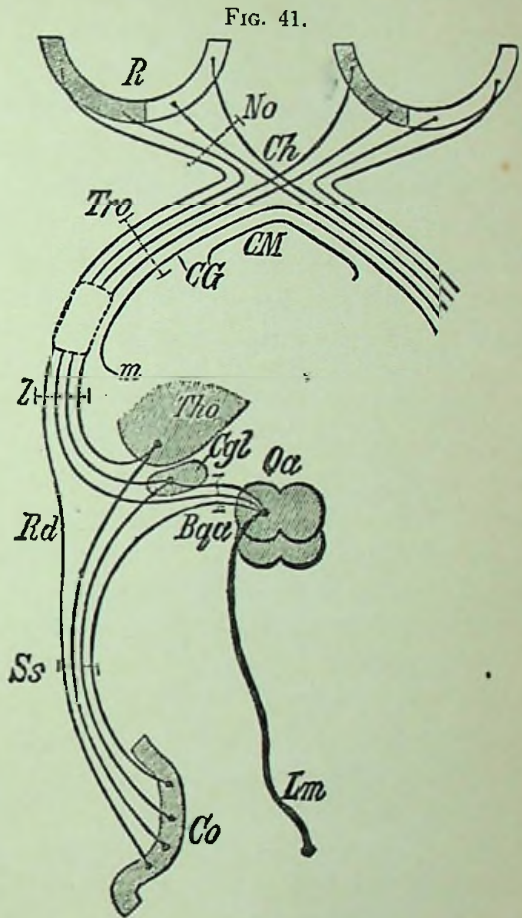
Anatomy.—The optic nerve extends from its terminal expansion, the retina, which receives visual impressions, to the brain centres, where perception takes place. It may be divided for its anatomical consideration into three separate regions—cranial, orbital and intra-ocular portions.

Each optic tract arises by two roots, of which the *external* is made up of fibres arising from the corpus geniculatum externum, from the thalamus opticus and from the anterior corpus quadrigeminum. From these ganglia radiating fibres extend to the gray matter of the occipital lobe. The *inner* root of the optic tract receives fibres from the corpus geniculatum internum and from both the posterior and anterior corpus quadrigeminum. Another bundle of fibres comes direct from the cortex of the occipital lobe. Other fibres have been traced as coming through the crus cerebri and along the pons varolii from the posterior columns of the cord. Still other fibres of this internal root come from the corpus dentatum of the cerebellum.

The optic tract formed by the union of these two roots passes forward along the inferior surface of the thalamus opticus, crosses the crus cerebri and unites upon the olivary process of the sphenoid bone with the optic tract from the opposite side to form the optic chiasm or commissure.

In addition to the fibres of the optic tracts, the chiasm has fibres which appear to come from the corpus subthalamicum and serve to connect corresponding parts on opposite sides of the brain. They are known as the commissural fibres of Meynert and of Gudden, and have no direct visual function (Fig. 41). In the optic commissure the fibres of each optic tract undergo partial decussation, the fibres of the right optic tract supplying the right half of each retina and the left optic tract supplies the left half of each retina. The divid-

ing line in the eye is on the vertical meridian through the macula, while at the fovea there is an intermingling of the fibres from both sides. The orbital portion of the optic nerve commences where it passes through the optic foramen from its origin in the optic commissure. From the chiasm to the foramen the nerve is about 10 mm. long, and from the foramen to the eyeball it is about 28 mm. long and 4 mm. in diameter. At the optic foramen the nerve becomes invested with a sheath from the dura mater, in addition to the pial sheath in which it has been inclosed while in the skull. Between the dural and pial sheaths of the optic nerve is a space which is imperfectly divided by trabeculae of connective tissue and containing lymph. This space is directly continuous with the arachnoid cavity of the brain. Another lymph space lies beneath the pial sheath, but this is normally only microscopical. The arteria and vena centralis retinae pierces the nerve about 15 mm. behind the eyeball. The central artery does not supply the nerve



Scheme of the Central Visual Apparatus. *R*, retina, shaded where it is innervated by the left, clear where innervated by the right hemisphere; *No*, nervus opticus; *Ch*, chiasma; *Tro*, tractus opticus; *CM*, Meynert's commissure; *CG*, Gudden's commissure; *l*, lateral tract root; *m*, median tract root; *Tho*, thalamus opticus; *Cgl*, corpus geniculatum laterale; *Qu*, nates; *Bqa*, brachia anteriora; *Rd*, direct cortical tract root; *Ss*, sagittal medullary layer of occipital lobe; *Co*, cortex (chiefly of the cuneus); *Lm*, median tract (Schleife).

behind the eyeball. The central artery does not supply the nerve

as a whole, but gives off very minute branches just behind the lamina cribrosa to supply it and the optic papilla.

The pial sheath is a fibro-vascular structure, very closely adherent to the nerve and gives off connective-tissue bands which form a network of trabecular tissue between the fibres of the nerve. It receives its blood supply from branches of the ophthalmic artery, and, by its continuity with the pia mater, forms a communication between the intra-cranial and orbital arteries. The pial sheath terminates by becoming blended with the inner layers of the sclera. The dural sheath forms a fibrous covering to the nerve and terminates by blending with the outer layers of the sclera.

The ocular portion of the optic nerve is that part where it penetrates the globe. On passing into the eyeball the sheaths are left behind, as described above, and with them the connective-tissue septa separating the fibres turn aside and blend with the sclera. The nerve fibres, having lost their neuroglia, are continued as naked axis cylinders, and terminate as the optic papilla.

The *lamina cribrosa* is made up of fibrous tissue interwoven with the connective-tissue sheaths and septa from the optic nerve at the level of the sclerotic opening. This structure is more or less visible with the ophthalmoscope and represents the limit of an ophthalmoscopic view. The optic nerve fibres, in order to gain entrance to the globe, must pierce both the sclera and choroid, which they do through a circular opening. The edge of this opening may be in close contact with the nerve or a small space may be left through which the sclera may be seen. Krause estimates the number of fibres within the optic nerve as high as 400,000.

The ophthalmoscopic appearance of the healthy papilla is that of a whitish, circular area, due to the lamina cribrosa, which shines through the transparent nerve fibres—the white substance of the sheaths having terminated at this point. It generally has a pinkish tint, due to the presence of capillaries, the degree of this coloration varying in different individuals. A little to the inner side of the disc the central artery of the retina is seen to emerge, which usually is seen to divide after passing the lamina cribrosa, although it may sometimes have divided before coming into view. The two chief divisions thus formed pass, one upward and the other downward, to the retina. The central vein is somewhat darker in color and

larger in size than the artery and accompanies it. There are frequently small lines of pigment bordering the disc at some point.

The *physiological cup* is an excavation at about the centre of the disc of a varying extent, but it never reaches to the edge of the disc, as does the cup of glaucoma. It is usually funnel-shaped and more distinctly white in appearance than is the rest of the disc. (See Fig. 2, Plate I.). This is due to an exposure of the central part of the lamina cribrosa from the divergence of the nerve fibres as they turn or bend to pass over into the retina.

The *sclerotic ring* is a whitish ring found at the edge of the disc and is caused by the opening in the choroid being somewhat larger than that in the sclera, and thus permitting the sclera to be seen through the transparent nerve fibres. It is generally more visible at the outer side of the disc, owing to a greater thinness of the nerve fibres at that point. The average diameter of the disc is about 1.6 mm., its apparent size varying with the refraction of the eye.

Opaque Nerve Fibres.—This is a rather frequent congenital anomaly which generally affects but one eye, though it is sometimes seen in both. The condition is due to the continuance of the sheaths of some of the fibres of the nerve for a certain distance into the retina. Opaque fibres are most often seen extending either above or below (See Fig. 10, Plate II.) and are usually grouped together, appearing as a white patch, which runs a variable distance, sometimes ending abruptly, but generally as a striated, fan-shaped margin. The diagnosis of the condition is not difficult; and yet it is sometimes confused with atrophy of the choroid or with the white mound around the disc seen in retinitis albuminurica. In opaque nerve fibres the white or yellowish patch is continuous with and concealing the margins of the disc. The retinal vessels may be wholly concealed or will appear here and there. The surrounding parts of the fundus are normal and vision is usually only affected by an enlargement of the blind spot.

Coloboma of the Sheath.—This is another very rare anomaly which depends upon an imperfect closure of the fetal fissure and is very frequently mistaken for a retraction of the choroid found in myopia. It is often accompanied by a fissure or defect in the choroid; but, unlike choroidal changes, it has no pigment border. There is an apparent elongation downward and backward of the nerve

which has a concave look. The nerve runs into the exposed sclera or sheath. The usual location of the coloboma is at the lower part of the disc, though in three cases that came under my observation and reported in the *Journal of Ophthalmology, Otology and Laryngology*, vol. ii., p. 2, 1890, the coloboma was in each instance at the upper part of the disc.

Hyperæmia of the Disc.—Simple congestion of the disc is evidenced by an increased redness, it assuming a general dull red hue which shades off into the surrounding fundus so that the outlines of the disc become blurred and indistinct. In addition to the appearance of the disc, as seen with the ophthalmoscope, there may be some photophobia, fatigue on using the eyes or slight pains around the eye. Hyperæmia may be caused by refractive errors, especially in hypermetropic eyes. It is also common in those exposed for a long period to the glare of a bright light. Cerebral hyperæmia, fracture of the skull, or morbid process at the base of the skull may result in hyperæmia of the optic nerve.

As the normal redness of the disc may vary, being greater in plethoric persons and in those using alcohol to excess, it is always somewhat difficult to say when an abnormal congestion is present.

The *treatment* must be directed to the cause, as it is more frequently symptomatic than idiopathic. The remedies especially to be considered are Bell., Duboisia, Phos. and Pulsat.

Hæmorrhage of the Optic Nerve.—When the extravasation occurs in the papilla it is readily seen and is found to occur where the vessels have become degenerated, as in albuminuria, diabetes, etc. It may also occur in embolism or thrombus of the central vessels, and is perhaps most frequently seen in some form of neuritis or neuro-retinitis. In these cases the vision may be but little affected, unless the fibres going to the macula are involved, when the damage to sight is serious.

Hæmorrhage into the sheath of the nerve behind the eye is more rare and generally results from injury, as fracture of the base of the skull or of the orbit. The ophthalmoscopic signs are not at all indicative of the condition, as they may simply consist in a slight hyperæmia and haziness of the retina, or there may be all the characteristic signs of embolism of the central artery. The vision is as a rule destroyed from atrophy.

Neuritis Optica.—Inflammation of the optic nerve has been divided clinically into several forms, viz. : *Papillitis or choked disc, neuritis descendens or neuro-retinitis, peri-neuritis or retinitis circum-papillaris* and *neuritis retro-bulbaris*. As all but the last variety present ophthalmoscopic signs and are very similar in appearances as well as causes and pathological changes, they will be described under the general heading of neuritis optica, while to the last form of neuritis retro-bulbaris, we shall devote a separate space.

PATHOLOGY.—There may be two forms of pathological changes in inflammation of the optic nerve, *i. e.*, serous and plastic infiltration. In the serous form there is simply an œdema, with a crowding away of the retina from the disc and sometimes colloid bodies are found scattered throughout the disc.

The most frequent form of neuritis is the plastic or interstitial form, which may be primary or succeed the serous form just described. In this there is excessive infiltration of cells, with an increase of the connective tissue, especially of that surrounding the central vessels of the nerve, together with that forming the neuroglia of the nerve itself. The nerve fibres themselves are but little affected, or, at most, somewhat more freely supplied with nuclei. Later on the pressure from the increased size of the nerve results in an atrophy of the nerve fibres. The atrophic changes of the nerve in choked disc are described at length by Ulrich.¹ In some cases where there is less thickening of the connective tissue, gray atrophy ensues, in which the nerve fibres are preserved, but become smaller through loss of their medullary sheath.

SYMPTOMS.—There are no external signs of neuritis, excepting in some cases a dilatation of the pupils, and, when present, is generally in those cases where central vision has been lost for some time, and in complete blindness the pupil is not only dilated, but is usually immobile. Pain is only present in those cases due to some orbital affection, when there may be some tenderness on pressure. Occasionally there is some protrusion of the eye and there may be some swelling of the lids. The vision in neuritis is sometimes perfectly normal, and yet the ophthalmoscopic picture of inflammation of the optic nerve be quite characteristic. This fact illustrates

¹ Archiv. Ophthalm., vol. xviii., 1, 1889.

the importance of an ophthalmoscopic examination in all cases, even though central vision be perfect. Usually there is, however, more or less impairment of vision, which may have come on quite rapidly or more often gradually. In some cases of an œdematous papillitis the vision will remain normal for several weeks and then commence to gradually fail, while in other cases it will be impaired from the first and steadily become worse.

The field of vision may be variously affected, sometimes remaining normal; again it may become concentrically contracted, or it may be irregularly contracted in different sections. Hemianopsia, absence of half of the visual field, may be present and be either horizontal or vertical, and indicates the origin of the neuritis to be intracranial. There may be a central scotoma, due to an enlargement of the normal blind spot from swelling, or there may be an abnormal scotoma, due to involvement of the axial fibres. Color sense may or may not be lost, and, when it fails, generally does so in the usual order of green first, then red and blue last. The loss of color perception is generally proportionate with the loss of central vision and affords an indication as to the course of the disease. If the vision and color sense fail gradually and proportionally, atrophy may be expected to follow, and, in cases where recovery takes place, the visual field and color perception return proportionately.

As the ophthalmoscopic symptoms vary somewhat in the different forms of neuritis, we shall briefly consider the various types before continuing with the study of the disease as a whole.

In *papillitis*, or *choked disc*, we find in its simplest form a serous infiltration, causing an excessive swelling, with redness of the disc and engorgement of the retinal veins. There is no loss of transparency in the process thus far, but to this may be added other inflammatory changes, resulting in a grayish exudation into the disc and surrounding retina, with sometimes hæmorrhages. When both eyes are affected, one is usually more so than the other and one nerve is apt to be affected before the other. The swelling in a marked case of choked disc, due to serous infiltration, forms an almost globular, bright red mass of marked prominence, measuring from two to six dioptries, whose outlines shade off into the surrounding retina. The retina may or may not be infiltrated, its arteries are small, but the veins are engorged. In cases where there is a more marked plastic

infiltration the disc is not only greatly enlarged, but more opaque; there is greater involvement of the retina, a yellowish exudation frequently taking place in the region of the macula resembling that of embolism, together with more extensive hæmorrhages and sometimes vitreous opacities. These cases are very similar to those of neuritis descendens and are most frequently found affecting both eyes, as is the rule in almost all cases of papillitis, when of intracranial origin. Cases due to intracranial lesion have been reported in which but one eye was affected. Monocular papillitis, due to cerebral tumor, usually affects the eye to the opposite side of the tumor, but in all cases of neuritis affecting but one eye the cause is generally below the optic chiasm.

In *neuritis descendens*, or *neuro-retinitis* the ophthalmoscopic appearances, while somewhat similar to those of papillitis, are not so well marked. There is less swelling of the disc, its outlines are indistinct, the arteries small and the veins enlarged. (See Fig. 9, Plate II.). The disc is opaque and of a deep red color and there is apt to be an infiltration along the retinal vessels. There is often more extensive changes in both the nerve and retina, which become swollen and infiltrated, white patches appearing in the retina in the vicinity of the macula and disc. These patches in the neighborhood of the macula often assuming the stellate appearance seen in *retinitis albuminurica*.

In *peri-neuritis* the centre of the disc appears depressed and surrounded by some swelling of the periphery. The redness of the disc may be general or confined to the periphery. The surrounding retina appears striated and infiltrated. This is a much more rare form than those just described, and, when seen, has been associated with meningitis.

COURSE.—The duration of optic neuritis will vary greatly in different cases. In some the disease will reach its height in two or three weeks, remain stationary for perhaps a similar period and then subside. In these slight or transient cases the course then will extend over a period of from six to eight weeks, at the end of which time the nerve may have returned to its normal condition. These cases are often dependent upon a meningitis which runs its course before the neuritis may be said to have reached its height. Other and more severe cases may develop rapidly, but the subsidence of the neuritis

will be very slow—taking weeks or months. Finally others will be much more chronic in their development and may last for a year or more without any apparent change recognizable with the ophthalmoscope. A case of choked disc has been reported by Matthewson¹ in which the appearance of the nerve remained unchanged for three years.

CAUSES.—It is impossible to differentiate the various forms of neuritis from the cause, for, while papillitis often indicates a cerebral or intracranial disease, still a neuro-retinitis may originate from similar conditions. If the neuritis is monolateral the cause is probably of local origin, depending upon some disease in the orbital region, as caries, periostitis, tumors and cellulitis, or of some disease of the surrounding structures, such as the frontal sinus or the antrum of Highmore. If bilateral, it is in the majority of instances due to some diseased condition of the brain, of which tumors are by far the most frequent cause. Neuritis resulting from tumors of the brain does not seem to depend upon their size or location, although tumors involving the cerebellum are considered the most apt to cause this lesion, while those of the convexity of the brain are least liable to cause neuritis. All varieties of tumors, together with cysts and abscesses, softening of the brain, cerebritis and hæmorrhage have caused inflammation of the optic nerve. In addition to these local and cerebral causes we may find neuritis appearing in constitutional disturbances of various kinds, among which may be mentioned syphilis. Horstmann² gives the description, together with the field of vision, in eight cases of specific optic neuritis. It may also be found in severe febrile diseases, such as typhus, variola, etc.; from toxic agents, such as lead, albuminuria, etc.; in anæmia, especially when occurring in youth; in females from menstrual disturbances; from simple exposure to cold, and rheumatism. It occurs in all ages and may be congenital. Several cases of optic neuritis have been found accompanying acute myelitis which was located in the lower and middle portions of the cord. The course of the extension in these cases has not been demonstrated, but in all probability takes place along the fibres of the optic tract which have been traced to the posterior columns of the cord.

¹ Trans. Fifth Internat. Ophthal. Congress, p. 613, 1876.

² Archiv. Ophthal., vol. xviii., 2, 1889.

The method by which an intracranial disease causes neuritis optica has been the subject of much research and controversy. We believe the weight of opinion to-day has abandoned the earlier theories and accepts now what might be called two methods of extension. In one it is by hydrops of the sheath, causing, through compression on the nerve, an œdema and neuritis. In the other method there is a descent of the inflammation along the nerve or its sheath as shown by microscopical examination.

PROGNOSIS.—This depends chiefly upon the cause and severity of the disease. If due to some grave cerebral or general disease, it is of course unfavorable; but, if there is no incurable disease behind causing the optic nerve lesion, then the eye trouble may be relieved. The progress of the neuritis is indicated as already mentioned by the progress of the visual and color sense. In neuritis from meningitis, or cerebro-spinal meningitis, useful vision may sometimes be recovered, especially if the primary disease is rapidly controlled or when the optic nerve has become involved only in the later stages of the disease; but, as a rule, however, more or less atrophy ensues. When the neuritis is due to orbital affections, syphilis, anæmia or menstrual disturbances, the prognosis is somewhat more favorable, as restoration of vision may be more or less complete. In all cases of neuritis optica the prognosis should always be guarded, as more or less loss of vision is apt to result from atrophy of the optic nerve.

TREATMENT.—As neuritis usually is associated with other and more serious diseases, the treatment will, as a rule, be directed to the general condition or cause of the neuritis. If resulting from some orbital condition, as cellulitis, tumors, etc., treatment as laid down under those headings would be indicated. In some cases of syphilitic neuritis the use of potassium iodide in large doses has given most flattering results. For other general indications, that which has been said under *Retinitis* applies to neuritis as well.

Neuritis Retro-bulbaris (*Orbital Optic Neuritis, Central Amblyopia, Toxic Amblyopia*).—This consists of an inflammation of the optic nerve between the eyeball and the chiasm and partakes of the nature of both a neuritis and an atrophy.

PATHOLOGY.—The pathological changes in retro-bulbar neuritis have been the subject of extended investigation, and Samelsohn¹ was

¹ Graefe's Archiv., 1882, No. 1.

the first to describe in detail the anatomical changes in this disease. Since then his results have been corroborated by a number of others, among whom may be mentioned the cases of Vossius and Uthoff, reported at a later date in the same archives. More recent papers, to which liberal reference has been made in the preparation of this subject, are those of Knapp¹ and Deady and Crippen². The disease is one of interstitial neuritis, with connective-tissue proliferation, which may start at different points, but especially directly behind the eyeball, or, more rarely, further back at the optic foramen, and has been found in some cases to extend into the cranial cavity. There is an increase of nuclei, hypertrophy of connective tissue and degeneration of nerve fibres, involving a limited area of the optic nerve. Near the eyeball the degenerated area is of a triangular shape, with the base at the lower and outer margin of the nerve and the apex at the central vessels; at the optic foramen the centre of the nerve has become affected, the process having extended gradually from the periphery of the nerve to its centre. The atrophy has been traced back through the chiasm into the optic tracts. This arrangement of the atrophic changes in the different parts of the nerve forms an explanation of the course of the optic nerve fibres going to the macula and also of the white sector of the internal side of the optic disc, seen when the disease has advanced to a certain stage. This same condition is the lesion in central amblyopia from alcoholism and other similar affections. A certain number of healthy nerve fibres may be seen in the atrophic parts, which explains why sight may be preserved in isolated spots of the field in persons practically blind from retro-bulbar neuritis and also why they do not become perfectly blind in the amblyopia from alcohol.

SYMPTOMS.—Knapp divides the disease into acute and chronic types and details the following symptoms as found in *acute retro-bulbar neuritis*: More or less severe headache; pain in the orbit aggravated by movements of the eye and by pressure upon it; impairment of sight which advances rapidly and may cause blindness within a day or two; central scotoma, for both color and form, which may be partial or complete, the periphery of the field remaining normal; diminished color-perception; moderate congestion and

¹ Archiv. Ophthal., vol. xx., 1, 1891.

² Journ. Ophthal., Otol. and Laryngol., vol. iii., 3, 1891.

serous effusion of the optic papilla and surrounding retina, which may be followed by ischæmia, or this may be present from the beginning, and the termination of the condition, as shown by the ophthalmoscope in either a return to the normal, a partial atrophy of the disc—always in the temporal half—or a general atrophy.

CAUSES.—Exposure and over-work, acute infectious diseases, such as measles, rheumatism, diphtheria, etc.; poisoning from alcohol, nicotine, lead, opium, etc., and suppression of menses.

PROGNOSIS is always uncertain, as many cases will either partially or completely recover, while others will result in permanent blindness, with sometimes the preservation of several islets of sight in the visual field, as already referred to.

In the *chronic* type, or what may, perhaps, be more properly termed *toxic retro-bulbar neuritis*, we find the following symptoms are present :

SYMPTOMS.—There is a gradual loss of vision almost always affecting both eyes, the subjects frequently complaining of a fog before the eyes and that they see better at dusk, or day blindness; there is no pain, either spontaneous or upon pressure; central scotoma, at first for colors and then absolute; ring scotoma are sometimes noticed; the color-perception is lost for both red and green, and exceptionally for blue (green appears as a dirty white and red as a brownish color); the range of accommodation is diminished; the peripheral boundaries of the visual field are normal and the ophthalmoscopic appearances in the different stages of the disease may show a slight congestion or a nearly normal condition of the papilla; an atrophy of the lower and outer segment of the disc or a general atrophy of the nerve.

CAUSES.—In a large majority of cases it is due to an abuse of alcohol, tobacco, or more frequently of both. Noyes (*loc. cit.*) found, out of 204 cases, that 132 were due to these causes. The remaining cases in the table cited by Noyes were due to diabetes, lead, sulphuret of carbon, syphilis, multiple sclerosis, cold, menstrual disturbances, pregnancy, loss of blood from abortion, anomaly of heart, periostitis orbitæ, and in 32 cases the cause was unknown. That tobacco alone can cause a retro-bulbar neuritis has been denied by some, but sufficient cases have been reported to make it certain in our opinion that it may.

PROGNOSIS.—In the early stage, before atrophy of the optic nerve has occurred, the prognosis may be considered favorable, as more or less complete recovery may be expected. In some cases the sight will return to normal, even though triangular atrophy of the disc remains.

TREATMENT.—When due to alcohol or tobacco, *total abstinence from all spirituous liquors*, or their reduction to a minimum, must be strictly enforced, as well as the necessity of giving up tobacco; after which our attention should be turned to those remedies which will restore the whole system to its natural tone.

Arsenic seems especially adapted to loss of vision dependent upon the use of tobacco.

Nux vom. has been, and probably always will be, the most important and most commonly indicated remedy in this trouble. The results following its use are often marvelous. There are no marked eye symptoms in this disease, and therefore nothing to guide us to this drug with the exception of the cause.

Terebinth.—Amblyopia potatorum, with dull aching pain in the back and dark-colored urine.

Atrophia Nervus Opticus.—Atrophy of the optic nerve may occur in any part of the nerve from the eye to its origin, and, when present, may extend in either direction. Atrophy may be subdivided into primary, secondary or consecutive.

Primary or simple atrophy is that form where the wasting away of the nerve substance has not been preceded by visible signs of inflammation, although Loring believed that all cases, if seen early enough and examined with sufficient care, would have shown evidences of inflammation.

Secondary atrophy is the term applied to those cases due to lesion of some part of the nerve or tract behind the eye and which is only seen at the disc later as a secondary result.

Consecutive atrophy refers to a wasting away of the nervous elements following an inflammation, and this form has again been divided by some into papillitic atrophy and retinitic or choroiditic atrophy, according to an inflammation of whichever tissue it was dependent upon.

PATHOLOGY.—Atrophy consists in a decay of all the nerve elements; there is a degeneration of the nerve fibres, and interspersed

between the fibres are found fat globules, granular cells and amyloid corpuscles; there is an increase of the connective tissue; the walls of the blood vessels become thickened and their calibre reduced; the nerve fibres are reduced to an indifferent structure; the whole nerve becomes smaller and appears to be changed into a cord of connective tissue. The medullary substance is first affected. In gray atrophy, in addition to these changes, the nerve assumes a gray, translucent and jelly-like appearance and a gelatinous substance may be found around the vessels.

SYMPTOMS.—The loss of central vision varies all the way from a slight depreciation to blindness, and, if both eyes are affected, it is apt to be more advanced in one than the other. The contraction of the field of vision is always a well-marked defect; it usually commences as a concentric, peripheric narrowing. The limitation may begin in any direction and advances concentrically, but is usually well advanced before central vision begins to decline; hence, if there is any paleness of the nerve or suspected atrophy, the field of vision should be carefully examined. Occasionally we find an irregular contraction of the field, which will cause a peripheral scotoma corresponding to the defect and it may occur either with or without concentric narrowing. Central scotoma is very rarely found in the earlier stages, yet it may occur. Hemianopsia, or complete loss of one-half of the visual field, may also be found. In this the same side of each eye is usually affected, although it has been seen in simple atrophy affecting the inner half of each retina, and in this respect simulating the limitation due to cerebral disease.

There is always a defect in the color vision in all kinds of atrophy. Green is usually first affected and is confounded with the gray or yellow colors; following the loss of the green will be that of the red, blue, yellow and white in the order named, although exceptionally red may be lost first. Dilatation of the pupil is often present in complete atrophy, and frequently will show no contraction when light is thrown into the eye, but may do so in the act of convergence. When atrophy is present in but one eye, and the pupil makes no contraction from the stimulus of light thrown into that eye, if the light be thrown into the unaffected eye instant contraction will take place in the diseased eye.

The ophthalmoscopic appearances in atrophy of the optic nerve

are always distinctive and characteristic. (See Fig. 11, Plate II.). The first change is the reduction in the amount of the circulation, which first affects the capillaries at the outer part of the disc because they are less numerous in this location. Diminution in the amount of the vascularity in the temporal part of the disc results in a slight paleness, in contrast with which the vessels from the nasal side appear more distinct and on account of this it may be mistaken for a congestion. The paleness then commences on the nasal side and finally extends over the entire surface of the disc. The diminution or disappearance of the capillaries often constitutes all the changes that occur in the vessels, as in some cases the larger vessels will remain normal for years. As a rule, however, there is, especially in consecutive atrophy, a marked decrease in the size of the larger vessels. Occasionally there may be seen a contraction of the arteries, while the veins will remain normal, or appearing, in contrast with the arteries, larger than normal. The light streak is usually lessened and in some cases entirely disappears, while there may be a development of a white line along the course of the vessels.

The alteration in the color of the optic disc admits of considerable variations, from a slight gray to a white hue, and sometimes assumes a greenish or bluish cast. Much care and consideration is always required to distinguish a slight pathological paleness of the nerve from that which is normal or physiological, as the whiteness of the disc may vary decidedly in health. The paleness of the optic disc in atrophy is due to the want of capillary vessels and to the development of connective-tissue. Owing to the shrinking or wasting away of the substance of the nerve in atrophy, the size of the disc appears, and is in reality, smaller than normal. The surface of the disc is flattened or concave, and the extent of the concavity will vary, depending somewhat upon the degree of the normal physiological cup. At the bottom of the excavation in atrophy the lamina cribrosa is usually distinctly seen and has a mottled appearance.

The outlines of the disc, in advanced cases of atrophy, is distinct and clear cut, but in atrophy following inflammation the margins are often veiled and ill-defined for some time.

The surrounding fundus, in atrophy following papillitis or retinitis, will frequently show spots of degeneration and masses of pigment here and there, indicating previous inflammatory changes and

hæmorrhages. In simple gray or white atrophy these spots are not seen.

COURSE.—In optic-nerve atrophy the course depends somewhat upon the cause, but is always slow, lasting for months and in many cases taking years to run its course to complete blindness.

CAUSES.—Gray degeneration occurs generally as the result of some disease of the spinal cord, especially locomotor ataxia; but is also seen in sclerosis and paralysis of the insane. As to the general causes, Noyes (*loc. cit.*) gives the following table of the causes of atrophy in 183 cases cited by Uthtoff:

	Whole Number.	Men.	Women.
Spinal cord.....	59	55	4
Brain.....	41	23	18
Simple progressive.....	22	16	6
After neuritis optica.....	17	13	4
Sudden embolism of arteries.....	8	3	5
Disease and accident in orbit.....	8	3	5
Dementia paralytica.....	7	6	1
Loss of blood.....	4	0	4
Alcoholism.....	4	4	0
Lead poisoning.....	2	2	0
Hereditary.....	3	2	1
Injury.....	3	2	1
Epilepsy.....	2	2	0
Nephritis.....	1	0	1
Railway spine.....	1	1	0
Congenital, with hydrophthalmia...	1	0	1
	183	132	51

In addition to this table, which only includes causes outside of the eye, could be added many other causes, such as syphilis, diabetes, menstrual disturbances, colds, malaria, etc., while, from within the eye, consecutive atrophy may follow from an inflammation of the nerve, retina, choroid, etc. Examination of Uthtoff's table shows a preponderance of cases resulting from lesions of the brain and spinal cord, and this fact has been frequently noticed by other observers, and, hence, examination of the eye is always important in suspected lesions of these structures.

DIAGNOSIS.—In well-marked cases of optic-nerve atrophy, the diagnosis presents no difficulties, but in the earlier stages, or where

there is but slight paleness of the nerve, it often requires a careful consideration of all the symptoms detailed, with especial attention paid to the field and color perception. The differential diagnosis between optic-nerve atrophy and glaucoma will be considered under the latter disease.

PROGNOSIS.—In all forms of atrophy of the nerve the prognosis should always be guarded, for, as a rule, it is unfavorable. In some cases, where the originating cause has been controlled, or but transient, as in meningitis—especially when occurring in young subjects—more or less complete recovery has taken place. Other cases will be met with in which there is a remarkable preservation of the sight, as judged from the appearance of the disc and the circulation. In estimating the prognosis, the field of vision should be carefully watched, as it is considered to be more unfavorable where there is a regular concentric limitation than in the irregularly notched field.

TREATMENT.—In true atrophy of the optic nerve very little can be done to restore vision, though we are often able to check its progress by the selection of appropriate remedies as indicated by general symptoms.

The general health requires most careful attention. The diet should be nutritious and light, while tobacco and all liquors must be prohibited. Mental and physical fatigue must not be allowed.

The hypodermic injection of *Strychnia* has proved efficacious in some instances, though its internal administration is usually more satisfactory.

Favorable results have been reported from the use of galvanism, and it seems as though, when properly and persistently used, it should be of value in checking the progress of the disease at least.

Nux. vom.—Has been followed by more favorable results in this condition than any other remedy.

Argent. nitr., *Verat. vir.* and others have been used with advantage.

Injury of the Optic Nerve.—This may result from a fracture of the orbital walls, or of the base of the skull, or from the penetration into the orbit of a foreign body, and it results in an atrophy of the nerve.

Tumors of the Optic Nerve.—Very few cases of tumors of the optic nerve are on record, and those reported have been of the fibroma, sarcoma, glioma and myxoma type.

SYMPTOMS.—There is simply a very slow, gradually increasing exophthalmos, with defective vision. The growths are usually very slow and painless, and the movements of the eye are generally unaffected. There is seen upon ophthalmoscopic examination symptoms of papillitis, the veins are engorged, the papilla œdematous and congested, and later there will be a shrinking of the vessels and white atrophy of the nerve.

TREATMENT.—Removal of the tumor is, of course, the only remedy. This should be done, if possible, without removal of the eyeball; but in most instances enucleation has been necessary. The nerve should be severed as far back as possible, so as to include the whole tumor.

As removal of a tumor of the optic nerve without enucleation of the eyeball has only been successfully made in a very few instances, the following successful operation made by Dr. Geo. S. Norton, and reported by the writer in the *Archives of Ophthalmology*, July, 1892, is worthy of record and is reported as taken from his case records:

“Miss J——, age 30, was first seen on Sept. 25th, 1890, and gave the following history: The right eye began to protrude ten or twelve years ago and has steadily increased ever since. For five years she had much sharp pain in the eye, extending to the back of the head and down to the stomach. Examination shows O. D. V. = $\frac{1}{200}$, O. S. V. = $\frac{1}{16}$, a protrusion of the right eye directly outward of twenty-two centimetres, which varies at different times, being greater on some days than others and greater during menstruation, and she says that the vision seems to be better when the eye is small. The ophthalmoscope showed the retinal vessels contracted and optic nerve atrophic. The movements of the eye were as good as could be expected from the amount of the protrusion. Is very nervous and would not allow of deep pressure to determine the nature of the growth.

“Oct. 7th.—Eyeball protrudes directly forward so that the posterior portion of the globe is just even with the outer border of the orbit. No pulsation could be detected. Patient very nervous, had a fainting spell with retching just before being put on the table for operation, but recovered after taking some whisky. Ether was given and well borne throughout the operation until after the tumor was removed, when the pulse became so much weakened that a hypo-

dermic of brandy was given. Palpation after she was under ether showed a soft, elastic tumor behind the eyeball and connected with it. Aspirating needle inserted at the outer canthus drew out a drop or two of serum. An incision was then made between the superior and internal recti muscles of sufficient size to permit of the finger being passed down to the tumor. Using the finger as a guide, the tissues around the tumor were severed, back to the optic foramen. The nerve was then divided at the optic foramen and afterward severed close to the eyeball. Tumor at once appeared at the opening and was removed. By rotating the eye the cut end of the nerve could be seen and it appeared clear and white. The socket was washed out with a 1 to 4,000 solution of the bichloride of mercury, the eyeball replaced and covered with the lid. There was but moderate hæmorrhage throughout, yet some infiltration of blood underneath the conjunctiva and into the lids was noticed, so that protrusion appeared about the same as before the operation; a compress bandage was applied, the ice-bag used locally and Acon. given.

"Oct. 21st.—The day after the operation the temperature was $99\frac{1}{2}$, pulse 102. The ice was used for three or four days. Patient has had no pain at any time. The eyeball protruded greatly for three or four days, caused by the infiltration of blood into the orbit and the lids, extending even to the other eye. There was quite extensive chemosis below, so that the conjunctiva protruded greatly, appearing between the lids. Upper lid greatly swollen, but covered the eyeball. This swelling gradually subsided, so that about the sixth or seventh day the lid retracted, leaving the eyeball exposed and the cornea became hazy. The eyelid was drawn over the eyeball and held in place by adhesive strips, which were kept on for four or five days. To-day there is still considerable haziness of the cornea, but it has diminished greatly. The eye has sunken back into the orbit nearly as much as the other eye. Eye is, however, nearly immovable, especially outward and inward, but stands somewhat outward. The conjunctiva still protrudes between the lids, but is diminishing, and with but slight discharge. No pain or unpleasant sensations.

"Nov. 20th.—Still some swelling at the inner canthus, moderate discharge, cornea a little hazy below, but clearing. Much better movements of the eye.

“Dec. 10th.—Optic disc very white, but from its centre are seen two small vessels running upward for about the distance of the diameter of the optic disc. There are also seen slight choroidal changes. Much less redness of the eye and movements much better.

“May 3, 1892.—Eighteen months after the operation there is little, if any, perceptible protrusion of one eye more than the other. The movements of the eye are a trifle limited in all directions, but the eye stands perfectly straight. An oblique illumination of the cornea shows a very slight opacity. The pupil is slightly dilated, but not as much as one year ago. In fact, the general external appearance of the eye is not noticeably different from the other, and the eye operated upon could only be told by a close examination. The ophthalmoscope shows the optic papilla to be of an extremely white, glistening appearance, with a faint line showing the position of the central vessels; at the upper part of the papilla there appears a leash of small vessels. There are some choroidal changes a short distance from the disc. The fundus appears normal and in the lower part of the field there is seen two good sized retinal vessels.”

CHAPTER XIV.

Amblyopia and Amaurosis.

UNDER this heading are classed all those conditions where there is either partial or complete loss of vision without any perceptible ocular lesions. The term *Amblyopia* is applied to those cases where there is but partial loss of vision, and *Amaurosis* where the loss of vision is complete. Formerly many cases of loss of vision from excessive use of alcohol and tobacco were classed under the heading of amblyopia, but in the advance of ophthalmological knowledge they have been found to be cases of inflammation of the optic nerve behind the eyeball and are now classed as cases of retro-bulbar neuritis. Hemianopsia, while also considered under this heading, perhaps should not be, because, while there is no perceptible lesion of the eye, the cause is known as due to some cerebral disease.

Congenital Amblyopia.—Imperfect vision in young children is quite frequently met with and is often associated with high degrees of hypermetropia and astigmatism. This condition will usually not excite attention until the child has entered into school life, and is probably due to the fact that, owing to the refractive error, distinct images have never been focused upon the retina. In many of these cases the vision will improve somewhat after the proper correction of the refractive error. If, however, the condition is not detected until adult life, no improvement is to be expected.

Other cases of what might be called congenital amblyopia are due to non-use of the visual function, owing to congenital opacities of the cornea or lens, from persistent pupillary membrane, or in cases of strabismus in early infancy. There is usually but one eye affected in these cases, and, when the vision is defective in both eyes, nystagmus is often present. Naumow¹ in an analysis of 47 cases of death of new-born infants, has found in 12 cases, retinal œdema, retinal hæmorrhages into the macula, choroidal hæmorrhages and the

¹ St. Petersburger Medicinische Wochenschrift, No. 3, 1889.

beginning of choked disc. These changes were found especially in those who suffered difficult and instrumental delivery, and he believes that congenital amblyopia has its origin in these changes, which are caused by stasis in the vessels of the head.

Traumatic Amblyopia may occur from any severe injury to the head, from concussion of the spine or from a direct blow upon the eye. In some of these cases there may be a fracture of the skull or a hæmorrhage along some part of the nerve, which is apt to produce a neuritis; and, having then inflammatory signs in the eye, should not come under the classification of amblyopia. The prognosis of these cases, while often favorable, should, as a rule, be guarded and dependent somewhat upon the severity of the injury.

Amblyopia from Lightning.—Cases of loss of vision from a stroke of lightning are usually accompanied by such lesions as burning of the skin, hair or cornea; ptosis is often present and cataract is apt to follow. In some cases there may be a neuro-retinitis, or, later, atrophy of the nerve. These cases often have a greater loss of vision than can be accounted for by the recognizable changes in the eye, and hence can only be considered in part an amblyopia.

Amblyopia from Loss of Blood.—Loss of sight may take place after severe hæmorrhage and may be accompanied by changes in the retina or nerve, yet in some cases may present no visible lesions. It has been seen after severe hæmorrhages from various organs, lungs, stomach, uterus, bladder, etc. Both eyes are usually affected in the large majority of cases and in nearly one-half the loss of sight is permanent. Temporary blindness may occur from loss of blood, and is due to the lack of blood supply to the visual centres or to the retina, and in these cases more or less complete recovery may be expected.

Toxic Amblyopia.—When due to alcohol, tobacco or lead, it has been found to produce an axial neuritis, and has already been referred to. Other drugs, such as quinine, salicylic acid, mercury, bisulphide of carbon and nitrate of silver, may produce loss of sight. Of these quinine amblyopia has been most frequently noticed; the patient, after a large or repeated doses, suddenly becomes both blind and deaf. The peripheral vision in these cases will often remain permanently affected, while the central vision will usually gradually return after a longer or shorter interval, in some cases requiring months. Oph-

thalmoscopic examination will often show pallor of the optic disc and diminution in the size and number of the retinal vessels. Other symptoms, such as contraction of the field of vision, loss of color perception and dilated pupils, may be noticed.

Hysterical Amblyopia.—Hysterical blindness is more frequently found in young girls and women. It is usually temporary and unaccompanied by other hysterical symptoms. The loss of vision is complete and but one eye is generally affected. There may be contraction of the field of vision, hemianopsia and color blindness resulting from hysteria, and we have seen other functional disturbances, such as ptosis, blepharospasmus and strabismus in hysterical subjects.

Pretended Amblyopia (*Malingering*).—The pretense of blindness is not infrequently met with, and, as a rule, these subjects only claim more or less complete blindness in one eye. Simulated blindness may be practiced for various reasons, the most frequent, perhaps, being in order to secure damages after some trivial injury, to excite sympathy, to secure pensions, etc. We have seen blindness claimed from the mere lodgment of a cinder in the cornea, which had been removed, leaving no trace of its location behind.

An exaggeration of an existing defect of the vision is often claimed. In all cases where the amaurosis is claimed to exist in both eyes, its detection becomes extremely difficult and may often only be proven by careful watching of the subject without his knowledge. The action of the pupils may give some clue; if dilated and immovable, the use of a mydriatic may be suspected, for in dilatation of the pupil in true blindness there may be some contraction from the stimulus of a bright light or upon convergence and there is apt, also, to be a shade more of dilatation when the eyes are in a shadow. By bringing an object suddenly before the eyes in assumed blindness there may be the natural closure of the lids to prevent injury to the eye. Where the loss of sight is claimed to be in but one eye, there are several tests that may expose the deception. The test by causing diplopia is perhaps the simplest. In this a prism of eight or ten degrees is placed before the sound eye with its base up or down, and if the person on looking at a lighted candle fifteen or twenty feet away acknowledges the double images, binocular vision is at once proven. Another test is made by using a strong convex

glass before one eye and a plane glass before the other to read the Snellen test type at twenty feet, and, by a reversible frame, make the person use unconsciously his bad eye. Again by paralyzing the accommodation of the good eye, or by placing a strong concave lens in front of this eye, and, if the patient can read, we know it is done with the affected eye. The stereoscope and various other methods are also useful in discovering an assumed blindness of one eye.

In all these tests caution should be taken that the patient does not suspect that you are trying to detect his dissembling. Rather let him infer that you are seeking to find the cause of his amaurosis.

Hemeralopia (*Night-blindness*).—This condition is found quite frequently without any recognizable lesions of the eye and must be considered as distinct from the night-blindness occurring as a symptom of retinitis pigmentosa and other lesions of the fundus. Hemeralopia is a functional complaint due to exposure to strong, brilliant lights, and is more prone to affect those whose systems have become greatly debilitated from the want of proper food. It prevails sometimes as endemic in certain countries, as in Russia, during their protracted fasts; it is frequently found in sailors, from exposure to tropical suns, and is often by them called “moon-blindness;” in soldiers, after prolonged marches; in travellers in the arctic zone and in those who work before furnaces.

Persons suffering from night-blindness are found to have good vision during daylight, but, upon the approach of dusk, or when going into a moderately darkened room, the vision becomes greatly impaired. The field of vision is normal and the fundus shows no lesion. The cause of the difficulty is probably a torpor of the retina, and, under favorable conditions, improvement may be expected.

TREATMENT.—As the general health is usually more or less impaired in hemeralopia, a generous diet must be ordered. Rest and protection of the eyes from bright light are first required; in severe cases it may be necessary to confine the patient to a dark room.

Lycopodium is the remedy most commonly needed in this disorder. Many cases have yielded promptly to its use.

Other remedies, as China, Hyos. and Ranunculus bulb. may be required.

Snow-blindness.—The dazzling of the snow may produce a con-

traction of the visual field, scotoma and night-blindness from torpor of the retina. (See retinitis nyctalopica.) In other cases it will cause intense photophobia, pain, blepharospasmus and result in an acute conjunctivitis, or sometimes an ulceration of the cornea.

Color Blindness.—Inability to discriminate colors is usually congenital, but may occur in diseases of the retina, optic nerve, brain or spinal cord, and consists of some impairment of the function of the retina. When not the result of disease, the subject's vision may be in every other respect perfect. He will simply be unable to detect certain colors, as red, green or blue, when partial, and, when complete, all colors will be indistinguishable, simply black and white being recognized. Complete color blindness is comparatively rare, but the partial loss of the color perception has been found to exist in about four per cent. of males and in about one-half per cent. in females. Red is the color for which blindness is most frequently present, while the varying shades of green are next most frequently lost.

The best test for color blindness is that made by Holmgren's wools, which consists in having the observer select from a heap of wools of various shades those that correspond to the one given him as a test object. There are three tests to be made. The first will detect all those who have any defect of color-vision, and the others show the nature of the defect.

In the first test, a skein of pure green, rather freely mixed with white, is used and the patient required to select all the corresponding shades of green. If he selects any of the confusion colors, viz.: grays, drabs, yellows, rose and salmon, or hesitates and shows doubt as to whether he should choose one, then he should be subjected to the second test. For the second test a bright shade of purple (rose) is taken as the test; the confusion colors are blues, violets, grays and greens. If the patient be *red-blind* he will choose the *blue* and *violet*, because purple, being composed of red and violet or blue, is to the red-blind identical with the two latter colors; while, if he be *gray-blind*, he will choose a *gray* and *bright green*. For the third test a bright red skein is selected, the confusion colors for this being the dark and light shades of green and brown or olive. The red-blind chooses a green and dark brown; while the green-blind selects a green or a lighter brown.

Hemianopsia (*Hemiopia*, *Hemianopia*).—Obscuration of one-half of the visual field almost always involves both eyes. The division is almost universally vertical, although cases have been reported in which the upper or lower half of the field has been lost. *Horizontal hemianopsia* may occur in diseases of the eye or possibly from some lesion causing pressure upon the lower or upper part of the optic nerve or chiasm, or downward upon one optic tract. *Vertical hemianopsia* may be of three varieties. The most frequent form is that of *homonymous hemianopsia*, in which the corresponding half of the field of each eye is wanting. Thus the right half of the field of each eye is lost, and is due to a loss of function in the left half of each retina and is called right homonymous lateral hemianopsia, and is *vice versa* when the left half of the field of each eye is wanting.

Bitemporal hemianopsia is where the external or temporal half of the field of each eye is blind.

Binasal hemianopsia is where both nasal fields are wanting and is the most rare form of vertical hemianopsia. In the two last forms of heteronymous hemianopsia the dividing line is apt to be irregular, while in the homonymous cases the line of division is usually distinct and vertical.

Monocular hemianopsia may occur from a lesion of one optic nerve in front of the chiasm and, as a rule, has an irregular boundary line.

Hemiachromatopsia is where the color sense in corresponding halves of each eye becomes lost. This is an extremely rare condition and but very few uncomplicated cases are on record. The lesion is probably in the cortex.

SYMPTOMS.—In a defect of the light sense in homonymous portions of the field there is a corresponding defect in the form and color sense. When the light sense is intact, in cases of homonymous defect for form, there is an equal defect for colors. Wilbrand¹ concludes that the centre for form lies between the centres for color and light sense and that the centre for color occupies the most central position in the brain. When the hemianopsia is partial the defect is usually of an equal extent in both eyes. The reaction of the pupil in hemianopsia is always a valuable diagnostic sign, and the examination of the pupil should be made in a dark room, the eye

¹ Hemianopsia. Berlin. 1881.

illuminated with a weak light, while an intense light is thrown obliquely in various directions into the pupil. According to Wernicke, if, in hemianopsia, the light thus thrown upon both the seeing and blind sides of the retina causes contraction, the lesion is back of the primary optic centres. If there is contraction when the light falls upon the seeing side of the retina and none when it falls upon the blind side, the lesion is either in or in front of the primary optic centres. Peripheral contraction of the field that remains in hemianopsia indicates some additional complication. Pressure on the insensitive sides of the eye will not cause phosphenes. Ophthalmoscopic examination shows no lesion, except in the later stages of the disease, when there is sometimes a paleness of the papilla.

Mauthner says in right homonymous hemianopsia the right optic nerve will appear atrophic, while the left remains normal. Blindness of the right side of the field causes more trouble in reading than when the left side is gone. Central vision may be either perfect or impaired.

CAUSES.—Homonymous lateral hemianopsia results from intracranial and generally cerebral disease, which may be either tumors, hæmorrhage, embolisms, injuries, softening, etc. The seat of the lesion may be in any part of the visual tract between the eyeball and the cortex of the brain. The following set of rules as preliminary to diagnostic laws in hemianopsia are taken from a most valuable paper on "A Contribution to the Pathology of Hemianopsia of Central Origin (Cortex Hemianopsia)," by Seguin:¹

"1. Lateral hemianopsia always indicates an intracranial lesion on the opposite side from the dark fields.

"2. Lateral hemianopsia, with pupillary immobility, optic neuritis or atrophy, especially if joined with symptoms of basal disease, is due to lesion of one optic tract or of the primary optic centres on one side.

"3. Lateral hemianopsia, or sector-like defects of the same geometric order, with hemianæsthesia and choreiform or ataxic movements of one-half of the body without marked hemiplegia, is probably due to lesion of the caudo-lateral part of the thalamus, or of the caudal division of the internal capsule.

"4. Lateral hemianopsia, with complete hemiplegia (spastic after

¹ Journal of Nervous and Mental Diseases, January, 1886.

a few weeks) and hemianæsthesia, is probably caused by an extensive lesion of the internal capsule in its knee and caudal parts.

" 5. Lateral hemianopsia, with typical hemiplegia (spastic after a

FIG. 42.

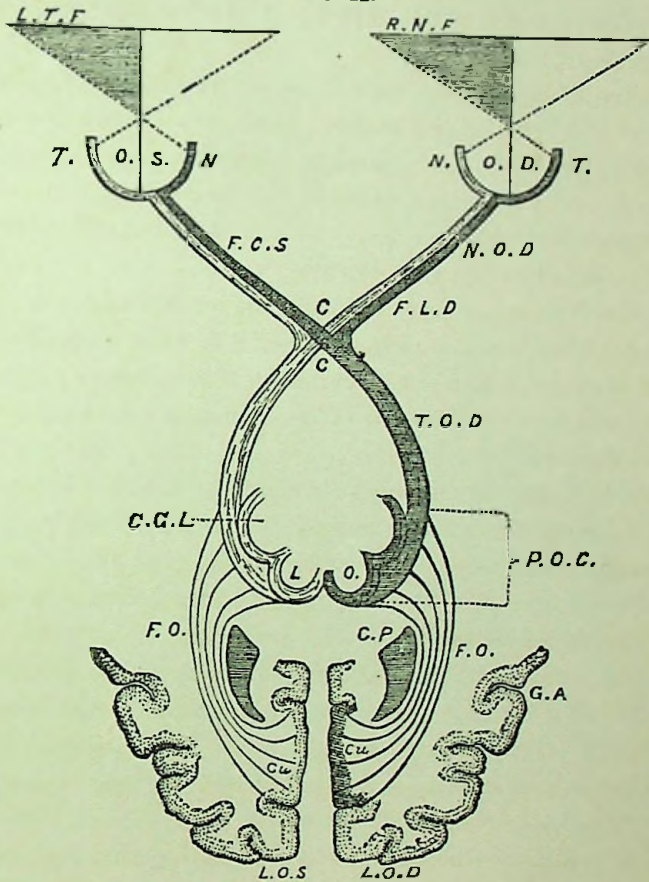


Diagram illustrating the visual path and its relation to the visual field, left lateral hemianopsia being shown (Seguin). L.T.F., left temporal half-field; R.N.F., right nasal half-field; O.S., oculus sin.; O.D., oculus dexter; N.T., nasal and temporal halves of retina; N.O.S., nervus opticus sin.; N.O.D., nervus opticus dext.; F.C.S., fasciculus cruciatus sin.; F.L.D., fasciculus lateralis dext.; C., chiasma, or decussation of fasciculi cruciati; T.O.D., tractus opticus dext.; C.G.L., corpus geniculatum laterale; L.O., lobi optici (corpus quad.); P.O.C., primary optic centres, including lobus opticus, corp. genic., lat., and pulvinar of one side; F.O., fasciculus opticus (Gratiolet) in the internal capsule; C.P., cornu posterior; G.A., region of gyrus angularis; L.O.S., lobus occip. sin.; L.O.D., lobus occip. dext.; Cu., cuneus and subjacent gyri constituting the cortical visual centre in man. The heavy or shaded lines represent parts connected with the right halves of both retinae.

few weeks), aphasia if the right side be paralyzed and with little or no anæsthesia, is quite certainly due to an extensive superficial

lesion in the area supplied by the middle cerebral artery; we would expect to find softening of the motor zone and of the gyri lying at the extremity of the fissure of Sylvius, viz.: The inferior parietal lobule, supra-marginal gyrus and the gyrus angularis. Embolism or thrombosis of the Sylvian artery would be the most likely pathological cause of the softening.

“6. Lateral hemianopsia, with moderate loss of power in one-half of the body, especially if associated with impairment of muscular sense, would probably be due to a lesion of the inferior parietal lobule and gyrus angularis, with their subjacent white substance penetrating deeply enough to sever or compress the optic fasciculus on its way caudad to the visual centre.

“7. Lateral hemianopsia, without motor or common sensory symptoms. This symptom alone is due, I believe, to lesion of the cuneus only, or of it and the gray matter immediately surrounding it on the nasal surface of the occipital lobe in the hemisphere opposite to the dark half fields. Most surgical cases come at once, or after convalescence, within this rule or in No. 6.

“In all cases coming under rules 3 to 7 inclusive the pupils react normally, and rarely does the ophthalmoscope show any lesion of the optic nerve, except, of course, in some tumor cases, when neuroretinitis may be expected.”

As to the nature of the lesion, the diagnosis must depend upon the history, nature of the attack and concomitant symptoms; but in all cases of cerebral disease, especially where the ophthalmoscope reveals no lesion, the visual field should be examined.

PROGNOSIS.—Restoration of the visual fields is rare, but, when it does occur, it is apt to be symmetrical in both eyes. If both hemiplegia and hemianæsthesia are present, the former may disappear and the latter remain. The hemianopsia is usually but one of other cerebral symptoms which may end in death. Nasal homonymous hemianopsia generally affords a better prognosis than temporal.

TREATMENT.—Half vision is usually only a symptom of some deep disorder of the eye, but as it is sometimes the only symptom to be found those remedies appropriate to it will be mentioned:

Upper half of visual field defective: *Aurum*, *Dig.* and *Gels.*

Right half of visual field defective: *Cyclamen*, *Lith. carb.* and *Lyc.*

Vertical hemiopia, either half invisible: *Calc. carb.*, *Chin. sulph.*, *Mur ac.*, *Nat mur.*, *Rhus*, *Sep.* and *Stram.*

CHAPTER XV.

Diseases of the Vitreous Body.

Anatomy.—The vitreous humor is the transparent, jelly-like structure occupying the space between the lens and the retina. The vitreous has somewhat of a depression on its anterior surface called the *lenticula fossa* in which rests the crystalline lens, and to the posterior capsule of which the vitreous is attached, while behind, it is adherent to the optic nerve. The presence of a *hyaloid membrane* inclosing the vitreous is claimed by some authorities; but, according to others, the so-called hyaloid is identical with the internal limiting membrane of the retina, which, according to Lieberkuehn, from the developmental standpoint, belongs to the vitreous. The structure of the vitreous has not with certainty been determined. It is claimed that it can be split into concentric layers and various forms of cells have been found in it. These cells are toward the centre roundish in shape and more stellate or fusiform toward the peripheral layers of the vitreous. Chemically the vitreous is 98 per cent. water, with salts, extractive matter and a trace of albumin. Its consistency becomes less as age advances and in adult life is slightly more tenacious than the white of an egg. Its index of refraction is identical with that of the aqueous humor. A canal of about 2 mm. in diameter runs through the vitreous from the optic nerve to the centre of the posterior capsule of the lens, and during foetal life it contains the hyaloid artery. The vitreous contains neither blood vessels or nerves, and yet, on account of its cells, it must be considered an organized structure.

Hyalitis Suppurativa.—Purulent inflammation of the vitreous may occur when a foreign body has penetrated into it, or it may be the result of an extension of some other inflammation of the eye and generally from an inflammation of the retina, choroid or ciliary body. It is now generally accepted that a primary hyalitis may occur and manifest itself either as an opacity or it may go on to

suppuration. Pus may be found in the vitreous in some infectious blood diseases, and is due to exhaustion and debility. After cataract extraction or the removal of a staphyloma, suppuration has sometimes been noticed as beginning in the prolapsed vitreous. A shining, cheesy mass of a tubercular character was once found in the centre of the vitreous by Deutschmann in an eye which presented no other tubercular affection. The evidence, therefore, seems to indicate that primary or spontaneous inflammation of the vitreous may occur.

SYMPTOMS.—There may be bulging of the pupillary border of the iris and retraction of its periphery. Posterior synechiæ are usually present and the tension is diminished. Together with the inflammation of the iris and ciliary body there is more or less pericorneal injection. Ophthalmoscopic examination will show a light yellowish reflex from the fundus, and, when the pus is circumscribed, the appearance resembles very closely a glioma of the retina and is sometimes called *pseudo-glioma*. It is distinguished from true glioma by the history, the appearance of the iris and the symptoms of iritis and by the diminished tension.

COURSE.—Suppuration of the vitreous usually results in destruction of the eye. It generally becomes complicated with choroiditis and often extends to a general inflammation of the eye or panophthalmitis. If the active process continues, the eyeball ruptures and atrophy follows. Less severe inflammatory conditions of the vitreous, resulting in opacities and more or less destruction of vision, may occur and, when it does, it is usually an extension from inflammation of other structures.

TREATMENT.—Hyalitis rarely occurs idiopathically, being usually associated with severe inflammations of the fundus, especially inflammation of the whole or part of the uveal tract. The treatment must then be directed to the primary disease. Particularly study the remedies recommended for choroiditis. Traumatic inflammation of the vitreous humor is more frequently observed, especially from a foreign body, which usually necessitates the removal of the eye.

When occurring in cases of great debility from low fevers and if seen in its earlier stages a stimulating, nourishing treatment may save the eye; but, as a rule, when pus has once formed in the vitreous the eye cannot be saved and enucleation is demanded.

Opacitates Vitrei (*Myodesopsia, Muscæ Volitantes, Synchysis, Synchysis Scintillans*).—Opacities in the vitreous may vary greatly in form and size from a mere diffuse dust-like haziness, to large membranous patches or strings. Their color may also vary from a gray to a decided black and they may be either fixed or floating in the vitreous. The diffuse opacities are often so transparent that they will simply appear to hide the retina as through a thin veil or fine dust, and this form of opacity generally occurs in syphilitic retinitis or choroiditis. In other cases there will be such intense opacities of the vitreous as to obscure all reflex from the fundus, and the diagnosis is made by exclusion, by oblique illumination the presence of any opacity of the cornea, anterior chamber or lens. If this condition results from a hæmorrhage, there may sometimes be seen on the posterior surface of the lens a red appearance from particles of blood which have become attached to the lens capsule. Membranous opacities may often be seen adherent by one or more points to the retina, choroid or disc.

SYMPTOMS.—The subjective symptoms depend upon the amount and density of the opacities. Thick, circumscribed opacities cause less impairment of vision than do thin and transparent but diffuse ones. Vision, therefore, may be not at all affected or wholly lost, but, in case of floating opacities varies according as the opacity is in the line of vision or not. Patients describe the appearance as gray or black spots of different sizes and shapes and often are able to draw pictures of their appearance.

Opacities of the vitreous are best determined by an examination with the direct method at the distance of about thirty centimetres and, as the patient moves the eye upward and downward dark spots or streaks are brought into view in the red reflex of the fundus. The movement of the eye may have to be continued for some time before the opacity comes into view. The rapidity of the movement of the opacity increases in proportion to the fluidity of the vitreous and the movement continues after movement of the eye ceases. Vitreous opacities move in an opposite direction to the movement of the eye, while opacities of the lens or cornea move with the movement of the eye, and cease as soon as the eye comes to rest. Opacity of the cornea or lens can be recognized by an oblique illumination.

COURSE.—Diffuse opacities may entirely clear up, or they may

become aggregated into thick, circumscribed shreds, while the remainder of the mass becomes more transparent. The thick, circumscribed opacities may be somewhat absorbed but more slowly and obstinately.

CAUSES.—Opacities are especially found in myopes, with posterior staphyloma and choroidal changes. They are frequently due to some inflammation of the ciliary body, choroid or retina, or from an injury of the eye which has caused a hæmorrhage into the vitreous. They have also in many instances been due to various general conditions, such as exhaustion after severe constitutional diseases, in anæmia, menstrual disturbances, syphilis, constipation, etc., and have frequently been seen where no cause can be given for their origin.

In *muscæ volitantes* or *myodesopsia* there is no true opacity of the vitreous, and the black spots complained of by patients as floating before the eye when looking at a bright surface are due to shadows upon the retina produced by some normal elements in the vitreous or from small particles of secretions or tears moving over the cornea. In these cases there is no interference with vision and the ophthalmoscope shows no opacity. They will frequently cause great annoyance, especially in nervous individuals, and are generally attributed by the laity to biliousness or indigestion.

Synchisis is a fluidity of the vitreous and can only be diagnosticated by the rapid movements of opacities in the vitreous during motions of the eye. The tension of the eye may be somewhat diminished, and it is more often found in elderly people with staphyloma or choroidal disease. Synchisis, when present in cataract cases, may complicate the extraction by loss of vitreous.

Synchisis Scintillans is where the fluid vitreous contains numerous scales of cholesterin. When seen it presents, with the ophthalmoscope, a beautiful appearance, as of a shower of brilliant crystals. This condition seems to be associated usually with choroiditis, although it may be seen in eyes presenting no evidence of other disease.

TREATMENT.—Dense membranous opacities may be torn with a fine needle, though operative measures are not usually required. If the opacity has been recent, especially if hæmorrhagic, a compress bandage should be applied and the patient kept in bed.

If there has been hæmorrhage into the vitreous humor, their absorption may be hastened by Arnica, Bell., Crotal., Ham. virg., Lach., Ledum or Phos. If the opacities are the result of inflammation of the choroid or retina, benefit has been derived from the following: Arg. nit., Aurum, Bell., Gels., Jab., *Kali iod.*, Kali mur., Kalmia, Lach., Lyco., Merc., *Nat mur.*, Phos., Prunus, Sen., Sil. and Sulph.

Hæmorrhage into the Vitreous.—Usually occurs from the vessels of the choroid, retina or ciliary body, and generally results from an injury, such as a blow or wound of the eye or concussion of the skull. The hæmorrhage may be partial or entirely fill the vitreous, being so dense as to wholly obscure the red reflex of the fundus, and then may often be seen as a dark red mass by the oblique illumination. There is partial or total blindness, which may have come on gradually or suddenly. Spontaneous hæmorrhage into the vitreous and retina have been seen to occur. The hæmorrhages will often be wholly or partially absorbed in the course of a few weeks, but more frequently floating opacities remain behind.

Foreign Bodies in the Vitreous.—Usually in injury the foreign body will become lodged in the coats of the eye, although it may penetrate into the vitreous. It most generally passes in through the cornea, wounding the iris and lens, or lens alone, and more often becomes lodged either in the iris or lens. In some cases the foreign body will penetrate by the way of the sclera, in which it may be lodged. It may drop into the vitreous, or, passing through the vitreous, become lodged in the coats of the eye at the opposite side, or, penetrating these, may become embedded in the tissues of the orbit. A foreign body within the vitreous usually becomes within a few hours surrounded by a cloudy opacity which may become organized, forming a cyst wall around it, but as a rule, instead of becoming encysted, it will result in inflammation, which may lead to abscess, or, remaining localized, result in detachment of the retina; or, by an extension of the inflammation, cause panophthalmitis.

In some cases the foreign body will remain visible in the vitreous for some time without becoming fixed or encysted, and may lead, when in this condition, to either glaucoma or sympathetic ophthalmia. The entrance of the foreign body is usually accompanied by hæmorrhage from the choroidal vessels. The most frequent foreign

bodies are chips of iron, steel, glass and shot—the latter are always more favorable than are other foreign substances. In diagnosing foreign bodies in the vitreous, the history of the injury will be the first clue. We may then find a corneal wound or scar, with evidences of injury of the iris or lens, by the ophthalmoscope. If there is not too great haziness of the lens or vitreous, we may often see the foreign body itself, which appears, if a piece of iron or steel, of a bluish or greenish white color with a glistening border.

TREATMENT.—Removal of the foreign body by means of the electro-magnet has been successfully done in many cases. The magnet is, of course, only applicable to particles of iron or steel, yet, as these substances form the large majority of cases, its use has been the means of saving many eyes that, previous to its employment, would have been lost. If seen shortly after the injury, before the wound is closed, the opening, if in the sclera, is somewhat enlarged, so that the substance will not be brushed off when the magnet is withdrawn. The needle of the magnet is then introduced through the wound to as near the foreign body as possible. When the substance can be located by the ophthalmoscope the needle can be passed directly to it. If, however, it cannot be seen, the appearance of the wound will often indicate the direction to be followed and a certain amount of exploratory excursions is permissible. If the penetration has been through the cornea and lens, the lens should first be removed and the needle inserted through the corneal opening. After the wound has closed, if the substance can be discerned with the ophthalmoscope, an opening may be made in the sclera by means of a meridional cut through the equatorial part of the sclera and the magnet used. If, however, the substance cannot be discerned, it is better to delay opening the sclera until the eye gives evidences of well developed inflammatory symptoms, as in rare instances it becomes encapsulated and may be allowed to remain, if the patient is made to thoroughly understand the importance of an immediate enucleation of the eye upon the first evidence of sympathetic irritation. Failing in the attempt to remove the foreign body, if the injury has been sufficient to destroy vision, enucleation or evisceration may be employed at once.

The inflammation arising from injuries must be subdued by ice

compresses, the instillation of Atropine, and proper internal medication. The remedies will usually be *Acon.*, *Arn.*, *Calend.*, *Ham.*, *Led.* or *Rhus.*

Cysticercus in the Vitreous.—The presence of a parasite in the eye is of extremely rare occurrence in this country, but is quite frequently met with in North Germany. Its origin is between the choroid and retina. It causes detachment of the retina, and finally perforates it, enters the vitreous and sooner or later causes an iridocyclitis, with inflammatory changes which end in destruction of the eye. The treatment is to remove the cysticercus.

Persistent Hyaloid Artery.—The hyaloid artery is an extension from the central artery of the retina which in the embryo passes through the central canal, already referred to, and furnishes the nourishment of the lens. Obliteration of this artery is usually complete before the termination of foetal life, but sometimes it fails and some vestige of the artery remains. With the ophthalmoscope a somewhat tortuous cord may be seen, which may extend from the disc forward to the lens or merely as a rudimentary strand attached either to the disc or lens and in some instances it has been seen to contain blood. This condition is often found associated with persistent pupillary membrane or other foetal abnormalities. The vision is generally somewhat affected.

Detachment of the Vitreous.—The vitreous may become detached from the retina by traumatism, or hæmorrhages, as a result of exudation in choroiditis and from intraocular growths. It is always of serious import from its tendency, by dragging upon the retina, to cause a detachment of that membrane. It is considered by some authorities to be a forerunner of nearly all detachments of the retina. Galezowski diagnosed detachment by a semicircular gray rim at the border of the optic disc, but there appears to be no constant signs by which it can be diagnosed with certainty.

CHAPTER XVI.

Diseases of the Crystalline Lens.

Anatomy.—The crystalline lens is a transparent, bi-convex, solid body that is inclosed in a transparent capsule and rests just behind the iris in a depression in the vitreous humor. The measurements of the lens at different periods of life were most carefully made by Priestley Smith,¹ who examined one hundred and fifty-six lenses and found the diameters to vary from 8.25 mm. to 10 mm. The antero-posterior diameter was not systematically measured, but he believes that the measurement of 3.7 mm. attributed to this axis of the lens in the schematic eye is too small even for the young adult, and that in elderly people he has found the axial thickness of the lens to be as high as 6.5 mm. His experiments also show that the healthy lens increases in weight and volume throughout the whole of life, adding from the twenty-fifth to the sixty-fifth year of life one-third to its weight, one-third to its volume and one-tenth to its diameters. Lenses which are becoming cataractous are as a rule smaller than healthy lenses. The lens in the young is perfectly colorless, but becomes yellowish later in life, at the same time it becomes flatter and less elastic. The shape of the lens is, therefore, more globular in early life, and, from its greater elasticity at this period, it has a greater amplitude of accommodation.

The substance of the lens is made up of long fibres or cells and an interstitial cementing substance. The fibres are band-like structures having an oval nucleus and are arranged in concentric lamellæ, each lamella consisting of a single layer of fibres. Each lens fibre runs from the anterior to the posterior surface in a meridional direction, the ends meeting at the poles of the lens in such a manner as to form a stellate figure. The result of this arrangement is to divide the mass into sectors. The fibres toward the centre of the lens are more compressed than the peripheral ones, and hence the

¹ Trans. Ophthal. Soc., vol. iii., 1883.

centre of the lens is spoken of as the nucleus and the more peripheral portion as the cortex. The refractive index of the lamellæ increases from the periphery toward the centre. In the young the superficial fibres have about the same index of refraction as the aqueous; but, as the refracting power increases with age, the difference causes an abrupt change which creates a reflection of light from the surface of the lens in old people and causes the grayish or semi-opaque appearance of the pupil so frequently seen in the aged.

The capsule of the lens is a highly elastic homogeneous membrane, thicker in front than behind. The anterior capsule is lined with a single layer of transparent, hexagonal cells which are supposed to govern the nutrition of the lens. The posterior capsule has no epithelial lining, but is in close contact with both the substance of the lens and the vitreous.

The lens is held in position by the *zonule of Zinn* or suspensory ligament of the lens, which is a continuation of the *membrana limitans* of the retina. This membrane is firmly attached to the ciliary processes, and, as it passes to the border of the lens, divides into two layers, to be inserted into both the anterior and posterior capsule. The small space left by the separation of this membrane is called the canal of Petit and is supposed by some to convey the nourishment to the lens. The function of the *zonule of Zinn* is probably to maintain the lens *in situ* and to control its accommodative changes.

Cataract.—Opacity may occur in the lens or its capsule, or both.

PATHOLOGY.—The changes that take place in the lens in cataract are those of degeneration and may best be considered under the classifications of hard and soft. Hard cataract is so called on account of the sclerosis that occurs in the nucleus, the fibres of the nucleus becoming more closely packed together and difficult to separate from each other.

The cortical fibres become swollen, granular and disintegrated—the spaces between the fibres containing coagulated masses. The haziness of the lens is due principally to the alteration in the cortical layers, although the primary cause is in the irregular shrinkage of the nuclear fibres, and it is this want of uniformity in the process of hardening of the nucleus which is supposed to cause the altera-

tions occurring in the cortical layers. In its incipency the lens swells by increase of fluid, and in the very late stages further degeneration occurs in the cortex, resulting in a semi-fluid molecular substance in which is found the hardened nucleus. This condition is called over ripe or Morgagnian cataract.

In soft cataract the fibres are swollen and varicose; they become degenerated and destroyed. There is an increased amount of fluid, the fibres containing molecules and *débris* of fat are thrown off between the fibres. The traumatic cataract is due to an injury, causing a rupture in the capsule, allowing the entrance of the aqueous, which causes a swelling and disintegration of the lens fibres. Kamocki¹ describes the pathological changes in the lens in diabetes as follows. Commencing with proliferation of the intracapsular cells, together with the formation of vesicle cells, and, finally, the absorption of water by the lens nucleus, with resulting loosening of its fibres, and drops of water forming in the spaces made by this separation of its fibres.

SYMPTOMS.—There is a slowly progressing dimness of vision which causes some obscuration of distant objects and, from the swelling of the lens, increases the refraction of the eye so that the tendency is to bring near objects closer to the eye and in some cases is sufficient to cause myopia of a low degree. Many instances where people have been said to have got their “second sight” have been occasioned by the swelling of the lens in cataract. The opacity in the lens will also often produce astigmatism or alter an already existing irregularity. The extent of the loss of vision will depend upon the situation and extent of the opacity and will be different in different cases; some will be greatly affected by the presence of a few striæ, while in others we are often surprised at the acuity of vision that will be possessed by an eye in which the fundus will be almost obscured by the numerous striæ. Photophobia and phosphenes are sometimes complained of and in some cases pain and asthenopic symptoms will be experienced on attempting to use the eyes. There is occasionally from the strain on using the eyes slight conjunctival hyperæmia. In ripe cataract the pupil will appear gray or white in color, excepting in some cases of so-called “black cataract,” when it will appear dark; the pupil may also be small

¹ *Archiv. Ophthal.*, vol. xvii., 1, 1888.

and sluggish. The anterior chamber is sometimes a little shallow from swelling of the lens.

The use of the ophthalmoscope, together with the oblique illumination, renders the diagnosis of cataract not at all difficult. Dilatation of the pupil either with homatropine or preferably cocaine renders the examination more thorough. With the oblique illumination the opacity, if immature, appears as white or gray streaks or dots. The ophthalmoscope is used by the direct method and with a weak illumination. The patient is then made to look in all directions so as to bring all parts of the periphery into view. The most frequently seen opacities in cataracts are in the form of streaks or spiculæ running from the periphery toward the centre of the lens, and which appear black with the ophthalmoscope. Particles may be seen in any part of the lens and the remainder of the lens be perfectly transparent. Thus the nucleus may be involved and the periphery clear, or the periphery may be affected all around or at one spot and the nucleus and balance of the lens remain clear. If the opacity involves the whole substance of the lens, there will be no red reflex from the fundus. In some cases the undilated pupil will give no reflex, but, upon using some mydriatic, the periphery of the lens will give the reflex, showing that the cataract is still immature and that the extreme periphery has not become entirely opaque.

COURSE.—Simple senile cataract, as a rule, follows a progressively increasing course from incipency to full maturity; but, according to some authorities, an immature cataract may in some cases remain stationary for many years. The period of time required for the development of mature cataract from its incipency is most variable, as in some cases the cataract will progress rapidly and blindness ensue within a few months, while others will go on for several years before the cataract will become fully matured. Some idea of the rapidity of the progress may be formed in the striated variety of the cataract from the appearance of the striæ, as the thin, narrow striæ are of much slower course than are the broad and thick striæ. Opacities occurring as dark, flocculent masses usually advance more rapidly than do those commencing as striæ. Opacities showing both the striæ of the cortex and the haziness of the nucleus as well are spoken of as mixed cataracts and are usually more rapid in their progress. After reaching maturity the cataract may proceed to the condition

of "over-ripeness" or Morgagnian cataract, in which the cortical substance becomes liquified and the nucleus displaced. Other changes sometimes met with in over matured cataracts are calcareous and fatty degenerations of either the lens or its capsule. Spontaneous absorption may take place in diabetic cataracts, and has been reported as occurring in the ordinary senile cataract.

The course above described refers to the ordinary senile or hard cataract, occurring in individuals upward of thirty-five years of age. All cataracts occurring under this age are of the soft variety, the course of which will be referred to later on under the different varieties of cataract.

CAUSES.—Schoen¹ in a paper upon "The Cause of Senile Cataract," draws the following conclusions from an examination of 4,030 eyes, of all ages, in which he found cataract in 441 eyes:

"1. The process heretofore distinguished as senile cataract begins always as equatorial cataract, with fine white dots and streaks.

"2. Nuclear sclerosis never appears without equatorial cataract. On the other hand, the statistics show 377 eyes with equatorial cataract without nuclear sclerosis. The latter is without doubt secondary.

"3. Nuclear sclerosis is associated with equatorial cataract first after the ages of sixty (two cases) and seventy (twelve cases).

"4. More than one-half (60 per cent.) of the patients with cataract have still normal acuteness of vision, wherefore changes in the centre of the lens may be excluded.

"5. Anterior cortical cataract is rarely associated with equatorial cataract before the age of fifty.

"6. Cataracta simplex is not peculiar to old age, but frequently occurs in its incipency in young people from twenty to thirty years of age. The designation 'senile' should, therefore, be dropped and 'simplex' be employed in its place.

"7. Three-fourths of the total number of cataractous eyes are hypermetropic or astigmatic.

"8. Equatorial cataract begins chiefly in the horizontal meridian.

"9. The macroscopic dots and stripes correspond to the insertion of the anterior and middle zonular fibres.

"10. The microscopical changes likewise are arranged around the base of these fibres."

¹ Archiv Ophthal., vol. xviii., 3, 1889.

Sugar in the urine has been found in about one per cent. of cataract cases. The urine should, therefore, always be examined in cataract cases, and especially when cataract is met with in young persons. Albumin has also been found in the urine in cataract cases. Cataract has been seen in persons suffering from epilepsy and other convulsions, also after meningitis, cutaneous diseases, etc. It is also frequently found in those working in excessive heat and light, as in glass-blowers. Heredity appears to bear a very important relation to its occurrence, as examples of its transmission have frequently been reported.

In countries subject to epidemics of ergotism cataract has been frequently found associated with it. Animals poisoned with Naphthalin have developed cataract. Cataract is often secondary to inflammatory affections of the eye, especially of the iris, ciliary body and choroid, in glaucoma and detachment of the retina. Traumatism is also a frequent cause, and may be either from a direct injury of the lens or from concussion.

Varieties of Cataract.—The description already given may be considered as applying in a general way to all forms of cataract, the most typical type of which is the simple or senile cataract. The classification of cataracts met with in different works is most confusing, as by different authorities they will be classed according to their anatomical location, their consistency, their color, whether primary or secondary, partial or complete, senile or congenital, etc. The following table, taken from De Schweinitz¹ gives a *résumé* of the various classifications :

Anatomically	{	1. Lenticular.	
		2. Capsular.	
		3. Capsulo-lenticular.	
	{	1. Senile {	(a.) Cortical } General.
		(b.) Nuclear }	
	{	2. Juvenile or congenital {	(a.) Complete { Complete.
		(b.) Partial {	Congenital
			Lamellar, or zonular.
			Pyramidal, or polar.
Clinically	{	3. Complicated or secondary {	Anterior polar cataract.
		(b.) Partial {	Posterior polar cataract.
			Complete cataract.
		4. Traumatic.	
		5. After cataract.	

¹ Diseases of the Eye, 1892, p. 386.

The clinical classifications are perhaps most frequently employed, and as the description already given applies to the first clinical subdivision, *i.e.*, senile cataract, we will refer briefly to some of the other varieties.

Complete Congenital Cataract involves all the layers of the lens and is a rare form of cataract. In this the lens is soft, densely opaque and either of a white or bluish-white color. There is also often an opacity of the capsule as well, and this form of cataract is apt, in course of time, to undergo degeneration, becoming shrivelled up, membranous or calcareous. There may be a dislocation of the lens from degenerative changes of the zonule of Zinn.

The cause of this variety of cataract has been variously attributed to heredity and disturbances of nutrition in intra-uterine life. The treatment before degenerative changes have set in is by discission. If, however, it has become calcareous or membranous, extraction should be made as in senile cataract.

Cataracta Lamellaris or **Cataracta Zonularis** is a congenital opacity involving only a portion of the lens, and, as its name implies, affects one or more lamellæ, forming an opaque layer surrounding the clear nucleus of the lens. Microscopical examination of this form of cataract has but rarely been made, and hence the description given by Beselin¹ is of much value. He concludes, "that a chemical alteration in the subsequent nucleus, brought about by a change in the nutrition of the part, attending rhachitis, is the primary factor. This change is followed by a general contraction of the affected part, which causes the formation of fissures between this part and the normally developed, unaffected, cortical layers of lens substance. A granular deposit takes place in the tissue plasma collected in the fissures and at the same time the neighboring lens fibres take on a form of granular degeneration. In the majority of cases lamellar cataract is present in both eyes, although it does occur in but one."

The vision is more or less affected, depending upon the density of the opacity and the amount of lens involved. The patients hold objects very close to the eyes and are commonly thought to be near-sighted, and true myopia may exist. With the ophthalmoscope there is seen a sharply defined opacity in the axis of the lens which is generally circular and more or less dense; the periphery of the lens is

¹ Archiv. Ophthal., vol. xvii., 3, 1888.

usually perfectly clear, although other dots of opacity may be seen here and there in the transparent portion. A history of convulsions, as pointed out by Arlt, is frequently found in these cases. In addition to rickets, scrofula or hereditary syphilis is often determinable as a constitutional cause and is frequently evidenced by an examination of the teeth, which appear irregular, notched and broken. Lamellar cataract, as a rule, remains stationary, though not invariably so.

The treatment of this form of cataract is usually by iridectomy, which should be made when, upon dilatation of the pupil, with the refractive error, if any, corrected, the vision is improved, as by displacing the pupil the transparent portion of the lens is used and clearer vision results. Dissection or removal of the lens may be made when the vision is less than one-third of the normal and there seems no likelihood of improving the vision by an iridectomy.

Cataracta Polaris Anterior or **Cataracta Pyramidalis** may be simply a minute white dot upon the capsule of the lens, or a larger, dense, chalky-white, circular patch involving both the capsule and the substance of the lens for a short distance immediately beneath. It often seems to stand out in front in a pyramidal form. The condition is sometimes congenital, and, if so, usually in both eyes. In these cases it may be the result of imperfect closure of the capsule, or possibly from the remains of the pupillary membrane. More frequently, however, the opacity occurs after birth from a central perforating ulcer of the cornea, as in ophthalmia neonatorum; the lens is thrown forward in contact with the cornea upon escape of the aqueous, a plug of lymph is thrown out, closing up the perforation, and as the aqueous re-forms the lens is pressed back, carrying with it a little mass of lymph attached to its capsule. In these cases a central opacity of the cornea may frequently be seen by the oblique illumination. This form of cataract is always stationary.

Cataracta Polaris Posticum is the term applied to an opacity of the posterior pole of the lens or its capsule. In its congenital form it is due to some remains or imperfect absorption of the hyaloid artery. When acquired it is usually the result of a disease of the choroid, vitreous or retina causing malnutrition. Opacities in the vitreous are usually determinable, and often lesions of the fundus may be discovered with the ophthalmoscope. The opacity is seen

to move but very slightly upon movement of the eye because of its position at about the centre of rotation. The opacity in itself does not cause a very great loss of vision, but the patients see poorly on account of the lesions further back. This form of opacity may remain stationary for a long time, but in the end the lens usually grows more opaque.

Cataracta Traumatica is an opacity of the lens due to injury and as a rule the whole substance of the lens becomes opaque. The traumatism may be a direct injury to the capsule of the lens, as in penetrating substances, which, by lacerating the capsule, permits the aqueous to come into contact with the substance of the lens, causing it to swell and become opaque. Absorption sometimes follows within a few weeks after the injury without other serious results, but in other cases the swelling of the lens will set up either glaucoma, iritis or cyclitis. A blow upon the eye may also cause an opacity of the lens by the force of the concussion, rupturing either the anterior or posterior capsule, and in some cases it may possibly occur without any rupture of the capsule. Cataract usually forms very rapidly after the admission of aqueous to the lens substance and results from the action of the sodium chloride of the aqueous upon the globulin of the lens substance. In an extensive rupture of the capsule some of the lens substance escapes into the anterior chamber where it swells up, breaks down and becomes absorbed. In some cases of slight laceration of the capsule there is formed a limited opacity, which may disappear, remain stationary or increase.

Cataracta Secundaria, or *after cataract*, as it is sometimes called, is the term applied to changes occurring in the capsule of the lens that remains after the extraction of the cataract. Secondary cataract may be either simple or complicated. In the majority of cases, after the extraction of the lens, the lacerated anterior capsule is thrown into folds and adheres to the posterior capsule, within these folds is shut up a small amount of lens substance which becomes opaque or there may be simply a proliferation or increased thickening of the capsule. This simple form may be either thick and opaque or thin and almost transparent. It may appear within a few days after the operation, or not for months, and is more apt to come on rapidly when peripheral opening of the capsule has been made. The complicated form of secondary opacity is a more serious affair, for in these cases there

may be thickening and contraction, the iris, which is adherent to the capsule, is drawn up toward the wound and may wholly obliterate the pupil. Cyclitis, detachment of the retina and other changes may ensue, the vitreous becomes fluid and the eye passes into atrophy, and sometimes even sympathetic ophthalmia may result from the irritation.

Secondary cataract should never be operated upon until all signs of irritation of the eye have ceased. We believe that, as a rule, four weeks after the extraction is the earliest date that the operation for secondary cataract should be made, and that it would be better to wait as many months, or even a year in many cases. Generally, however, these patients are desirous of securing the use of their eyes again as soon as possible, so that usually the operation is made in from six weeks to three months after the extraction. We have seen a very thick, opaque secondary opacity gradually absorb so that after several months it became very thin and almost transparent.

Cataracta Capsularis is the name sometimes used where there is an opacity of the capsule. It may be seen either congenitally or as secondary to some other inflammation of the eye, and there is generally a proliferation and thickening of the epithelium of the capsule. This form of cataract is more often placed under the heading of polar cataract, either anterior or posterior.

DIAGNOSIS.—The simple diagnosis as to the presence or not of either a partial or complete cataract has been sufficiently shown under the symptoms already detailed. The importance, however, of a thorough examination of the cataract itself, together with a diagnosis as to whether complicated or not by other diseased conditions of the eye, is of the utmost value in forming an opinion as to the advisability of an operation and the prognosis as to the ultimate vision after an extraction. The size and density of the lens should be determined, the action of the pupil, whether adhered to the capsule, sluggish or freely movable, and the tension of the eye must be considered. The perception of light is the most important diagnostic point to determine both the acuity and the field of vision. In a mature, uncomplicated cataract the patient should be able to recognize the light of a candle in a dark room from thirty to forty feet away. The patient should also be able to recognize the direction from which the light comes, and the test should be made by holding the light in

all parts of the field of vision. Any inability to recognize the light in the different directions would at once cause a suspicion of some intraocular lesion, which, of course, renders the prognosis less favorable. The examination as to the light perception may be made by the ophthalmoscopic mirror held from three to five feet away and using a weak illumination. A decided limitation in the field might indicate detachment of the retina, atrophy of the choroid, or other lesions of the nerve, retina or vitreous. The tension of the eye should be noted, as cataract may occur with glaucoma, when it would be increased, or with an inflammation of the ciliary body or choroid, when we would have a diminished tension with possibly a discoloration of the iris and tenderness of the ciliary region. Fluctidity of the vitreous would be indicated by tremulousness of the iris and lens. This might also occur from a relaxation or loosening of the suspensory ligament. The lens itself, if shriveled or flattened, or if of a chalky-white or calcareous appearance, would indicate some serious intraocular changes.

Operative procedures are not necessarily contra-indicated by the existence of any of these conditions, still it is important to recognize the complication in order that the probable results may be correctly appreciated by both the surgeon and the patient. The diagnosis as to whether the cataract is mature or not is also of importance, as in immature cataract, where there is not complete opacity of the cortex of the lens, more or less of its cortical substance may remain after escape of the nucleus and cause trouble. The usual test is by the oblique illumination, which, when the cataract is immature, shows a shadow upon the lens on the side from which the light comes. This is the shadow of the iris and is due to the fact that the opaque lens is posterior to the plane of the pupil and that there is a clear space between the iris and the opacity. When the cataract is ripe the opacity is level with the margin of the pupil and there is no shadow formed. In hypermature cataract the shadow is present, but a careful examination may show the yellow nucleus of the lens sunken out of the axis of the eye and its rim may be seen in the pupil and may change its position as the head is inclined from one side to the other. We must avoid mistaking the black rim at the pupillary border of the iris, due to a projection of its posterior pigment layer, for the shadow. In certain cases of so-called amber lenses the nucleus of

the lens, instead of appearing of the usual grayish-white color, assumes an amber like translucency, and in these cases there may be a slight iris shadow together with a certain reddish reflex from the fundus with the ophthalmoscope, while the cataract is really matured as much as it ever will be. No red reflex from the fundus is to be seen with the ophthalmoscope in any other variety of cataract when matured. The appearance of the surface of the lens gives some information, for when the striæ appear very fine the lens is hard, while, if broad and white, the cortex is more or less soft.

PROGNOSIS.—In the immature senile cataracts, particularly where the opacity is in the form of peripheral striæ, I believe, if they are taken in the earlier stages, that the tendency to progress to complete opacity *can* be checked by homœopathic treatment in the majority of cases. In my report of "The Homœopathic Treatment of Incipient Senile Cataract, with Tabulated Results of One Hundred Cases"¹ this claim of the value of homœopathic remedies to check the progress of incipient cataract was borne out by the fact that one-half of all the cases under observation for two years or over, showed no failure in the vision and no increase of the opacity, and that in about one-third more there had been but a very slight loss of vision. Further that in those cases where the vision was better than $\frac{1}{3}$ at the commencement of the treatment, there was no increase of the cataract in 60 per cent. of the cases; but that in those cases where the vision was not better than $\frac{1}{3}$ the growth of the cataract seemed checked in but 45 per cent. of the cases treated. Therefore, I believe we are warranted in holding out to patients with incipient senile cataract a probability of preserving their sight unimpaired, instead of dooming them to a long period of gradually increasing blindness, with the prospects of an operation at the end. Rare instances of the spontaneous disappearance of cataract by absorption have been reported. The usual course, however, of cataract, when once started, is a steadily increasing opacity of the lens until complete and blindness has ensued. For matured cataracts nothing but operative procedures are to be considered, and, when uncomplicated, the results are usually good. Unfavorable conditions in these cases are when the patient is very greatly debilitated, in very fat subjects, or when there is a bad cough. Other conditions which would

¹ No. Amer. Jour. of Homœo., Dec., 1891.

militate against the prompt healing of the wound are of course unfavorable and should be relieved, if possible, before the operation is undertaken. The most formidable of these are catarrh of the lachrymal sac, chronic conjunctivitis and pterygium, all of which should be corrected, if possible. Careful prophylaxis is always an essential feature in the prognosis and should be followed out thoroughly. The results of cataract operations are usually good. Statistics have been compiled which show the average per cent. of failures of numerous operators, taken collectively, to be only from 5 to 10 per cent.; but, for individual operators of an extended experience the per cent. has been much lower.

A vision of $\frac{1}{10}$ has been called fully successful, and when but mere perception of light and worse failures, this standard, under recent years experience with asepsis, should, we think, be lowered to that adopted by some, of $\frac{1}{6}$ in order to be called successful.

TREATMENT.—A large number of cases are to be found in our literature in which the internal administration of a few doses of the properly selected remedy has worked a wonderful cure of cataract, but the great majority of these must be taken “cum grano salis,” and put aside with the remark, “mistaken diagnosis.”

After years of experience in the treatment of cataract, I have no doubt that a careful selection of drugs, according to the homœopathic law, and their continuance for a long period, will succeed in a large proportion of cases in checking the progress of the disease and in many cases clear up a portion of the diffuse haziness, thus improving vision to a certain extent. But, after degeneration of the lens fibres has taken place, no remedy will be found of avail in restoring its lost transparency and improving the sight. We must then, providing the vision is seriously impaired and it is a senile or hard cataract, wait until it has become mature, when the lens should be extracted.

The medical treatment will consist of the selection of remedies, according to the constitutional symptoms observed in the patient, for the objective indications are entirely or nearly absent. We cannot yet decide from the appearance of an opaque lens, what remedy is required.

The following drugs have been found most efficacious in arresting the progress of cataract :

Calcareo phos.—In checking the progress of cataract it has appeared to be of decided service and will be of value when the following symptoms are present: Headaches, especially of the right side, pain around the right eye, aching pain in the right eye, tired feeling of the right eye. These have all been relieved by *Calc. phos.* Other symptoms noted were: Eyes feel stiff and weak, dizziness, rheumatic pains, etc.

Causticum.—Of all the remedies used, *Causticum* has undoubtedly proven of the most value in my hands. The principal indications for *Causticum* seem to be a feeling as if there was sand in the eyes, sensation of pressure in the eyes, heaviness of the lids, burning, itching of the eyes, with a desire to keep them closed, photophobia, flashes of light before the eyes, winking and twitching of the lids.

Iodoform.—Dr. William R. King of Washington, D. C., reports in the *Journal of Ophthalmology, Otology and Laryngology* for April, 1891, six cases of incipient cataract very much benefited by the use of this drug.

Naphthaline is a remedy I have used, simply because it was found to have produced cataract in the eyes of animals, but my success with this drug has been very indifferent.

Phosphorus has proven of value in some cases of cataract. The especial indication of the eyes seems to be the *colors before vision*, black floating spots before the eyes, flashes of light and the concomitant symptoms of the drug.

Sepia.—Eyes feel weak, worse toward evening and better in the middle of the day; some sharp pains in the eyes, heaviness of the lids, twitching of the lids, smarting of the eyes, relieved by eating; *headaches which are worse morning and evening*; perspires very freely, worse morning and evening. The morning and evening aggravation seems to be characteristic of *Sepia*, and it is a useful remedy in the cataracts of women.

Other remedies that may be called for are *Argent. nit.*, *Calc. carb.*, *Chin. ars.*, *Con.*, *Ignat.*, *Kali iod.*, *Kali mur.*, *Lach.*, *Lyco.*, *Magn. carb.*, *Natr. mur.*, *Nitric ac.*, *Nux vom.*, *Puls.*, *Senega*, *Silicea* and *Sulph.*

Galvanism I have employed in a great many cases, but always together with remedies. The cases in which it has been used have

shown no more favorable results than those treated with remedies alone, so am undecided whether it has any value or not.

Massage of the eye in incipient cataract has been credited with surprising results by some. I have employed it in three or four cases only, with no apparent results.

In addition to the remedial treatment just referred to for immature cataract the refraction should be carefully examined and the glass which gives the best vision prescribed.

Operative Treatment of Cataract.—*Iridectomy* may be performed in the usual manner, as already described, for three purposes: First, in order to secure an artificial pupil in front of some transparent portion of the lens in central, stationary forms of cataract, as in lamellar and partial congenital cataracts when central. Iridectomy is indicated in these cases when, after dilatation of the pupil, there is sufficient improvement in the vision to warrant the slight disfigurement of a new pupil. It should be made in front of the clearest portion of the lens and preferably downward and inward. Iridectomy may also be of service in some cases of polar cataract, but, as this variety will sometimes increase, the beneficial results are not as liable to be permanent.

As a second indication for iridectomy, it may be made for the purpose of producing artificial ripening of an immature senile cataract, according to the method suggested by Förster which is by making an upward iridectomy and then bruising the lens fibres by rubbing the cornea either through the lids or by a horn spoon directly upon the cornea. Some operators insert a spatula into the anterior chamber and press directly upon the lens. This method is indicated in those cases in which the opacity has reached the stage where the blindness is sufficient to incapacitate one for their customary occupation and the progress of the cataract still indicates a long period before maturity when extraction is justifiable. In some cases complete maturity of the opacity will result in from two to four weeks, when extraction may be made. Others will mature more slowly, and, in some cases, we have seen no effect whatever from the operation. Only gentle rubbing of the cornea is required, and no bad results have ever occurred in our hands from the procedure. In some cases we have followed this method in one eye, when there was an equal opacity in both, with subsequent extrac-

tion and good vision in the operated eye, while the other would be watched for several years before the cataract would become matured and extraction be warranted. Thus, instead of waiting for the cataract to become ripe and ready for extraction, several years of useful vision may be given the patient in those cases where the cataract is almost matured in both eyes.

The third use of an iridectomy is as a preliminary operation to the extraction or at the same time as the extraction. Up to within the last two or three years my universal practice was, when the patient would submit to two operations, to always make a preliminary iridectomy, believing it to be by far the safest method of extraction, more certain to insure success than any other method, and with less danger of after-inflammation. My more recent method is to extract without an iridectomy, and this is undoubtedly the ideal operation in suitable cases. When an iridectomy is made, it is more frequently done at the time of the extraction. The following indications for iridectomy are recommended by Galezowski¹: (1) Where the iris falls before the knife; (2) in synechiæ; (3) when the corneal wound is too small; (4) in capsular cataract; (5) in subluxation of the lens; (6) in constitutional cataract (glycosuria, albuminuria); (7) in syphilis.


Discission, or needle operation, is applicable to all forms of complete cataract in children, viz.: Congenital or traumatic cataracts. The object of this operation is to open the capsule of the lens, and, by allowing the entrance of the aqueous to the lens substance, cause its absorption. The value of this operation is especially in children under fifteen years of age, as after that age absorption takes place very slowly, if at all. The operation may be made in congenital cataract as early as the third month, but it is just as well to wait until the child is a year old. In very early life one slight puncture is often sufficient to cause complete absorption, although in later years it will usually have to be repeated several times at intervals of two or three months.

The method of discission is, after dilatation with atropia, to produce general anæsthesia in young children, or the use of cocaine in older subjects. The lids, separated by the speculum, and the eye steadied with fixation forceps, the needle (Fig. 43) or knife needle

¹ Soc. d'Ophth. de Paris, July 2, 1889.

(Fig. 44) is now entered through the cornea at the temporal side, and, reaching to the opposite side of the pupil, the needle penetrates the capsule, when, by using the cornea as a fulcrum it is made to cut the capsule (Fig. 45). A second cut may be made at right angles to

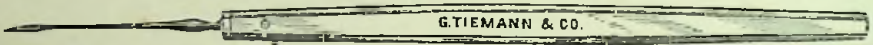FIG. 43.



Bowman's Stop Needle.

the first, although at the first operation it is better not to make too extensive laceration of the capsule, for fear of too much swelling of the lens, causing damaging pressure upon the iris or ciliary body. More extensive cutting of the capsule may be made at subsequent

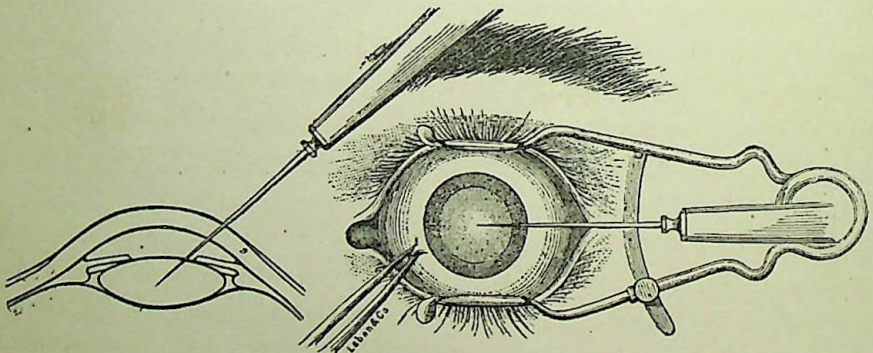
FIG. 44.



Knapp's Scalpel Needle.

operations. Sometimes two needles may be used, entering them at opposite sides of the cornea and penetrating the lens at the centre of the pupil, then, by inclining the handles toward each other, the points separate and an opening is at once made. Stop needles are

FIG. 45.



The Needle Operation.

made for this purpose, which prevent a too deep entrance of the needle.

After the operation atropia should be instilled and the eye bandaged. In young children there is usually but very little, if any,

reaction; but the older the subject the greater is the liability to swelling and inflammatory reaction. Sometimes the lens begins to swell rapidly within a few hours, fragments of the lens substance push forward into the anterior chamber, and there will be associated with it much pain and pericorneal injection. Ice compresses should be immediately applied, atropia instilled and aconite given. If not controlled within a short time and the aqueous becomes hazy, iris discolored and chemosis sets in, a large paracentesis should be made to allow of the escape of the aqueous and some of the lens substance, if possible.

Discission is also made for the opacity of the capsule following extraction, and for this purpose the knife needle is always preferable. The operation is the same as just described, excepting that in secondary cataract the object is to secure by a clean cut the curling away of the divided membrane in such a manner as to give a clear pupil, and for this purpose various shaped discissions have been recommended and practiced.

The shape of the discissions most generally made are +, T and >. Knapp,¹ in a paper on "Glaucoma after Discission of Secondary Cataract," says that the first or + shaped discission gives the truly ideal results, *i.e.*, clear pupils, and is made by making at first a horizontal incision, then, by cutting from above down to the horizontal section and from below upward in the same way. But, owing to the occurrence of glaucoma in about 1 per cent. of his cases during the last six years, he has returned to the T-shaped discission. Care should be taken not to enter the knife any deeper into the vitreous than is necessary for a sufficient opening in the capsule. In some rare cases the use of the two needles as described may be preferable to the knife.

We believe that discission should be practiced in a large majority of cases of cataract extraction, as by so doing a greater improvement of vision can be gained. Disastrous results have been reported from discission, but so far we have been fortunate enough not to meet them, and hence do not consider our cataract operations completed until a perfectly clear pupil has been secured by discission. The operation should never be made until all signs of irritation of the eye, after the extraction, has passed away. The knife must be very sharp, and

¹ Archiv. Ophthal., vol. xxi., 2, 1892.

all rough handling or dragging upon the resisting bands must be avoided.

Cataract Extraction.—The various methods for the extraction of a cataractous lens that have been employed by different operators would, if described in detail, form a volume in themselves. In fact, it may be said that no two operators follow precisely the same method in every detail. The experience and *technique* of one will vary from that of another, and, in consequence, the procedure of one varies in some details from that of the other. On account of this variance, many so-called modifications are being constantly brought forward. There are, however, two essentially different methods of extraction which will be considered, viz.: Extraction with an iridectomy, and extraction without an iridectomy, or, as it is frequently called, the simple operation.

Previous to all cataract operations are certain preliminary considerations worthy of attention. As to the season of the year, it should depend upon the location, simply avoiding, if possible, extreme cold or heat. Age has less influence upon success than the general condition of the patient. Any chronic disease, such as nephritis or diabetes, that will impair the vital forces will tend to influence unfavorably recovery from the operation. A severe cough, asthma, incontinence of urine, or any condition affecting the general health, should be controlled as far as possible. All sources of infection, such as suppurating wounds, erysipelas, catarrh of the lachrymal sac, conjunctivitis, etc., must be provided against.

Thorough antiseptic measures are, we believe, essential, although in the present chaotic state of general opinion regarding asepsis and antisepsis, each operator must draw his own conclusions. Personally, as we can conceive of no reasons against it, excepting the additional labor involved, we prefer to follow out antisepsis, even though unnecessary, until it has been positively proven useless. The room and bedding should be perfectly clean and free from all sources of impurity; the patient should have the face, hair, beard and hands thoroughly scrubbed with soap and water once or twice before the operation. The surgeon and the assistant should have their hands scrubbed with soap and water and the nails carefully cleansed and then again washed in a solution of mercury or carbolic acid. The instruments are thoroughly cleansed either in a solution of bichloride

of mercury, 1 to 2,000, or in carbolic acid, 1 to 200, with the exception of the knife, which is immersed in a solution of boracic acid, or for a few minutes in boiling water. The face of the patient is then washed with one of the above solutions, taking great care to cleanse the margin of the lids at the root of the ciliae. The conjunctival sac, especially if it contains any secretion, should be flooded

FIG. 46.

Graefe's
Linear Knife.

FIG. 47.


Noyes'
Linear Knife.

FIG. 48.

Knapp's
Cystotome.

FIG. 49.

Hard Rubber
Lens Spoon.

FIG. 50.

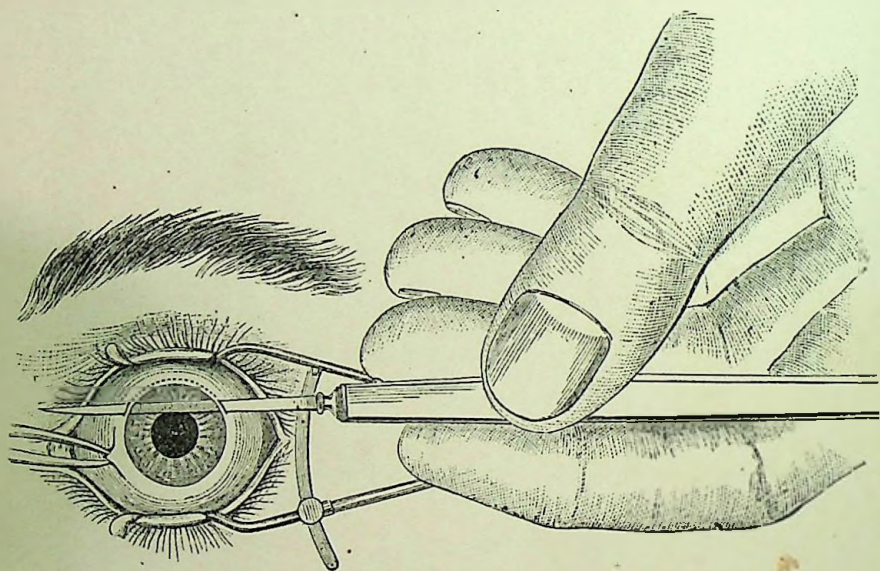
Fenestrated
Lens Spoon.

with a 1 to 8,000 solution of the bichloride of mercury. General anæsthesia is not employed unless the patient is particularly nervous and unmanageable, when ether is administered. A 2 or 4 per cent. solution of cocaine is dropped upon the cornea two or three times, at intervals of about ten minutes, when local anæsthesia is complete.

Extraction with Iridectomy.—This operation as most generally

performed is practically that introduced by von Graefe as his modified linear operation, the slight variations or so-called modifications being merely a slight variance in the position of the incision. Anæsthesia being complete, the speculum is inserted and the globe steadied with the fixation forceps. The knife is then entered by making the puncture at the corneo-scleral margin at a point on a level with a semi-dilated pupil. The direction of the knife when making the puncture is toward the centre of the pupil, and, when well in the anterior chamber, is gradually, while being pushed across the chamber, brought parallel to the horizontal diameter until its

FIG. 51.



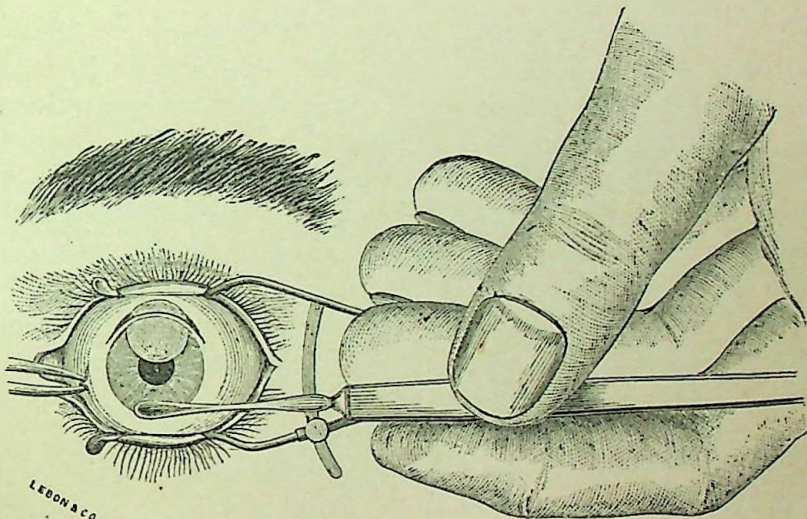
The Incision.

point comes directly on a level with the puncture. The counter-puncture is now made and the knife cut out so that the whole section is about in the corneo-scleral margin. (See Fig. 51.) This first stage of the operation varies, as already referred to, with different operators merely as to the position of the puncture, counter-puncture and the completion of the section above, some making it further in the cornea and others deeper in the sclera, and some making a conjunctival flap above. In making the counter-puncture the point may catch in a wrong position, when it may be slightly withdrawn and entered again, care being taken not to increase the size of the opening at the

point of puncture and allow of the escape of the aqueous. In cutting out the iris may fold over the knife, when one of two procedures should be followed—either slowly withdraw the knife and postpone the operation, or preferably complete the section, cutting through the iris, which does not materially interfere with the success of the operation, except by the bleeding in the anterior chamber.

After the completion of the section, the iris, if not previously removed, is seized at its pupillary border with the iris forceps and gently drawn out. As but a small iridectomy is necessary, no undue traction should be made upon the iris. The iris should be

FIG. 52.



The Removal of the Lens.

severed by one cut of the scissors, and, if its edges become caught in the wound, it may be made to free itself by gentle friction with the lid, or be replaced with the spatula.

The cystotome is then introduced into the anterior chamber, the back of the instrument preceding and its cutting point held parallel to the surface of the lens; it is now pushed downward to the lower margin of the pupil or even beneath the iris, and the point turned toward the lens, the capsule of which it readily pierces. The division of the capsule is usually made by drawing the cystotome from the lower border directly upward, making a vertical incision through the capsule, and then a horizontal incision crossing it above, making

a T-shaped opening. My method has been that practiced by Knapp, making a peripheral cystotomy. The larger the opening in the capsule the easier the lens is removed.

The final step in the operation is the removal of the lens, and for this purpose it is my preference to remove the speculum, holding the upper lid with the index finger of the left hand while the assistant draws down the lower lid; but most authorities recommend leaving the speculum *in situ*. (See Fig. 52). Pressure is then made with a scoop upon the lower border of the cornea, directing the force backward, not upward, until the upper edge of the lens, having been tilted forward, engages in the wound; the direction of the force should now be slightly upward as well as backward, following the lens as it passes out. The cortical substance is usually more easily removed directly following the nucleus than after waiting for the anterior chamber to fill, and the effort should be made to remove as much of the cortical substance as possible by gentle manipulation of the cornea with the scoop, gradually coaxing it out. A too prolonged attempt in this direction, however, must not be made, as it tends to increase the danger of inflammatory reaction, and a clear pupil can be obtained later by discission.

After removal of the lens great care should be taken to thoroughly cleanse the wound from any cortical substance, shred of capsule, or prolapse of the iris. This is done with a hard rubber spud or spoon, dropping a solution of boracic acid upon the eye at the same time. The conjunctival sac is then thoroughly cleansed by irrigating with a solution of boracic acid and all shreds or blood-clots removed, and then the dressing is applied. Many forms of dressing have been used by different operators from the simple application of strips of isinglass plaster to very elaborate bandages. My plan has been to apply to the closed eyes a piece of antiseptic gauze, over this a light layer of absorbent cotton and then a light bandage, without pressure, merely to hold the dressing in place.

AFTER-TREATMENT.—The patient is placed in bed in a slightly darkened room and directed to lie as quietly as possible, turning from the back to the unoperated side as he desires. We believe it best that the patient be not allowed to sit up to eat, nor, as a rule, permitted to get up to urinate, but that rest in the prone position be followed for the first two or three days, unless the patient becomes very

nervous and restless, when more liberty may be allowed. After this time he may be permitted to sit up and gradually allowed to do more and more each day. The dressing should not be removed for the first twenty-four or forty-eight hours, if it has not become disarranged or the patient complained of pain or discomfort of the eye. At the end of the second or third day, if there has been no trouble, the eye may be examined for the first time, and, after a week, a lighter dressing may be substituted in place of the bandage for a few days more.

Accidents during the operation are apt to be met with. One in which the iris falls before the knife during the incision has already been referred to. Another unfortunate accident is when the wound is too small to permit of the escape of the lens. When this occurs, the incision should be enlarged with the blunt-pointed scissors. Dislocation of the lens, either partial or complete, has occurred from too great pressure with the cystotome. If it is pushed back into the vitreous it should be removed with the scoop or wire loop.

Escape of the vitreous may occur either before or after the extraction of the lens. If it occurs during the attempt to force the lens through the external wound, further pressure on the cornea must be at once abandoned, as it will cause further loss of vitreous without resulting in the escape of the lens. The lens will then have to be removed with the scoop or wire loop, which is gently inserted well behind the lens, care being taken not to cause greater dislocation, and, by gentle pressure forward to prevent its slipping off, is gradually drawn out. When the loss of vitreous has occurred after the escape of the lens, the wound should be cleared of the vitreous by careful wiping or by cutting off the prolapsed portion with the scissors. Loss of vitreous, while a frequent and undesirable accident, is not necessarily serious, as good visual results are often obtained even after a large loss of vitreous. Kerschbaum¹ reports the loss of vitreous thirteen times out of two hundred cases operated upon, and in no instance did loss of the eye occur.

In some cases the division of the capsule is not of sufficient extent to allow of the shelling out of the lens, and when this occurs the cystotome must be again inserted and a larger laceration made.

Of the evil results that may occur after the operation severe pain

¹ Archiv. Ophthal., vol. xx., 3, 1891.

is usually the forerunner, and may set in within a few hours or several days after a perfectly smooth operation and may indicate an intraocular hæmorrhage, suppuration of the wound or iritis.

Intraocular hæmorrhage is the most serious accident that occurs after an extraction, and, as a rule, results in panophthalmitis and loss of the eye. It is fortunately of extremely rare occurrence, as shown by the fact that, in the extended experience of Dr. Knapp, but one case had been seen by him up to November, 1890, which he reports in the *Archives of Ophthalmology*, January, 1891. In this case the eye was saved by carefully removing the blood, washing the conjunctival sac with a mild antiseptic, sterilizing the outside of the lids and applying an antiseptic dressing, which should be changed once or twice daily, according to the discomfort and discharge. If panophthalmitis supervenes, the eye should be enucleated at once.

Suppuration of the cornea, since the general practice of antiseptics in ophthalmic surgery, has, fortunately, become of quite infrequent occurrence. It results from some infection of the wound, either introduced at the time of the operation or within the first few days following, from some lachrymal or conjunctival discharge, and in some cases occurs in the very old or debilitated patients from want of sufficient nutrition in the cornea. It occurs usually within the first three days, though may occur as late as two weeks after the operation. The onset of suppuration is usually ushered in with severe pain, and, upon examining the eye, we find the lids swollen and puffy, the conjunctiva chemosed, the cornea hazy and sloughing at the margins of the wound. The suppurative process may be checked and the wound healed without any damaging results, or it may result in slough of the cornea with leucoma, or extend into a general panophthalmitis. The treatment is practically the same as described under ulcerations of the cornea.

Iritis following cataract extraction generally makes its appearance about the eighth day, sometimes earlier or later, and should receive the usual treatment for this condition.

To prevent as well as to arrest the progress of any form of inflammation in its initial stage occurring soon after cataract extraction, no local remedy is equal to the use of ice. Internal medication is also of decided value in the treatment of the various complications which arise after cataract extraction. For the neuralgic pains, which

often occur within the first twenty-four hours, relief can often be obtained from five-drop doses of the tincture of *Allium cepa*, as first recommended by Dr. Liebold. Morphine in rare cases may be of service to relieve this pain. In any inflammation of the eye following cataract extraction, *Rhus tox.* is a most valuable remedy, and is given as soon as the patient begins to complain of pain, accompanied by lachrymation and puffiness of the lids. After pus has formed, *Hepar*, *Silicea*, or *Calc. hypophos.*, either alone or in alternation with *Rhus*, are of value. In some cases a low form of chronic conjunctivitis follows for awhile after the operation, and one of the best things for this condition is to keep the patient out in the open air.

Extraction without Iridectomy.—Simple extraction, as this is usually called, is practically the same as the operation already described, with the exception of removing a section of the iris. All the preliminary precautions should be followed out in this as in any other operation, with the exception of the *Atropia* dilatation. The corneal incision varies somewhat in that it is made wholly in the clear cornea in simple extraction and should involve about the upper two-fifths of the circumference of the cornea. The object of making a more central incision in this operation is to avoid the greater tendency to incarceration and prolapse of the iris from a too peripheral incision. A free division of the capsule should be made by inserting the cystotome as before and carrying it well under the margin of the iris. The speculum may then be removed and the upper lid drawn back with the forefinger of the left hand, which at the same time may make slight pressure on the upper part of the globe. The spoon is now applied to the lower part of the cornea and pressure made directly backward until the lens is tilted upon its axis and presents at the opening, when the pressure should be upward and backward, which causes an extrusion of the lens with more or less prolapse of the iris. A gentle pressure and stroking of the cornea with the spoon below, together with pressure above to open the wound, will promote the escape of the cortical substance remaining. This may be aided by irrigating the lips of the wound and the conjunctival sac with a warm, saturated solution of boracic acid, many operators recommending the irrigation of the anterior chamber at the same time. The prolapsed portion of the iris, if it has not already returned to its place, can be made to do so by gently stroking

and pushing it within the lips of the wound with a smooth probe or spatula. On replacing the iris it should return to a central position and assume its circular shape; if it should not, gentle massage through the closed lid will often cause it to do so. Before applying the dressing, as already detailed, the eye should be thoroughly irrigated with the boracic acid solution and a few drops of Eserine solution instilled.

In the use of Eserine, Bull¹ cautions against the instillations of a strong solution of Eserine, believing that it is apt to cause iritis, and claiming that half a grain to the ounce solution, or, in some cases, even one-tenth of a grain is sufficient to produce any desired contraction. After forty-eight hours a solution of Atropia may be instilled to prevent posterior synechiæ, which are apt to follow; in other respects the after-treatment in uncomplicated cases is the same as in extraction with iridectomy.

The accidents and complications liable to occur in this operation are the same as those already referred to, with the addition of prolapse of the iris, which may occur at the time of the operation or immediately afterward, before closure of the wound, and in some cases by the reopening of the wound after having partially healed. When it occurs soon after the operation and cannot be returned to its place, it should be cut off. Prolapse may also occur later, and when it does is almost always of traumatic origin, due to some sudden movement of the patient, from coughing, lying on the operated side, from a too early examination of the eye, etc.; and when occurring later, after the wound is partially healed, it should be left undisturbed, as they generally disappear or cicatrize in a smooth manner and cause no trouble.

Incarceration of the iris or anterior synechiæ is an adhesion of the iris in the lips of the wound without being prolapsed through it. This accident causes considerable distortion of the pupil and may be the source of irritation to the eye. Its occurrence, however, is, we believe, becoming less and less frequent, owing to a more general adoption of the more central corneal incision.

As previously stated, we believe the extraction without an iridectomy to be the ideal method of removing cataractous lenses; but as it has its advantages and disadvantages, we quote from Bull (*loc.*

¹ Trans. Amer. Ophthal. Soc., 1890, p. 578.

cit.) a comparison of the same with the operation of extraction with iridectomy :

“1. If successful and without complication, it preserves the natural appearance of the eye—a central, circular and movable pupil.

“2. The acuteness of vision, with the astigmatism carefully corrected, is somewhat greater than after the old operation.

“3. Eccentric vision and orientation are decidedly better than by the old operation.

“4. Small particles of capsule are much less likely to be incarcerated in the wound, and thus act as foreign bodies and excite irritation.

“5. It is a shorter operation in point of time, by reason of the absence of an iridectomy.

“6. As there is no iridectomy, there is little or no hæmorrhage, and this may be considered a very decided advantage.

“The disadvantages of simple extraction are as follows :

“1. The technique of the operation is decidedly more difficult than that of the old operation. The corneal section must be larger, in order that the passage of the lens through it may be facilitated, as the presence of the iris acts as an obstacle to its exit. The section must be performed rapidly, so as to avoid the danger of the iris falling on the knife and being wounded. This rapid passage of the knife across the anterior chamber renders it difficult to make the height of the flap an even curve, particularly when the incision is entirely in the clear cornea, as it should be. The cleansing of the pupillary space and the posterior chamber is much more difficult than after the old operation.

“2. Posterior synechiæ, secondary prolapse and incarceration of the iris are more frequently met with than after the old operation. The two latter may be largely avoided by making the corneal section, as before stated, in the clear cornea and not in the limbus, which is too peripheral and rather favors both prolapse and incarceration of the iris.

“3. The operation is not applicable to all cases. This objection, however, may be applied to all operations.”

Aphakia.—Absence of the lens is recognized by greater depth of the anterior chamber; a peculiarly black pupil and often tremulousness of the iris is present. Dilatation of the pupil will often show

traces of the opaque capsule left behind. The power of accommodation is also lost. Removal of the lens in an emmetropic eye will leave a high degree of hypermetropia equal to about 11 D., and, of course, much less in a previously myopic eye. In addition to the hypermetropia, after the extraction of the lens, there is usually a certain amount of astigmatism, varying from 1 D. to 4 D., which is more often "contrary to the rule" and which should be corrected, together with the hypermetropia. Glasses, as a rule, should never be prescribed until all signs of irritation of the eye have passed away, and are not often worn constantly at first with comfort.

Luxatio Lentis (*Ectopia Lentis, Dislocation of the Lens*).—This condition may be either partial or complete, and may be congenital (*ectopia lentis*) or from disease of the eye and from traumatism. The lens may be tilted obliquely, in the vertical plane or in any direction. It may be displaced backward into the vitreous or forward into the anterior chamber, and, from injury of the sclera, it may become lodged under the conjunctiva or entirely escape from the eye. Dislocation most often follows some disease where the vitreous has become fluid and the suspensory ligament, stretched and atrophied, gives way. High degrees of myopia favor this displacement, and when but partial, the border of the lens being in the pupil, there will exist two different states of refraction in the same eye, so that he may have monocular diplopia.

SYMPTOMS.—A high degree of hypermetropia is produced in emmetropic eyes; the accommodation is lost, the anterior chamber is deepened from the sinking of the iris and the pupil is small. When due to disease, atrophy of the choroid and opacities of the vitreous are generally present.

DIAGNOSIS.—If the edge of the lens is in the pupil it will appear as a dark border with the ophthalmoscope by the direct method and a double view of the fundus be seen, one image through the lens and the other beyond the lens. Total absence of the lens is determined by the catoptric test, which is made in a dark room with a lighted candle passed slowly before the eye, when, if the lens is present, three images should be seen—a clear, distinct, upright image from the cornea; a second, also upright, but diffused and faint image from the anterior surface of the lens, and a third, small, sharp and

rather bright image, which is inverted from the posterior surface of the lens. If two or all of these images are seen, the lens is in place.

A dislocated lens will frequently become cataractous and may give rise to attacks of glaucoma, iritis, etc.

PROGNOSIS.—Congenital displacement, or ectopia lentis usually occurs upward or upward and inward and upward and outward. It is often hereditary and usually remains unaltered. Other defects are frequently found with congenital dislocation. When the displacement is due to disease, the vision is as a rule very bad and apt to grow worse. In traumatic cases the lens will usually become cataractous. Severe inflammation and glaucoma is apt to occur from a displacement into the anterior chamber.

TREATMENT.—If the dislocation is forward into the anterior chamber, removal of the lens by a peripheral incision is a very simple affair. In some cases it is first necessary to transfix the lens with a needle to prevent it from slipping back through the pupil again. If the dislocation occur from a rupture of the sclera and it lies beneath the conjunctiva it is easily removed. If the lens remains clear and is but partially dislocated, it should be left alone and the most suitable glasses be prescribed. Dislocation of the lens backward into the vitreous is a much more serious affair. When it is of long standing and has caused no irritation of the eye, it may be left alone. If, however, it rests in the front part of the vitreous particularly and there are signs of inflammation which may lead to destruction of the eye, its removal should be attempted. The operation recommended by Knapp and Bull for the removal of lenses dislocated into the vitreous, is, after thorough local anaesthesia, to make an upper corneal section and remove the speculum. The upper lid is now lifted away from the eyeball by the assistant, and, through the lower lid, pressure is made on the lower part of the eyeball and made directly *backward*. The lens will usually rise into the pupil and may come through the pupil and engage in the corneal wound, where the hook or spoon will usually become necessary to complete the removal. Failing to remove the lens by this procedure or when the backward pressure causes an escape of the vitreous before the lens can be engaged in the wound, then the spoon or wire loop must be introduced into the vitreous and the lens extracted.

Dr. Agnew devised a double needle or bident which has been successfully used in a number of cases for the removal of a lens dislocated into the vitreous. It is used to fish up the lens and hold it from being pushed further backward by transfixing the globe about 6 mm. behind the cornea. The usual corneal section is then made and the lens extracted with the scoop, after which the bident is removed.

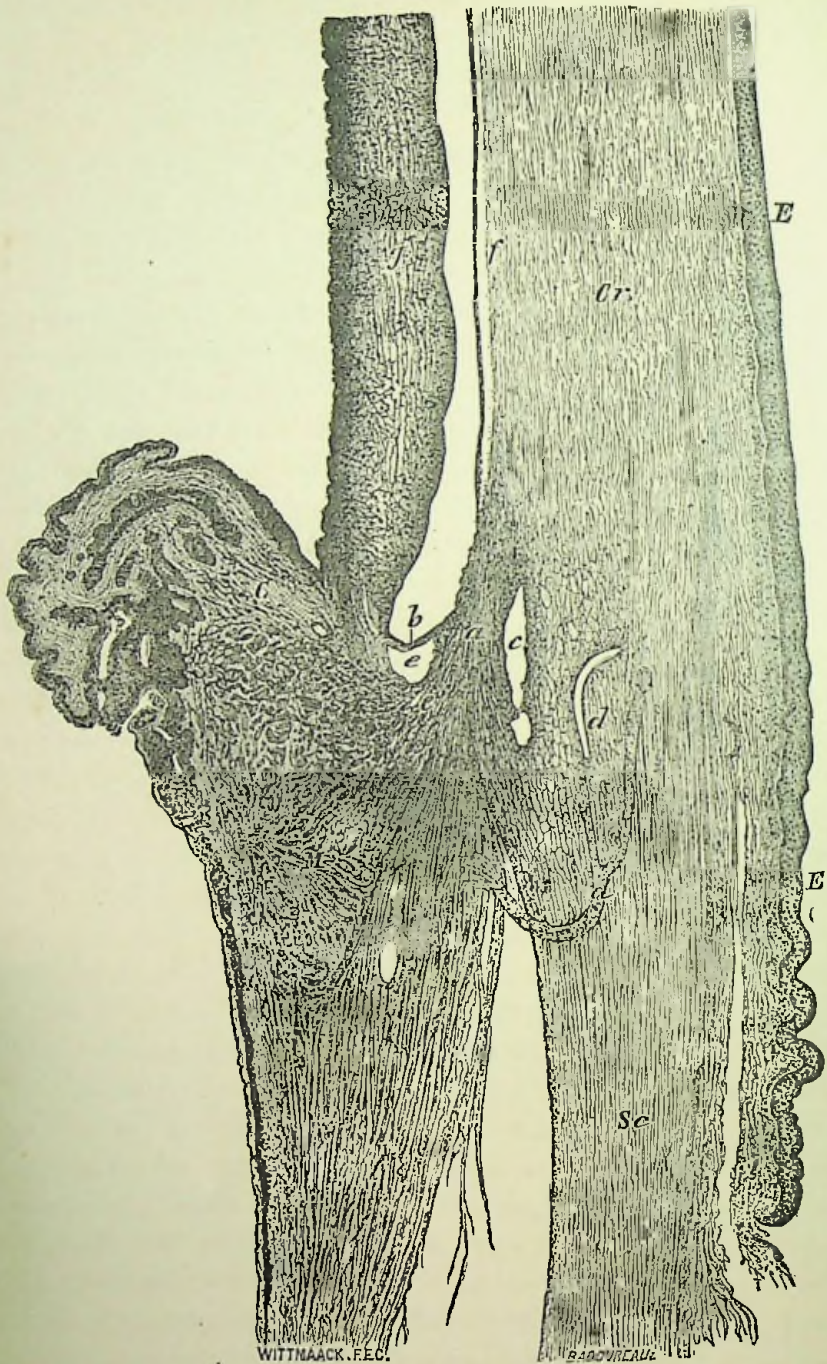
CHAPTER XVII.

Glaucoma.

THE name comes down from olden times, and was employed because, in certain advanced cases, the pupil acquires a greenish hue (*γλαυκός*, green). Glaucoma should be more broadly defined as *an excess of pressure within the eye, plus the causes of and the consequences of that excess*. In the preparation of this chapter very liberal use has been made of the most excellent work by Priestley Smith on "The Pathology and Treatment of Glaucoma."

Anatomy.—The important part which the iritic angle plays in the causation of glaucoma makes a knowledge of its anatomical construction important. According to Waldeyer the iritic angle is the point where the tissue of the iris, cellular stroma of the ciliary body, muscle of accommodation, and the posterior and external portions of the cornea and sclerotic intersect (Fig. 53). These structures jointly form a peculiar cavernous tissue composed of flattened and rounded elastic trabeculæ, which, as a continuation of Descemet's membrane, forms toward the canal of Schlemm a true fenestrated lamellæ. Into the composition of this trabecular elastic tissue enters the elastic tendons and cellular tissue of the ciliary muscle. The membrane of Descemet splits up in this fenestrated lamellæ. Toward the anterior chamber this trabecular tissue is arranged cross-wise, leaving in front of the more closely constituted trabecular tissue large spaces called Fontana's spaces, which are simply the large meshes of the trabecular tissue that merge into the membrane of Descemet and is then called the ligamentum pectinatum iridis. Fontana's spaces communicate in this way directly with the anterior chamber. The canal of Schlemm is formed by a series of spaces or fissures of the cavernous tissue toward the external surface of the eye in the sclerotic, hence the spaces of Fontana and the canal of Schlemm are nothing more than a series of continuous lacunæ in the trabecular tissue and all communicating together. They belong to the lymphatic system and never

FIG. 53.



Section Through the Ciliary Region (Waldeyer). *a*, cavernous tissue of the ligamentum pectinatum; *b*, prolongation of the iris; *c*, canal of Schlemm; *dd*, blood vessels; *ee*, spaces of Fontana; *f*, Descemet's membrane; *I*, iris; *M*, ciliary muscle; *Cr*, cornea; *Sc*, sclera; *EE*, epithelium.

contain blood during health. The canal of Schlemm communicates with the sclerotic veins and thus completes the connection between the anterior chamber and the venous circulation. A system of valves is supposed to exist which prevents the blood from passing into Schlemm's canal and the anterior chamber.

The Zonula of Zinn is a transparent structure extending from the posterior surface of the ciliary processes to the lens. It is derived from the hyaloid layer of the ciliary body, and, as it passes to the border of the lens, separates, leaving a small triangular space called the canal of Petit. Through this structure transfusion readily takes place from the vitreous to the aqueous humor.

Physiology of Secretion and Excretion.—The normal intraocular pressure is equal to about 25 mm. of mercury, and the pressures in the aqueous and vitreous chambers are equal. An excess of even 5 mm. in the vitreous would cause a displacement of the lens and iris. A tension of $+3$ is equal to an intraocular pressure of about 80 mm., but a pressure equal to 200 mm. of mercury has been produced experimentally in animals by compression of the aorta and simultaneous irritation of the fifth nerve.

The maintenance of the normal pressure in the chambers of the eye depends upon the due secretion and excretion of the fluids which traverse them. The intraocular fluids flow from the blood stream. The ciliary body supplies the fluid to the vitreous, lens and aqueous, and is well adapted for this purpose by the peculiar arrangement of its secreting surface into ridges and grooves, which are in direct contact with the vitreous and aqueous. Pathological changes confirm this fact, for eyes excised in the first stages of infiltration of the vitreous show an inflammatory exudation extending into the vitreous from the ciliary body. In a shrinking of the vitreous it becomes detached from the retina, but remains adherent to the ciliary body. Disease of the ciliary body always tends to destruction of the vitreous. Priestley Smith has made an elaborate series of experiments regarding secretion and excretion and concludes that "the fluids which nourish the vitreous body and lens and fill the aqueous chamber are secreted chiefly by the ciliary portion of the uveal tract. The larger part of the secretion passes directly into the aqueous chamber, forward through the pupil and out at the filtration angle. A very much smaller portion passes backward through the vitreous

body and escapes at the papilla. The hyaloid membrane and zonula, which separate the two chambers, are readily permeable by the vitreous fluid."

The escape of the fluids from the anterior chamber by filtration through the ligamentum pectinatum into the canal of Schlemm and sclerotic veins has been proven by the experiments of Leber.

Pathology.—In the advanced stages of glaucoma there may be found, from the long existing intraocular pressure, pathological changes in nearly all the structures of the eye. The most important changes are those found occurring at the iritic angle and which result in a partial or total occlusion of the vessels composing or entering into the canal of Schlemm. They consist of inflammatory changes at the junction of the cornea, sclera and iris. The iris becomes adherent to the cornea and partially or wholly closes up the Fontana spaces; the tissue of the iris becomes sclerosed and the vessels of the iris and ciliary body are degenerated; the ciliary processes become engorged and the ciliary muscle atrophied. These changes seem to still further hinder the excretion of the fluids from the eye and in this way augment the trouble. The outer layers of the choroid become affected, its chorio-capillaris atrophies, the venæ vorticosæ thickened and their calibre occluded by hyperplasia and outgrowths of the endothelium. The sclera gives evidence of inflammatory action and fatty degeneration. The fibres of the optic nerve become inflamed and atrophy in the later stages. The lamina cribrosa loses its power of resistance and is pressed backward. The retina shows a thickening and cystoid degeneration, with subsequent atrophy. There may be fluidity and detachment of the vitreous and the lens cataractous.

SYMPTOMS.—There are certain characteristic signs or symptoms of glaucoma more or less regularly found in all varieties of the disease which may be interestingly studied individually.

Recession of the near point or diminution of the range of accommodation is one of the earliest prodromal symptoms. As this disease is especially one of old age, we naturally have more or less presbyopia, but, in glaucoma the presbyopia increases rapidly and is greater than it should be at that time of life. It is due to the increased intraocular pressure upon the choroid, ciliary body and suspensory ligament of the lens, causing a partial paralysis of the ciliary

nerves ; it prevents the ciliary muscle from contracting, which, in turn, prevents a relaxation of the suspensory ligament, thus keeping the lens flat.

Changes in Refraction.—Glaucoma may occur in any condition of the refraction, although hypermetropes are more predisposed to it, and it is found in from 50 to 75 per cent. of the cases. Glaucoma may also cause hypermetropia from a flattening of the cornea and slight shortening of the antero-posterior diameter of the eye from the pressure.

Iridescent Vision.—The halo or rainbow of colors around a light is perfectly circular, and the size and breadth of each colored ring increases the further the light is from the eyes. The intensity of the colors vary with the light, the red being the brightest by gas or candlelight and the blue by electric light. The arrangement of the colors is always the same. There is, first, a colorless space surrounding the light ; the internal ring next to the colorless space is always the blue or bluish-green, while the outer ring is red. The generally-accepted explanation as to the cause of the halo is, that it is due to a diffraction of the rays entering the eye, as a result of the opacity in the cornea.

The Increased Tension.—To estimate increased hardness of the eyeball, the patient should be made to look downward and to gently close the eyes, for, if squeezed tightly together, that alone may slightly increase the tension. The index fingers of both hands should be applied to the lids (as there is not the same delicateness of touch between the first and second fingers of the same hand) and press gently first with one finger and then the other. Estimate according to the resistance or indentation of the globe. Tonometers or instruments devised for estimating the tension have been employed, but are hardly practical for general use. The following signs are in general use for designating the degree of the tension, viz. : T₀, tension normal ; T + ? or T - ?, a doubtful increase or decrease of tension ; T + 1, a marked increase as compared with normal ; T + 2, a great increase, but the globe admits of some dimpling ; T + 3, stony hardness, or no impression from firm pressure ; T - 1, a decrease as compared with normal ; T - 2, greater loss of tension, and T - 3, eye very soft—no tension at all. The tension differs physiologically in different eyes ; the sclera is more elastic in

young than in old people; a large eye yields more than a small one, and variations in the form of the eye affect the tension. Disease of the sclera might increase or decrease the tension. Variations in the curvature of the sclera at the point of impression, will cause a slight difference in the tension, the greater the curvature the softer the eye. The tension should always be estimated from palpation on the sclera some distance back of the cornea. The tension in glaucoma may vary at different times.

Haziness of the cornea is usually present in all forms of glaucoma, excepting in glaucoma simplex, when it may be absent. The haziness is uniform, but most intense at the centre, and often shows a dull, stippled appearance of the surface. Haziness of the cornea either disappears immediately or soon after the tension becomes normal again. The haziness is due to an œdema of the cornea, and its rapid disappearance on the return of normal tension is owing to the elasticity of the cornea. Other theories have been advanced to explain the haziness of the cornea, and, in those long-standing cases where the opacity is permanent, some other cause or change probably exists.

Anæsthesia of the cornea is found in almost all cases of chronic glaucoma, and is apt to be more complete at some points than others. This anæsthesia is explained by Fuchs as due to an increased amount of fluid in the nerve channels, causing a distention, and that the nerve fibres become paralyzed by the infiltration and pressure from this fluid, at some places, he has found the nerve fibres torn asunder.

Dilatation and Inactivity of the Pupil.—This is a very constant symptom of glaucoma. The pupil is often oval or egg-shaped, and, in this respect, differs from the dilatation in optic-nerve atrophy, when it is usually circular. The cause of the dilatation has been attributed to a paresis of the ciliary nerves from the pressure, and also, by some, to a constriction of the vessels of the iris. The irregularity of the dilatation is supposed to be due to a firmer attachment of the iris to the sclera at some points than at others.

The green reflex from the pupil is due to the bluish-white tinge from the haziness of the cornea and aqueous, combined with the physiological yellow tint of the nucleus of the lens caused by age.

Shallow Anterior Chamber.—This is due to a pushing forward of the lens and iris and in old cases to the peripheral adhesion of the iris

to the posterior surface of the cornea. It may be so shallow in some cases as to render an iridectomy very difficult.

The haziness of the humors is very slight and diffuse and is due to the increased amount of fluid within the eye.

Enlargement of the ciliary veins is due to the compression upon the venæ vorticosæ, causing a damming up of the blood, which has to pass off through the anterior ciliary veins.

Pulsation of the retinal veins may be physiological and is found in normal eyes. It is due to a transmission of the arterial wave through the vitreous, and is apparent at the papilla because the veins bend and are contracted at this point. The walls of the veins are thin and the pressure from the vitreous causes a momentary stoppage of the circulation until another arterial wave pushes the blood forward again. It is also noticed, in some instances, where an artery crosses a vein and the pulsation is then given direct to the vein. When absent, it may be owing to a hypertrophy of the walls of the artery, and, hence, no pulsation. As venous pulsation may be seen in normal eyes, it is not of especial diagnostic value.

Pulsation of the Retinal Arteries at the Disc.—There is, of course, a normal physiological pulsation of the arteries, but it is so slight as not to be seen in normal eyes, yet it may be produced by pressure upon the globe with the finger. It is so rarely seen under other circumstances that, when present, it is claimed by some to be almost pathognomonic of glaucoma. It is due to a resistance to the flow of blood, the current only being complete during systole. This resistance is caused by the increased intraocular pressure and possibly, as claimed by some, to an active spasmodic constriction of the vessels themselves. The absence of arterial pulsation in some cases is due to hypertrophy of the walls of the arteries.

The pain of glaucoma varies from a slight sense of fulness or dragging to a most severe acute neuralgia over the whole region supplied by the fifth nerve, and may be associated with general symptoms of pallor, fever, nausea and vomiting. The cause of the pain is pressure upon the nerves from the increased tension.

Swelling of the lids, chemosis and exophthalmos are all due to infiltration from the pressure.

Contraction of the field of vision is usually a loss of the inner or nasal side first, followed by a loss of the lower, then the upper part

of the field, showing an affection first of the temporal or outer half of the retina and then of the upper and lower quadrants. This order of retinal affection is due to the vascular distribution. The temporal portion of the retina being less freely supplied with vessels, it becomes first affected from the pressure obstructing its capillary circulation. There is, however, in glaucoma no absolute constancy in the manner in which the field is affected, as there may be concentric restriction of the entire field, or sectional defects, and even in some cases a central scotoma with the periphery of the field remaining good.

Excavation of the Optic Disc.—More or less cupping of the disc is met with sooner or later in all forms of glaucoma, but it bears no close relation to the loss of vision. It is the result of the intra-ocular pressure upon the lamina cribrosa, which becomes pushed backward, and, when complete, the vessels are pushed to the inner or nasal side, the veins are large and the arteries small, the vessels bend sharply over the edge of the disc, becoming lost to view and reappearing again at the bottom of the cup, and the disc itself appears of a grayish blue color. (See Fig. 12, Plate II.) Surrounding the papilla is a narrow, yellowish-white ring, due to atrophy of the choroid. By an examination with the indirect method we can determine by the parallax test slight degrees of excavation. This shows, upon moving the object lens from side to side, an apparent movement, the edges of the papilla seeming to slide back and forth over the centre. From this we know that the edge of the papilla lies nearer to the eye of the observer than its centre. The depth of the excavation can be approximately estimated by the direct examination, allowing 3 D. to every millimeter of depth.

It is important to distinguish the excavation of glaucoma from that occurring physiologically and from atrophy of the nerve. (See Fig. 2, Plate I., and Figs. 11 and 12, Plate II.)

The *physiological cup* is white and never involves very much of the nasal part of the disc over which the vessels can be seen to course. The vessels can always be followed down the side of the cup, which is funnel-shaped and not deep like the cup of glaucoma.

The *cup in atrophy of the nerve* is shallow and usually involves the whole of the disc. The vessels never bend sharply over its margins.

The cup of glaucoma is abrupt and deep, the vessels disappearing at its edge. There is a crowding of the vessels to the nasal side. It often has a greenish hue, and there is usually a yellowish choroidal ring around the papilla.


The impairment of vision varies considerably. In every acute attack it fails rapidly and then recovers somewhat when the symptoms subside, but each attack causes a little more destruction than the preceding one, until finally it becomes completely lost. The loss of vision is due to pressure upon the nerve elements of the retina and optic nerve, excepting in those cases where the loss of vision is sudden and complete, when it may result from an ischæmia of the retina.

Photopsia, or subjective sensations of light, is an inconstant symptom which may be present especially during attacks and may persist even after complete blindness and is probably due to a dragging upon the retina.

COURSE.—The history of a case of glaucoma will usually show a longer or shorter period of premonitory symptoms. This prodromal stage may have extended over several weeks or months, and then there will occur a sudden attack of acute glaucoma, lasting from a few hours to several days, when the symptoms subside and the eye returns to normal or nearly so. These attacks return, the intervals becoming shorter and shorter, the vision more and more impaired until finally it leads to a chronic or absolute glaucoma. In some cases an acute attack may continue directly into an absolute form without any subsidence of symptoms. Glaucoma does not lead to spontaneous cure, but tends, if unchecked, to absolute blindness.

CAUSES.—The statistics of glaucoma show it to form about one per cent. of all eye cases, varying, however, in different countries and different clinics. It is especially a disease of old age, some claiming that an attack of primary glaucoma under the age of thirty-five is extremely doubtful.

Sex seems to have little or no influence, and in some cases it seems to be hereditary. Hypermetropia predisposes to glaucoma, 50 to 75 per cent. of the cases being found in hypermetropic eyes. Neuralgia of the fifth nerve may cause it, as does also irritation from decayed teeth. Attacks are often precipitated by hysteria, convulsions, nervous excitement, anxiety, mental disturbances, anger,



fear, etc. Any condition causing vascular turgescence may cause it, as in gout, acute rheumatism, atheroma, climatic changes, intoxication, indigestion, fever, sleeplessness, etc. The use of atropine in some eyes will cause it. It has also occurred from sympathetic irritation from an iridectomy of the other eye.

Priestley Smith concludes, from a study of the immediate causes of increased intraocular tension, that it may result from three conditions, viz.: "Hypersecretion by the ciliary processes, serosity of the fluids and obstruction at the filtration angle."

Hypersecretion may be expected from irritation of the fifth nerve or from dilatation of the ciliary vessels, and, while these conditions may serve to act as an exciting cause, he considers it a pure hypothesis.

The serosity of the intracocular fluids is probably a supplementary cause of increased tension, for, whenever the circulation of the blood is obstructed, serum is apt to escape from the capillaries. In a mild form of serous inflammation of the uveal tract there is a serous exudation, the aqueous is cloudy, punctate spots on the posterior surface of the cornea, dilated pupil and an increased tension, which may result in glaucoma from the serous nature of the intraocular fluids.

To an obstruction in excretion he chiefly attributes the cause of increased intraocular pressure. This obstruction at the iritic angle in glaucoma was first demonstrated by Knies¹ and Weber² in 1876. Since then Priestley Smith has examined over eighty eyes having had various varieties of glaucoma and found obstruction of the filtration angle in all but three or four. As predisposing causes to this obstruction he considers the rigidity of the sclera that increases with age and the extra rigidity of the sclera found in Jews (who as a race are found to have a greater liability to glaucoma) one factor in the causation of glaucoma. The smallness of the eye, as demonstrated in the Egyptians, who, as a race, have small eyes and are especially prone to glaucoma, may be considered another feature. The increasing size of the lens in age, as demonstrated by him, seems, however, to be the most important predisposing factor in the causation of obstruction at the iritic angle with resulting glaucoma. His measurements

¹ von Graefe's Archiv., vol. xxii., 3.

² von Graefe's Archiv., vol., xxiii., 1.

further show that a small cornea belongs to a small eye, that the horizontal diameter of the cornea in glaucomatous eyes is less than that in healthy eyes, and that the size of the lens in small eyes is not proportionately small. The increase of the size of the lens in age without proportionate increase in the other structures of the eye causes it to encroach upon the surrounding parts; its margins press upon the ciliary processes, its anterior surface approaches nearer the cornea and in this way the depth of the anterior chamber is decreased. Priestley Smith summarizes as follows:

“The causes of primary glaucoma, then, are various and complex, and are not yet completely known; but they are alike in this—they all lead to compression of the filtration-angle. With that compression the actual glaucoma process begins. The escape of fluid is retarded and the intraocular pressure rises; this, in its turn, increases the compression of the filtration-angle. The fluid which still exudes from the turgid ciliary body is albuminous and less diffusible than the normal secretion; it tends to accumulate behind the lens, and this latter, being pressed forward, intensifies the mischief. Thus cause and effect react upon each other in a vicious circle.”

The causes of secondary glaucoma are those of some previous disease of the eye which obstructs the excretion.

Annular posterior synechiæ, by partially or totally obstructing the passage of the fluids from the posterior to the anterior chambers, causes glaucoma because the secretion going on, the iris becomes pushed forward and closing up the filtration-angle increased tension sets in. Iridectomy may be advisable in annular synechiæ to prevent glaucoma.

Anterior synechiæ, from some perforating wound or ulcer of the cornea, causes an insufficient access to the filtration-angle.

Dislocation and injuries of the lens will often be the cause of glaucoma. When dislocated into the anterior chamber it causes a stoppage of the filtration-angle, a lateral dislocation causes by pressing forward the iris and ciliary processes. An injury of the lens by the keratome in iridectomy, needling of a soft cataract, or penetrating wounds of the eye injuring the lens, causes swelling with pressure upon the iris and glaucoma. The lens should be immediately removed in these cases. Glaucoma occurs in some cases after extraction of the lens and also after discission for secondary cataract.

Intraocular tumors and hæmorrhages also cause increased tension. In serous exudations from the uveal tract glaucoma results from diminished filtration power of the fluids. Glaucoma has also been seen in eyes with a detached retina.

DIAGNOSIS.—The importance of an early diagnosis in this disease cannot be over-estimated, and, in all cases, the chief symptoms to be looked for are the enlarged ciliary veins, anæsthesia and haziness of the cornea, irregularity of the pupil, contraction of the field of vision, pulsation of the retinal arteries, cupping of the optic disc and increased tension.

Acute glaucoma has frequently been mistaken for iritis, and in some cases the differential diagnosis, which practically rests upon the increased tension and dilatation of the pupil in glaucoma, is extremely difficult. The inflammatory symptoms of both give the same appearance, the fundus is often not to be seen in either, there may be haziness of the cornea in both, and the iridescent vision may occur in iritis as well as glaucoma. Add to this the fact that the two diseases may occur at the same age, that Atropia may have been used in the eye with partial dilatation of the pupil and the difficulty to accurately determine the tension in an acutely inflamed eye may render the differential diagnosis extremely uncertain. The two diseases may even exist together.

Glaucoma simplex and optic nerve atrophy are, according to Schweigger,¹ often mistaken for each other. The essential diagnostic point seeming to rest upon a comparison of the field of vision in the two diseases, which would, of course, be aided by the presence of any or all of the following symptoms of glaucoma: The history, haloes, pain, increased tension, more rapid progress, depth of the cup and arterial pulsation. The peripheral color sense is not so markedly defective in glaucoma as in atrophy. We have also seen cases where the failing vision has been attributed to cataract, but the mistake could hardly be made by any careful observer. Other cases we have seen attributed to a cold in the eye, the pain said to be neuralgia, and instillations of Atropia used. This inexcusable error could not have been made had the tension of the eye been examined.

PROGNOSIS.—In all forms of glaucoma the prognosis is always bad, if the disease is allowed to follow its own course, as blindness

¹ Archiv. Ophthal., vol. xx., 4, 1891.

inevitably results sooner or latter. When, however, the proper treatment is undertaken, the prognosis may be said to be favorable in all forms excepting the absolute or hæmorrhagic glaucoma; that is, the further progress of the disease can be stopped and vision, as a rule, preserved where it is without further loss, and in many cases of acute glaucoma, where the disease has been of but a short duration, there may be complete restoration of sight after an iridectomy.

Varieties of Glaucoma.—This disease may be divided into two general classes; *primary glaucoma*, which arises without previous disease of the eye, and *secondary glaucoma*, or that form in which we can see some previous disease of the eye to account for the glaucoma.

Glaucoma Acuta.—Usually the patient has had warning of impending danger in the way of certain *premonitory symptoms*—due to an increased tension and not to inflammation. There is premature recession of the near point. This impairment of the accommodation, where the patient is unable to use his ordinary glasses, but keeps changing every little while for stronger and stronger ones, is always suggestive of glaucoma. He complains also of having noticed a periodic dimness of vision, as though clouds of smoke were coming before the eyes from time to time. There is seen a rainbow of colors encircling a light, and, upon examination of the eye at this time, there will be detected a slight increase of the tension, the pupil is dilated and sluggish, the field of vision may be contracted and there may be a hyperæmia of the retina. This condition may have existed for a longer or shorter period, when suddenly there comes on an attack of acute glaucoma. The onset is apt to occur during the night and sets in with severe pain in the eye and head, which increases in severity and is often accompanied by vomiting, fever and general prostration. These attacks are usually brought on by some sudden excitement or grief. Upon examination of the eyes we may find any or all of the following symptoms: The lids are swollen and may be œdematous; conjunctiva inflamed, possibly chemosed; scleral vessels injected, eyeball protruded, lachrymation, photophobia, cornea hazy and may have lost its sensitiveness to touch, iris discolored, pupils dilated and sluggish, greenish reflex from the pupils, aqueous cloudy and anterior chamber shallow. There is intense pain in the eye and head, *the eyeball is hard*, the vision im-

paired and the field contracted. Ophthalmoscopic examination is often unsatisfactory on account of the haziness and general inflammation of the eye; but, if possible, there may be seen an excavation of the optic disc, the retinal arteries are small and pulsate, the retinal veins enlarged and there may be slight extravasations of blood.

An attack of acute glaucoma may last a few hours, or two or three days, when the symptoms will gradually subside, the vision return and the eye becomes normal again. These attacks usually follow one another, the intervals growing less and less, until it finally passes into what is called chronic or absolute glaucoma. In some cases the first attack will be of unusual severity, in which the vision does not return, the tension does not decrease and the dullness of the cornea persists. These cases are called *glaucoma fulminans*. The cupping of the optic nerve is frequently not present in an attack of acute glaucoma. The impairment of the vision may mean that it is reduced to the faintest glimmer of light, which De Wecker says is due to ischæmia of the retina. The pain in acute glaucoma is often so intense that the patient may ignore a complete loss of vision and demand relief for his neuralgia, and in this way often mislead the physician.

Glaucoma Chronica.—This form may develop from an acute attack, or directly from the premonitory stages. In fact, it generally does not amount to an actual attack, but develops gradually the symptoms of the acute, irritation being absent.

Among its symptoms we find the anterior ciliary veins enlarged and tortuous, the sclerotic has a dull, leaden hue, the cornea is hazy and loses its sensitiveness to touch, the pupil is large and inactive, the iris is discolored and becomes atrophied, the anterior chamber is shallow, the tension is increased, may be $+ 3$. An ophthalmoscopic examination shows an excavation of the optic disc, the retinal veins large and the arteries small and pulsate. There is a progressive failure of sight, the field becomes more and more contracted and the halo around the light is seen. The pain in chronic glaucoma varies. If the disease has come on gradually it may be entirely absent, though rarely so, and in other cases it may be severe. There may be a remission of the symptoms in some cases, or they may continue all the time, but become increased from nervous excitement. Chronic glaucoma gradually leads on to absolute.

Glaucoma Simplex.—This is considered by those who claim glaucoma to be a non-inflammatory disease to be the most characteristic form, as in this variety of glaucoma there are no inflammatory symptoms. We will simply find an increased tension which may vary at different times, the pupil dilated and sluggish, though, as a rule, not so much so as in acute or chronic. The vision is impaired and the field contracted, there is no pain, haziness of the cornea or injection of the anterior ciliary vessels. With the ophthalmoscope there is seen an excavation of the optic disc, some choroidal atrophy around the disc and displacement of the retinal vessels. The characteristic signs of glaucoma simplex are the increased tension, excavation of the disc and the regularity with which the pressure acts upon the circulation of the retina, first limiting and then abolishing the field of vision. Spontaneous pulsation of retinal arteries is not usually seen in this form of glaucoma, although a slight pressure on the globe with the fingers will usually produce pulsation by checking the regular flow of blood. In the excavation of the disc in glaucoma the edge of the disc overhangs so that the vessels wholly or partially disappear from view as they pass over the margin of the disc, and some claim they are always displaced toward the inner side and believe that in any excavation where the vessels are not so displaced the cupping is not the result of glaucoma. The choroid around the excavated disc in glaucoma may be detached by the pressure, often presenting the appearance of posterior staphyloma. Glaucoma simplex is usually chronic in form and generally terminates in absolute.

Glaucoma Hæmorrhagica.—This may be considered a primary glaucoma when associated with hæmorrhage, or secondary when it is caused by hæmorrhage. The symptoms are the same as those already detailed under acute or chronic forms, plus the greater tendency to hæmorrhage on account of the degeneration of the vessels. The hæmorrhage occurs especially from the retinal vessels. Varicose and aneurismal dilatations, together with changes in the walls of the retinal vessels, have been frequently found. Sudden relaxation of the tension by an iridectomy has often resulted in a serious intraocular hæmorrhage, causing destruction of the eye. The pain in this form of glaucoma, when there may be but even a slight increase of the tension, is often unbearable and frequently necessitates

enucleation. In many cases the hæmorrhage is the cause of the outbreak of acute symptoms when there were no glaucomatous signs before. Hæmorrhagic glaucoma generally affects but one eye.

Glaucoma Absolutum.—By this we mean a glaucoma that has run its course, or all cases that have resulted in a total loss of sight. The results vary somewhat, whether due to acute or chronic, or simple glaucoma.

Result of acute or chronic glaucoma.—In this the anterior ciliary vessels are large and dark, especially at the recti muscles; the conjunctiva is thinned, the sclera pale, the cornea rough, hazy and not sensitive to touch; the pupil is dilated to a mere rim, which is in contact with the cornea; the lens is cataractous and pushed forward near to the cornea, the pain often continues severe and the patient has the subjective symptoms of photopsies and chromopsies.

Result of glaucoma simplex.—In these cases the eyeball will usually appear healthy and may be free from pain, but there is extreme hardness of the ball, excavation of the disc, choroidal atrophy around the disc, arteries contracted, anterior chamber shallow, pupil dilated (may be contracted) and vision entirely lost. An eye may remain in this condition for years or pass into degenerative changes at any time.

In the last stages of an absolute glaucoma from any form, the eyeball may enlarge, cornea flatten and sclera bulge. This process is accompanied by severe pain until finally the eyeball ruptures and passes over into atrophy. Another change is where the eyeball shrinks, the secretion all the time growing less, the tension becomes minus and atrophy ensues. This last change may or may not be accompanied with pain and inflammatory attacks may occur.

Glaucoma Consecutiva.—The preceding forms of glaucoma have resulted from a loss of balance between secretion and excretion in previously healthy eyes, that is, due to either an increased secretion or an obstructed excretion in eyes in which there was no other apparent disease. In this there is a similar disturbance in eyes showing other diseased conditions. All affections of the eye become glaucomatous when, with other symptoms, there is an increase in the tension. The symptoms, then, of secondary glaucoma are increased tension, which may be the only symptom. The accommodation and refraction may be impaired, but, as a rule, the other dis-

eases of the eye will hide this. The vision is impaired; may have iridescent vision; the field is contracted, more or less severe pain, anterior chamber shallow, pupil dilated, if not bound down by posterior synechiæ from other disease. There is marked dilatation of the episcleral vessels and cupping of the disc. Often there are changes in the form of the globe and the condition terminates in atrophy, as in glaucoma absolutum.

TREATMENT.—This should vary according to the stage of the disease; taken in the premonitory stage where the patient suffers from only occasional attacks of temporary blindness, pain, etc., while in the interval the vision is good, we may look for benefit from the use of remedies. The only local remedy to be considered is either the sulphate or salicylate of eserine, which is usually employed in the strength of a half per cent. solution and may be instilled into the eye as often as every hour or even oftener, and should in itself speedily cut short an attack. Even in some cases of acute glaucoma, if used early and often, the necessity of an operation may be postponed, if not permanently avoided. In all cases the use of eserine should be early, *very early*, hence we believe it best in cases once having had a premonitory attack, that the patient should be supplied with the eserine with directions as to its use that no time should be lost. The action of the eserine is to cause contraction of the iris and in this way it is drawn away from the iritic angle and the filtration passages opened; it also, by constriction of the vascular system of the eye, diminishes secretion. Mydriatics, especially atropine, must be avoided, as they are liable to cause an acute attack of glaucoma.

Iridectomy.—The introduction of this operation for the relief of glaucoma was empirically made by von Graefe, in 1857, and is still *the* operation for this disease. Iridectomy has been the means of saving useful vision in thousands of patients who would otherwise have been hopelessly blind. While iridectomy is the most valuable remedial agency extant for this disease, still it is not infallible, as in some cases or forms of glaucoma even this operation will not check the disease. In operating, the previous use of eserine is advisable, as it renders less liable accidents from sudden relief of the tension, and it has also been advised by Arlt and others that it be used in the sound eye as well, for the mental anxiety caused from

the dread of an operation has been considered not infrequently to have been the cause of an attack in the good eye. Ether should, as a rule, be used in this operation, as thorough anæsthesia cannot be obtained from cocaine in a glaucomatous eye. The incision should be made entirely in the sclera, the iridectomy large and care taken that the escape of the aqueous be very gradual and that no remnants of the iris remain in the wound.

Sclerotomy has been strongly advocated by DeWecker, but it has not seemed to have met with the hearty support of the other authorities. In certain cases, especially the hæmorrhagic form of glaucoma, sclerotomy may with advantage take the place of iridectomy. The writer has had the best of results from this operation in a few instances. Other operative procedures have been suggested for the relief of glaucoma but thus far have not proved worthy of notice.

In the premonitory stage, as has already been said, our endeavor should be to cure by the aid of internal medication, which may be done in many cases if we take into consideration the constitutional disturbances which are associated with or cause the intra-ocular trouble. The habits of our patient should receive careful attention. The excessive use of stimulants (either alcohol or tobacco) or any exhaustive mental or physical labor must be strictly forbidden. Only moderate use of the eyes should be allowed, and, during the attacks, or when they follow each other in rapid succession, complete rest is necessary. Bright light, either natural or artificial, should be avoided, or the eyes protected by colored glasses. The diet should be good and nutritious, particularly in elderly persons, and all indigestible substances forbidden.

The results from the use of internal remedies in glaucoma seem to me somewhat problematical, chiefly because the reports of cases cured by remedies alone seem sufficiently unreliable to warrant a question as to the diagnosis. In the majority of cases recorded, where no operation was made, the local use of eserine was employed as well as the remedy, and in consequence it is unscientific to give the credit to the remedy alone.

Aconite may be of service at the commencement of an acute attack when we have much heat, redness and burning pain in the eye, together with fever and other symptoms of the drug generally.

Asafœtida.—Glaucoma, with severe, *boring pain over the eye*, and around it.

Belladonna.—Of benefit in relieving the severe pains of glaucoma, especially if accompanied by throbbing headache and flushed face. The eyes are injected, pupils dilated, fundus hyperæmic and pain both in and around the eye. The pains are usually severe and throbbing; may come and go suddenly and are *worse in the afternoon and evening*. The eyes are hot and dry, with *sensitiveness to light*. Halo around the light, red predominating. Photophobia.

Bryonia.—From its value in serous inflammations in general, this remedy has been given with benefit in glaucoma. It is more often indicated in the prodromal stage. The eyes feel full, as if pressed out, often associated with sharp, shooting pains through the eye and head. *The eyes feel sore to touch and on moving them in any direction*. There may be a halo around the light, with heavy pain over the eye, worse at night. The usual concomitant symptoms will decide us in its selection.

Cedron.—For the relief of the pains of glaucoma, when they are severe and *shooting along the course of the supra-orbital nerve*.

Colocynth.—Of service in relieving the pains of glaucoma when they are severe, burning, aching, sticking or *cutting* in character in the eye and around, always *relieved by firm pressure* and by walking in a warm room; aggravated by rest at night and upon stooping.

Gelsemium.—Is one of our principal remedies in this disease and is, perhaps, more frequently used than any other. There seems to be no especially characteristic symptoms upon which it is given, hence we come to the conclusion that its use has depended upon the fact that clinically it has proven its value.

Nux vom.—Indicated if the *morning aggravation* is very marked and for the resulting atrophy of the optic nerve.

Osmium.—This remedy has proven of value in the hands of some, and from its symptoms should be given a more thorough trial. It has sudden, sharp, severe pains in and around the eye. Dimness of vision, objects seen in a fog. Halo of various colors around a light.

Phosphorus.—Of great importance in improving vision and removing many subjective symptoms after iridectomy. Fundus hyperæmic and hazy, halo around the light, and various lights and colors (especially red) before the eye. Sensation as if something was

pulled tightly over the eyes. Vision impaired, better in the twilight.

Prunus spin.—*Pain severe, crushing, in the eye, as if the eye were pressed asunder, or sharp, shooting through the eye and corresponding side of the head (Spig.)* Aqueous and vitreous hazy, fundus hyperæmic.

Rhododendron.—*Incipient glaucoma, with much pain in and around the eye, periodic in character and always worse just before a storm, ameliorated after the storm commences.*

Spigelia.—*Pains sharp and stabbing through the eye and head, worse on motion and at night.*

Our range of drugs will be extensive in this affection, as we must take into consideration all the general symptoms to make a sure prescription. The above remedies have been most often called for in the cases we have met, though the following may be found useful: Arn., Ars., Aur., Cham., Con., Crot. tig., Ham. v. Kali iod., Macrotin, Merc. and Sulph.

PART II.

THE

OPHTHALMIC THERAPEUTICS.

OPHTHALMIC THERAPEUTICS.

ACETIC ACID.

Clinical.—The benefit obtained from Acet. ac. in croupous inflammation of the air-passages led to its use in croupous conjunctivitis. Though empirically prescribed at first, it has proved of decided value in certain forms of this inflammation. It is adapted to those cases in which *the false membrane is dense, yellowish-white, tough and so closely adherent* that removal is almost impossible; thus differing from Kali bichr., in which the membrane is loosely attached, easily rolled up and separated in shreds or strings. The lids are œdematously swollen and red, especially the upper, which hangs down over the lower. It does not seem to correspond to the diphtheritic form of conjunctivitis, for, though the false membrane is closely adherent, it does not extend deeply into the conjunctival tissue—no scars remaining after resolution—and at no time is there firm, rigid infiltration of the lids. Little or no benefit can be derived from its use if the discharge is profuse and purulent, mixed with small portions of the membrane, or if the cornea has become involved.

Compare Arg. nitr., Pulsat. and Hepar.

ACONITE.

Objective.—*The lids (especially the upper) are swollen, red and hard, with a tight feeling; worse mornings. Edges of lids sore, red and inflamed. Eyes brighter than usual. Pupils dilated. The conjunctiva is intensely hyperœmic and œdematous, mostly toward the inner canthus. Inflammation extremely painful, so that one may wish to die. Lachrymation with local inflammations is usually slight, if any.*

Subjective.—In the lids, *dryness, burning, sensitiveness to air.* Pressure into the upper lids, as if the whole ball were pushed into

the orbit, causing a bruised pain in the eye; itching, smarting, *burning in the eyes*, especially worse in the evening. Sticking and tearing pains around the eyes, worse at night. The eye is generally sensitive, with *much heat, burning and aching*, worse on looking down or turning the eyes; feeling as if the eyes were swollen, or as if sand was in them. The ball, especially the upper half, is sensitive if moved; feeling as if it would be forced out of the orbit, relieved on stooping; the ball feels enlarged, as if protruding and making the lids tense. Sparks before the eyes, flickering. Vision as through a veil; it is difficult to distinguish faces, anxiety and vertigo. Photophobia.

Clinical.—Aconite is the remedy for inflammations of the eye in general, which are very painful, with *heat and burning*, as well as dryness; also for inflammatory conditions *resulting from injuries*, ranging from those of a most severe character, as when all the tissues of the globe have been injured by a perforating wound, to those dependent upon the irritant action of foreign bodies in the cornea or conjunctiva, or the irritation caused by ingrowing lashes. Sometimes it is indicated in acute inflammation of the lids or lachrymal sac, though not as frequently as some other remedies.

The verifications of this drug in the following forms of inflammation of the conjunctiva are every-day occurrences; *Catarrhal inflammation* (first stage, prior to exudation), marked by great redness, heat, burning and pain; chemosis, with pain so terrible that patient wishes to die. Early in purulent inflammation, as illustrated in the case of a child with following conditions: Lids red and swollen; intense redness of conjunctiva and chemosis, worse in the right eye; much purulent discharge, with heat and sticking pains; aggravated in the morning. Under Aconite^s, with ice externally, a rapid cure resulted.

Acute aggravations of granular lids and pannus, with excessive hyperæmia, heat and dryness, especially if the aggravation be induced by overheating, from violent exercise, or by exposure to dry, cold air.

Affections of the cornea seldom require its use, except when of traumatic origin, although one case of superficial ulceration of the cornea in a woman fifty years of age which had been present ten days, with burning heat in the eye and sharp pain on looking at the

light or reading, was quickly relieved under Aconite³, after Hepar had failed.

Benefit may be derived in the acute stage of scleritis, with contracted pupils, sticking or tearing pains, photophobia, blue circle around the cornea and aching in the ball. (Compare Spig.)

For *traumatic* iritis Aconite is one of the first remedies to be thought of. It may also be required in simple plastic iritis when caused by exposure to cold, or in recurrent iritis as shown in the following case: A lady, æt. 42, had, in both eyes, quite extensive posterior synechiæ resulting from an iritis eighteen years previous. One week before the doctor saw her she was attacked with severe neuralgia, especially in right side of head. Twenty-four hours later the right eye became tender to touch and very painful, lachrymation profuse and hot, pericorneal and conjunctival injection; pupil dilated sluggishly and irregularly under the action of Atropine; face flushed. Rhus tox. and afterwards Merc. corr. were given without avail. Aconite³ gave almost immediate relief, and in ten days the patient was well. For one and a half years she had occasional attacks, which became less frequent, and the trouble finally disappeared under the influence of Aconite. During some attacks both eyes were affected, but the right was much worse than the left. (Atropine was used.)—W. P. FOWLER.

Of use in the earlier stages of violent acute inflammation of the deep structures of the ball, when it becomes sensitive to touch and feels as if it were protruding (rarely, if ever, called for after the exudative stage is reached).

The following case illustrates the good effects of Aconite in asthenopia: A middle-aged man was employed to sort railroad tickets, to run through columns of figures and do other fine work by a dim light; in eight days he began to have a spasmodic closure of the lids and heavy feeling over the eyes; then his eyes would get very hot—"felt as though they could set a match on fire," or as after a lash with a whip. The conjunctiva of the lids was intensely red, with constant winking and closing of the lids; could hardly force them open. The heat was always dry and temporarily relieved by cloths wet in cold water; vision normal; refraction normal. Aconite relieved these symptoms magically and allowed the man to continue

his work (which he was obliged to do) till time enabled him to change his occupation.—T. F. A.

In a case of paralysis of the ciliary muscle of one day's standing, caused by sleeping near an open window, the accommodation was wholly restored within forty-eight hours after using Aconite³⁰.

AGARICUS.

Objective.—The lids are half-closed, swollen, especially toward the inner canthus; ptosis, *twitchings of the lids*, with contracted *fissura palpebrarum*, without swelling. Twitchings of the ball, often painful; twitching of the ball while reading (especially the left); very little appearance of inflammatory action.

Subjective.—Pressure and heaviness in the eyes, especially painful on moving them or exerting them by lamp-light, with left-sided headache and involuntary twitching of the facial muscles. Yellow spots before the vision when looking at white. Vanishing of sight suddenly when in open air. The bitings, itchings and jerkings about the brow and in the lids are very numerous in the provings. In the eyeball the sensations are mostly pressive and aching; the ball is sensitive to touch. Vision dim, as through a veil, with flickering; reads with difficulty, as the type seems to move. Short-sightedness. Beating in vertex driving almost to despair. Headache with chorea. Tearing in the head.

Clinical.—Agaricus is of the greatest service in spasmodic affections of the lids and muscles of the ball. Its value can hardly be overestimated in *morbid nictitation* or chorea-like spasms of the lids, with general heaviness of them, especially if the *spasms occur on waking*, or are relieved temporarily by washing with cold water. Four drop doses of the tincture, two or three times a day, will often relieve when the higher attenuations have no effect.

Dr. Linnell reports a case of lagophthalmos of the left eyelid with paralysis of the same side of the head. There was marked twitching of the eyelids on the unaffected or right side, together with right trigeminal neuralgia. These symptoms which had existed for one year were promptly cured by Agaricus.

An interesting case of anæmia of the optic nerve, retina and choroid, with general tendency to chorea, has been cured by this drug.—T. F. A.

Benefit has been obtained from Agaricus in myopia dependent upon spasms of the ciliary muscle, especially if complicated with twitchings of the lids.

Its usefulness in nystagmus is illustrated by the following case: A school girl, at 14, was unable to read, owing to spasms of the orbicularis and oscillation of the globes. The motion was circulatory in both eyes and continual, whether eyes were fixed at near or far points; it caused much pain, indistinctness of vision and occasional attacks of vertigo. In three months' treatment with Agaricus, 3d trit., a powder three times daily and gymnastic exercises of the ocular muscles, the globes were so far controlled as to cease oscillating when the vision was fixed upon near objects. Improvement continued.—W. H. WINSLOW.

That its action upon the muscles is not confined to spasm is shown in the following case of weakness of the internal recti: A lady suffered from muscular asthenopia consequent upon uterine disorders and spinal anæmia. The spine was very sensitive to touch between the shoulders. She could not fix the eyes long even upon distant objects; could not converge the eyes (weak internal recti). She had sudden jerks in the ball itself; twitches of the lids and at times in other parts of the body; the lids seemed heavy, as if stuck together, but were not; she had been given prisms (which, allowed binocular vision without effort) and had been under various forms of general and local treatment. After Agaricus the change was marvellous; within a week the eyes could be fixed on objects at ten feet without conscious effort; the unpleasant sensations had entirely vanished and the patient was enabled to begin systematic gymnastics for the eye (initiated by fixing the eyes on a white object while it is moved slowly right and left). The eyes have steadily improved, but the old pain returned in the spine; relieved only temporarily by applications of cold water.—T. F. A.

ALLIUM CEPA.

Lachrymation excessive, especially of the left eye, with redness of the eyeball after frequent sneezing. *Lachrymation (not excoriating) with coryza.* The lachrymation is for the most part in the evening in a warm room, the left eye weeps more and is more sensitive to the light. Sensation as if something were under the lid, which causes a gush of tears to wash it out.

Clinical.—Of use in acute catarrhal conjunctivitis, associated with a similar condition of the air-passages, as in hay-fever; the lachrymation is not excoriating, though the nasal discharge is (reverse of *Euphrasia*). Dr. Liebold first recommended this drug in five drop doses of the tincture for ciliary neuralgia after cataract extraction. G. S. N. reports a case of irido-choroiditis in a young man somewhat subject to iritis. The inflammation began in the iris with the usual symptoms and, although the pupil was kept dilated with atropine, the inflammation progressed until the chemosis became excessive, the eyeball very sensitive to touch, the aqueous and vitreous so clouded that the fundus could not be seen, the vision was lost and the pain in the eye extending to the whole head, worse on the right side and aggravated at night, became almost beyond control. His nerves were completely shattered from pain and loss of sleep and it was feared that the eye was lost. *Allium cepa* was given in five-drop doses with most rapid relief of the pain. It also seemed to exercise a favorable influence upon the inflammation, so that under this drug and *Rhus* the patient made a rapid recovery with complete restoration of vision.

ALUMEN EXSICCATUM.

Clinical.—This substance, first recommended by Dr. Liebold, has been employed with great benefit in *trachoma*, by dusting the crude powder upon the inner surface of the lids, allowing it to remain about a minute, more or less, and then washing off with pure water. At the same time the lower preparations are given internally. As a saturated solution in glycerine it may also be used with great benefit in *trachoma* and *pannus*.

ALUMINA.

Objective.—The upper lids are weak, seem to hang down as if paralyzed, especially the left lid; the lashes fall out; small pimples or incipient styes on the lids. Twitching of the lids, especially right upper. Redness and inflammation of conjunctiva, worse in right eye and aggravated in the evening. Lachrymation, hot or even acrid, may be present, but absence of lachrymation predominates. Squinting of the eyes.

Subjective.—Burning and dryness in the lids every evening,

with pain in the internal canthus of left eye and much dry mucus in the morning on waking; morning agglutination; the eyes burn on being opened, with photophobia; itching in the canthi; dryness and excoriation in the internal canthi. In the eye in general the sensations are: Burning; burning dryness; burning on waking, especially on looking up; pressure on the eyes, cannot open them; also photophobia.

Vision.—Dim vision, which obliges her to wipe her eyes continually, thus giving relief, with a sensation as if the lids would adhere in the corners; dim vision, as through a fog, or as if hairs or feathers were before the eyes. In the evening the vision is dim and eyes dry, so that she cannot use them.

Clinical.—Alumina is indicated in chronic inflammation of the lids in which there is dryness and smarting without much destruction of tissue (ulceration) and without great thickening of the lids.

Nictitation, dependent upon enlarged papillæ of the conjunctiva, has been relieved.—J. H. BUFFUM.

Some cases of chronic granular lids, or loss of power in the upper lids, met with in old, dry cases of granulations, yield only to this drug. The evening-dryness and dimness of the eyes, with inability to use them, have been verified in cases of chronic dry catarrh.

Dr. A. Wanstall recommends Alumina very highly for both acute and chronic catarrhal conjunctivitis, especially the latter, and sends me this case illustrating its action: Miss A., æt. 18, artist, for a year or more has been unable to use her eyes at night. *Hm.* $\frac{1}{30}$. Eyes inflame after using; palpebral conjunctiva especially inflamed, with rough appearance on lower lids (follicular); dry scurfs on lashes. The patient declined to wear glasses. Alumina was prescribed, and in one week she reported: "I can now read with more ease at night," and in six weeks she was entirely cured. A slight relapse eighteen months later was speedily relieved by the same remedy.

Alumina should be one of our most important remedies for loss of power of the internal recti (compare Conium and Natr. mur.) and for paralytic squint.

AMMONIUM CARBONICUM.

Eyes weak and watery, especially after reading. A large black spot floats before vision after sewing.

Clinical.—Ammon. carb. is especially serviceable in cases of muscular asthenopia from overstraining the eyes by prolonged sewing, etc. (Compare Ruta, Natr. mur.).

AMYL NITRITE.

Under the ophthalmoscope the veins of the disc were seen to become enlarged, varicose and tortuous; the arteries small, but not abnormally so; conjunctiva bloodshot; protruding, staring eyes; sight hazy; stupefaction; dull, heavy pressure over the eyes, as if a heavy weight were within.

Clinical.—Amyl nitr. is one of the two remedies most frequently indicated in a form of ciliary neuralgia with acute conjunctivitis dependent upon disturbances in the vaso-motor system. Its sphere of action is illustrated in the following case: Patrick A., 23 years of age; left eye had been inflamed three weeks before he was seen. For two weeks the pain had been quite severe, very sharp in character and extending through the left eye to the back of the head; always worse at night; the conjunctiva was very red with deep ciliary injection; the pupil was contracted, but could be dilated regularly, though slowly, by Atropine. He was treated as an out-patient for five days, with Atropine externally and Merc. protiod. or Merc. corr. internally. As he appeared to be growing worse he was taken into the New York Ophthalmic Hospital, put to bed, a cotton pad applied to the eye, Atropine instilled and Bryon.³⁰ given internally. Only slight temporary relief seemed to follow the use of the Bryon., and various remedies were given for three weeks with no permanent benefit. Terebinth. cleared up the urine, which at one time was quite dark, though it produced no change in the eye. Cedron gave relief from pain for several days, but nothing permanent. As no benefit was obtained from Atropine and no tendency to adhesion of iris to lens was observed, its use was discontinued. It was noticed that when the Atropine was stopped for only a few hours the pupil would rapidly contract. The tension was frequently tested and found to vary, even in a short time, sometimes being greatly diminished and again normal. Most of the time, however, it was decreased; vision hazy. The left side of the face was flushed, and its temperature higher than the right; tongue coated and appetite poor. Amyl nitr.³⁰ was then given. Amelioration of the pains

was noticed within twenty-four hours, while the redness of the eye and the other abnormal symptoms began gradually to disappear. In a week he was discharged cured.

This drug has been found of great service in some cases of exophthalmic goitre, one case of which has been completely cured by the olfaction of Amyl nitr. alone.—T. F. A.

Embolism of the central artery of the retina has been reported as cured by the olfaction of the Nitrite of Amyl.

ANTIMONIUM CRUDUM.

Small humid spots in the external canthus which are very painful if sweat touches them; mucus in the canthi mornings with dry crusts on the lids. Eyes red and inflamed, with itching and agglutination nights and photophobia mornings; lids red with fine stitches in eyeballs. Itching in the canthi.

Clinical.—This drug has cured, or assisted in curing, some obstinate cases of *blepharitis* in which the lids have been inflamed, swollen and moist, with pustules on the face; especially when occurring in cross, peevish children. (Compare Graphites.)

Marked success has been observed by Dr. Wanstall from the use of this remedy in scrofulous ophthalmia characterized by pustules on the cornea or conjunctiva, with profuse mucous discharge and lachrymation; lids swollen, red, excoriated and bathed in the secretions; accompanying which will be found pustular eruptions on the face, moist eruptions about and on the ears, soreness of anterior nares, swollen upper lip, etc.

APIS MEL.

Objective.—*Lids much swollen, red and œdematous; often everted; the upper lid hangs like a sac over the eye.* Erysipelas of the lids; they are dark bluish-red and so swollen as to close the eye, following severe pains; the swelling extends around the eyes and down over the cheek. The conjunctiva becomes congested, puffy, œdematous and full of dark red veins. Lachrymation hot, spurts out of the eye. Lachrymation with burning in the eyes and with photophobia; with pains in the eyes on sewing, evenings; with pain on looking at bright objects; with severe burning and sensation of a foreign body in the eye.

Subjective.—Burning, *stinging* and sensation of swelling around the left eye in the superciliary ridge. Soreness of the lids and canthi, with agglutination; burning of the edges of the lids, causing lachrymation. Stinging or itching in the internal canthi, or smarting of edges of lids. *Stinging in the ball* and pain across the forehead; aching pressing in the lower part of the left eyeball. Fullness inside the ball, with flushed head and face. Violent shocking pains over the right eye extending down to eyeball. Smarting and sensation of burning in the eyes, with bright redness of the conjunctiva; very sensitive to light. *Stinging pains*; pains on sewing; most dreadful pains shoot through the eye in inflammations; pains throbbing and burning; pains aggravated on moving the eyes; photophobia; eyes pain and are easily fatigued on exertion.

Clinical.—The clinical record of this drug is important, verifying nearly all its symptoms. It is especially adapted to *cedematous conditions of the lids or conjunctiva*, particularly non-inflammatory; inflammations with burning, biting pains; inflammations following eruptive diseases; inflammations with severe shooting pains, heat of the head, red face, cold feet, etc.; erysipelatous inflammations of the lids, with adjacent smooth swelling of the face, especially with chemosis.

It is also indicated in various forms of blepharitis with thickening or swelling, such as incipient phlegmon, with great puffiness and stinging pains. The following case by Dr. C. R. Norton shows its use in acute inflammation of the lids: Lids much swollen, red and blue; cannot open them; lachrymation, much pain, restlessness at night, cold water gives great relief. Grew worse under Acon.³. Apis²⁰⁰ cured speedily. Chronic blepharitis with thickening of conjunctival layer, so that the lower lid is everted.

Ulceration of the margins of the lids and canthi with stinging pains may require this remedy.

Illustrative of its action in syphilitic ulceration of the lids is the following case: Mrs. H., æt. 42, for three months had suffered from ulceration of the lower lid of the right eye. The history of syphilis was clear. Massive doses of iodide of potassium had arrested an extensive ulceration of the soft palate, but the ulcers on the lid appeared immediately afterward. There were two ulcers; one ex-

tending from the inner canthus along the margin of the lid to the centre and the other, smaller, near the external canthus. They were dark red at the base with ragged edges; lids œdematously swollen and red. There was much pain of a sharp, stinging character. Merc. was given with no benefit; then Apis³, under which the pain almost immediately ceased, the swelling of the lids subsided and in three weeks the ulcers had entirely healed. No return of the difficulty to the present time, five years.—W. P. FOWLER.

Occasionally of service in acute catarrhal conjunctivitis, if there is bright redness of the conjunctiva and chemosis, with stinging pains; also in ophthalmia neonatorum, with great swelling of the lids and adjacent cellular tissue.

Various and severe forms of keratitis have been cured by Apis, although I believe its sphere of usefulness in diseases of the cornea is very limited. Keratitis, with dreadful pains shooting through the eyes, with swollen lids and conjunctiva, with photophobia and hot lachrymation gushing out on opening the eyes (see Rhus). Pustular keratitis with chemosis, dark red conjunctiva and swollen lids. Ulceration of the cornea, vascular, with photophobia, lachrymation and burning pain; lids everted and often ulcerated on the margin.

An interesting case under my care in the N. Y. Ophthalmic Hospital shows that Apis may be of service in parenchymatous keratitis: A boy, 11 years of age, was brought to me with the right cornea densely infiltrated, moderate redness and photophobia. Inflammation was just commencing in the left eye. The history of hereditary syphilis was tolerably clear. There was an exostosis on inferior maxilla; the joints were enlarged and painful, so that he could not walk; high fever and loss of appetite. He was taken into the hospital and several remedies given with no avail. Both corneæ became worse, were infiltrated and inflamed, until vision was nearly lost in both eyes. His fever also increased and was accompanied with drowsiness and thirstlessness. Apis¹ was given, with immediate relief of the drowsiness, fever and inflammatory symptoms of the eye. Under its influence the cornea began at once to clear and a complete cure was the final result.

A case of hydrops retinæ, with pressive pain in the lower part of the ball, with flushed face and head, was partially relieved by Apis, but not cured.—T. F. A.

Asthenopic troubles, especially affections from using the eyes at night, causing redness of the eyes, with lachrymation and stinging pains, may call for this remedy.

The character of the pains will usually serve to distinguish the Apis from the Rhus cases, which are objectively very similar. Apis does not seem to control suppurative inflammations of the deep structures of the eye as does Rhus, though the puffiness of the lids might seem to indicate it; these cases are at first generally painless and the external swelling is not bright red, as are the local and external troubles of Apis.

The burning, hot lachrymation calls to mind Arsen., but the discharges are not acrid and excoriating in Apis, though they feel burning hot; besides the Arsenicum cases usually present a well marked cachexia.

ARGENTUM METALLICUM.

Margins of lids very thick and red. Violent itching in the canthi.

Clinical.—This remedy has proved useful in some cases of blepharitis, relieving the severe itching of the lids and angles of the eye. One case of stricture of the lachrymal duct improved very rapidly under its use until lost sight of.—T. F. A. (Compare the violent itching of this drug with Zinc., in which it is very marked at the internal canthus.)

ARGENTUM NITRICUM.

Objective.—Ophthalmia, often with intense pain, abating in the cool and open air, but intolerable in a warm room. *The conjunctiva, both ocular and palpebral, becomes congested and infiltrated, with scarlet redness. The caruncula lachrymalis is swollen and looks like a lump of red flesh; clusters of intensely red vessels extend from the inner canthus to the cornea. Profuse mucous discharge in the morning on waking, with dullness of the head, especially in the forehead and root of the nose. The margins of the lids are red, sore and thickened, with but little secretion; the canthi red and sore. Opacity of the cornea.*

(From the local application of this drug, most violent inflammation of the conjunctiva, of the lids and eyeballs ensues, with profuse muco-purulent discharge which is not excoriating to the lids.)

Subjective.—Heaviness over the eyes, which open with difficulty. Boring above the left eye. Infra-orbital neuralgia. Burning, biting and itching in the eyes, especially in the canthi; heat and pain in the ball on motion and touch; aching pain, deep in the eye, early in the morning.

Vision.—She is only able to read by holding the page which she is reading at a distance from her eyes. The letters become blurred before the eyes; her sight vanishes when reading or writing. Vanishing of sight. Obscuration of sight with anxiety; heat in the face and lachrymation; gray spots and bodies in the shape of serpents move before the vision.

Clinical.—Nitrate of silver has been very freely employed as an empirical remedy for various diseases of the conjunctiva and cornea; it is now, however, quite going out of fashion and being replaced by preparations of copper.

It is useful in blepharitis if the lids are very red, thick and swollen, especially if complicated with granulations, conjunctivitis or some deeper inflammation of the eye. In one case of ciliary blepharitis with entropion, caused by being over a fire, and ameliorated in the cold air or by cold applications, it effected a cure.

Acute conjunctivitis resulting from bathing, with profuse discharge and dark redness of the conjunctiva has been relieved.

Nitrate of silver is not homœopathic to granular lids in the later stages, but is the appropriate remedy in the early stages of acute granular conjunctivitis, in which the conjunctiva is intensely pink or scarlet-red and the discharge is profuse and inclined to be mucopurulent. Although these may be confounded with *Euphrasia* cases, there is a wide difference, more easy to recognize than to describe. In *Euphrasia* the profuse discharge causes soreness of the lids and more or less swelling; the character of the inflammation is more acute and short lived and, as a rule, the redness is much less brilliant. In Nitrate of silver cases we may, indeed, have very little discharge, except, perhaps, flakes of mucus, when the patient complains of itching and biting in the eyes and a dry, burning sensation without real dryness. (*Cantharis* has intense heat and real dryness; Sulphur is very often indicated in these dry conjunctival catarrhs, especially if there be sharp sticking pains under the lids as if splin-

ters were sticking into the eyeballs. Compare also Alumina, Graphites and Natr. mur.)

The greatest service that Argent. nitr. performs is in *purulent conjunctivitis*. With large experience in both hospital and private practice, not a single eye has been lost from this disease when seen before the cornea has been destroyed, and most of them have been treated with Nitrate of silver, which should be used internally and in all severe cases locally as well. In the mild cases where the discharge is not excessive and the chemosis not great I am in the habit of using a solution of from ten to twenty grains of the first potency to the ounce. When the discharge is thick, yellow and profuse, especially if the chemosis is extensive, it should be used locally in a solution of from two to five or even ten grains to the ounce. In the very first stages of purulent conjunctivitis it may sometimes be aborted by a single application of a solution of Nitrate of silver, thirty grains to the ounce. The most intense chemosis, with strangulated vessels, most profuse purulent discharge, even the cornea beginning to get hazy and looking as though it would slough, have been seen to subside rapidly under this treatment. The subjective symptoms are almost none; their very absence, with the *profuse purulent discharge* and the swollen lids, swollen from being distended by a collection of pus in the eye or swelling of the subconjunctival tissue of the lids themselves (as in Rhus or Apis) indicates the drug.

It has also relieved and contributed to the cure of diseases with destruction of tissue, as ulceration of the cornea; in one case with pains like darts through the eye mornings, better evenings; in another case there were small ulcers on the upper part of the cornea with much inflammation, burning pain and profuse discharge.

It has also been useful in kerato-iritis, with violent congestion of the conjunctiva; the cornea was vascular and eroded, with terrific pains from the vertex into the eye and with burning heat in the eyes.—T. F. A.

Coldness of the eye, with boring pain in the head and a sensation as if the scalp was drawn tightly, has been removed by Arg. nitr.—T. F. A. (Fluor. ac. has a sensation of cold air blowing into the eye.) In the Arg. nitr. cases we sometimes meet with trembling of the whole body and headaches.

A case of retino-choroiditis was successfully treated by this remedy.—W. H. WOODYATT.

Arg. nitr. has greatly improved two cases of atrophy of the optic nerve.—C. M. THOMAS.

Dr. Woodyatt was the first to call attention to Arg. nitr. as a remedy for weakness or paralysis of the accommodation. Since then it has been found of great service in many cases of this kind, especially if dependent upon errors of refraction, in which the asthenopic symptoms on using the eyes are not relieved after correction with the proper glasses.

A very interesting case, illustrative of the optical illusions of this drug, is reported by Dr. C. Th. Liebold: A young man was totally blind from cerebral disease, associated with loss of virility; was perfectly sane, but constantly complained that he seemed to see trees, people and green fields, but *everything was covered with snakes*, writhing and twisting in every form; snakes over his body, over his food; snakes of all sizes everywhere; he would sit for hours and contemplate these snakes he seemed to see; sometimes he saw bugs. Dr. Liebold found in Berridge's Repertory, under "tortuous bodies," Arg. nitr., among other remedies; it at once removed the snakes, but did not restore vision.

ARNICA.

The margins of the upper eyelids are painful when the lids are moved, as if they were too dry and a little sore. Cramp-like tearing or pressure in the eyebrow (left). Headaches between the eyes.

Clinical.—Arnica has been employed with marked success in a variety of eye troubles resulting from blows and various injuries; sometimes applied locally (tincture diluted with water) and sometimes given internally. It seems to be better adapted to contused than lacerated wounds, and to injuries before inflammatory symptoms have become prominent, although benefit has been derived from its use in inflammations of the lids, conjunctiva, and even of the whole globe, when of traumatic origin. (Acon., Calend.)

In hastening the absorption of extravasations of blood in the conjunctiva, aqueous humor, retina, or other ocular tunics, especially if resulting from injuries or the straining in whooping-cough, Arnica

often acts well; it seems also, sometimes, to correct the relaxed condition of the blood vessels and the too fluid condition of the blood, which predisposes to sub-conjunctival hæmorrhages in whooping-cough. (Hamamelis is more frequently used in hæmorrhages into the anterior chamber, and Ledum in sub-conjunctival ecchymoses.)

In two cases of traumatic detachment of the retina, Dr. Hunt has observed the retina become re-attached under the influence of Arnica³⁰.

Paralysis of the muscles from trauma has been cured, as in the following case of partial paralysis of the left superior oblique: A man, æt. 25, after violent muscular exertion and injuries, saw double on looking down. There was an injury of left upper eyelid and a corresponding ecchymosis of the ball. Patient suffered from diplopia and vertigo; he carried his head forward and to the right; was fearful of his balance, the ground seeming to waver under his feet; relieved by closing his left eye. The muscle recovered completely under Arnica.—PAYR.

ARSENICUM.

Objective.—*Eyelids swollen and œdematous*, first the upper and then the lower (this swelling is mostly non-inflammatory and painless); the œdematous lids are firmly and spasmodically closed and look as if distended with air. Blepharo-adenitis; edges of lids very red. Continual trembling of the upper eyelids, with lachrymation. Cornea degenerated. Conjunctiva inflamed; extreme *redness of the inner surface of the eyelids*. *Lachrymation and discharges from the eye excoriate the lids and cheek*. Anxious expression of the face.

Subjective.—Sub-orbital pain on the left side with prickings as with needles, sometimes quite severe. Extreme redness of the inner surface of the eyelids, with an uneasy sensation rather than pain, often obliging one to rub the eyes. Pain in the margin of the eyelids on moving them, as if they were dry and rubbed against the eyeballs. *Burning on margins of lids*. In the evening a feeling as of sand in the eyes, obliging him to rub them. *Burning in the eyes*; eyes hot, with burning, sore pain in the balls, and a feeling as if they had no room in the orbit. Pulsative throbbing in the eyes and with every pulsation a stitch; after midnight. Photopho-

bia. She appeared to be sensitive to light and often kept her eyes closed.

Clinical.—Only by concomitant symptoms can we distinguish between Arsenicum and Apis for *non-inflammatory œdematous swelling of the lids*, as both are indicated in this condition.

Blepharitis following erysipelas ten years previous, with scaly condition of edges of the lids and dry, smooth, scaly skin, was cured by this remedy.—J. H. BUFFUM.

Its value in croupous conjunctivitis following ophthalmia neonatorum was illustrated in a child three weeks old. The discharge was moderately tenacious, stringy and yellow-white in color. The lids were slightly œdematous. The right cornea was clear, but the palpebral (especially lower lid) was covered with shreds of exudation, loosely attached but easily removed, leaving a bleeding surface and hypertrophied papillæ. On the lower half of the left cornea was a large ulcer which had perforated and the remainder of the cornea was opaque. The conjunctiva of the lower lid was covered with a dense, white, semi-transparent, fibrinous exudation which could not be removed without much force. A similar membrane was present on the upper lid, but not as dense nor as firmly attached. After Arg. nitr, Bromine and Chlorine water had failed to improve, Arsen.³⁰ was given on account of the restlessness after midnight and desire to nurse often and little. A solution of alcohol (ʒj ad ʒij) was used locally at the same time. The membrane rapidly disappeared and the ulcer healed, leaving a slight purulent discharge which Arg. nitr. controlled.

Arsenicum may be called for in chronic trachoma, in which the internal surfaces of the lids are inflamed, painful, dry and rub against the ball, especially if there are *intense burning pains and excoriating lachrymation*.

In scrofulous ophthalmia this remedy has been frequently employed with success, especially in ulcers of the cornea, with soreness of the internal surface of the lids, which are swollen and spasmodically closed, so that opening them causes intense burning, sticking pains, worse at night, excessive photophobia and acrid lachrymation; tears gush out on opening the eyes; eyes can be opened well in the cool, open air, but not in the house, even in a dark room; eyes feel as if they had no room in the orbit; throbbing, pulsating

in the eyeballs and around the orbit, with general ulceration of the cornea recurring first in one eye and then the other, especially in young people who are anæmic (in one case when the eyes were better the feet were swollen); ulcer on outer side of cornea with elevated edges, pain like the pricking of needles, excoriation of the external canthus, burning and sticking pains. The following case shows still further the action of Arsenic in ulceration of the cornea. A woman, æt 35, had ulcers of the cornea with chronic trachoma, with a blepharitis which dated some years from the suppression of an eruption on the scalp, which she described as scaly and very itchy. The cornea had become dim and dotted with small, white scars from old ulcers; she had no lashes left; the lids were very sore on the inner margins; she had photophobia and various neuralgic pains. On the 12th of May she received one dose of Sulphur²⁰⁰. In a week the right eye was somewhat better, but the left was much worse. The head is getting sore, with an itching, moist eruption which forms a dry scurf; she complains of pains and restlessness at night; there is twitching of the eyes as if they were drawing into the head, with burning heat, hot lachrymation and photophobia, with tearing pains around the eyes on looking at the light. Arsen., one dose, was prescribed. In twelve days she reported wonderful improvement; no heat, no pains, no twitching; since the ulcers had healed the photophobia vanished; she received Sac. lac. and continued to improve for three weeks, when a slight return of the photophobia necessitated a repetition of the dose; each dose acted about four weeks. She gradually recovered nearly perfect vision, with disappearance of the granulations and perfect cure of the eruption.—T. F. A.

Vascular elevations on the cornea resulting from ulceration, aggravated by opening and closing the eyes, with violent, burning pains every afternoon, have been benefited. .

Parenchymatous keratitis may require the use of this remedy, as, for example, the following case occurring in my clinic and treated by Dr. Charles C. Boyle: Mrs. J., æt. 30, had suffered from an inflammation of the eyes for eleven weeks. Both corneæ were very hazy, densely infiltrated and vision nearly lost, especially in the right eye. There was deep ciliary injection and commencing vascularity of the cornea; much photophobia and lachrymation; *burning pain in the eye and over the brow, worse about four A.M.*; shooting

pain in the ball, over the head and down the cheek; sensation like pins and needles sticking in the eyes, worse at night. Pupil dilated slowly under Atropine. No specific history. For one week Cinnab.³ and Aur. mur.³, with Atropine externally, were prescribed with only an aggravation of the symptoms. Arsen.³ was then given with almost immediate amelioration of pain and rapid diminution of the inflammatory symptoms. One week later the 30th was prescribed. In about four weeks the haziness of the cornea had so nearly disappeared that with correcting glasses vision was $\frac{20}{30}$.

Several cases of kerato-iritis with burning pains over the orbit, worse at night and with profuse acrid lachrymation have been cured.

Benefit has been derived from its use in syphilitic iritis and also idiopathic iritis, characterized by burning pains in the eye, worse at night, especially after midnight, with great restlessness and much thirst.

Arsen. cured a progressive choroiditis disseminata which alternated with bronchial catarrh; when the eyes were better the chest was worse, and vice versa. There was heat in the eyes and burning in the chest, with dyspnoea and a whole train of Arsenic chest symptoms.—T. F. A.

The favorable results obtained from the use of Arsen. in retinitis albuminurica are sometimes very gratifying, as shown in the following case: Miss M. P., æt. 20; retinitis albuminurica fully developed in both eyes. L. V. counts fingers at two feet. R. V. $\frac{20}{30}$. Right ventricle hypertrophied; appetite variable; bowels regular; great thirst for small amounts; occipital headache of a pricking character; tongue large, dry and yellowish; menses too often and venous; breath oppressed and pulse irregular. Cured in two months by Arsenicum 3d and 30th, and Sulphur.³⁰. Last report: No albumin; R. V. $\frac{20}{30}$; L. V. $\frac{15}{30}$.—W. S. SEARLE.

Both Arsenicum and Rhus are often indicated in scrofulous cases, but the paroxysmal character of the pains, the extreme prostration often present, the burning, sticking pains and the excoriating discharges will distinguish Arsenic. The brilliant red inner margins of the lids and the dryness of the inner surfaces are very marked indications for its use in trachoma. The nervous irritability associated with the symptoms of Arsenic is a very pronounced anæmic hyperæsthesia.

Arsenic cases are generally relieved by warm applications. They are very frequently periodic in their occurrence, commencing every fall, and often alternating from one eye to the other.

ARUM TRIPHYLLUM.

Clinical.—A brilliant cure of catarrh of the lachrymal sac, with *desire to bore into the side of the nose*, was made by this drug.—C. A. BACON.

ASAFŒTIDA.

Severe boring pains above the brows. Tearing pain in the forehead; dull pressure at the external border of the left orbit. Troublesome dryness of the eyes. Periodic burning in the eyes and pressing together of the lids, as if overcome with sleep. Burning in the ball from within outward.

Clinical.—Asaf. is very useful in *ciliary neuralgia*, and from its power of relieving the intense boring, burning pain in the brows, especially at night, has arisen its very beneficial action in certain forms of deep-seated inflammation of the eyeball attended by these ciliary pains and turbidity of the humors, as in iritis, kerato-iritis, irido-choroiditis and retinitis, especially if of syphilitic origin. The pains are usually throbbing, beating, boring or burning in character, either in the eye, over or around it; they are often intermittent, extend from within outward and are ameliorated by rest and pressure (reverse of Aurum).

Asaf. has relieved a sharp pain extending through the eye into the head upon touching.

ASARUM.

Clinical.—Asthenopia, accompanied by congestive headaches, has been cured. The eyes were worse morning and evening, when outdoors in the heat and sunlight; were better in the middle of the day and from bathing them in cold water.—T. F. A.

ATROPINE.

About 9 P.M. eyelids felt heavy and difficult to keep open. Sharp pain under the right eye, with slight pain in the temples. Neuralgic pains commencing under the left orbit and running back to the ear,

lasting perhaps ten minutes at a time and then disappearing for fifteen or twenty; these have been noticed for several hours.

Clinical.—In addition to the extensive use of Atropine for dilating the pupil, its use for the purposes of lessening the intraocular blood pressure in inflammatory diseases of the internal structures of the eyeball and also in inflammation of the cornea and even conjunctiva, has lately come into vogue.

Its wholesale and empirical application for therapeutical purposes is unwise and often unsafe, since we have few accurate data upon which to base a prescription of Atropine to cure (it should never be used when Belladonna is indicated, since Atropine does not comprise Belladonna).

It is a very happy provision that the local application of Atropine to a healthy eye almost always spends its whole drug power upon the peripheral nerve fibres of the iris and ciliary muscle and that very seldom do any constitutional symptoms arise. The instances of such marked drug affinity for accessible portions of the human body are, indeed, rare, or, at least, rarely recognized. We have then a mechanical agent, as it were, for treating diseases of the iris. Neither Bell. nor Atrop. are often indicated remedies in iritis. Is then the use of Atropine to be commended? The necessary conditions for the successful treatment of iritis are above all: First, rest of the organ affected; second, isolation as far as possible from contiguous structures, in order to avoid adhesions of the iris to the surface of the lens. Rest of the iris can be approximately obtained by placing the patient in a perfectly dark room and keeping him in a recumbent position. But we still have to deal with emotional effects as well as the irritating action of the inflammatory process. Darkness favors the dilatation of the pupil and consequent withdrawal of the margin of the iris from the lens capsule, but the inflammatory process supplies the stimulus or irritation which was banished with the light and so but little has been gained. We cannot keep the patient constantly in the dark without detriment to his general health. Attempts of this kind have been attended with considerable damage to the patient. In several years' experience we have seen no single bad effect from the use of strong (four grains to the ounce) solution of Atropine for dilating the pupil in order to examine the fundus. Its use should always be avoided in all stages

of glaucoma, as cases are reported of most violent inflammation following its use in that disease (though Belladonna does not seem to be at all homœopathic to glaucoma, as the action of Atropine is probably mechanical).

If an attack of iritis could be promptly recognized and met at the very beginning, before the exudative stage is reached (that is, within twenty-four hours), there *might* be no need of Atropine; but if exudation has taken place and the inflammation is violent, use immediately a strong solution of Atropine, a drop every one to four hours; it will not materially interfere with the action of remedies. It is, however, *in all cases, the safest plan*, for, if adhesions take place, an iridectomy will usually be required. For sub-acute cases a much weaker solution, one-quarter to one-eighth of a grain to the ounce, may be sufficient to dilate the pupil. In severe cases, in which the congestion of the capillaries is enormous and the iris, being so full of blood, cannot dilate, Aconite may be employed in frequent doses to reduce the hyperæmia. In rare cases of this kind even cupping of the temples may be justifiable as a temporary expedient to enable us to obtain a dilated pupil. This being accomplished, remedial measures may be resumed and continued.

Its use is recommended for the relief of ciliary neuralgia.

AURUM.

Objective.—Redness and swelling of the lids. Redness of the sclerotic; constant lachrymation; morning agglutination.

Subjective.—Burning, stitching, drawing and itching in the inner canthus of the eyes and in the lids; sensation, upon using the eyes, as of violent heat in them; pressure in the eyes and constant feeling of sand in them; pressive pain in the right ball from above downward, also from without inward, worse on touch; pain in the eye from blowing the nose.

Vision.—Hemiopia, *the upper half of the field of vision seems covered by a black body*, the lower half visible. He cannot distinguish anything clearly because he sees everything double and one object is seen mixed with the other, with violent tension in the eyes.

Clinical.—In considering the clinical application of Aurum in ophthalmic diseases, no distinction will be made between metallic gold and the muriate, for experience has not yet demonstrated that

there is any practical difference between these two preparations. It has been my practice to use the muriate when the administration of a low potency is desired, and the metallic if a high attenuation is required.

In blepharitis it is rarely useful, though it may be called for, especially in syphilitic patients after the abuse of mercury, if the lids are red, swollen and ulcerated.

For *trachoma with or without pannus* (especially with), there is probably no remedy oftener indicated than Aurum. Its characteristics are not well marked, but its usefulness has been confirmed in a variety of cases; there is commonly much photophobia, lachrymation and pain, burning or dull in character, compelling one to close the lids, usually worse in the morning and ameliorated by the application of cold water; although one or more of these symptoms may be absent without necessarily contra-indicating this remedy.

For ulcerations and pannus-like thickening of the outer layer, Aurum is of great service, especially in cases of scrofulous ophthalmia with ulcerations and vascularity of the cornea; with great irritability of the patient; great sensitiveness to noise; photophobia; profuse, scalding lachrymation; sensitiveness of the eyes to touch; swollen cervical glands; pains from without inward, worse on touch (reverse of Asaf.).

No remedy has given greater satisfaction in the treatment of *interstitial keratitis* than Aurum muriaticum and many cases of this sluggish form of inflammation have yielded promptly to its use. Its sphere of action does not seem to be closely circumscribed, for rapid improvement has followed its use in cases of a scrofulous origin, as well as in those which can be traced to *hereditary syphilis*. The *cornea is more or less opaque* and may be very vascular or not. The degree of ciliary injection, photophobia and pain is variable. An example of the speedy cure which may be effected by this drug, is found in the following: A boy, seven years of age, had been suffering from inflammation of the eyes and loss of vision for two weeks. There was diffuse haziness of both corneae, with dense points here and there, moderate redness and photophobia; no pain. The vision was reduced to counting fingers at two feet. Child scrofulous. Under Aur. mur.³, in four weeks, right vision $\frac{2}{7}$ and left vision $\frac{2}{10}$.

Two weeks later there was only slight haziness of the cornea remaining. Its verification in cases dependent upon hereditary syphilis is of frequent occurrence. In old, obstinate cases of superficial ulceration of the cornea with moderate redness, photophobia and lachrymation.^c

In low forms of episcleritis in which the cornea is becoming infiltrated from the sclera, with moderate redness, pain and photophobia, benefit has been derived from Aurum.

Favorable results have followed its use in iritis and kerato-iritis, particularly the syphilitic variety, and after the abuse of mercury. There is usually much pain around the eye which seems to be deep in the bone and to extend from without inward; aggravated by touch. In one case recently under my care in which the improvement and cure was remarkably rapid under Aur. mur.³, there was great swelling of the iris, extensive posterior synechiæ, large *gumma of the iris*, haziness of aqueous, with deposits on posterior surface of the cornea, tending to extension into the parenchyma, together with much pain and soreness around the eye; worse at night.

It is almost a specific for exudative chorio-retinitis with exudations in the vitreous.—T. F. A.

Choroiditis with injection of sub-conjunctival vessels, slight iritis, photophobia, pains in the hip, great craving for coffee, and general feeling of malaise, was cured by this remedy.—H. GILBERT.

Hemiopia, in which the right half of objects is invisible, has been helped, though not cured. But the form of hemiopia to which Aurum is especially adapted is when the patient can see nothing above the median line, as the following case will illustrate: Some years ago a gentleman, who had taken large quantities of iodide of potash, complained that the vision of the left eye had been failing for a year and a half; he could not see the upper half of a room, or any large object, though the lower half was clear; no pains in the eye; objects seemed smaller and more distant; had some black spots before vision; was always worse as the day progressed and better in the morning; twitching in the upper lid. On inquiry it was found that he had syphilis ten years ago, but had not been recently troubled with any secondary symptoms, except that a large bursa-like swelling on the wrist had persisted a long time. Vision was $\frac{5}{200}$. Upon ophthalmoscopic examination there was found chorio-

retinitis (chronic) with an accumulation of fluid beneath the retina, which settled to the lower portion of the eye and caused a large *detachment of the retina*. *Vitreous hazy from infiltration*. Right eye normal; refraction normal. Knowledge of the pathological condition here gave no clue to the remedy, and we were obliged, this time at least, to rely upon the symptomatology (as one should always be ready to do). The remarkable symptom of not seeing anything in the upper half of the field of vision is of course the most prominent. In addition to the Aurum symptom, we may find, under Digitalis, "as if the upper half of the field of vision were covered by a dark cloud evenings on walking." Digitalis, moreover, covers the pathological point, having been found curative in fluid exudations of various kinds. The symptoms are also worse in the evening, while those of Aurum are usually worse in the morning. Still, taking the history of the case into account and the previous dosing with iodide of potash, Aurum²⁰⁰ was given, under which he steadily improved; the haziness of the vitreous almost entirely disappeared; the inflammation of the retina subsided and in one year the vision rose to and remained at $\frac{15}{100}$, beyond which it would not go, for the retina was partly disorganized and could not be repaired with retinal tissue.—T. F. A. Since then several cases of retinal disease have been successfully treated with Aurum, though in some cases no improvement followed and the remedy only served to arrest further progress of the malady (compare Gelsem.). Aurum cases will usually be found to follow overdosing by potash or mercury and perfect vision can never be expected from the nature of the tissue changes.

One singular case of a man, 40 years old, was sent for advice. A large, black sub-choroidal tumor was found in the fundus just behind the lens growing from the inner side. He suffered no pain, but the symptoms of vision were those of Aurum. The whole disease had only lasted about six weeks. Vision $\frac{5}{200}$. After taking Aurum²⁰⁰ a week, vision rose to $\frac{5}{80}$ and in eight weeks more to $\frac{5}{60}$, since which time he has not been seen. It was probably an exudation tumor and may have been absorbed.—T. F. A.

Its reported benefit in paralysis of the muscles from syphilitic periostitis seems reasonable; though I have not yet had occasion to verify its action.

BADIAGO.

Bluish purple margins of lids. Headache, extending to the eyeballs. Pains in the eyeballs, extending into the temples, aggravated by turning them in either direction. Slight aching pains in the posterior portion of both eyeballs and in the temples (with headache from 2 P.M. till 7 A.M.). The left eyeball quite sore, even upon closing it tightly.

Clinical.—This variety of sponge has been useful in some cases of exophthalmic goitre and should always be thought of in this disease.

BARYTA CARBONICA.

Redness of the conjunctiva, with swollen lids. Itching of the eyes. Sensation as of a gauze before the eyes in the morning and after a meal.

Clinical.—Dr. Dudgeon advises its use in scrofulous inflammations of the eye characterized by phlyctenules and ulcers on the cornea, especially when associated with glandular swellings.

BARYTA IODATA.

Clinical.—Up to the present time no proving has been made of this substance, so that its sphere of action is hypothecated from its composition; clinically, it has proved a great addition to our armamentarium. It was first introduced to notice as an ophthalmic remedy by Dr. Liebold, who says that it is especially adapted to diseases occurring in scrofulous subjects, in which there is great swelling of the glands, particularly of the lymphatics, "which feel like a string of beans everywhere between the muscles down to the spinal column; they can be felt of all sizes and all degrees of induration; some may be suppurating, while others have healed with an ugly scar." It has been used very successfully in chronic recurrences of phlyctenular keratitis and conjunctivitis found in the above subjects.

Dr. Woodyatt has reported a cure of specific interstitial keratitis of both eyes, in which vision had decreased so that fingers could not be counted at more than four feet, complicated with enlargement of the cervical glands which were hard and painful on pressure. Since then I have verified its usefulness in one case of parenchymatous keratitis.

BELLADONNA.

Objective.—The eyes are protruding, staring and brilliant. The eyes become distorted, with redness and swelling of the face; spasms of the eyes; the eyes are in constant motion. Lids puffy, red and congested; inflammatory swelling of the lower lid near the inner canthus, with throbbing pains, etc. Conjunctiva red, tumefied. Lachrymation, with great photophobia. Total absence of lachrymation; motion of the eyes attended with a sense of dryness and stiffness; the conjunctival vessels fully injected. Pupils (at first, or from large doses) dilated; (afterward, or from minute doses) contracted. *The optic disc greatly deepened in tint, and the retinal arteries and veins much enlarged, the veins most markedly so.*

Subjective.—*Eye dry, motion attended with a sense of dryness and stiffness.* Pain and burning in the eyes. Feeling of heat in the eyes; it seems as if they were surrounded by a hot vapor. Burning heat in the eyes. The surface of the ball became quite dry, which caused a very disagreeable and uncomfortable sensation, which could not be relieved by winking or continued closing of the eyes. Pressive pain deep in the ball when she closed the eyes; feeling as if the eyes protruded.

Vision.—Dimness of sight or actual blindness. Every object in the room, both real and spectral, had a double or at least a dim outline, owing to the extreme dilatation of the pupils. *Everything he looks at seems red.* A large halo appears round the flame of the candle, partly colored, the red predominating; at times the light seems as if broken up into rays. Occasional *flashes of light before the eyes*; sparks of electricity before the eyes, especially on moving them; large, bright sparks before the eyes. Retina insensible; he is quite blind. *Photophobia.* Diplopia. Flickering before the eyes, When walking in open air, black spots and stripes before the eyes, rapidly appearing and disappearing. Objects passing before the eyes have an undulating motion.

Clinical.—The use of this drug in inflammatory diseases of the eye is much more limited than is generally supposed.

Erythema and erysipelatous inflammation of the lids often require the administration of Belladonna.

It may be of service in some forms of conjunctivitis (especially catarrhal in the early stages) with dryness of the eyes, thickened, red

lids and burning pains in the eyes, though not as frequently called for as Aconite. Its use may be necessary in acute aggravations of various chronic diseases, as in granular lids, when, after taking cold, the eyes become *sensitive to air and light*, with dryness and a gritty feeling in them; or in chronic forms of keratitis in which the eye suddenly becomes intensely congested, with excessive photophobia, heat and pains which may be throbbing or sharp, shooting through the eyeball to the back of the head.

Idiopathic iritis has been cured in the early stages by this remedy, but it is not often indicated. Two cases, however, of *simple plastic iritis, resulting from a cold on the eighth day after a cataract extraction*, in which the pains were severe and of a throbbing character in and above the eye, worse at night, were promptly relieved under Bell.³⁰, after Atropine, cold and warmth externally, and Rhus, Merc. and Bry., internally had been given a faithful trial for several days with no improvement.

Mydriasis resulting from nervous headache has been relieved.

In diseases of the fundus, Belladonna has been a most valuable remedy. It has been employed with great advantage in hyperæmia of the choroid and also in inflammation, especially the disseminate form of choroiditis. There will usually be found accompanying these cases much headache, congestion of the head and considerable photophobia.

Bell. has relieved temporarily the severe pains of glaucoma, though I have never seen any permanent benefit from its use. (Glaucomatous eyes are exceedingly sensitive to the action of this drug, and atropine should never be used if possible to avoid it.)

It is often the remedy for *hyperæsthesia of the retina* dependent upon some anomaly in refraction, or due to reflex irritation, as illustrated in a case of hyperæsthesia of the retina with neuralgic dysmenorrhœa, by Dr. Fowler¹:—Miss F., æt. 22, had not been able to use her eyes for three months on account of the pain and dazzling whenever there was light enough to enable her to read or sew. On awakening in the morning the light produced intense pain not only in the eyes but in the head. Sometimes the headache continued all day; evening and darkness alone relieving it. Complained of “sparks” and flashes of light before

¹ Trans. Hom. Ophthal. and Otol. Soc., '79.

the eyes; also of a feeling of heaviness in the eyeballs. Her general health was poor, "felt tired all the time;" menses regular, but very painful; sleep restless; mood despondent; complexion pale; appetite poor. Examination of eyes showed nothing abnormal. After *Nux. v.* had failed to benefit, *Bell.*³ was given; in three weeks she could use her eyes about as well as ever and had no pain at menstrual period. There had been no further trouble of the kind two years later.

In *hyperæmia of the optic nerve and retina* this remedy has been especially efficacious, particularly if dependent upon cerebral congestion and accompanied by aching pain in the eye, aggravated by any light; also, in chronic forms of hyperæmia, if a red conjunctival line is very marked along the line of fissure of the lids. In some of these cases, as well as in some acute inflammatory affections, retinal photopsies are present, such as red sparks, flames, bright spots, lights, etc.

Its usefulness is not, however, confined to simple congestion of the optic nerve and retina, as it is one of our chief remedies in inflammation of these tissues. The following cases will show the sphere of action in inflammation of the optic nerve and retina: Optic neuritis, in which the papilla was very much swollen, veins large, flashes of light before the eye and pains in the head. *Bell.* cured speedily. Retinitis, occurring in a young lady who was subject to congestive headaches, always worse in the afternoon. The retina was very hazy and œdematous, appearing as if covered with a bluish-gray film; outlines of disc ill-defined; vessels large and tortuous. Under *Bell.*³⁰ a rapid disappearance of the above symptoms took place. Neuro-retinitis. Edith G., æt. 5, had suffered from "chills and fever," which had been relieved without quinine. Six weeks previous to my seeing her and immediately after the chills had been stopped, it was first noticed that her sight was poor, but variable; sometimes she seemed to be nearly blind, while again would distinguish medium-sized objects with comparative ease; complained very often of headache, especially every afternoon, when the head would be quite hot and the face flushed. She was more irritable and cross than formerly. The condition at the time was reported as follows: "Child has a full face, light complexion and red hair; is bright and smart. Her vision is very poor; does not seem to be

able to count fingers, though, owing to her age, her statements are unreliable; sight is markedly better in right than left eye; nothing abnormal is to be seen externally, with the exception of a slight convergent strabismus in left eye. Ophthalmoscopic examination after dilatation of both pupils with Atropine. Right eye: Optic disc very much swollen and outlines ill-defined; its edges, as well as the surrounding retina, are so infiltrated that it is only by tracing the retinal vessels that the optic nerve entrance is discovered. The arteries are about normal in size, but they, as well as the veins, which are large and tortuous, are veiled here and there by the infiltration. In the macula lutea bright white patches are seen, of a triangular shape and extending more toward the nerve than outward from the macula (are somewhat similar to the stellated arrangement usually found in retinitis albuminurica). Left eye: The same swollen condition of the optic nerve and surrounding retina is perceived as in the right eye, though mingled with the infiltration into the retina are spots of exudation of an opaque character. The retinal vessels are enlarged, especially the veins which are full and tortuous; they are hidden at points by the exudation into the retina; while along their course, especially on the nerve entrance and immediately around, small points of extravasation of blood are noticed. The changes in the macula lutea are similar to those in the right eye, though the white patches are more marked and divided into many by fine lines or inter-spaces. A careful examination of the urine shows not the slightest trace of albumin." Bell.³ was given. In three days vision was better. In two weeks no hæmorrhages were to be found in the retina, the swelling of optic papilla and retina were decidedly less and the headache was relieved. In one month the vision was very good, both nerves somewhat atrophic and the points of exudation in the retina could scarcely be distinguished, though no perceptible change could be seen in the white patches in the macula lutea.

A case of apoplexy of the retina, with suppression of menstruation, occurring in a girl, æt. 18, is reported by Payr: She was subject to cerebral congestions, sudden heat of head, vertigo, burning and throbbing frontal pain, noises in the ear and illusions of vision, while the rest of the body was cold and shivering. Headache increased, pulsation of the carotids became more severe, photopsies and

then sudden blindness. Numerous apoplectic spots were found in the macula lutea, no change of papilla, pulsation of central vein, much active cerebral congestion and great photophobia. Under Bell, complete recovery of vision and absorption of the hæmorrhages took place.

Convulsive movements of the eyeball in the light, with terrible pressive pain extending through the whole head, ameliorated in a dark room, have been cured by Bell.; hence its use has been recommended in strabismus due to spasmodic action of the muscles, or when resulting from brain affections. In orbital neuralgia, especially of the infraorbital nerve, with red face and hot hands, it is a valuable remedy.

Some cases of amaurosis and amblyopia will require this drug, especially if they are congestive in form and accompanied by the headache and other characteristic symptoms.

BROMIUM.

Great depression of mind; pain deep in the crown of the head. Protruding eyes. A gray point before the right eye, moving up and down with movement of the eye. Particularly in blondes.

BRYONIA.

Objective.—Puffiness of the right upper lid. The conjunctiva is dark-red and swollen, with some discharge of pus. Morning agglutination and frequent lachrymation.

Subjective.—Pressive pain above the left eye. Pressure from within outward over the right orbit into the brain, which changes to a pressure on the eyeball from above downward. Pain deep in the right orbit, aggravated by pressure upon the eyeball. Drawing together of the left upper lid, with a sensation of heaviness therein; aching pains in the eyes. Severe burning and lachrymation of the right eye. Very *sensitive pressive* pain (coming and going) in the left eyeball, *especially violent on moving the ball*, with a feeling as if the eye became smaller and retracted in the orbit.

Vision.—Dim vision; on reading, the letters seem to run together; *appearance of all colors of the rainbow*; every object seems covered with these colors; photophobia.

Clinical.—It is found that Bryonia is rarely indicated in diseases

affecting the external tissues of the eye, although in one case of acute inflammation of both the ocular and palpebral conjunctiva, worse in the left eye and toward the outer canthus, with marked *soreness to touch or upon any motion of the eyes* and with a sticking sensation as of hairs in the eyes, a speedy cure resulted under Bryonia.

Its great sphere of usefulness is, however, in diseases of the uveal tract.

Favorable results frequently follow its use in iritis caused by a cold, especially in rheumatic subjects, in which there is *sharp, shooting pain through the eye into the head, aggravated by motion* and relieved by pressure; or if the pain is a steady aching in the posterior portion of the eye, extending through to the occiput, worse at night and on motion.

It is also often indicated if the inflammation has extended to the choroid, as was shown in a case of acute irido-choroiditis of the left eye in which there were present opacities in the vitreous, tremulous iris, great ciliary injection, pus in the anterior chamber, soreness in eyeball on moving it and darting pains from the eye through the head, with heaviness of the head afternoons. Bryonia speedily relieved.

In the serous variety of choroiditis it is an important remedy, as one would be led to suppose from its relation to serous inflammation in general. Experience has also verified its usefulness in this disease.

Glaucoma appears to have been checked in its progress by Bryonia when the eyeball has seemed too full, as if pressed out, with sharp, shooting pains in the eye and head, worse at night; also, in a case in the prodromal stage, in which the symptoms were as follows: The vision of the left eye had been failing three months, and especially for one week; there was heavy pain over the eye, worse at night; halo around the light for one day; cupping of the optic disc, and T+. The patient was rheumatic and nervous. Under Bryonia²⁰ all the symptoms were relieved with the exception of the excavation of the nerve.

A case of hyperæmia of the optic nerve and retina was immediately relieved by this drug; a bluish haze appeared before the vision (vision $\frac{2}{3}$); with severe pain over the eye as from a *needle going through the eye* and head (compelling her to go to bed); with heat through the whole head, aggravated by stooping.

Ciliary neuralgia often requires Bryonia, especially if the pains are sharp and severe, even making the patient scream out; the pains are aggravated by opening the eye and by any motion of the eyeball; the eyes must be kept closed and at rest. The pains, when this remedy is indicated, are usually *sharp in character, passing through the eye into the head, or from the eye downward into the malar region and thence backward to the occiput; the seat of pain becomes as sore as a boil, and the least exertion, talking, moving, or using the eyes aggravates the trouble.* The following symptoms have been reported as cured by this drug, though not found in any proving; some have been repeatedly verified, and seem to direct the choice of the remedy; they are mostly variations of sensation in different persons, dependent upon the great characteristics of the remedy—aggravation on motion, and amelioration on pressure: Pressing, crushing pain in the eyes, worse on motion; soreness and aching of the eyes on moving them; scalding in the corners of the eyes, aggravated at night; dull pain and soreness, especially in the left eye, worse in the morning and relieved by pressure.

CACTUS GRAND.

Clinical.—From its action on the heart, cases of exophthalmic goitre have been improved. Angell advises its use in hyperæmia of the eye, especially of the fundus.

CALCAREA CARBONICA.

Objective.—Swelling and redness of the lids, with nightly agglutination; during the day the eyes are full of mucus, with a hot sensation, smarting pain and lachrymation. Redness of the conjunctiva. Lachrymation on writing.

Subjective.—Painful sensation as if a foreign body were in the eye. Pressure and itching in the eyes, worse in the evening. Itching, burning and stitches, especially on the margins of the lids and in the inner canthi.

Vision.—Farsightedness. Only one side of objects visible, with dilated pupils. Dimness of the eyes after getting the head cold. Halo around the light. Flickering, sparks and black spots before the eyes. Photophobia.

Clinical.—The clinical record of this drug, in superficial inflammations of the eye, is very full.

It has been found especially curative in various forms of blepharitis occurring in unhealthy, "pot-bellied" children inclined to grow fat and who sweat profusely about the head; lids red, swollen and indurated; inflammation of the margins of the lids causing loss of the eye-lashes, with thick, purulent, excoriating discharge and burning, sticking pains; blepharitis with great itching in the lids.

Indurations remaining after styes and tarsal tumors have disappeared under its use.

Simple inflammation of the conjunctiva may call for this remedy, as in the following instance of acute conjunctivitis *caused by bathing*: There was moderate redness and lachrymation; eyes felt hot and feverish, with a sensation as of sand in them. Acon.³ failed to relieve; Calc.³⁰ cured quickly.

The discharges from the eye are often profuse and, therefore, this drug has been used with advantage in purulent ophthalmia, especially in that form found in new-born children, characterized by profuse yellowish-white discharges, great swelling of the lids and ulceration of the cornea.

Conjunctivitis trachomatosa, with pannus, much redness and lachrymation, caused from working in the wet, has been speedily relieved.

A marked illustration of the curative action of the drug in affections caused by working in water is shown by the following case: A boatman suffered for years from repeated attacks of sore eyes, *caused by getting wet and cold*. Pterygium developed and grew rapidly. Calc. c. speedily checked the progress of the disease, and when last seen the cornea had cleared and but little thickness remained in the internal canthus.—T. F. A.

Favorable results have followed the use of this preparation of lime in various forms of *inflammation of the cornea caused from getting wet or aggravated in damp weather* (Rhus). It is, however, particularly in serofulous inflammations of the cornea and conjunctiva, characterized by pustules and ulcers, that Calc. c. proves so beneficial. The following cases afford a good illustration of the prominent features of this drug: A man was attacked with phlyctenules on the conjunctiva, after a severe cold, caused by working at

night washing carriages. There were severe, sharp, shooting pains from the eye up into the head, worse from two to three in the morning and ameliorated on closing the eyes. Sulph. failed to benefit, but Calc. c.³⁰ gave immediate relief.—Keratitis phlyctenularis, with much redness and photophobia; pain at night which wakes the child from sleep, with cold perspiration; was cured under Calc. c.³⁰.—Keratitis pustulosa, with profuse lachrymation, excessive photophobia and sticking pains; lids closed, red and swollen, with painful itching in them; agglutination mornings; head scurfy; cervical glands swollen, also the upper lip; acrid discharge from the nose; eruptions that burn and itch; abdomen distended and hard; skin pale and flabby. After the administration of Calc. the above symptoms were promptly relieved and the eye restored. It will be observed that the photophobia and lachrymation are usually excessive, but cases sometimes occur in which they are absent or present only in a moderate degree, though the general indications lead us to prescribe this remedy. The pains are more commonly sharp or sticking in character (Sulph.), though they may vary greatly. Another form of ulceration of the cornea in which Calcarea is frequently indicated is when an ulcer or pustule appears in the centre of the cornea with more or less haziness of the corneal tissue around it, no vascularity of the cornea, very little or no ciliary injection, and a variable amount of photophobia and lachrymation. (Compare Puls. and Sil.)

It has seemed to hasten the absorption of the exudation into the cornea in interstitial keratitis, especially after the inflammatory symptoms have, in a measure, subsided. Benefit has also been derived from its use in opacities of the cornea resulting from various forms of keratitis. Dr. C. M. Thomas writes me: "I have lately treated three cases of transverse calcareous band of the cornea, in two of which a complete clearing of the cornea followed a six to twelve weeks' use of Calcarea carb., preceded by a number of doses of Sulph. The third and least marked of the three resisted all treatment."

The following symptoms found in asthenopia have been verified: Pain in the eyes after using them, worse in damp weather and from warmth. Burning and cutting pains in the lids, especially on reading, or sticking pains in the eyes, with dull hearing. Dim vision

after fine work, like a cloud before the eyes, objects run together, with desire to close the eyes. Red and green halo around the light.

The selection of *Calcarea* will, in the majority of cases, depend mainly upon the general condition (*cachexia*) of the patient, since the eye symptoms are very often too general to individualize the remedy. The reverse may be said of *Euphrasia* and other remedies exhibiting no general *dyscrasia*.

CALCAREA HYPOPHOSPH.

Clinical.—The hypophosphite of lime has proved to be a remedy of the first importance in severe cases of abscess or ulceration of the cornea. It is especially adapted to those cases in which the patient is in a very low state of general health and does not seem to have vitality sufficient to resist the ulcerative process. We meet with this condition not infrequently in sloughing ulcers of the cornea, and also in that dangerous form of ulceration, the crescentic, in which, although it may not primarily be dependent upon a debilitated state of the general system, the health usually becomes impaired from the severity of the ulcerative process and *blennorrhœa* of the conjunctiva, which commonly accompanies this condition. In some of these cases pus will be found in the anterior chamber (*hypopyon*) or the iris will become inflamed and so increase the intensity of the symptoms.

CALCAREA IODATA.

Clinical.—The provings of this preparation of calcium give no clue to its sphere of action in diseases of the eye. But it is found by clinical observation to be an important remedy in scrofulous inflammations of the eyes and lids, as in chronic cases of *blepharitis*, complicated with enlargement of the tonsils.

It is, however, of especial value in pustules and ulcers, particularly of the cornea, marked by great photophobia, acrid lachrymation, sticking pains and spasm of the lids; upon forcing open the lids a stream of tears flows down the cheek; also in *erysipelatous* swelling of the lids, chiefly of the upper, which is shining and red (compare *Rhus*). The inflammation of the eye is always worse from the least cold, to which these cases are very susceptible. It is chiefly indicated in pale, fat subjects who sweat much about the head, with enlargement of the tonsils and cervical glands.

In several cases benefit seems to have been obtained from the use of iodide of calcium in checking the progress of both conical cornea and staphyloma; in one marked case of progressive staphyloma of the cornea, the sequela of trachoma and pannus, the bulging of the cornea was checked and the infiltration into its parenchyma absorbed under the use of Calc. iod.

CALCAREA PHOSPHORICA.

Eyes red; capillary vessels visible in streaks from corners to cornea. Sensation of something in the eye; always felt if it is mentioned. Cannot read; light hurts, particularly candle-light.

Clinical.—Valuable results have been obtained from the use of Calc. phos. in parenchymatous keratitis, especially if occurring in patients of a scrofulous diathesis; in one case, in which the haziness of the left cornea had been present two weeks and had extended from above downward, the vision was almost wholly lost. On account of enlargement of the tonsils, Dr. C. C. Boyle prescribed Calc. phos.³, under which rapid improvement took place and six weeks later only a slight macula remained; vision $\frac{2}{50}$. The photophobia has been well marked in all cases of corneal inflammation successfully treated with Calc. phos.

In checking the progress of cataract, it has appeared to be of decided service. The range of usefulness of this drug in ophthalmic disorders is, no doubt, much more extended than here given, but further experience is necessary to demonstrate its proper sphere of action.

CALCARIA PICRATA.

Dr. Sterling¹ reports valuable results from the use of this drug in styes and phlyctenules of both the cornea and conjunctiva. He has aborted styes within twenty-four hours and in phlyctenular troubles has subdued them within forty-eight hours, especially where there has not been pronounced vascularity.

CALENDULA.

Clinical.—The most marked success which has attended the use of Calendula has been observed in injuries of the eye and its appendages, especially cut wounds.

¹ Trans. Amer. Inst. of Homœo. for 1885.

In wounds of the lids and brows which have been badly treated by plasters until suppuration has taken place, the local application of *Calendula* is the remedy.

After all operations upon the eye or lids, this drug is useful in preventing any undue amount of inflammation and in hastening recovery. Its action is not, however, limited to the prevention of inflammation, as it has been of service in various forms of traumatic inflammation of the eye.

Benefit has been derived from this drug in blennorrhœa of the lachrymal sac.

In the practice of Dr. W. P. Fowler, good results have been obtained from *Calendula* in a large number of cases of pustular conjunctivitis, especially if there was little or no photophobia, but much redness. He has given the third potency internally and applied a solution of the tincture locally, twenty drops to two drachms of water.

Only occasionally has this drug been used internally; its most marked results having been obtained from its local application. A solution of the tincture—from ten drops to two drachms to the ounce of water—may be employed, but a decoction, made from the leaves, is the best preparation which can be used upon the eye.

CANNABIS SATIVA.

(Under this drug the symptoms of *Cannabis indica* will be included, but designated by *, as the clinical application of the two remedies is apparently the same.)

Objective.—*Injection of the vessels of the conjunctiva. **The vessels of the conjunctiva of both eyes are injected in a triangular patch extending from the internal canthus to the cornea; worse at night. The cornea becomes obscured.* *Lachrymation.

Subjective.—*Heat in the eyes. Sensation of spasmodic drawing in the eye; as if sand were in the eyes. Pressure from behind the eye forward.

Vision.—*While reading the letters run together. *Twinkling, trembling and glimmering before the eyes. *Sensitiveness of the eye to light.

Clinical.—*Cannabis* deserves to be employed more extensively in ophthalmic troubles than it has hitherto been, especially in affections of the cornea and conjunctiva. I would suggest its use in pterygium, though have not, at present writing, given it a trial.

The following case will illustrate its action in pustular keratitis; Colored man, æt. 28, duration of disease two days. There was a large pustule on the inner margin of the left cornea, with excessive injection of the conjunctival vessels, commencing in a broad base at the internal canthus and terminating in the pustule which forms the apex of a triangle, similar to a pterygium. He was entirely cured in three days under Cannabis ind.—A. WANSTALL.

Both varieties of Cannabis have been used with benefit in vascular conditions of the cornea. Some cases of pannus have yielded to its influence, though more valuable results have been obtained from its use in parenchymatous keratitis, as a case recently under treatment will illustrate: A boy, æt. 7, was brought to me on December 24th for treatment of an interstitial inflammation of the right cornea of two weeks' duration. The history of hereditary syphilis was fairly clear. Under Aurum mur.³ the eye was nearly well on January 20th, when the left eye became inflamed and continued to grow worse until March 2d, notwithstanding the use of Aurum, Con., Arsen., etc., internally, and the instillation of Atropine in the eye. On March 2d the *cornea was densely opaque and vascular*, so that the iris could not be seen through it. The epithelial layer was a little rough, but there was no superficial ulceration. There was *profuse lachrymation and intense photophobia*; the child not being able to open his eyes in any light. He complained of some pain. Cannabis sativa³ had been given for four days with no relief; the tincture, ten drops in two-thirds of a glass of water, one teaspoonful every hour, was now prescribed. Immediate improvement followed its use and on March 8th the child could open the eye well, had no pain and the vascular infiltration into the cornea had diminished. The cornea continued to clear for a month or more, when, only a very moderate amount of haziness remaining, other remedies were given for other symptoms.

CANTHARIS.

Inflammation of the eyes. Lachrymation. *Burning in the eyes and glowing heat as from coals.* Biting sensation as if salt were in them.

Clinical.—Has proved efficacious in inflammations of the eye caused by burns, as in the case of a young man who had had a hot

iron thrust into the eye, burning the conjunctiva and thus producing quite severe conjunctivitis, with burning pain in the eye. Cantharis quickly relieved the pain and cured. In another case, in which the cornea was inflamed as the result of a burn from fireworks, with some ciliary injection, great photophobia and moderate pain, a speedy cure was effected under Cantharis³⁰, after Aconite and Atropine had failed to relieve.

CARBO VEGETABILIS.

Subjective.—A heavy weight seemed to lie upon the eyes so that he must make a great exertion when reading or writing in order to distinguish letters. The muscles of the eye pain when looking up. Itching in the margin of the lids and about the eyes.

Vision.—He became short-sighted after exerting the eyes for some time. Black floating spots, flickering and rings before the eyes.

Clinical.—This drug has been too little employed in eye diseases and its clinical history is extremely scant.

From its symptomatology we are led to recommend its use in cases of myopia, accompanied by posterior staphyloma, in which it ought to relieve the unpleasant symptoms and prevent the increase of the staphyloma, though I do not imagine that it would in any degree diminish the amount of myopia.

In asthenopia, as the verified symptoms indicate, it has proved beneficial. Dr. Deady reports a case of vascular tumor of the lid cured by this drug.

CARBOLIC ACID.

Very severe orbital neuralgia over the right eye. Slight pain over the right eyebrow; the same kind of pain, but in a milder degree, under the right patella, both of short duration.

Clinical.—In conjunctivitis trachomatosa, with or without pannus, remarkable success has often followed the use of Carbolic acid and glycerine as a local application. I have used it in the proportion of six drops to the ounce and in many cases it has acted much better than tannic acid or other astringents.

As indicated by the above verified symptomatology, it has proved of service in some cases of supra-orbital neuralgia.

CAUSTICUM.

Objective.—Inflammation of the eyes, with burning and pressure in them and agglutination in the morning. Visible twitching of the lids and in the left eyebrow. Lachrymation even in a warm room, but worse in the open air. Pupils dilated.

Subjective.—Burning and stinging as with needles in the eyes, with dryness and photophobia, especially in the evening. *Pressure in the eyes as if sand were in them.* Pressive pain in the eye increased by touch. Biting and pressure in the eyes, which seem heavy, with redness of the lid. Itching of the eyes, especially in the lids; disappears on rubbing. *Inclination to close the eyes*; they close involuntarily. *Sensation of heaviness in the upper lid* as if he could not raise it easily, or as if it were agglutinated to the lower lid and could not be easily loosened. Opening of the lids is difficult. Itching on the lower lid and on its inner surface, with burning as soon as he touches the eye or moves it.

Vision.—Photophobia; constantly obliged to wink. Flickering before the eyes, as from swarms of insects. If he winks, he sees sparks of fire before the eyes, even on a bright day. The eyes become dim and the *vision indistinct*; it seems as though a thick cloud were before the eyes. Obscuration of the vision, as if a veil were drawn before them; transient obscuration on blowing the nose. Farsightedness; unable to read without glasses.

Clinical.—From the symptomatology given above and the many verifications, it will be readily seen how important a remedy Causticum must be in ophthalmic diseases.

It has been employed with benefit in some cases of blepharitis (especially if ameliorated in the fresh air—Liebold) and in certain forms of tumors of the lids, particularly warts on the lids and brow.

Simple acute conjunctivitis, with a *sensation of sand in the eye* and dull pain in the eyeball as if sore, has been relieved under Caust.³⁰⁰. It is not, however, often the remedy for external inflammations of the eye, though as an intercurrent, in scrofulous inflammations and trachoma with pannus, it has been of decided service, if called for according to indications in the above symptomatology.

The action of Caust. upon the lens is probably as pronounced as that of any remedy in our materia medica, and many cases of cata-

ract have been arrested in their progress and even the sight improved, where before its administration they were rapidly going on to complete blindness.

The following case will illustrate its action: A man appeared for treatment with well-marked hard cataract, which was rapidly increasing. (Had been told by celebrated oculists of the old school that he would soon be blind and that he then could be operated upon.) He complained of the following symptoms: A sensation as if there was a substance in the eye too large, causing a kind of heaviness and distension, only in the evening; also a feeling as if there was something moving in the eyes in the evening; could not retain his urine and could not feel the urine passing through the urethra. Under the influence of Caust. the progress of the cataract was immediately checked and one year afterward the vision was found somewhat improved, though the white striæ in the lens underwent no appreciable change. After seven years his vision remained fully as good as when he began treatment.—T. F. A. That this remedy has checked the progress of cataract and improved the vision has often been demonstrated to my satisfaction. A case of an old lady, sixty-five years of age, with immature hard cataract in both eyes, in which the vision improved in three months under Caust., from V. $\frac{20}{100}$ o. u., + 14 V. $\frac{20}{70}$, to R. V. $\frac{20}{70}$ L. V. $\frac{20}{80}$, + 16 R. V. $\frac{20}{70}$ L. V. $\frac{20}{40}$, is only one case out of many found on my record books. It must not be supposed, however, that I believe cataract can be cured by internal medication, for I have never seen any change in the opaque striæ found in the lens, but only a clearing of the diffuse haziness which often accompanies this condition.

But its principal sphere of action is in *paralysis of the muscles*, and here it is the remedy "par excellence." It has been used more often with advantage in paralysis of the ciliary muscle, external rectus, levator palpebræ superioris, or orbicularis, though indicated in paralysis of any of the muscles, particularly if caused from exposure to cold. In cases of paralysis following diphtheria it has also been of service. Selected from a number of cures are the following, which will serve to illustrate its action: A girl, eleven years of age, had complained of her vision gradually failing for near objects for a week; supposed to be due to a cold. V. $\frac{20}{80}$ improved by + 24 to $\frac{20}{20}$. Could only read $3\frac{1}{2}$ Snellen, at the distance of two or

three feet, or with + 24 glasses. The eyes were perfectly normal, pupils not dilated and the action of the other muscles good. The diagnosis was paralysis of the accommodation in both eyes. Caust.²⁰⁰ was prescribed. Three days later, when next seen, she had fully recovered the power of accommodation and reported that two hours after first taking the medicine the vision began to improve and on the next day she could read as well as ever. A lady, 32, after being over-heated by dancing, took cold and was attacked in the night with severe tearing pains in the left half of the face; afterward she saw indistinctly; diplopia followed, with inability to turn the left eye outward (paresis n. abducentis sin.). Caust. removed the paresis entirely in fourteen days.—PAYR.

For paralysis of the muscles brought on by getting wet, Rhus is more often called for than Caust., as the latter is especially indicated in those cases resulting from exposure to cold.

CEANOTHUS AMERICANUS.

Dr. French reports in the *Trans. Amer. Inst. of Homœo.*, 1884, a case of glioma retinae, in which he found curative action of the extract of red clover. After enucleation the microscope revealed the characteristic gliomatous cell formation. For four days after enucleation the stump discharged an ichorous, excoriating and sanguinolent fluid with the appearance of unhealthy granulations in the centre of the stump. The Ceanothus was applied locally and the fluid extract given internally. The character of the discharge was changed within twenty-four hours to healthy pus and so remained until the stump was healed. On the sixth day the child was profusely salivated, which disappeared upon stopping the drug. Two years had elapsed with no sign of recurrence of the disease and the child was in perfect physical health. Another case reported by G. S. N. will be found under Glioma Retinae.

CEDRON.

Pain across the eyes from temple to temple. *Severe shooting pain over the left eye.*

Clinical.—The sphere of usefulness for Cedron, so far as experience has taught us, is confined to neuralgic affections of the eye, particularly when involving the supra-orbital nerve; and in *supra-*

orbital neuralgia, it is among the first remedies to be thought of. *The pains are usually severe, sharp and shooting*, starting from one point over the eye (more often over the left) and then extending along the branches of the supra-orbital nerve up into the head; in some cases the pains would come and go suddenly and would be worse in the evening or upon lying down, though these may not be characteristic. One case of pressing frontal headache of long standing, occurring in a woman troubled with chronic disseminate choroiditis, with sharp pains extending from above the eyes back to the temples and occiput and always worse before a storm, was very quickly and permanently relieved by a few doses of Cedron³.

The severe supra-orbital pains found in iritis, choroiditis and other deep inflammations of the eye are often speedily controlled by this drug.

CHAMOMILLA.

Objective.—The eyelids are swollen in the morning and agglutinated with purulent mucus; much discharge of pus or blood. Conjunctiva swollen and dark red. Lachrymation.

Subjective.—Burning and sensation of heat in the eyes; pressure in the eyes, which are inflamed and full of mucus in the morning. Violent pressure in the orbital region; sensation in the eyeball as if it were compressed from all sides, with momentary obscuration of vision. Stitches in the orbital region and soreness in the canthi.

Clinical.—Chamomilla is especially adapted to superficial inflammations of the eye occurring in children, being rarely, if ever, useful in diseases of the deeper tissues.

It is an excellent remedy in ophthalmia neonatorum characterized by the usual symptoms (even if the cornea has been attacked) if the child is very fretful and wants to be carried all the time. It should also be thought of in inflammations of the eye in which the congestion is so great that the discharges are bloody as well as purulent (Nux).

Cham. has proved very serviceable in scrofulous ophthalmia occurring in *cross, peevish children during dentition*, and it will often relieve the severity of the symptoms, even though it does not complete the cure. The symptoms which call for this drug are usually severe; the pustules and ulcers are chiefly situated on the cornea, and are attended with great intolerance of light, considerable redness and lachrymation.

CHELIDONIUM MAJUS.

Objective.—Twitching and blinking of the lids. The white of the eye is of a dirty yellow color. Redness of the conjunctiva, especially of the lower lid. Lachrymation.

Subjective.—Tearing pain in and above the eyes. *Neuralgic pain above the right eye*, especially in the evening when reading by artificial light. Pressive pain above the left eye, which seems to press down the upper lid. *Aching or pain in the eyeballs on looking up* or moving the eyes.

Vision.—Dimness of vision. A blinding spot seems to be before the eyes, and if he looks at it the eye waters.

Clinical.—At one time remarkable success was claimed to have followed the use of this drug in a variety of eye troubles, as inflammations, opacities of the cornea, intermittent ciliary neuralgia, etc., but later observations have failed to verify much of its vaunted success.

The pain in and over the eye upon looking up has occasionally led to its employment with favorable results; as for instance in a case of acute aggravation of chronic trachoma in which the right eye had been very red and inflamed for five days, with much pain all night and a hard, sharp pain on turning the eye upward. Under Chel.³⁰ the pain was at once relieved and the acute condition had entirely subsided in three days.

This remedy may be of service in affections of the muscles, as suggested by the following case: A lady (age 40) reported that her eyes had been growing weak for three days from no apparent cause. She complained of distant objects being blurred and that upon attempting to fixate an object, two were seen. Near vision was not affected. Examination showed decided weakness of the right external rectus muscle. Chel.²⁰⁰ relieved all the symptoms in two days.—T. F. A.

CHIMAPHILA UMBELLATA.

Clinical.—A large number of cases of pterygium have been treated by this drug, a few of which have been improved, while others have exhibited no good results from its use.

Dr. Bushrod James reports favorable results from the use of this remedy in checking the progress of incipient senile cataract.

CHINA.

Motion of eyes painful, with sensation of mechanical hindrance. Lachrymation, with crawling pains in the eyes and in the inner surface of the lids. Dimness of vision.

Clinical.—The clinical application of China in ophthalmic disorders has been varied, according to the reports in our literature, though it is a remedy not often called for in ophthalmic therapeutics.

It is especially adapted to those diseases of the eye which are of a malarial origin, or in which the pains are of an intermittent type; also to those affections in which there is impairment of tone from loss of vital fluids.

CHININUM MURIATICUM.

Clinical.—This form of quinine, in appreciable doses, has been used with great success in controlling the severe neuralgic pains occurring in iritis and various other diseases of the eye. In some cases it does more than control pain, as it exercises a very beneficial influence over the progress of the disease. This is especially so if malaria complicates the trouble and the *pains are intense and intermittent in type*.

Favorable results have been observed from its use in trachoma with or without pannus.

In ulceration of the cornea it is of service if the iris has become involved and there is severe pain, either in the eye or above, periodic in character, especially if accompanied by chills; also in ulceration of pannoused corneæ, with much pain in the morning. The intensity of the pains and their intermittent character will furnish our chief indications.

CHININUM SULPHURICUM.

Disc and retina both very anæmic. Pupils dilated. Neuralgic twinges in the supra and infra-orbital nerves, generally periodic in character.

Vision.—Dimness of vision as from a net before the eyes and as from a dark fog. Great sensitiveness of the eye to the light, with lachrymation in the full glare of light. Bright light and sparks

before the eyes. Black spot, size of pin's head, about eighteen inches from right eye and moving with eye for some weeks.

Clinical.—From the physiological action of quinine upon the eye, it should prove a valuable remedy in affections of the optic nerve and retina. It has not, however, been employed to any extent, although cases of optic neuritis are said to have been cured by its use.

An interesting case of intermittent strabismus, occurring in a child and continuing for some time (would squint one day and be entirely well on the next) was cured by the use of this remedy in the hands of an empiric.

CHLORALUM.

Clinical.—The hydrate of chloral has a marked action upon the eye, in some persons producing injection of the conjunctiva, weakness of the eyes, paleness and congestion of the optic nerve, dimness of vision, etc. The clinical verifications of these symptoms have not, however, been made.

Dr. Buffum reports that he has cured with Chloral. hyd.^s, the following symptoms in asthenopia: "Burning, smarting, itching; lids gummed in the morning; lids heavy, droop at night and after use; eyeballs feel too large; lids puffed; all symptoms brought on by use; eyes feel better in cool air."

CHRYSOPHANIC ACID.

Clinical.—This drug is of especial value in obstinate cases of blepharitis ciliaris, especially in scrofulous, poorly nourished children, with pustules or eczematous eruption about the eyes. In phlyctenular keratitis and conjunctivitis when but little pain, photophobia or lachrymation with eczematous eruption of the face.

CICUTA VIROSA.

Objective.—Eyes staring; she stares with unaltered look at one and the same place and cannot help it. Pupils dilated and insensible. Pupils first contracted then dilated.

Vision.—When she attempts to stand she wishes to hold on to something, because objects seem now to come nearer, and now to recede from her. Objects seem double (and black).

Clinical.—It is in spasmodic affections of the eye and its appendages that this remedy is especially indicated. Thus we find it very valuable in strabismus, particularly if periodic and spasmodic in character; many cases of which have been cured (this, of course, excludes that form of periodic squint dependent upon an anomaly of refraction). Strabismus occurring after a fall or blow has been relieved.

CIMICIFUGA.

Eyes congested during headache. Pain over the eyes, extending from them to the top of the head. Pain over the left eye, extending along the base of the brain to the occiput. Pain in the centre of the eyeballs, and also sensation as if pain were situated between the eyeball and the orbital plate of the frontal bone, worse in the morning. *Aching pain in both eyeballs.* Black specks before the eyes.

Sensation of swelling or heaviness of the eyelids. Dilatation of the pupil.

Clinical.—Cimicifuga is not often required if there has been much tissue change, unless it be to control the pains which arise in the course of the disease, as for instance in occasional cases of ulceration of the cornea in which the pains are sharp, extending through the eye into the head.

It may be indicated in asthenopic troubles, as in a case of accommodative asthenopia in a myope of one-sixth, with aching in the eyeballs and shooting pains back into the head, aggravated at the menstrual periods. Cured by Cimicif.—J. H. BUFFUM.

In certain forms of ciliary neuralgia its value has been frequently demonstrated. It is indicated by aching pains in the eyeball or in the temples extending to the eyes so severe, especially at night, that in some instances it seems as if the patient would go crazy; also if the pains are sharp or shooting, extending either from the occiput through to the eyes, from the eyes to the occiput or from the eyes to the top of the head; these pains are generally worse on the right side, in the afternoon and at night, and are ameliorated on lying down.

Macrotin, a resinoid from Cimicifuga, has often been employed in place of the whole drug, especially in ciliary neuralgia. Its action upon the eye is very similar to Cimicifuga, and, by some, it is usually given in preference to the latter. Angell highly recommends

it for hyperæsthesia of the retina. A case of hyperæsthesia of the retina with retroversion of the uterus, characterized by much pain in and above the eyes, intense photophobia and profuse lachrymation is reported cured under Macrotin.²—W. F. FOWLER.

CINA.

Pulsation of the superciliary muscles; a kind of convulsion. A slow stitch extending from above the upper orbital margin deep into the brain. Pupils dilated.

On rising from the bed all becomes black before the eyes, with dizziness in the head and faintness; he totters to and fro; relieved on lying down. Yellow vision.

Clinical.—Cina or Santonine may be of service in strabismus or other ophthalmic disorders depending upon helminthiasis, if the child has a pale, sickly look, with blue rings around the eyes, pain about the umbilicus, boring of the nose, etc.

Santonine has been used with favorable results in asthenopia caused by anomalies in refraction. The second decimal potency was employed.—W. H. WOODYATT.

CINNABARIS.

Inflammation of the eye. Aching soreness of eyes, worse in the evening. *Pain from inner canthus of left eye across eyebrows.* Weakness and sleepiness in the eyes about noon; could scarcely keep them open. *Drawing sensation from right inner canthus across the malar bone to the ear.* Shooting pains in inner canthus of right eye, with a burning and itching. *Pain from right lachrymal duct around the eye to the temple.*

Clinical.—This form of mercury is an important remedy in ophthalmic therapeutics, and the indications for its use are generally very clear.

In various forms of blepharitis, conjunctivitis and keratitis, even when severe ulceration of the cornea has occurred, it has proved especially serviceable, if accompanied by that characteristic symptom of *pain above the eye, extending from the internal to the external canthus, or a pain which runs around the eye, usually above but sometimes below*; this pain may vary greatly in intensity and character, being sometimes sharp, stinging or stitching, at other times dull or

aching, and may extend into the eye or up into the head. The photophobia and lachrymation are usually very marked as well as the redness. The lids frequently feel so heavy that it is with difficulty they are kept open, especially in the evening.

Keratitis parenchymatosa and scleritis, in which there has been more or less pain over the eye, have been benefited by Cinnabar.

In iritis and kerato-iritis it is often called for, especially in the syphilitic variety and if gummata are present in the iris. The chief indication will be found in the characteristic pain over the eye, although, in addition to this, there may be shooting pains through the eye into the head, or soreness along the course of the supra-orbital nerve and corresponding side of the head. *The pains are worse at night*, usually in the evening, though in one case the aggravation was from one to three in the morning.

Asthenopia, with pain extending from the inner canthus around the eye and soreness over the exit of the supra-orbital nerve, worse in the morning; also with pain around the right eye, aggravated in the evening and upon using the eyes; has been relieved by this remedy.

Cinnabar is a very valuable remedy in certain forms of ciliary neuralgia, as indicated by the symptoms already mentioned. The pains are not sharp and lancinating, radiating from one point in various directions as in Spigelia, neither do they follow the course of the supra-orbital nerve as do the pains of Cedron. Kali bichrom. has a similar pain, on the left side.

CLEMATIS.

Inflammation of the white of the eye with lachrymation. Pain in the eye. Burning in the eyes as if fire were streaming out of them, with sensation of dryness.

Clinical.—This remedy has been most useful in iritis or kerato-iritis, in which there has been much dryness and burning heat in the eyes with great sensitiveness to cold air, light or bathing. In one case of chronic syphilitic iritis of two months' standing, with deep ciliary injection, slight pain, especially at night, and posterior synechiæ, a cure followed the use of Clematis¹ for ten days, after both homœopathic and allopathic treatment had failed to relieve him.

COLOCYNTHIS.

Painful pressure in the eyeballs, especially on stooping. Pain in the eyes; a sharp cutting in the right eye-ball.

Clinical.—It is chiefly serviceable in controlling the pains of iritis and glaucoma, with severe burning, sticking or cutting, extending from the eye up into the head and around the eye; or else an aching pain going back into the head, usually worse on rest at night and on stooping and *ameliorated by firm pressure* and walking in a warm room; a sensation on stooping as if the eye would fall out is also sometimes present. The lachrymation is profuse. Dr. Linnell¹ reports a case of irido-choroiditis serosa which was at least aggravated, if not primarily caused, by the use of a Colocynth hair wash.

COMOCLADIA.

The eyes feel very heavy, larger than usual, painful and pressing out of the head, as if something were pressing on top of the eyeballs, moving them downward and outward. *Right eye very painful, feeling much larger and more protruded than the left.* The eyes feel more painful when near the warm stove. Right eyeball very sore, worse on moving the eye. Eyeballs feel worse on moving them.

Clinical.—Ciliary neuralgia, from asthenopia, iritis and a variety of ocular diseases, has been relieved by Comocladia when indicated by the above symptoms.

CONIUM MACULATUM.

Objective.—Whites of the eye yellow. Affected with a weakness and dazzling of the eyes, together with a giddiness and debility of the whole body, especially the muscles of the arms and legs, so that on attempting to walk one staggers like a person who had drunk too much liquor. Partially paralyzed condition of the external muscles of the eye; he could hardly raise the eyelids, which seemed pressed down by a heavy weight and was disposed to fall off to sleep. Pupils dilated.

Subjective.—Pressure in the eyes while reading. Burning in the eyes and on the inner surface of the lids. Aching pain across the

¹ No. Amer. Journ. Homœo., 1887.

eyebrows and mistiness of vision. Itching and pricking in the inner canthus. Smarting in the inner canthus as if something corrosive had got into the eye.

Vision.—Weakness of vision. Double vision. *Sluggishness of accommodation*; vision good for fixed objects, but when an object is put in motion before the eyes there is a haze and dimness of vision producing vertigo.

Clinical.—In superficial inflammations of the eye Conium is a remedy of the first importance; but when the deeper structures have become invaded, not as much benefit has been derived from its use.

Indurations of the lids have been removed and ptosis has been benefited by Conium.

It is, however, in inflammatory conditions of the cornea (ulcers and pustules) that this remedy is chiefly useful, especially if the *inflammation is superficial, involving only the epithelial layers* and caused either from an injury, cold or scrofulous diathesis, the latter of which is most frequently the case. The indications for its use are generally very clear and well marked; thus, the *photophobia*, which is the most prominent symptom, is *excessive*, so that it is with great difficulty that we are enabled to open the spasmodically closed lids, and when they are opened a profuse flow of hot tears takes place (Rhus). Upon examination of the eye we usually find *very slight or no redness*, not sufficient to account for the great photophobia, which is out of all proportion to the amount of trouble. The discharge of mucus or pus is rarely profuse, but intimately mixed with the tears. The pains vary greatly, but are generally worse at night (eye aches on lying down to sleep) and in any light; relieved in a dark room and sometimes by pressure. Hence it appears that Conium is chiefly adapted to those cases in which the nerves are in a state of hyperæsthesia or when only the terminal filaments are exposed by superficial abrasion of the epithelial layer.

Hyperæsthesia of the retina frequently calls for this drug. The following instructive case, in which hyperæsthesia of the retina was a prominent symptom, came under my care about three years ago: Jessie H., æt. 20, had been subject to severe headaches, often with nausea, all her life. Seven weeks previous to my seeing her, upon waking in the morning, she found she could see only dimly, with

great photophobia and loss of color perception. She had been perfectly well (no headache or pain in the eyes) the day before and interested in obtaining a situation which she desired. This condition of the eyes continued, without change, until I saw her, although she had suffered from a mild attack of pneumonia during the interval. There was some leucorrhœa, but no other uterine symptoms. Upon examination found *photophobia so intense that she could not open the eyes*, even in a moderately darkened room, without the aid of blue glasses. She could not see print of any size, not even No. 200, Snellen, though could count fingers at twenty feet. *All colors appeared white*. External and internal examination of the eyes revealed nothing abnormal. There was constant headache in the forehead, somewhat in occiput, worse after 4 P.M. and in the morning, relieved by tying the head up. Conium¹ was given. Upon the next day, when in church, she was attacked with intense pain in both eyes, followed by headache, after which she could distinguish colors. Ten days later the sensitiveness to light had nearly disappeared, the headaches had been relieved and her perception of colors was good. Vision $\frac{1.8}{200}$, but with convex 40 vision $\frac{2.0}{20}$. Could not read without glasses, but with convex 60 could read at usual distance. Under the use of *Ruta grav.*² for about six weeks, both near and distant vision became perfect without glasses (vision $\frac{2.0}{20}$).

By reference to the symptomatology, it will be seen that it must be an important remedy in paralysis of the muscles, especially weakness of the accommodation, in which it has often been of great service. The following case, rapidly cured with Conium, illustrates its use in asthenopia: Can read only a few seconds before the letters run together; burning pain deep in the eyes, with hot flashes; cannot bear either light or heat, is worse in a warm room and better in the mornings and on a cloudy day; black spots are seen on closing the eyes; distant objects appear more distant; objects are surrounded by prismatic colors, out of doors; eyes perfectly normal in appearance.—T. F. A.

CROCUS SATIVUS.

Objective.—Visible twitching of the lids, with a sensation as if something must be wiped from the right eye. Inclined to press the eyes tightly together from time to time. Pupils dilated.

Subjective.—Sensation of soreness in the lids. Feeling in the eyes as though he had wept very violently. After reading a while (even during the day) the eyes pain, with a sore burning and some dimness, so that he was frequently obliged to wink. Feeling as of biting smoke in the eyes. Feeling as though water were constantly coming into the eyes, only in the room, not in the open air.

Vision.—The light seems dimmer than usual, as if a veil were between the eyes and the light; is frequently obliged to wink and wipe his eyes, as though a film of mucus were over them.

Clinical.—The use of Crocus has been chiefly limited to the relief of individual symptoms, arising in the course of various diseases, as indicated by the verified symptomatology.

The chief benefit has been observed from its use in asthenopic troubles, in which the above symptoms are especially found.

The feeling in the eyes as from violent weeping, especially if complicated with the sensation as if something were alive in the abdomen, is well marked and has been relieved by Crocus.

The following clinical symptoms have also disappeared under the use of this drug: Pain in the eye to the top of the head (Cimicif., Lach.). Pain in the left eye darting to the right. A sensation of cold wind blowing across the eyes (Fluoric acid). Constant winking with suffusion of the eyes in tears.—J. T. O'CONNOR.

CROTALUS HORRIDUS.

Yellow color of the eyes. Blood exudes from the eye. Pressure and oppression above the eyes.

Clinical.—The chief sphere of action for Crotalus, in common with the other snake poisons, as suggested by Dr. C. Th. Liebold, is to be found in intraocular hæmorrhages. It has appeared to hasten the absorption of extravasations into the vitreous, though more favorable results have been obtained from its use in *retinal hæmorrhages*. It has been of service in the extravasations into the retina dependent upon various forms of retinitis, but it is especially adapted to those cases which result from a degeneration of the vessels and are non-inflammatory in origin, in which it is more frequently indicated than Lachesis. The latter is, however, very similar to Crotalus in its action upon intraocular hæmorrhages, and general indications must decide between the two.

CROTON TIGLIUM.

Inflammatory redness of the conjunctiva. Copious lachrymation.

Violent pains in the eye. *Tensive pain above the right orbit.*

Clinical.—Croton tig. may be called for in pustular eruptions upon the lids, either with or without corneal or conjunctival complication, especially if accompanied by vesicular eruptions upon the face or head. (Ant. crud., if pustules are confined to the margins of lids.)

That it is an important remedy in herpes zoster ophthalmicus was illustrated in the case of a child in which a vesicular eruption, with much redness of the surrounding integument, appeared along the course of nerves on the right side of the forehead after very severe pain. The pain continued after the appearance of the eruption and was so violent the child could not sleep at night. Some of the vesicles were filled with pus. *Crot. tig.*³⁰ gave immediate relief, after *Rhus*³⁰ had proved of no avail.

In phlyctenular keratitis and conjunctivitis it has been employed with benefit, especially if associated with the characteristic eruption upon the face and lids; the eyes and face feel hot and burning, the photophobia is marked and ciliary injection deep, with considerable pain in and around the eye, usually worse at night.

It is not, however, confined to pustular inflammation in its first stage, but is useful when the pustules have terminated in ulcers and also in real ulceration of the cornea, especially if there is much pain in the supra-ciliary region and an eruption on the face. In one case there was always much pain in the eye whenever a movement from the bowels occurred. *Crot. tig.* immediately relieved.—T. F. A.

CUNDURANGO.

Clinical.—This drug has been very useful in superficial ulceration of the cornea, with varying amount of redness, photophobia and pain, if accompanied by sores or cracking of the corners of the mouth.

CUPRUM ACETICUM.

Clinical.—The acetate of copper has proved beneficial in insufficiency of the external recti muscles.—J. H. BUFFUM. The following case of paralysis of the left nervus abducens is reported by C. Heinigke in *H. Kl.*: A young man, æt. 29, was suddenly taken,

on leaving the cars after several hours of railroad ride, with indistinct and double vision. The above diagnosis was fully confirmed and electricity with iodide of potash was used for three months with no change. No other symptoms were present, with the exception of slight frontal headache, of which the patient had been suffering for years. Sulphur and Rhus did little good. Cuprum acet., first 3, then 6, and afterwards 30, in repeated doses and at gradually increasing intervals cured the case within a few months.

CUPRUM ALUMINATUM.

(The preparation of aluminate of copper most commonly employed is the so-called "Lapis divinus," which is composed of equal parts of sulphate of copper, nitrate of potass. and alum.)

Clinical.—The aluminate of copper has been successfully used to a great extent in trachoma, to which condition it seems especially adapted. The results obtained are usually more satisfactory than those found from the sulphate of copper, which is the main reliance of the old school in the treatment of this disorder. It is used by application of the crystals to the granulations, at the same time giving the remedy in the potencies internally. Cuprum al. has been of service in conjunctivitis pustulosa with inflammation of the lids, though it cannot be often indicated in this affection.

Benefit has been derived from its use as a local application to opacities of the cornea. Its irritative action serves to stimulate the absorption of the new cells in the cornea which result from inflammation.

CUPRUM SULPHURICUM.

Clinical.—The sulphate of copper is one of the most efficient local applications employed by the old school in many superficial troubles of the eye, chief among which may be mentioned granular lids, although it has also proved beneficial in both catarrhal and purulent conjunctivitis.

DIGITALIS.

Pupils dilated. Objects seem green or yellow. In the evening while walking it seemed as though the upper part of the field of vision was covered by a dark cloud.—Digitalin.

Clinical.—This remedy is reported to have been beneficial in some

cases of superficial inflammation of the eye, but I have never had occasion to confirm its usefulness in ophthalmic inflammation.

Some benefit has seemed to follow the use of Digitalis in detachment of the retina, especially in relieving such disagreeable symptoms as wavering before the eyes and the appearance as if everything were green.

DUBOISIA.

(The sulphate of Duboisin is more commonly used than the whole plant, Duboisia, but as the two are so similar in action, both will be considered under the above heading.)

Objective.—Lids slightly œdematous. Agglutination of lids in the morning. Dilatation of the pupil. *Vessels of the optic disc much enlarged and tortuous*, so as to be easily visible. *Disc red and outline indistinct. Retinal veins dilated and tortuous.* Retinal arteries diminished. *Fundus of the eye generally very hyperæmic.*

Subjective.—Eyes hot and dry. Eyes feel tired as if overworked. *Pain in eyeball, just beneath brow. Sharp pain in the upper part of the eyeball.*

Vision.—Complete *paralysis of the accommodation*; could not read at any distance and could not look at food while eating, on account of pain. Can read better and the print looks blacker at double the usual distance. Paralysis of the accommodation takes place before dilatation of the pupil and continues after the latter has recovered.

Clinical.—From a very valuable paper upon the clinical and physiological action of Duboisin, by Dr. Charles Deady in the *Trans. of the Am. Hom. Oph. and Otol. Soc.*, 1880, the following conclusions upon its usefulness in diseases of the cornea and conjunctiva are cited: "The results obtained in the cases of ulcer of the cornea, in which it has been used, are sufficiently good to warrant a trial in cases which prove intractable under other remedies. So far as we have been able to observe it seems to be adapted to a slow form of ulcer, more or less deep and *without* severe photophobia and lachrymation; in cases of superficial ulceration, or in which much photophobia was present, we have thus far obtained no benefit from its use.

"The drug has been successfully used in several cases of *chronic hyperæmia of the palpebral conjunctiva*, involving to some extent the

borders of the lids. The symptoms calling for its use in this condition strongly resemble those of Aconite, viz., bright redness of the palpebral conjunctiva, with heat and dryness of the eye. The difference between the two drugs consists in the fact that the hyperæmia which Duboisin cures is a *chronic affection*, such as is found in hyperopes and which is not always relieved by the use of glasses."

In diseases of the fundus, especially of the optic nerve and retina, Duboisin has proved, as might be expected, an important remedy. Its value in *hyperæmia of the retina associated with weakness of the accommodation* is well illustrated in the following cases by Dr. Deady:—"May 17, Mrs. C. Ophthalmoscope shows retinal veins very much swollen and tortuous; arteries about normal; fundus in other respects normal. There is much frontal headache; sharp pain through upper part of eyeballs from front to back, very much aggravated by artificial light; eyes feel hot and dry; conjunctiva of lids hyperæmic; sight has been growing dim for last two months; V. = $\frac{20}{30}$; Hm. = $\frac{1}{60}$, with which V. = $\frac{20}{20}$. Accommodative asthenopia; print blurs when held as near as eight inches. R. Duboisin³, three hours.

"May 20th. Better in every respect; no headache; no pain in eyes; ophthalmoscope shows fundus to be normal; conjunctiva normal; can read without any discomfort.

"CASE II.—Lady, æt. 21. May 18th. Cannot read by gaslight; dry, disagreeable feeling in eyes, pain and burning; lids swollen so as to almost close palpebral aperture; conjunctiva of lids very hyperæmic; lids very œdematous, look like two bags of water. These symptoms would all be brought on by reading one-half hour in a room artificially lighted, or would come on without reading if she remained in the room an hour. Print blurred when read from eight to ten inches; ophthalmoscope shows a marked hyperæmia of fundus; hyperæmia of conjunctiva of the lids so great that it had been diagnosed by former physician as granular lids. V. $\frac{20}{30}$; Hm. = $\frac{1}{60}$, V. $\frac{20}{20}$. R. Duboisin³, four times a day.

"May 21st. Very much better; eyes look well; lids normal; V. = $\frac{20}{20}$; fundus normal.

"May 25th. Eyes normal."

In *optic neuritis* and *retinitis* Duboisin is, no doubt, often indicated, for several cases have yielded promptly to its influence, as the fol-

lowing will illustrate: A man, æt. 42, had suffered from attacks of vertigo for three months. There was a history of syphilis twenty years and of a blow on the head seventeen years before. When first seen he complained of sleeplessness day and night, severe headache from the back of the neck over the head to the eyes, worse at night, and eyes painful as if the balls were being pressed into the head. V. $\frac{2}{0}$ o. u. with difficulty. The ophthalmoscope revealed a typical picture of "engorged papilla" in each eye, marked enlargement of vessels on the disc and extravasations on the right optic papilla and in the retina immediately around it. Bell,³ was given for ten days with slight change in the symptoms except that hæmorrhages were found on both discs, pain above the eyes with constant aching in them and heavy pressure on the vertex, worse in the morning. Within two weeks under Duboisin² the pain in the head had been relieved, the hæmorrhages in the nerves and retina had disappeared, and the inflammation was decidedly less. V. $\frac{2}{0}$ o. u. There were one or two slight aggravations after this, but not important, when the patient was lost sight of.

True weakness of the accommodation may call for this remedy, as already suggested by the symptomatology and the cases of hyperæmia of the retina (compare Ruta, Con., Arg. nitr.). I use the term "true weakness," for I believe many of the so-called cases of asthenopia are dependent upon an "irritable weakness" of the accommodation, which is controlled by Jaborandi or one of that class of drugs.

ELECTRICITY AND GALVANISM.

Clinical.—The sphere of electricity in eye diseases, while at present limited, is, we think, capable of much further extension. The reason of this limitation, we believe, lies in the fact that the oculist too little understands the true principles of electricity to try it in diseases where it might be serviceable, while the electro-therapist, not having the sufficient number of eye cases necessary to form scientific data, has not the opportunity to give this agency the thorough trial it should receive in order to demonstrate its true value in ocular diseases.

Commencing with the eyelids, we find electrolysis of the utmost value in the very annoying and obstinate condition of *trichiasis*.

Epilation gives but temporary relief of the condition and has to be frequently repeated. Plastic operations are not always successful and only usually made when there is complete incurvation of all the lashes. In those partial cases of trichiasis, when only a part of the hairs turn in, electrolysis is the ideal treatment.

The use of electrolysis in trichiasis was first suggested by Michel, of St. Louis.

It is best to use a triangular platinum or gold needle, which is to be inserted into the hair follicle and then connected with the negative pole of an eight to twenty cell battery, while the positive pole is applied to the temple. Minute bubbles of gas appear around the needle and the tissue whitens when the circuit is closed. The current should be continued for about a minute or until the hair can be removed without resistance. When properly applied the hair bulb is destroyed and the hair will not grow again.

Angiomata or vascular tumors of the lid or orbit are also better removed by electrolysis than by any other method or operation. When the growth is small the negative pole may be applied by a sponge to the temple, but if large both poles should be attached to platinum needles two or three inches in length, which are then to be inserted into the tumor. The positive needle should remain in one position while the negative may be inserted at different points for a few minutes at a time. The first sitting should be brief and careful notice taken of the reaction, as sometimes a too severe inflammatory reaction occurs. Other growths, even epithelioma, have been destroyed by electrolysis.

Blepharospasm has been successfully treated by galvanism. In this it is best to apply the positive pole behind the mastoid and the negative on the eyelid.

In *strictures of the lachrymal duct*, electrolysis has been especially advocated by some. We have used it in a great many cases with universally good results; it seems, however, to be particularly adapted to chronic strictures associated with blenorrhœa of the sac. The beneficial results are evidenced by an improvement in the blenorrhœa as well as in the stricture itself. My method of using electrolysis in these cases is to insert the ordinary lachrymal probe in the usual way until it comes in contact with the stricture, then attach the upper end of the probe to the negative pole, holding the positive

on the temple; make gradual pressure until the stricture yields. The electrolysis, repeated at four or five sittings, is usually sufficient to keep the passage permanently opened.

Granular and Follicular Conjunctivitis.—I have seen cases of true trachoma very materially benefited by the use of electricity, while in follicular conjunctivitis I believe all cases that followed the treatment at all regularly were wholly relieved. The cases of trachoma were treated with the double electrode applied directly to the conjunctiva after the use of cocaine. The follicular cases were treated by puncturing the follicles, which renders the course of such a treatment necessarily long and tedious.

George Lindsay Johnson, of London, describes in the *Archives of Ophthalmology*, vol. xix., a new method of operating upon cases of trachoma by electrolysis and claims for it very favorable results. His plan is to make incisions parallel to the free border of the lid through the whole breadth of the conjunctiva by means of a three-bladed scalpel, the depth of the incision to be regulated by the swelling or thickening of the conjunctiva. The electrolyzer, made of two platinum blades, is then drawn slowly along the furrows made by the scalpel, all the grooves being taken in turn. He says the best results are obtained by using a current of about thirty milliamperes and cautions against using a stronger current.

In diseases of the cornea we find at present only a limited sphere for the use of electricity. The galvanic current has a favorable effect in the rare disease of *neuro-paralytic keratitis*, and as other treatment has proven of but little value in this affection, its use should always be tried. In *corneal ulcers*, especially of the serpiginous and crescentic varieties, the use of the galvano-cautery has proven of great value. Its use in this disease is to destroy the septic material lining the base and sides of the ulcer. In using it the galvano-cautery loop is brought to a red heat and, with the lids opened and the eye steadied with the left hand, the red hot loop is applied directly to the zone of propagation. The eye, previously cocainized, suffers no pain. The resulting eschar is thrown off in about twenty-four hours and the cornea heals with a less dense macula than under any other mode of treatment. Care should be taken that the patient does not see the cautery before it is applied, as the knowledge that a red hot wire is to be applied to the eye is

not generally conducive to steadiness of the eye. By continuing the application of the loop a moment longer the floor of the ulcer can be perforated when desirable and the hypopyon evacuated.

In *exophthalmic goitre* cases that seem well authenticated have been reported cured by galvanization of the sympathetic.

The use of the electro-magnet in removing particles of iron and steel from the eye has been very generally adopted by oculists and many successful cases have been reported.

The results as to vision are always far more favorable if used very soon after the injury. Various magnets have been used for this purpose, that of Hubbell being perhaps the best on account of its size, shape and power. If the particle has penetrated into the interior of the eye, as for example the vitreous, and the wound is still open, it should first be made somewhat larger, so that the foreign body will not be scraped off from the magnet when it is withdrawn. The needle of the magnet is then to be inserted into the wound and as near as possible to the foreign body, which can sometimes be located by the ophthalmoscope. In this way particles of steel weighing twenty milligrammes have been removed from the vitreous and the eye recover with perfect central vision.

In *muscular* troubles of the eye we find, however, perhaps the most extended and general use of electricity. Cases of paralysis, both complete and partial, of all the ocular muscles, have been restored by this agency. It is usually applied by placing one electrode (some say the positive and others the negative) over the affected muscle, while the other is placed upon the brow or at the back of the neck; it should be applied regularly every day or two and from one to three minutes at each sitting. The current should be constant at first and then interrupted a few times at each application. It should also be used as strong as possible without causing too much discomfort.

In cases of muscular insufficiencies where we are trying to restore power to the weakened muscle by the systematic exercise with prisms, it is our universal rule to apply electricity for a minute or two after each treatment and to this use of electricity we attribute much credit in the restoration of the muscle power. It certainly leaves a very grateful sensation to the eye when gently used and often the patient states that the eyes feel rested and stronger after

its use. It has been and is claimed by some that electricity gives beneficial results in various diseases of the lens, choroid, retina, optic nerve, etc., but with these the writer has had no experience and finds no sufficiently accurate evidence to warrant a favorable opinion of its use.

ESERINE.

No proving of Eserine, an alkaloid of Calabar bean, has been made, but it is very extensively employed in ophthalmic practice. In the *Medical Analectic*, October, 1887, we find recorded a poisoning from a solution of gr. j to ʒj. About one-half hour after the instillation of one drop of this solution in the eye severe clonic spasms of the eyelids set in; a quarter of an hour later spasmodic stiffness of the lips, especially the upper, set in, and soon the same sensation under the jaw on the left side. Within an hour there was a feeling of tremor or spasm in the arms or thighs and at the same time a sensation of pressure on the eyeballs and of weight and pressure within the head. Mental confusion and memory impaired; slept uneasily, waking often; pupils contracted to a pin point and conjunctiva injected. The action of Eserine upon the ciliary muscle is to stimulate its contraction and diminish the range of accommodation. It is, therefore, as pointed out by Macbride, homœopathic in spasm of the accommodation. It has also proven of value clinically in ulcerations of the cornea.

Laqueur,¹ of Strassburg, first recommended the instillations of Eserine in the treatment of glaucoma. Since then it has been used by most oculists with varying success. There is no doubt that in some cases it may relieve the intra-ocular tension temporarily, if not permanently. Its action is chiefly, if not wholly, mechanical. By acting upon the muscular tissue of the vessels it causes a contraction in their calibre, or, as is more probable, by drawing away the iris from the angle of the anterior chamber the filtration passages are opened and so excretion accelerated. It should not be substituted for iridectomy, however, but be reserved for exceptional cases, as, for instance, when the operation must be postponed for one reason or another, or when the tension increases after an iridectomy, or in some cases of secondary glaucoma.

¹ Archiv. für Ophthalmologie, xxiii., 3.

The following case in which Eserine proved beneficial is of interest: A woman had a cataractous lens dislocated into the anterior chamber by a blow on the temple two days previously. There was conjunctival irritation, much photophobia and lachrymation, with severe throbbing pain in eye and right side of head. The tension of the eyeball was increased. "I decided to remove the lens at once, and succeeded, after some difficulty, in doing so. During the next twenty-four hours the tension remained normal and the wound tended to heal kindly. On the second morning following the removal of the lens she complained greatly of pain, which had kept her awake during the night and still continued. The upper lid was swollen and œdematous. The borders of the cut for a space of two or three lines were hazy and infiltrated, a slight stringy and mucous discharge had occurred, and the tension of the eyeball had again increased. A solution of Eserine $\frac{1}{2000}$, one drop every two hours, was instilled into the eye, and Eserine, the 3d trituration, a dose every two hours, was prescribed. In the course of twenty-four hours the tendency to sloughing had ceased and a rapid recovery followed."—
D. B. HUNT.

Eserine has been recommended by prominent specialists of the old school for a variety of ocular diseases, as conjunctivitis purulenta; keratitis, especially suppurative; kerato-conus; asthenopia, muscular and accommodative. Harlan¹ reports eighteen cases of corneal ulcers after injury, all of which were cured with Eserine. And it is being recommended now in much weaker solutions than formerly, $\frac{1}{1000}$ or even $\frac{1}{4000}$ being considered strong enough by some. Personally we have seen perfect contraction after cataract extraction without iridectomy from a $\frac{1}{1000}$ solution.

EUPATORIUM PERFOLIATUM.

Soreness of the eyeballs.

Clinical.—As an intercurrent remedy in various affections in which excessive soreness of the eyeballs has been a prominent symptom, this drug has been very useful.

EUPHRASIA.

Objective.—*Redness and swelling of the margins of the lids, with at times an itching burning in them and increased watery discharge.*

¹ Med. Rec., June 23, 1888.

Margins of lids red, with dry sensation. The lids are swollen and red. Injection of conjunctival vessels. Lachrymation profuse; *tears acrid and burning.*

Subjective.—Burning and pressure in the eyes, with much lachrymation. Biting in the eyes at times; biting water runs from them. Burning, biting in the eyes, obliging frequent winking. Itching of the eyes on going out, obliging frequent winking and wiping of the eyes, with increased lachrymation in the afternoon. Burning in the margins of the lids, with distressing sensation of dryness. The lids are sensitive and swollen. *Feeling as though the cornea were covered with much mucus; it obscures his vision and obliges him to frequently close and press the lids together.* Vision somewhat dim, as through a veil, in the evening. Eyes sensitive to candle-light.

Clinical.—The indiscriminate use of Euphrasia in all cases of ophthalmia, as prescribed by many practitioners, is not to be imitated, for although it is a remedy of great importance, especially in superficial diseases of the eye, still its sphere of action is well defined.

The results of many cases have proved its value in blepharitis. When indicated, the lids will be found red, swollen and covered with a *thick, yellow, acrid discharge, together with profuse acrid burning lachrymation, which makes the lids and cheek sore and excoriated;* firm agglutination of the lids in the morning is also present and fluent coryza often accompanies the eye symptoms.

The cases of catarrhal and strumous inflammation of the cornea and conjunctiva, which speedily respond to this drug, are to be counted by scores, for it is in these cases that Euphrasia is especially efficacious. It is useful in both the chronic and acute form of inflammation, but especially in the latter, as follows: Catarrhal inflammation from exposure to cold; catarrhal inflammation of the eyes and nose in the first stage of measles; papillary trachoma with or without pannus; pustules on the cornea and conjunctiva; superficial ulceration of the cornea (sometimes accompanied with pannus), though is rarely indicated in the deep form, except, perhaps, as a palliative in the first stage. In all the above cases we usually find much photophobia, though it may be nearly absent. The lachrymation is profuse, acrid and burning, as is also the thick, yellow, muco-purulent discharge, which is usually present excoriating the

lids, making them red, inflamed and sore, as well as giving the cheek an appearance as if varnished. The conjunctiva may be quite red, with chemosis. The pains are not characteristic though usually smarting, sticking or burning, from the nature of the discharges. Fluent coryza often accompanies the above symptoms.

The blurring of the eyes, relieved by winking, so often found in superficial inflammations of the eye, and due to the secretions getting upon the cornea, thus interfering with vision, and then carried away by the movement of the lids in winking, is a simple symptom, which is almost invariably relieved by Euphrasia.

Purulent ophthalmia has been benefited, particularly that form found in new-born children (ophthalmia neonatorum). The condition of the lids and nature of the discharges already given, which indicate its choice, will be found more often in the later stages than at the beginning of the disease.

The following case indicates that it may be useful in paralysis of the muscles: A man, æt. 52, appeared for treatment, with total paralysis of the oculo-motor nerve, even to those filaments which supply the iris and ciliary muscle, which came on rapidly after exposure in the cold and wet. Electricity was applied every day or two for about five weeks, and either Rhus or Caust. given internally at the same time, with no benefit. At the end of this time, on account of some slight catarrhal symptoms, Euphrasia³⁰ was given and the electricity continued. After taking two doses of Euphrasia the upper lid could be slightly raised, the pupil began to contract and the eye to turn inward; within four weeks a complete cure was effected.

Euphrasia is very similar to Mercurius in the character of its discharges, only that in Merc. they are thin and excoriating, while under Euphrasia they are thick and excoriating. Arsenicum also has acrid secretions, but they are usually thin, not as profuse as in the above remedies and are accompanied by much burning pain and photophobia. Rhus, like Euphrasia, has profuse lachrymation, but it is not as excoriating. In paralysis of the muscles, caused by exposure to cold or wet, Euphrasia may be compared to Caust. and Rhus, the remedies upon which we chiefly rely in these affections, but it seems especially called for when a catarrhal condition of the eye is, at the same time, present.

FERRUM.

Sticking pain over the left eye, coming suddenly and lasting a short time only.

Clinical.—The iodide of iron has been used by Dr. Liebold with benefit in exophthalmic goitre. In one case, occurring in a woman after suppression of the menses and characterized by protrusion of the eyes, enlargement of the thyroid gland, palpitation of the heart and excessive nervousness, the menses soon reappeared, the nervousness diminished and all the symptoms improved after the administration of Ferrum iodatum. Another similar case, occurring in a colored woman, was relieved by the acetate of iron.

FERRUM PHOSPHORICUM.

First stage of abscess of the cornea, for the pain and redness. Inflammation of the eyes, with acute pain, without secretion of mucus or pus. Acute conjunctivitis. Conjunctivitis and photophobia in measles. Pain in the eyeball aggravated by moving the eyes. Retinitis. *Eyes inflamed, red with burning sensation, sore and red looking. Sensation as if grains of sand were under eyelids.*¹

Clinically this remedy has proven of great value in parenchymatous keratitis where there is excessive inflammation. The cornea appears as though a hæmorrhage had occurred in its layers. Excessive lachrymation and photophobia.

FLUORIC ACID.

Sensation as if the eyelids were opened by force and a *fresh wind were blowing on them*; after that, sensation like sand in the eyeball, which had the same feeling as if the eyes were inflamed.

Clinical.—A case of lachrymal fistula on the left side, of one years' duration, with a clear, yellow scab on the cheek, near the inner canthus, which is but slightly red and painful to pressure. Every three or four days it begins to itch, grow moist, then heals again; it is sometimes painful before it opens. Fluoric acid³⁰ cured.

—C. HERING.

The symptom, *as if cold wind were blowing in the eye*, has been frequently verified in various ophthalmic diseases.

¹ The Twelve Tissue Remedies, Boericke & Dewey, 1888.

GELSEMIUM.

Objective.—*Drooping of the eyelids.* Eyelids half closed, with apparent inability to move them. Lids close on looking steadily at anything. Irritability of the conjunctiva. Pupils dilated.

Subjective.—Soreness of the eyeballs. *Great heaviness of the lids.* Drawing over the eyes. Dull, full feeling (attended with some aching) in the whole of the orbits. Eyes tire upon using for near vision. Pain running from over the eyes to the occiput, aggravated on the right side. Bruised pain above and back of the orbits.

Vision.—Dimness of vision. *Dimness of sight and vertigo.* Glimmering appearances before the eyes. *Smoky appearance before the eyes, with pain above them.* Objects appear double. Diplopia which can be controlled by an effort of the will. Diplopia when inclining the head toward either side, but vision single when holding the head erect.

Clinical.—Gelsemium is rarely found of benefit in superficial affections of the eye, but is especially adapted to diseases of the fundus and paralysis of the nerves.

Its action upon the uveal tract is very marked, especially in the serous form of inflammation, either when it involves the iris, ciliary body and choroid separately or all three at the same time. In serous iritis, the hypersecretion and cloudiness of the aqueous humor, together with moderate ciliary injection and varying amount of pain in the eye and head, will be our chief indications. (Compare with Kali bichrom., which is the remedy for descemetitis, improperly classed by some authorities under serous iritis.)

In *serous choroiditis* Gelsem. is a remedy of the first importance. According to Dr. W. A. Phillips in a paper read before the Am. Hom. Ophth. and Otol. Soc., in 1881, the symptomatic indications for its use in serous choroiditis are: "1. A dull pain in or about the eye, extending all of the time, or periodically, or finally, to the back of the head, and ameliorated by hot applications, but not by cold. 2. Impairment of vision gradually developed and not characterized by sudden changes, either for the better or the worse. 3. Heaviness of the lids. 4. Inability to accommodate the eye quickly for varying distances. 5. The asthenopic symptoms not marked by great irritability of the eye, but resulting from an evident want of tone or energy of the muscular structures—in other words, a passive asthe-

nopia rather than active. 6. In general, a feeling of depression and lassitude, which is not relieved by food or stimulants." In addition to the above it will usually be found that the haziness of the vitreous is very fine, the tension tends to increase, the pupil to dilate and the eyeball to become sore to touch, with aching pain over and in the eye. The impairment of vision is not necessarily constant, as it may vary greatly, being one day very dim and the next quite bright. Many cases, illustrative of the marked benefit to be obtained from this drug could be given, but I will only briefly report, on account of certain peculiar symptoms present, the first case¹ in which it was employed. Mrs. T., æt. 56, of dark complexion and bilious temperament, had been suffering from a serous inflammation of the choroid for nearly three months. The vitreous was so hazy that the fundus could not be seen. The vision was so nearly lost that she could hardly count fingers. The eyes were somewhat red and irritable, the pupils slightly dilated and T + (?). There was constant sore, aching pain in the eyes and around, with sharp sticking pain on moving the eyes. Byronia, as well as several other remedies, had been used with temporary relief at times. At last, in addition to the above symptoms, small transparent points, elevations of the epithelium, made their appearance on the right cornea, looking like the swollen ends of nerve filaments; they were excessively sensitive to touch or any movement of the lids and would come and go suddenly, often in the same day; after two days they became permanent and were very painful. Gelsem.³⁰ was given, when they gradually disappeared, the vitreous cleared and the vision was completely restored within two weeks.

Its usefulness in serous inflammation of the whole uveal tract (irido-choroiditis) is sufficiently illustrated in the following case: A woman, æt. 32, had complained of the eyes being weak for two months, but worse recently. Right vision $\frac{2}{10}$ with difficulty. Left vision, counted fingers at 20 feet. Ophthalmoscope showed serous inflammation of the iris and choroid, deposits on the membrane of Descemet, aqueous and vitreous hazy in both eyes and left pupil dilated and sluggish. There was a sensation of pressure over both eyes and headache in the temples. She was a seamstress and would not take proper rest. R. Gelsem.³⁰. Two weeks later she reported

¹ Reported in detail in Hahnemannian Monthly, Nov., 1875.

that she began to improve immediately on taking the above powders, had taken no other medicine and had used the eyes all the time for sewing. Right vision $\frac{2}{30}$ with difficulty. Left vision $\frac{2}{30}$ with difficulty. Eyes appeared perfectly well, with the exception of a few small points on the posterior surface of the cornea and slight dilatation of the left pupil, which eventually disappeared.

From its value in serous inflammations and from some temporary benefit derived from Gelsemium in glaucoma, it is recommended for this disease, especially if dependent upon increased secretion. (Glaucoma is probably usually due to obstruction in excretion.) Dr. F. Park Lewis reports that it has been of use to him in "one case of glaucoma after iridectomy. Notwithstanding a large coloboma in both eyes, the sight began to diminish and pain and tenderness to come back in the head. Gelsem.¹ relieved the pain and somewhat benefited the sight."

This remedy has been of service in some cases of disseminate choroiditis and chorio retinitis—in one case there seemed to be a bluish snake before the vision.—T. F. A. Dr. C. M. Thomas writes me: "In disseminate choroiditis and retino-choroiditis with no outside symptom, the good effect of Gelsem. is undoubted and it is used by me almost to the exclusion of other remedies."

A case of retinitis albuminurica, in which the dimness of vision came on suddenly during pregnancy and was worse after delivery, was cured under Gelsemium. There were white patches and extravasations of blood throughout the retina, while the outer part of the optic nerve appeared whiter than usual. There was no pain, only an itching of the eyes.—T. F. A.

Another great sphere of usefulness for this drug is to be found in *detachment of the retina*. Dr. F. H. Boynton first reported, in the *American Observer*, a case cured under Gelsem. in which the detachment had been present three weeks and was dependent upon an injury. It was accompanied with diffuse haziness of the vitreous and serous inflammation of the choroid and retina. In one month, under Gelsem.³⁰, the vision improved from perception of light to $\frac{2}{70}$ and the retina became completely re-attached. Since then similar results have been obtained from its use in detachment of the retina, from myopia. (Compare Arnica and Aurum.) It is no doubt the most commonly indicated remedy in this affection.

In paresis or paralysis of any of the ocular muscles, decided benefit has often been derived from the use of this remedy. It has been of service in paralysis following diphtheria (Buffum), and when associated with paralysis of the muscles of the throat, although often when indicated there is a complete lack of all subjective or objective symptoms, with the exception of the impairment of the muscle.

In asthenopia, dependent upon weakness of the external recti muscles, Gelsem. was highly recommended by Dr. W. H. Woodyatt. As a remedy for clearing up troublesome asthenopic symptoms, even local irritations, such as blepharitis and conjunctival hyperæmia, due to refractive errors, Dr. C. M. Thomas has found it more serviceable than any other drug.

In paralysis of the nerves, compare Gelsem. with Caust., Conium and Rhus, and in serous choroiditis compare with Bryonia. The condition which indicates Gelsemium is usually one of stolid indifference to external irritants, in which respect it stands in marked contrast to Conium, whose paralytic symptoms are characterized by great reflex irritability, photophobia, etc.

GRAPHITES.

Objective.—A sty on the lower lid, with drawing pain before the discharge of pus. Red, painful inflammation of the lower lid and inner canthus. *Very inflamed margins of the lids. Inflammation of the external canthus. Dry mucus in the lashes. Agglutination of the eyes in the morning. Redness of the whites of the eyes, lachrymation and photophobia. Lachrymation.*

Subjective.—Sensation of dryness in the lids and pressure. Heaviness of the lids. Heat about the lids. Heat, burning and biting in the eyes.

Vision.—Vanishing of sight during menstruation. Intolerance of light, with redness of the eyes. *Great sensitiveness of the eyes to daylight.*

Clinical.—There are few remedies in the materia medica so commonly indicated in inflammatory conditions of the lids, conjunctiva and cornea as Graphites, especially if occurring in scrofulous subjects, with eczematous eruptions, which are moist, fissured, bleed easily and are situated chiefly on the head and behind the ears.

It is particularly indicated in the *chronic form of blepharitis*, or in eczema of the lids, though sometimes called for in acute attacks, especially if complicated with such affections of the cornea as ulcers and pustules. In chronic ciliary blepharitis, in which Graphites is useful, *the edges of the lid will usually be found slightly swollen and of a pale red color; the inflammation may be confined to the canthi (blepharitis angularis), especially to the outer, which have a great tendency to crack and bleed easily upon any attempt to open the lids; the margins may be ulcerated; dry scurfs are usually present on the cilia; there may be burning and dryness in the lids and biting and itching, which cause a constant desire to rub the eyes. (Compare with Antimon. crud., which is adapted to pustules on the margins of the lid.)*

In one case of slight roughness of the integument of the lids, with intense itching, which had been present for a year or more, quick and permanent relief was obtained from Graphites.

It is of service in preventing the recurrence of successive crops of styes. It is also valuable in eczema of the lids if the eruption is moist and fissured, while the margins of the lids are covered with scales or crusts.

In catarrhal ophthalmia Graphites has been employed with benefit, and in scrofulous ophthalmia characterized by ulcers and pustules it is second to no other drug in importance. It has cured deep ulcers of the cornea, even with hypopyon, but it is more particularly adapted to superficial ulcerations, especially if resulting from pustules; often with considerable vascularity of the cornea. The pustules which have been removed under the influence of Graphites have been of various kinds and accompanied by various symptoms; they may be either on the cornea or conjunctiva, but especially on the former; the attacks may be acute or chronic, but it is particularly called for in the chronic recurrent form.

The following case illustrates very markedly the action of this remedy: A boy had been troubled for a long time with chronic pustular inflammation of the cornea. No sooner would he recover from one attack before another would appear. There was great photophobia, so that he could not open his eyes to see his way; profuse lachrymation; burning and aching in the eyes, sneezing upon opening them; *external canthi cracked and easily bleeding; both corneæ*

pannoused; thin acrid discharge from the eyes, and *nose sore and surrounded by thick moist scabs*. Under the influence of Graph. a rapid and permanent cure was effected.

The *photophobia* is usually intense and the lachrymation profuse, though in some cases nearly or entirely absent; it is generally worse by daylight than gaslight and in the morning, so that often the child cannot open the eyes before 9 or 10 A.M. The redness of the eye is generally marked and the discharges of a muco-purulent character, constant, thin and excoriating. The pains vary and are not important, being sometimes sticking, burning, aching or itching in character. The lids are red, sore and agglutinated in the morning or else covered with *dry scurfs* and the *external canthi are cracked and bleed easily* upon opening the eye. A thin, acrid discharge from the nose often accompanies the ophthalmias of Graphites.

Graphites is somewhat similar to Hepar and Sulphur in scrofulous inflammation of the eyes. Under Graphites, however, the discharges from the eyes and nose are thinner and more excoriating, and there is a greater tendency toward cracking of the external canthi. The latter symptom is also sometimes observed under Hepar, but is not as marked, and the discharge is not as excoriating, though the lids are more swollen, eyes redder and ulceration deeper. The Sulphur patient is more restless and feverish at night, and complains of occasional sharp sticking pains in the eye; though the face and body may be covered with eruptions, they differ in character from those of Graphites.

HAMAMELIS VIRGINICA.

Clinical.—A spontaneous eversion of the upper lid during the course of a severe conjunctivitis was relieved by the application of dilute "Pond's Extract."—W. S. SEARLE.

This remedy has been employed with decided success in inflammation of the conjunctiva or cornea, even in ulceration of the latter, if caused by a burn or an injury.

The action of Hamamelis in injuries of the eyeball is very similar to that of Arnica and Calendula, although it seems to be of more service than either of the above in *hastening the absorption of intra-ocular hæmorrhages*. Illustrative of this point is a case which came under my observation this day. A colored boy was brought to my

clinic two days ago on account of an injury of the left eye received two days previously. The cornea was abraded, there was some blood in the anterior chamber and the vitreous was so dark from hæmorrhage into it that the fundus could not be illuminated. There was only perception of light. *Hamamelis virg.*³ was given internally, and the tincture, 10 drops to the ounce, used externally. To-day (after two days) his vision is $\frac{20}{50}$ and only slight haziness of the media remains.

Traumatic iritis with hæmorrhage into the iris and traumatic iritis with great pain at night and hæmorrhage into the interior of the eye have been speedily relieved by this drug.

HEPAR SULPHUR.

Objective.—*Redness, inflammation and swelling of the upper lid, with pressive pain.* The lids are closed in the morning on waking, so that she cannot open them for a long time. Inflammation and swelling of the eye, with redness of the white.

Subjective.—Smarting pain in the external canthus, with accumulation of hardened mucus. Pains in the eyes from the daylight. Feeling as if the eyes were being pulled back into the head by strings. *The eyes are very painful in bright daylight if he attempts to move them.* Pressure in the eyes, especially on moving them, with redness. Eyes sore, agglutinated at night; secretion of hardened mucus. Pressive pain in the eyeballs and a feeling as if beaten when touched.

Vision.—Obscuration of vision while reading. The eyes become dim and he cannot see well in the evening by candle-light. Feeling of blindness before the eyes on rising and standing up after sitting bent over. Field of vision reduced one-half. Complains of a continual movement of bright circles before the eyes.

Clinical.—In dacryocystitis and orbital cellulitis Hepar is a remedy of importance, especially if *pus has formed and there is great sensitiveness to touch, with throbbing pain.* It may prevent the formation of pus or accelerate its discharge; it also seems useful in controlling the discharge after the canaliculus has been opened.

Hepar may be called for in chronic ciliary blepharitis if complicated with swelling of the meibomian glands, or ulcers and swellings on the margin of the lid, which are painful in the evening and

upon touch, though its chief sphere of action in palpebral diseases is in acute phlegmonous inflammation of the lids, which tends toward suppuration. The inflamed lids will be swollen, tense and shining, as if erysipelas had invaded them, with *throbbing*, aching, stinging pain and sensitiveness to touch; *the pains are aggravated by cold and relieved by warmth.*

Eczema of the lids, in which thick honey-comb scabs are found both on and around the lids, with nocturnal agglutination, etc., is especially amenable to Hepar.

Palpebral tumors have frequently disappeared under its use.

It is sometimes useful in simple catarrhal conjunctivitis after the inflammatory stage has passed, and also in some cases of purulent conjunctivitis characterized by profuse discharge and excessive sensitiveness to air and touch. Pustules on the conjunctiva may require its use, but not usually, unless the cornea has become involved.

For the severer forms of strumous ophthalmia, in which the pustules and ulcers invade the cornea and are marked by great intensity of the symptoms, there is probably no remedy more frequently indicated than Hepar. Its value in *ulcers and abscesses of the cornea*, especially the deep sloughing form of ulcer complicated with hypopyon, is undoubted. It has proved curative in some torpid ulcers in which general symptoms have pointed to its use, but there is usually *intense photophobia, profuse lachrymation, great redness of the cornea and conjunctiva*, even chemosis, and *much pain of a throbbing, aching, shooting character*, which is *relieved by warmth*, so that one constantly wishes to keep the eye covered, and is worse on any draught of air (Sil.), at night or in the evening; the lids are often swollen, spasmodically closed and very *sensitive to touch*, or may be red, *swollen and bleed easily upon opening.*

It has been successfully employed in acute aggravations of pannus which tends toward ulceration, especially if occurring in mercurialized subjects.

In keratitis parenchymatosa it often serves to promote absorption after the disease has been checked by Merc., Aurum, Calc. or other remedies. It may, however, be of service in arresting the progress of the disease, as is well illustrated in the following case: Mary A—, 33 years of age. For three months the left cornea had been

so hazy that the iris could only be seen with difficulty, and for two months the right cornea had gradually become involved from the periphery toward the centre. Both cornea were wholly opaque and vision lost. There was considerable pain in the eyes and head, with iritis. The ciliary injection was great and the dread of light excessive; lachrymation marked. There was no history of syphilis, but she suffered severely from rheumatic pains, particularly in the shoulder. Various remedies, high and low, had been given for two months with no avail. Under Hepar³⁰ rapid improvement took place; in a month she was discharged with fair vision and only moderate haziness of the corneæ.

Kerato-iritis frequently requires the use of this remedy, especially if characterized by ulceration of the cornea, hypopyon, sensitiveness to air and touch and such other marked symptoms as illustrated in the following case: A man was attacked with severe inflammation of the cornea and iris of the left eye. Examination showed superficial ulceration of the cornea, much ciliary injection, contraction of the pupil, sluggishness of the iris and great photophobia and lachrymation. There was much pain extending from the eye into the corresponding side of the head, worse at night, especially about two or three A.M. and the seat of pain in the head, as well as in the eye, was quite sore to touch. The lids were considerably swollen and the discharge from the eye was slight. A cure was quickly effected under Hepar.

For *hastening the absorption of pus in the anterior chamber* (hypopyon) there is no better remedy than Hepar. On this account it has been employed with benefit in iritis with hypopyon, or associated with small abscesses in the iris (suppurative iritis). It has also appeared to exert a very beneficial influence in purulent capsulitis after cataract extraction, either used alone or in alternation with Rhus.

Inflammation of the ciliary body, in which the sensitiveness to touch is excessive, sometimes yields to this drug.

From its usefulness in suppurative inflammation in general, it has been administered with benefit in suppurative choroiditis or panophthalmitis.

An interesting case of anæsthesia of the retina of two months' duration, the result of looking at an eclipse, has been reported to

me by Dr. Chas. Deady. The patient complained of seeing a light spot in the centre of the field of vision, surrounded by a dark ring, and again by a lighter ring, all of which were constantly turning and changing into various colors, especially green; aggravated on coming into a room from the bright sunlight and only relieved during sleep. There was also a feeling as if the eyes were pulled back into the head with photophobia. V. $\frac{20}{100}$. Field of vision very much contracted. Under Hepar^{an} the sensation of the eyes being pulled back into the head was at once relieved, and in twelve days the vision became $\frac{20}{0}$ and the field of vision much enlarged.

Ulceration of external parts of the eye, which bleed easily and are very sensitive to touch, most positively indicate Hepar. These cases usually have excessive photophobia, which is also very marked in Merc. protiod.; while Kali bichrom., though indicated in extensive destruction of tissue and great sensitiveness of the eye to touch, lacks entirely the photophobia so marked under Hepar.

HYDROCOTYLE.

Clinical.—This remedy has seemed to be of benefit in some cases of tumors of the lid, especially in epithelioma. Linnell cured a case of lupus with this drug.

HYOSCYAMUS.

Eyes look red, wild, sparkling. Squinting. Pupils dilated.

Obscuration of vision; objects seem indistinct; he is near-sighted and is obliged to hold the book nearer than usual when reading. Dimness of vision, as if a veil were before the eyes. Deceptive vision; the flame of one light seemed smaller, that of another larger, though both were of equal size. Illusions of vision; small objects seem very large.

Clinical.—A case of hemeralopia in a myopic eye, with shooting pains from the eyes into the nose and head and accompanied by headache ameliorated on closing the eyes, was relieved by Hyos.—T. F. A. A one per cent. solution of the hydrobromide of hyoscyamine, according to Macbride, causes complete paralysis of the accommodation in from eighteen to thirty minutes; that its effects

pass off in from three to five days, and that it causes no disagreeable symptoms in children and young adults, but must be used with care in the old.

HYPERICUM.

Clinical.—The benefit which has been observed from this remedy in relieving the pain in old cicatrices led Dr. John L. Moffat to its use in a case of pain and irritation of the eye from an anterior synechia which resulted from an injury two or three years previous. The healthy eye was also irritable. *Hypericum*³ relieved.

IGNATIA.

Pain extending from the head into the left eye, when the eyes began to burn and water. Pressure within the eye as from sand. Sensation as if a particle were in the left external canthus. Pain in the inner surface of the upper lid as if it were too dry in the evening.

Unable to endure the glare of light. Zigzag and serpentine, white flickering at one side of the field of vision.

Clinical.—The following case of exophthalmus from Dr. A. Wanstall: Colored girl, *æt.* 17. Has always been very nervous and restless at night, walking and talking in her sleep. There has been "swelling of the eyes," lachrymation and pain in the eyes, with headache for six months, after having had a tooth drawn. A moderate amount of exophthalmus was present, together with palpitation of the heart; pulse 120 and congestive headaches, but no enlargement of the thyroid gland. Menses regular. Under *Ignatia*³ in one week the exophthalmus was scarcely perceptible and all the other symptoms were relieved.

Morbid nictitation, with spasmodic action of various muscles of the face, has been relieved by this drug.

Catarrhal conjunctivitis with a sensation as of sand in the eye and great dryness, may require this remedy, as in the following: A lady, artist of dark complexion and so excessively nervous that she started at the slightest noise, had been working late at night. She complained of one eyelid feeling as if sand were under it, with great dryness. Diagnosis, conjunctivitis palp. ac. *Ignatia*, 3d dec., one dose, removed the feeling in half an hour.—F. PARK LEWIS.

Dr. J. H. Buffum reports the following: Two "chipping ulcers" at upper margin of right cornea, accompanied by periorbital pains, sharp sticking, generally in one spot in supraciliary ridge, temple or side of head. The sleep was disturbed and digestion poor. Ignatia⁶ cured in four days.

Dr. W. P. Fowler reports¹ a case of "hyperæsthesia of the retina with hysteria," characterized by intense photophobia and ciliary neuralgia with general nervous symptoms, which was cured in ten days under Ignatia³ and proper hygienic measures.

A case of ciliary neuralgia in a woman was cured very promptly by this remedy; the pains were very severe, extending from the eye to the top of the head, producing nausea, and often alternated with swelling in the throat (globus hystericus); the pains would begin very slightly, increase gradually until they became very severe and would only cease when she became exhausted.

From a study of the clinical application of Ignatia it will be seen that its usefulness is confined almost exclusively to those ophthalmic affections which may be found in nervous, hysterical patients.

IPECACUANHA.

Inflammation of the eyes. On opening the right lids, which were swollen, there was a copious gush of tears. The conjunctiva of the bulb was injected and infiltrated. *The cornea was dim, as if infiltrated; on close examination there was noticed a number of small depressions.* Intense tearing or tensive pains in the eyes. *Great photophobia.* Profuse lachrymation. Conjunctiva injected, especially of the lid. Skin of lids red. Pupils contracted. Constant severe pain over the eyes, especially the left.

Clinical.—My attention was first directed to Ipecac. as a remedy for pustular inflammation of the cornea and conjunctiva by Dr. A. Wanstall, who was led to its use from an article of Jousset's recommending it as a remedy for pustular conjunctivitis. W. says: "In my hands it has been as near a specific as can be, and certainly I have never handled any one drug that will cure as many cases." It is no doubt a very valuable remedy for *phlyctenular ophthalmia*, as I have had occasion to verify in many cases. It is adapted to both

¹ Trans. Am. Hom. Oph. and Otol. Soc., 1879.

phlyctenules and ulcers of the cornea or conjunctiva, especially if there is *much photophobia* with redness and lachrymation. (Con. has intense photophobia, but with little or no redness of the conjunctiva or lachrymation.) The cornea may be vascular. The redness of the conjunctiva, lachrymation and pain are variable, though are usually well marked. Nausea occasionally accompanies the above symptoms. (Compare Conium, Hepar and Merc. protoiod).

JABORANDI.

Contraction of the pupil. Tension of the accommodative apparatus of the eye, with approximation of the nearest and farthest points of distinct vision. Everything at a distance appeared hazy, and although he could read moderate-sized type at one foot, at two feet it was indistinct. The state of vision is constantly changing, becoming suddenly more or less dim every few moments.

Clinical.—In 1878, after a study of the physiological action of Jaborandi upon the eye, I determined to test its value, according to the law of similia, in *spasm of the accommodation*. The results in many cases exceeded my most sanguine anticipations.

Selected from a large number of cases are the following, which will illustrate its sphere of action :

CASE I.—*Hyperopia et spasmus musc. cil.* James L., æt. 32, complained of everything becoming black before the eyes on stooping, aching of the eyes on reading and spots before the vision. V. $\frac{20}{30}$. With concave 42, V. $\frac{20}{20}$. Ophthalmoscope showed slight hyperopia. R. Jaborandi³. Three days later all the symptoms were relieved; V. $\frac{20}{20}$.

CASE II.—*Spasmus musc. cil.* Mr. M., æt. 32. V. $\frac{20}{30}$. Concave 42, V. $\frac{20}{20}$. For nine months had had spots before the vision and aching of the eyes upon using. In three days, under Jabor.³, vision had become $\frac{20}{20}$ and the muscæ volitantes had disappeared.

CASE III.—*Myopia cum spasmus musc. cil.* Mr. R., æt. 28. For seven years had been writing in a poor light all day. He thought his nearsightedness had appeared within one or two years. He complained of the myopia increasing and the eyes tiring on using them one and one-half hours. Fundus normal. V. $\frac{20}{70}$ o. u. Concave 40, V. $\frac{20}{20}$. Three weeks after using Jaborandi³, he reported that he had used his eyes more than usual and had experienced no trouble. V. $\frac{20}{60}$. Concave 50, V. $\frac{20}{20}$.

CASE IV.—*Hyperopia cum asthenopia*. Miss S., æt. 40. For many months had not been able to read more than five minutes without the eyes tiring. *Nausea was always produced on looking at objects moving*. Jaborandi³ relieved the nausea in twenty-four hours and in a week she could read three-quarters of an hour without inconvenience.

CASE V.—*Cataracta dura immat. et asthenopia*. Mrs. D., æt. 52. For four years the eyes had been weak, worse for four months; she could not use them even a few minutes without smarting and pain in them, with nausea. The pain and nausea were also experienced when looking steadily at a distance. There was much vertigo, as if the head were too light, especially on moving or looking at objects. Dull pain in the eyes was constantly present, with occasional sharp pain. Jaborandi³ relieved in three days all the nausea, vertigo and pain in the eyes.

The following symptoms observed in various anomalies of refraction have also been speedily relieved by this drug: Blur before the eyes at times, especially on looking in the distance. Eyes tire easily and are irritable, especially on moving them. Heat and burning in the eyes upon using. Headache upon using the eyes. Smarting and pain in the globes on use. Dim vision, twitching of the lids and pain in the eyeballs.

From the above it will be seen that Jaborandi is of the greatest importance in *spasm or irritability of the ciliary muscle*. In explanation of its usefulness in so-called asthenopia, I am inclined to believe that a large number of these cases are not dependent upon true weakness of the accommodation, but upon an *irritable weakness* and that Jaborandi relieves by virtue of its power to control irritation. This is also further demonstrated in its ability to relieve reflex symptoms, as in cases IV. and V., in which *nausea and vertigo due to reflex irritation from the eyes* were at once cured by this drug. Thus far these two reflex symptoms have been valuable and characteristic indications.

The following case by Dr. J. H. Buffum indicates that it may be of service in affections of the retina: "*Torpor retinæ*. John W., æt. 14. One year ago after constant and close application in doing fine work on cardboard he observed that retinal images were retained for several minutes. No other symptoms of discomfort or pain.

Vision soon began to diminish until for three months past he was unable to use the eyes at all for work. To-day, April 13th, R. V. $\frac{20}{30}$. L. V., fingers at eighteen feet. Convex, 42, R., V. $\frac{20}{30}$. Insufficiency of each internal rectus. Has sharp pains in the eye shooting back into the head, with general dull ache of the head. Light is painful. Ophthalmoscope gives negative results. R \bar{y} . Jaborandi^s every three hours. One week later he reports that pain has lessened very rapidly and the headache is very slight. V. $\frac{20}{30}$ o. u. R \bar{y} . same and Dyers exercise. After twenty-two days' treatment with Jaborandi, he returned home able to use the eyes for two hours at a time without glasses and without discomfort. He has continued well for nearly a year."

From examination into the general sphere of action of Jaborandi it should be suggested to our minds as a remedy for serous choroiditis and in one case it has improved the vision somewhat.

Its action upon the ciliary muscle seems to extend to a limited degree to the internal recti. It is, therefore, recommended for periodic convergent squint, for strabismus of recent date not dependent upon weakness of the opposing muscle in which for one reason or the other it is necessary to postpone the operation and for the tendency to recurrence of squint after an operation. Illustrative of the latter is the following: "*Strabismus convergens ex hyperopia*. Louis L., 9 years of age. Squint for seven years, especially in the left eye. R. V. $\frac{20}{30}$. L. V. $\frac{20}{30}$. Convex, 36, R. V. $\frac{20}{30}$. Nov. 22d, made tenotomy of both internal recti. Nov. 23d, there was crossed diplopia at the distance of one foot, but the eyes were apparently straight. Dec. 3d, slight but marked convergence again. Prescribed convex 40 for constant use. Dec. 27th, no improvement. R \bar{y} . Jaborandi^s. Jan. 11th, eyes perfectly straight. March 20th, no convergence and had not used glasses."

Jaborandi is very similar to Physostigma and Agaricus in its action upon the accommodation, though it has been of more service to me in spasmodic affections of the ciliary muscle than either of the two latter remedies. It is opposed to Duboisin in its action; the latter being indicated in *true* weakness of the accommodation, while Jaborandi is called for in *irritable* weakness.

KALI BICHROMICUM.

Objective.—Margins of the lids very red. Eyelids slightly granular. Dark rings about the eyes. Inflammation of the eyes, with yellow discharge and agglutination in the morning. Inflammation of the eyes. Redness of conjunctiva, with lachrymation. Conjunctiva both of bulb and lids injected. Appearance of small white pustules in the conjunctiva. Pustule on left cornea, with surrounding indolent inflammation. Lachrymation. Lachrymation, with burning pain in the eyes.

Subjective.—Itching and burning in both eyes, lachrymation and photophobia. Heat and pressure in the eyes. Burning in the eyes. Violent shooting pains from the root of the nose along the left orbital arch to the external angle of the eye exactly, with dimness of sight like a scale on the eye. Heavy pain above the eyes aggravated on motion and from cold. Much smarting of the eyes aggravated in the evening and in the open air. Especially useful in affections due to a rheumatic diathesis.

Clinical.—The local application of a saturated aqueous solution of bichromate of potash to large acute granulations of the lids has often caused their disappearance. It is, however, also serviceable as an internal remedy in trachoma and pannus, as shown in the following case: "A man, æt. 27, had granular lids, complete pannus of right eye, so he could barely count fingers, and partial pannus of the left eye; there was considerable discharge and everything appeared slightly red to him; eyes seemed to feel better when lying on his face. Under Kali bichr. the pannus entirely cleared, leaving a slight opacity behind, but could read No. 3 Snellen's test type easily with the right eye."—T. F. A.

Kali bichr. is of great value and especially indicated in mild cases of croupous conjunctivitis (a condition midway between purulent and genuine croupous inflammation), in which the false membrane is loosely adherent, easily detached and has a tendency to roll up and separate in shreds, which come away in the discharges, giving them a stringy appearance. The discharges are profuse and the conjunctiva very much inflamed; even chemosis. The lids are swollen and the cornea may be hazy.

It is of especial importance, however, in chronic indolent forms of inflammation of the eye, particularly of ulcers and pustules on the

conjunctiva or cornea, in which no active inflammatory process is present and therefore characterized by *no photophobia and no redness* or very little, not as much as might be expected from the nature of the disease; the pains and lachrymation are also usually absent. Corneal ulcers which have a tendency to bore in without spreading laterally indicate Kali bichr. The eye may be quite sensitive to touch and the secretions are of a *stringy character*.

Opacities of the cornea have been cleared under this remedy; sometimes used internally alone and again both externally and internally.

For *true descemetitis*, characterized by fine punctate opacities in the membrane of Descemet, especially over the pupil, with only moderate irritation of the eye, there is no remedy so frequently called for as Kali bichr. If a serous inflammation of the iris accompanies the changes in the membrane of Descemet, Gelsemium should be suggested to our minds.

KALI CARBONICUM.

Objective.—Inflammation of the lids of the right eye, with pain in the eyes and inability to read by the light. *Swelling between the eyebrows and lids like a sac.* Redness of the white of the eye, with many vessels in it. Lachrymation.

Subjective.—Pressure above the eyes. Sharp tearing in the right orbit and in the eye at night. Soreness of the external canthus with burning pain. Burning, biting and pressure in the eyes. The eyes are painful on reading. Stitches in the middle of the eye. Smarting pain in the eye. Weakness of vision. Photophobia.

Clinical.—Œdema of the lids, especially if accompanied by sticking pains and heart indications often subsides under the use of Kali carb.

It may be occasionally of service in small round ulcers of the cornea with no photophobia.

The verified symptoms indicate its usefulness in asthenopic troubles.

KALI IODATUM.

Swelling of eyelids. Injection of the conjunctiva. The conjunctiva of one or both eyes is often seen to be affected; the attack commences by a more or less general and more or less rapid vascular

injection, to which is speedily added a tumefaction of the mucous membrane, and an infiltration, generally well marked, of the sub-mucous cellular tissue, which gives rise to considerable chemosis of the eye and œdema of the eyelids.

Vision dim and foggy; she sees objects only indistinctly. Pain over the left side of the head and in the eye, aggravated on dark, stormy days.

Clinical.—The iodide of potassium is of the greatest importance in the treatment of many *syphilitic affections of the eye*. It serves to antidote the syphilitic poison, and there should be no hesitation in employing it in material doses.

Periostitis of the orbit will often require this remedy, especially if of syphilitic origin, though cases in which there has been no trace of syphilis have been benefited. There will be more or less swelling extending even to the temple, with œdema of the lids. The pain may be intense or absent entirely.

Tumors of the orbit have disappeared under the use of material doses of Kali iod., as in the following: "A colored woman, with a history of syphilis, had several tumors on the entire upper border of the left orbit, firmly adherent to bone and appearing to extend into the orbit. The growths were very hard and encroached considerably upon the upper lid, especially at the inner corner; were painless and presented no signs of inflammation or softening. Entirely disappeared under the iodide of potassium in material doses."—A.

WANSTALL.

It is sometimes useful in stricture of the lachrymal duct.

Its action in pustules of the conjunctiva and cornea is very similar to bichromate of potash, and it has been used with benefit in similar cases.

In *syphilitic iritis*, Kali iodatum is of great value. It is especially indicated if the inflammation is very severe and unyielding to the influences of atropine. The inflammatory process in the iris is so high that the pupil tends to contract, notwithstanding the frequent instillation of the strongest solutions of atropine. *The iris is much swollen and the aqueous more or less cloudy. The ciliary injection is very marked and of a bright angry appearance.* The pain may be severe, but is worse at night. The photophobia and lachrymation are variable.

Kali iodatum is a very prominent remedy in the treatment of acute or chronic irido-choroiditis and disseminate choroiditis, especially if of syphilitic origin. In one typical case of syphilitic choroiditis, recently under treatment, in which the chief symptom was an *excessive and variable amount of haziness of the vitreous*, the vision improved from R. V., counts fingers (held to outer side of the field) at two feet and L. V. $\frac{10}{200}$, to normal, under the daily use of fifteen grains of the iodide of potassium. Its special indications are not known, though its effects are often marvellous, even when the disease is non-syphilitic in origin, as the following case of disseminate choroiditis will illustrate: A young lady had for a long time complained of loss of vision and severe headaches. There was no history of syphilis. The fundus of the right eye showed extensive white patches (atrophy of the choroid) and deposits of pigment over its whole extent, optic nerve hyperæmic and slight haziness of the vitreous. Commencing atrophic spots in the choroid of the left eye and hyperæmia of the nerve could be detected by the ophthalmoscope. R. V. $\frac{20}{200}$. L. V. $\frac{20}{20}$. She was directed not to use the eyes more than was necessary, and Bell. was given for three or four weeks with no marked improvement, with the exception that the headaches were not quite as frequent. Kali iod. was now prescribed and the eyes rapidly began to grow stronger, the hyperæmia of the fundus disappeared and the headaches ceased entirely. Six months after using Kali iod., R. V. $\frac{30}{30}$. L. V. $\frac{20}{20}$, though the atrophic spots in the choroid, of course, underwent no change.

In paralysis of any of the muscles dependent upon syphilitic periostitis the iodide of potassium is the remedy most frequently called for. The following case of paralysis of the left nervus abducens will show its action: A man, 40 years of age, ten days previous to his appearance for treatment awoke in the morning with dizziness, and afterward had three similar attacks. Had had a severe cold. For two days had noticed a blurring of vision and diplopia which had been steadily increasing and was only noticed on looking to the left. Examination showed only slight action of the left external rectus. R_y. Caust.³⁰. Two days later the paralysis of the muscle had become complete. It was found that he had had syphilis. R_y. Kali iod., eight grains a day. In two days decided improvement was observed, and in two weeks the muscle had regained its normal power.

KALI MURIATICUM.

Discharge of white mucus from the eyes, or yellow-greenish matter. Superficial flat ulcer of the eye arising from a vesicle. Blisters on the cornea. Feeling of sand in the eye. Onyx and hypopyon.

Clinical.—The recommendation by Schüssler of Kali mur. for the stage of exudation in inflammations suggested its employment in parenchymatous keratitis, especially since we know that the Kalies are adapted to indolent forms of inflammation, which this form of keratitis usually assumes. The following case will give its sphere of action in *parenchymatous keratitis*: Mr. L., æt. 35. For three months there had been an infiltration into the right cornea, which commenced at the outer side and extended over the whole cornea. He could only count fingers. There was occasional pain, moderate photophobia and redness. The pupil dilated slowly and incompletely, though regularly under atropine and contracted quickly. Aurum. mur., Cinnabar and other remedies, with atropine externally, had been used with no benefit, except some relief of pain. Under Kali mur., 6th dec., the inflammation was soon arrested and the cornea gradually cleared. In three months R. V. $\frac{2}{3}$. The improvement has continued.

In asthenic ulcers of the cornea with but little redness, photophobia, lachrymation or pain. The ulcer generally begins at the periphery and extends toward the centre, its base is a dirty white or yellow, often very vascular and with considerable infiltration of cornea around the ulcer and with a moderate amount of mucous discharge. In some cases the infiltration becomes more purulent in character and extends between the layers of the cornea (onyx) or into the anterior chamber (hypopyon), but even then the inflammation retains its asthenic type.

The benefit which has been derived from the muriate of potassium in a case of chorio-retinitis indicates that it may be a valuable remedy in intra-ocular troubles. "Chorio-retinitis: Mr. D., æt. 36. Noticed two years ago such dimness of the right eye that he could not read a newspaper. Had observed no previous trouble. After a month's treatment he could read again, but, suffering a relapse, the same treatment for a year proved ineffectual and the case was deemed hopeless. No history of syphilis. Examination showed

cornea, iris and pupil normal. No external redness. By ophthalmoscope, vitreous rather hazy, with some black shreds suspended in it, having very limited motion on rotating the eye. This would indicate that the vitreous was not fluid. Optic nerve and blood vessels normal. Inside the disc, a large, irregular, atrophic spot, involving the choroid and retina, surrounded by several small ones; edges irregular and pigmented; the sclerotic seen white through their centres; adjacent choroid congested and thickened; some vessels lost in the infiltrated part to appear on the other side; a dull pain, occasionally, in the eye and over the brow, with an ill-defined feeling of contraction around the eye. V. $\frac{20}{200}$. Snellen 11, slowly deciphered. Prescribed Kali mur., 6th dec., four times daily. At the end of a month vision rose to $\frac{20}{30}$ and Snellen 3 was read at five inches. A year afterward the man could read Snellen at $2\frac{1}{2}$, distant vision $\frac{20}{70}$, but under Kali mur. for a week it was again $\frac{20}{30}$. The patient's business engagements prevented longer treatment.—
W. H. WOODYATT.

KALMIA LATIFOLIA.

Sensation of stiffness in the muscles around the eyes and of the eyelids. Pain in the eyes, which makes it painful to turn them. Glimmering before the eyes. Ptosis with supra-orbital neuralgia.

Clinical.—From its action upon the muscles we are led to give it in asthenopia and with good results, especially if there is present a *stiff drawing sensation in the muscles* upon moving the eyes.

Sclero-choroiditis ant., in which the sclera was inflamed, vitreous perfectly filled with exudation and glimmering of light before the eye, especially on reading with the other, was cured by this drug.—
T. F. A.

Kalmia was prescribed in a case of retinitis albuminurica occurring during pregnancy, on account of the characteristic pains in the back; it was continued for a long time, during which the white patches gradually became absorbed and recovery took place.—
T. F. A.

Dr. Hunt reports several cases of rheumatic iritis with sharp pain, boring in the eye, ciliary injection and tenderness of the eye, in rheumatic subjects, promptly relieved by this drug.

Dr. Boyle cured a case of tenonitis with *Kalmia* in which the lids were red and swollen, chemosis and pain on movement and pressure of the eye. Also several cases of scleritis with syphilitic history after Kali iod. had failed.

KREOSOTUM.

Burning and redness of the conjunctiva. Smarting in the eyes. The tears are acrid like salt water.

Clinical.—Kreasote has been of service in acute aggravations of chronic keratitis, in which there was excessive, hot, smarting lachrymation; also in blenorrhœa of the conjunctiva, with moderately profuse discharge and much smarting in the eyes.—T. F. A.

LACHESIS.

Subjective.—The eyes feel stiff. Aching of the eyes, especially of the left. A sticking, drawing pain in the right eye extending up to the vertex. Pressure in the eyes. Stitches as from knives in the eyes, coming from the head. Pains near the eyes.

Vision.—*Dimness of vision; much black flickering before the eyes,* that seems very near; it frequently makes reading difficult. A fog before the eyes; in the evening a bluish-gray ring, about six inches in diameter, around the light. Eyes sensitive to light. *Flickering before the eyes.* Flickering and jerking in the right eye, with violent congestion to the head. Flickering before the eyes, as from threads, or rays of the sun. Flickering in peculiar angular zigzag figures, with congestion to the head and headache. A beautiful bright blue ring about the light that was beautifully filled with fiery rays.

Clinical.—A case of orbital cellulitis, following an operation for strabismus, was effectually and rapidly cured under this remedy. The symptoms were a marked protrusion of the eye and chemosis, with a purulent discharge and sloughing at the point of tenotomy, with a black spot in the centre of the slough; the retina was hazy and congested.—T. F. A.

Lachesis is sometimes useful in phlyctenular keratitis, especially the chronic recurrent form, in which the surface of the cornea may be ulcerated, with moderate redness of the eye. The chief characteristic, however, has been the marked *photophobia, which is always*

worse in the morning and after sleeping. The various pains in the eyes and head are also subject to the same aggravation.

As already referred to in the article upon *Crotalus*, *intra-ocular hæmorrhages* will often call for *Lachesis*. Many cases might be given to illustrate its usefulness in this respect, but little would be gained by so doing, for the eye indications, with the exception of the hæmorrhages, have usually been unimportant or absent altogether. It may be said, however, that hæmorrhages into the anterior chamber, into the vitreous, into the retina and into the choroid, whether of spontaneous origin or dependent upon various diseased conditions, have all been seen to speedily disappear under the use of this remedy. The general indications are of more value in the selection of this drug than those relating only to the eye. The brilliant results often observed from its employment in *retinitis apoplectica* do not seem to be confined to the absorption of the hæmorrhages as it also appears to control the inflammatory symptoms and diminish the tendency to retinal extravasations.

Its value in relieving asthenopic symptoms is suggested by the following case: Mr. M., æt. 24, had complained of his eyes a year or more. Had been using convex 48, which neutralized his hyperopia and were correct. He was very nervous and had a variety of pains and sensations in and around the eyes, especially the left, all of which were worse upon thinking of his eyes, upon using them and upon waking in the morning. These pains were experienced even when using his glasses. There was no weakness of the internal recti. After the failure of several remedies, *Lachesis*³⁰ was given, with permanent relief in four weeks.

LACTIC ACID.

Clinical.—Hyperæsthesia of the retina, with steady aching pain in and behind the eyeball was quickly relieved by a few doses of Lactic acid.—T. F. A.

LEDUM PALUSTRE.

A pressure (or dull pain) behind the eyeball as if it would be forced out.

Clinical.—*Ledum* has proved chiefly beneficial in contusions or wounds of the eye and lids, especially if accompanied by extravasations of blood.

In a case of complete ptosis (right eye) from an injury by a piece of wood striking the eye, in which there was *ecchymosis of the lids and conjunctiva*, a complete restoration of power to the upper lid took place in five days under *Ledum* externally and internally, after *Arnica* had been used for two days with no benefit.

Ecchymoses of the conjunctiva, either of traumatic or spontaneous origin, are often quickly absorbed by the use of this remedy, and in many cases more promptly than when our usual remedies, *Arnica* or *Hamamelis*, are employed. (It should be used in the same manner as *Arnica*.)

A case of *hæmorrhage into the anterior chamber*, after an iridectomy, which had resisted both *Hamamelis* and *Arnica* for two weeks, was absorbed in four days under this drug, used externally and internally.

It is the remedy in asthenopia, if there is dull pain behind the eyeball, as if it would be forced out.

LILIUM TIGRINUM.

Lachrymation. Burning feeling in the eyes after reading or writing; eyes feel very weak. Blurred sight with heat in the eyelids and eyes.

Clinical.—Favorable results have been obtained from *Lilium* in the relief of so-called asthenopic symptoms, which were in all probability dependent upon spasm of the accommodation, as follows: "Mr. B., æt. 45, teacher. Has been wearing convex 36 for his old sight, selected at an optician's; latterly had been using the microscope a good deal and has been annoyed some by fatigue of the eyes. Test: V. $\frac{2}{3}^0$, Am. concave 24°, axis horizontal, V. $\frac{2}{3}^0$, A. 9'' to 24½''. Prescribed *Lilium tigr.*⁵⁰ four times a day. In seven days V. $\frac{2}{2}^0$ clearly. A week later, A. 7'' to 29''. One week later, A. 5½'' to 31''. Examined a month later after the medicine had been stopped and found the condition unchanged. Had abandoned his glasses entirely."—W. H. WOODYATT.

LITHIUM CARBONICUM.

Eyes pained during and after reading, as if dry. Uncertainty of vision and an *entire vanishing of the right half of whatever she looked at*; or if two short words occurred in succession, that on the right hand was invisible.

Clinical.—A brilliant cure of hemiopia with Lithium³⁰ is reported by Dr. Dunham, in which only the left half of an object was visible with the right eye and nothing at all with the left. In two or three other cases of hemiopia, in which only the left half of objects was visible, no benefit was derived from this remedy.

It may be of service in some cases of asthenopia.

LYCOPodium.

Objective.—Swelling and painfulness of the lids, with nightly agglutination of the canthi. Styes on the lids toward the inner canthus. *Ulceration and redness of the eyelids*; the water which flows from the eye smarts and bites the cheek. Inflammation of the eyes, with itching in both canthi, redness and swelling of the lids of the right eye; distressing pain, as if they were dry, with nightly agglutination.

Subjective.—Eyelids dry, with smarting pain; they cannot be opened, even on rubbing, in the morning. Smarting and burning of the lids. Dryness of the eyes in the evening and at night. Dryness beneath the lids, as from dust, in the morning on waking. Eyes dry and dim. Eyes dry, difficult to open, with smarting pain, in the morning. Severe burning and itching in the eyes. Pressive pain in the eyes, as if dust were in them. Stitches in the eyes. Itching in the canthi.

Vision.—Vision weak, is unable to distinguish small objects as well as formerly. *The evening light blinds him very much; he cannot see anything upon the table.* A veil and flickering before the eyes after the afternoon naps. Hemiopia: he sees only the left half of an object; same with one eye as with both, but worse with the right. Sensitiveness of the eye to daylight. Floating black spots before the eyes at a short distance.

Clinical.—External diseases of the eye are not commonly amenable to this drug, as its chief remedial power has been exhibited in the disorders of nutrition and function of the deep seated structures.

Ciliary blepharitis and hordeola occasionally call for the use of Lycopodium.

The progress of cataract has been arrested by this remedy when prescribed for chronic dyspeptic symptoms.—T. F. A.

Opacities of the vitreous have occasionally been known to disappear during the administration of Lyco.

Hemiopia, in which the right half of the field of vision was obscured, has been improved.

In *Hemeralopia* its great value as an eye remedy becomes apparent, for no other drug in our *Materia Medica* has cured such a large number of cases as *Lyc.* There seems to be no marked indication for its use, with the exception of the night blindness coming on in the early evening, though in some instances it was found that the patient could see better at a distance than near at hand, yet in other cases this indication was wanting, so it cannot be considered important. If black spots floating before the eyes accompany the night blindness this drug is particularly called for.

LYCOPUS VIRGINICUS.

Clinical.—This remedy is noticed here on account of its reputed power in the treatment of exophthalmic goitre (*morb. Basedowii*). In my hands, however, it has failed to benefit in every case in which it has been given.

MERCURIALIS PERENNIS.

Objective.—Blinking of the eyes in the open air and sunlight. Twitching of the upper lids, especially of the left eye. Watery eyes. Pupils dilated.

Subjective.—On waking at night she was unable to open the lids immediately; they seemed paralyzed and could not be opened until she had rubbed them. Weakness of the upper lids, so that at times she could not completely raise them. *Lids heavy and dry. Dryness of the eyes. Burning in the eyes. Pain in the eyes while reading and writing.* Bruised, sore feeling of the eyes, with sensation as if they were too large for their sockets or as if they would be pushed out.

Vision foggy. Weakness and sensitiveness of the eyes to bright and artificial light. Blinking of the eyes while sewing or reading by the light. *Letters run together while reading.*

Clinical.—Hyperæmia of the conjunctiva after using the eyes with heaviness of the lids will often find its remedy in *Mercurialis*.

In a case of conjunctivitis trachomatosa with pannus, *Mercl.*²⁰ seemed to act very promptly in relieving all the symptoms. The pannus was slight and the boy complained of feeling very sleepy. There was lachrymation and blurring of the vision in the morning.

Our attention should be more frequently directed toward this drug in the treatment of asthenopia. It is especially indicated if the patient complains of a sensation of dryness in the eyes and heaviness of the lids. (Compare with Alumina.) The sensation as of a mist before the eyes in the morning, and a burning pain in the left eye, worse in the evening and after using, occurring in cases of asthenopia, have also been relieved. Also the hyperæmia of the conjunctiva, already noted, should suggest this remedy in these cases.

MERCURIUS CORROSIVUS.

Redness of both ocular and palpebral conjunctiva. *Inflammation of the eyes.* Pupils insensible to light.

Eyes painful. Burning in the eyes. Tearing as if in the bone above the left eye, near the root of the nose, and in other parts of the bone. Pain behind the eyeballs as if they would be forced out. Photophobia.

Clinical.—The corrosive sublimate is more often indicated in severe inflammatory conditions of the eye, especially superficial, than any other form of mercury.

In certain forms of blepharitis it is frequently very valuable, as in inflammatory swelling of indurated lids; inflammatory swelling of the cheeks and parts around the orbits, which are covered with pustules, or in scrofulous inflammation of the lids, which are red as in erysipelas. In these cases the lids are usually *very red and excoriated by the acrid lachrymation, and the pains are very severe, particularly at night.*

Chronic catarrhal conjunctivitis, tending toward trachoma, with redness and excoriation of the lids, and a dull feeling, with itching in the eyes in the evening, has been cured under this remedy.

Merc. corr. is usually more useful in strumous ophthalmia than Merc. sol. It is chiefly called for if phlyctenules, ulcers, or even deep abscesses are formed in the cornea, for then the severity of the symptoms would lead us to its selection, as this remedy is especially indicated in the erethistic form of inflammation. The eye is usually very red and the cornea vascular and ulcerated. The cornea may have become so weakened from the inflammation as not to be able to resist the normal intraocular pressure and so commencing staphyloma may be noticed. *The photophobia is excessive and the lachry-*

mation profuse, which, together with the *ichorous discharges* are *acrid, excoriating the lids and cheek*. The pains vary in character, though are generally very severe and not confined to the eye, but extend into the forehead and temples; always worse at night. The lids are much swollen, erysipelatous, œdematous or indurated; are red and excoriated from the acrid discharges and are spasmodically closed, rendering it almost impossible to open them and they often bleed easily upon attempting to do so. There are also usually present pustules on the cheek around the eye, soreness and excoriation of the nose, enlargement of the cervical glands, coated tongue, etc.

It has been employed with benefit in ophthalmia neonatorum in which the discharges were thin and excoriating, especially if the mother has gonorrhœa or syphilitic leucorrhœa.

Episcleritis, with *much pain in and around the eye at night*, requires Merc. corr.

For kerato-iritis it is one of our chief remedies.

In *iritis*, especially the syphilitic variety, it no doubt surpasses any other remedy in frequency of indication, and by some it is even considered a specific, providing atropine is used at the same time locally. The severity of the symptoms and the intensity of the pains at night over the eyes and through them, through the head and in the temples, are our chief indications. *It is no less useful in the other forms of plastic iritis*, as every-day experience fully verifies.

It seems to act beneficially in some cases of posterior synechia, causing them to soften so that atropine can tear them, and it sometimes appears to absorb them entirely, if recent.

Hypopyon occurring in the course of abscess of the cornea or iritis has been frequently absorbed under its use.

If the inflammatory process has extended to other portions of the uveal tract (cyclitis, choroiditis, irido-cyclitis or irido-choroiditis) this remedy still deserves special prominence.

In retinitis albuminurica, no remedy has been employed with better success in such a large number of cases; the inflammatory process is often seen to rapidly subside, and the exudations into the retina disappear under the influence of this remedy. The prescription is chiefly based upon the pathological changes, as the symptoms are so few in this disease.

In retinitis hæmorrhagica or apoplexia retinae, Merc. corr. is of great value in hastening the absorption of extravasated blood and in toning up the walls of the vessels so as to successfully resist further blood pressure. A case now under treatment in which there was no marked inflammation, but profuse hæmorrhages throughout both retinae, improved rapidly under Merc. corr.² after other remedies had been given three months with no benefit. Within two months V. had improved from $\frac{1}{100}$ to $\frac{1}{30}$, most of the hæmorrhages had absorbed and no new hæmorrhages were occurring.

In superficial inflammations of the eye, Mercurius closely resembles several remedies, as Graph., Euphras., Arsen. and Sulph., but the severity of the symptoms and nightly aggravations are much more marked under Merc. than either of the above. Under Graphites the discharges are also acrid and excoriating and the photophobia often intense, but the pains are not usually so severe as under Merc. Besides we usually find the external canthi cracked and a moist eruption on the face and behind the ears when Graph. is indicated. The acrid discharges of Euphrasia are generally thick, while those of Mercurius are thin. The character of the pains and general cachexia will serve to distinguish it from Arsen. and Sulph.

MERCURIUS DULCIS.

Clinical.—Ciliary blepharitis associated with phlyctenular ophthalmia and accompanied by eruption on the face, soreness of the nose and swelling of the upper lip, is often amenable to Merc. dulc.

Calomel has been employed for many years by the old school in scrofulous ophthalmia, and even to this day it is considered by them as one of their most important remedies, though not a specific as was formerly supposed. Dusting the fine powder in the eye is the manner in which it is used by them.

We also, as homœopaths, find it adapted to certain forms of *strumous ophthalmia*, though given in a different manner, in different doses and upon different principles. We use it only internally and for the general cachexia, as the following case will illustrate: A little girl, æt. 6, light complexion, pale skin, muscles soft and flabby, glands enlarged and general strumous diathesis. Upon examination a very deep ulcer of the left cornea was seen which had so nearly perforated that the membrane of Descemet had begun to bulge; small

ulcers and pustules were present at the border of the cornea. In the right eye pustules and maculæ of the cornea were also found. There was *considerable redness and great photophobia*. Various remedies, chiefly the anti-psorics, had been given with no benefit; Merc. dulc.², three doses daily, was administered; improvement soon began and went rapidly on to recovery, leaving only a macula behind.

Benefit has also been derived from the use of Merc. dulc. in deeper forms of inflammation of the eye, as in irido-choroiditis, especially if dependent upon a serofulous diathesis, and the general cachexia of the patient suggests the remedy.

MERCURIUS IODATUS FLAVUS.

Clinical.—Dacryocystitis blenn. may call for this remedy, though it is not often indicated.

In some cases of blepharitis of syphilitic origin favorable results have been obtained from Merc. prot., if the concomitant symptoms point to its use.

It has been of service in uncomplicated granular lids, but is more particularly adapted to trachoma with pannus. It may be indicated in all stages of pannus, but especially in acute aggravations after the first, or Aconite stage has passed. In these cases it often exerts a marked beneficial influence upon the trachoma itself. (Special indications have been given after ulceration of the cornea, page 163.)

Merc. iod. flav. has been useful in pustular inflammation of the cornea and conjunctiva, but its principal sphere of action is in *ulceration of the cornea*, especially in that form of ulceration which commences at the margin of the cornea and *extends, involving only the superficial layers, either over the whole cornea or a portion of it, particularly the upper part*, which appears as if chipped out with the finger nail, the so-called serpiginous form. Also in cases of *ulceration occurring in the course of pannus and granular conjunctivitis* it is excelled by no other remedy in frequency of indication.

In all these cases there is usually present excessive photophobia and redness, though sometimes these may be nearly absent. The pains are generally of a throbbing, aching character, *worse at night*; the pain often extends up into the head, which is sore to touch. In nearly every case we have the *thick yellow coating at the base of the tongue* and swelling of the glands in various parts of the body, which are so prominent under this drug.

Dr. A. Wanstall describes¹ a peculiar sclero-corneal formation in a colored boy in which the entire sclero-corneal margin was occupied by a slightly elevated opacity of little width and upon which was situated a chain of very minute vesicles. The pericorneal subconjunctival tissue was profusely injected with very fine vessels, through which was also distributed a large quantity of pigment, forming a zone as striking in appearance as the one occupying the limbus corneæ, into which it imperceptibly merged. The opacity of the cornea was sharply defined. Under Merc. prot.³ the pericorneal injection rapidly disappeared and the proliferation of tissue passed over into a macula.

Benefit has been derived from this preparation of Mercury in syphilitic iritis, although it is not as frequently required as Merc. corr.

In intraocular troubles Dr. Woodyatt has observed very favorable results from the use of the iodide of mercury, as in opacities of the vitreous and in irido-choroiditis, as the following will illustrate: "Miss L., aged 26. Eight years ago she noticed a drooping and heaviness of eyelids. After two years she found sight of left eye imperfect, and when this dimness appeared the drooping of both eyelids ceased. No redness, pain nor photophobia; but black spots and flashes of light were sometimes seen. A year later the right eye was affected and rapidly grew worse than the left. Two years ago the sight failed entirely. Examination of right eye: No external redness; anterior chamber shallow; iris discolored and crowded forward by a swollen, opaque lens, to the capsule of which it was attached all around the margin of a contracted pupil. Not even quantitative sight existed. Left eye: Anterior chamber shallow; iris dimmed and discolored; pupil moderately dilated and mobile. Ophthalmoscope revealed pigment spots on the lens capsule; vitreous hazy throughout; lying in it, near the retina, were three greenish-blue spots a little larger than the optic nerve, probably hæmorrhagic effusions undergoing degeneration. V. = $\frac{20}{50}$, Snellen $1\frac{1}{2}$ read slowly at 3 inches; irregular dilatation of pupil under atropine. Patient in fair health and only complains of black spots in the visual axis, inability to bear strong light and to use her eyes continuously. Pre-

¹ Trans. of Am. Hom. Ophthal. and Otol. Soc. for 1880.

scribed Mercurius iod., 3d dec., four times a day; to use protective glasses and to abstain from near work.

"Twenty days later V = $\frac{20}{30}$, Snellen 1½ read at 8 inches. During the menses, two days after this record, there was hæmorrhage into the vitreous. For one day sight was only quantitative, but it rapidly cleared. For ten days V. = $\frac{20}{20}$, emmetropic. Résumé: Duration of treatment, 60 days; left eye, from V. = $\frac{20}{30}$ to $\frac{20}{20}$."

Cases of paralysis of the oculo-motor nerve of syphilitic origin have been cured by this preparation of mercury as is markedly shown in the following case: A young man appeared for treatment with complete paralysis of all the fibres of the third pair of nerves of the right eye. It was probably of syphilitic origin, as fifteen months previously he had had a chancre which was followed by pain in the bones, worse at night, sore throat, etc. Kali iod., in material doses for three weeks and Rhus tox.¹ for one week, together with electricity all the time, failed to improve. After three days' use of Merc. iod. flav.³⁰ and electricity, the power began to return to the muscles so that he could raise the upper lid somewhat and in less than a month he was fully restored.

MERCURIUS IODATUS RUBER.

Clinical.—The action of this form of mercury is very similar to that of the yellow iodide and by some is used instead of the latter.

Its usefulness has been especially verified in trachoma and pannus, though the points of difference between the two iodides in this affection are not known.

MERCURIUS NITROSUS.

Clinical.—The nitrate of mercury has been successfully employed, both externally and internally, in various forms of blepharitis with no particular indications.

As a caustic in syphilitic ulceration of the lids, there is none better.

This preparation of mercury is more often indicated than any other in *pustules and ulcers of the cornea*, particularly the former. It has been especially used by Dr. Liebold with remarkable success in a large number of cases, without regard to symptoms. Severe cases as well as mild, chronic cases as well as acute, and superficial

tomatology, but are guided in its selection simply by clinical indications.

In scrofulous ophthalmia it has proved beneficial. There is commonly bright red swelling of the conjunctiva; the lids may be everted and granular; the cornea is superficially ulcerated and covered with vessels; the discharges from the eye are copious and purulent, forming crusts upon the lids which are firmly agglutinated in the morning; the photophobia is usually great; the symptoms are aggravated by working over a fire.

Benefit has been derived from its use in ophthalmia neonatorum.

In trachoma with pannus it is a valuable remedy. It is rarely of much service in the acute stage, for it is especially adapted to old chronic cases, in which the cornea is covered with pannus of high degree, with considerable redness, discharge and photophobia; granulations may be present, or may have been already removed by caustics.

MERCURIUS SOLUBIS.

Objective.—*The upper lid is thick and red, like a sty.* Great swelling, redness and constriction of the lids, which were very sensitive to touch. Eyelids agglutinated in the morning. He is unable to open the eyes well, as if the eyeballs were agglutinated (to the lids). Inflamed swelling in the region of the lachrymal bone. Inflammation of both eyes, with burning pain, worse in the open air. The eyes were forcibly drawn together, as if long deprived of sleep. Lachrymation.

Subjective.—A sensation as of a cutting substance beneath the left upper lid. Heat, redness and pressure in eyes. Heat in the eyes, and lachrymation. Burning in the eyes. Burning and biting in the eyes, as from horse-radish.

Vision.—If she attempts to look at anything she cannot distinctly recognize it, and then the eyes are almost always involuntarily drawn together; the more she tries to restrain the contraction the less able is she to prevent it; she is obliged to lie down and close the eyes. A fog before one or both eyes. Dimness of vision. The eyes cannot tolerate the firelight or daylight. *Firelight blinds the eyes very much in the evening.* Things like black insects or flies constantly float before the vision.

Clinical.—Mercurius solubis has for many years been one of the most prominent remedies in ophthalmic practice, and even now it may be considered one of the polychrests.

Inflammation or blenorrhœa of the lachrymal sac should suggest this remedy, if there is considerable swelling and pain at night, or if the discharge is thin and acrid in nature, providing the general condition of the patient at the same time calls for it. For fistula lachrymalis, with external ulceration resulting from syphilis, it has also proved useful.

In blepharitis there is no better remedy if the lids are *red, thick and swollen* (particularly the upper) *and sensitive to heat, cold or touch*. The lachrymation is *profuse, burning and acrid*, making the lids sore, red and painful, especially worse in the open air or by the constant application of cold water. *The symptoms are all worse at night in bed and by warmth in general, also from the glare of a fire*, which is unusually painful. It is especially indicated in ciliary blepharitis caused by working over fires or forges, or by gaslight.

Ophthalmia neonatorum, marked by acrid discharge (usually thin) which makes the cheek sore and particularly if caused from syphilitic leucorrhœa in the mother, is more quickly relieved by this drug than any other.

In superficial inflammations of the cornea and conjunctiva, either ulcerative, phlyctenular or catarrhal, Mercurius has proved especially serviceable. We are led to its use by the following symptoms, which have been collected from a large number of cases: In inflammatory conditions dependent upon syphilis, either hereditary or acquired, it is one of the first remedies to be thought of. The ulcers of the cornea are usually quite vascular, though they may be surrounded by a grayish opacity and complicated with existence of pus between the layers of the cornea (onyx). The redness of the conjunctiva is variable, though more frequently of high degree; in some cases chemosis. *The dread of light is generally very marked*, in some cases so intense that the eyes can hardly be opened, even in a darkened room, and is more often *aggravated by any artificial light, as gaslight or glare of a fire*. The lachrymation is *profuse, burning and excoriating* and the muco-purulent discharges are very *thin and acrid*. The pains are generally severe and varying in character, but are more frequently tearing, burning, shooting or sticking, and are

not confined to the eye, but extend up into the forehead and temples; are *always worse at night*, especially before midnight, from heat, damp weather or extreme cold, and are often ameliorated temporarily by cold water. The lids may be spasmodically closed, are thick, red, swollen, even erysipelatously, *excoriated by the acrid discharges and are sensitive to heat, cold or contact*; there is usually biting and burning in the lids, sometimes a feeling as if there were many fiery points in them; worse in the open air. The general aggravations in the evening by gaslight and at night after going to bed are of the first importance. At the same time the concomitant symptoms of soreness of the head, excoriation of the nose, eruptions on the face, condition of the tongue, offensive breath, night sweats without relief and pain in the bones, especially at night, would lead us in its selection.

Keratitis parenchymatosa dependent upon hereditary syphilis very frequently calls for Mercurius, which has proved extremely valuable in this affection. It may also be of service in interstitial inflammation of the cornea, if traceable to acquired syphilis, as was verified in a case recently under treatment.

Kerato-iritis, both with and without hypopyon, has been cured with Merc.; it is indicated by the pains and nightly aggravation. In one case in which benefit was derived the pain was very severe at night, the eye feeling as if it were a ball of fire, the lachrymation was hot and hypopyon was present.—T. F. A.

In the treatment of episcleritis it should be considered with Thuja, as the following case will illustrate: A woman, *æt.* 35, had been troubled for a long time with inflammation of the eyes; the corneæ were covered with scars from old ulcerations; the scleral vessels were injected, especially between the insertion of the recti muscles, where the sclera was slightly bulged and thinned, so that the dark color of the choroid showed through; she complained of a steady aching pain in the eye all the time, worse at night. Merc.²⁹ was given, which relieved the pain within a few hours and a rapid recovery ensued. In another case similar to the above in its pathological changes the pains were pricking in character, especially on turning the eye outward, with a "dizzy" pain and beating over the eye and in the temple at night. Merc.³⁰, with Atropine, cured in four days.

Mercury has always been and probably always will be the principal remedy for *iritis*. The solubis has been employed with great success in many cases, though it is not as commonly useful as the corrosivus. It is especially called for in the *syphilitic* variety and when gummata are present in the iris, though its sphere of usefulness is not confined to this form, as it may be indicated in the rheumatic or any other form of *iritis*, in mild cases as well as severe, when hypopyon is present and when it is absent. The usual symptoms of *iritis*, contraction, discoloration and immobility of the iris, ciliary injection, haziness of the aqueous, etc., are of course found, but the characteristic indications are to be looked for in the pains, which are usually of a *tearing, boring character, chiefly around the eye, in the forehead and temples, which are often sore to touch*; with this there may be throbbing, shooting and sticking pains in the eye; all of which are always *worse at night*.

In retinitis or in choroiditis, particularly if dependent upon syphilis, this remedy has been employed with benefit. In these cases the retina is often very sensitive to the glare of a fire. It is the great remedy for *diseases of the optic nerve and retina occurring in workers in foundries*.

In a case of ciliary neuralgia, in which the pain was very severe in character, shooting from the eye to the occiput, worse at night, with vertigo and soreness of the head and arm to touch, prompt relief was obtained by Merc. sol.³⁰ after Sulph. had failed.

MEZEREUM.

Obstinate jerking of the muscle of the left upper lid. Lachrymation, with biting in the eyes. Eyes hot, inflamed, on rising in the morning; the conjunctiva of the ball very much injected, dirty red, especially in the vicinity of the external canthus; most in the left eye; with pressive pain and a sensation of dryness. Much pressure in the eyes, with a sensation of dryness, as if the conjunctiva of the lids were very much inflamed. Smarting in the eyes, compelling to rub them. Pressive pain above the left eye. Itching, biting on the margin of the lids and skin near the nose.

Clinical.—In eczematous affections of the lids, face and head, characterized by *thick, hard scabs from under which pus exudes on pressure*, Mezereum is especially useful. It has been given with

benefit in blepharitis, pustular conjunctivitis and abscess of the cornea, chiefly when these symptoms have been present.

Ciliary neuralgia, especially after operations upon the eye, has been relieved by this drug.

MURIATICUM ACIDUM.

Clinical.—The following symptom, found in a case of muscular asthenopia, was speedily relieved by Muriatic acid: Sharp burning pain extending from the left to the right eye in the morning, ameliorated by washing. Vertigo worse on moving the eyes.

NAPHTHALIN.

In the *Berliner Klinische Wochenschrift*, No. 44, 1887, there is reported the changes occurring in the eyes of animals who were fed naphthalin. When the drug was given in large doses, from thirty to forty grains, the results came on rapidly, with sometimes detachment of the retina; in smaller doses the process was much slower. The fundus was filled with numerous small brilliant points, which seemed to be formed as a large, white plaque, usually below the optic disc, and which in extending covered over the choroidal vessels. The same brilliant spots were seen in the optic papilla. The most important changes were seen in the lens, which showed a turbidity extending from the posterior surfaces and the borders, increasing so rapidly that within two days the whole posterior surface was dim. There were also opaque radiating striæ coming from the borders of the lens. The author believed the haziness to be due to an exudation between the capsule and the lens and also between the lens fibres.

From the experiments upon animals Naphthalin has been frequently tried to arrest the progress of cataract, but so far as known at present with little or no success.

NATRUM CARBONICUM.

He could hardly open the lids; they involuntarily closed. Small ulcers about the cornea, with stinging pains in the eye, so that he was obliged to shade it from every ray of light. Needle-like stitches in both eyes, after dinner. Heaviness of the upper lids.

Eyes dim; he was constantly obliged to wipe them. Black, floating spots before vision while writing. Blinding lightnings before the eyes on waking.

NATRUM MURIATICUM.

Objective.—Redness of the margins of the lids; in the morning the eyes were agglutinated with scabs. A catarrhal affection of the margins of the lids developed; *they became red, with burning, especially in the evening while reading*; secreted mucus and were agglutinated in the morning on waking and covered with thick scabs. Spasmodic closure of the lids. Irritability of the margins of the lids and their conjunctiva. Lachrymation in the open air. *Acrid lachrymation, which makes the canthi red and sore. Redness of the white of the eyes, with lachrymation.* Redness and inflammation of the white of the eye, with a feeling as if the balls were too large and compressed. Inflammation of the eyes and lachrymation in every slight wind. *Giving out of the eyes. The eyes give out on reading*; with a pressure in the right eye, extending into the head, disappearing on walking about the room. *The eyes give out on writing.*

Subjective.—Slight pressive pain above the eyebrows. Sensitive dry sensation in the eyes, as after weeping a long time, while riding in a carriage. Pain as from a foreign body in the eye. Burning in the eyes, with increased secretion of mucus; the lids are agglutinated in the morning, with great sensitiveness to lamplight. Violent burning in the eyes in the evening. Pressure in the eyes. *Pressure in the eye on looking intently at anything.* Sticking in the right eye. Sensitiveness of the eyes. Smarting pain in the eyes. *Sensation as if sand were in the eyes in the morning.* Itching in the eyes. Itching in the inner canthi and lachrymation. Violent itching of the left inner canthus.

Vision.—Eyes dim and weak. Vision not as clear as usual; the eyes seem misty all day. Objects seem covered with a thin veil. On looking at anything, especially on sewing, sudden darkness before the eyes; she could see nothing till she directed the eyes to another object, at 6 P.M., with sleepiness. *Unsteadiness of vision; objects become confused on looking at them. Letters and stitches run together* so that she cannot distinguish anything for five minutes. Small fiery points before the eyes wherever she looks.

Clinical.—Natrium mur. has been successfully employed in a variety of ophthalmic affections, both superficial and deep. It is better adapted to chronic diseases than to those which are more acute in their course.

Well authenticated cases of morbus Basedowii are reported to have been permanently relieved by this remedy. It is, therefore, mentioned in this place, though my own experience has not verified the indication.

Stricture of the lachrymal duct, fistula and blenorrhœa of the lachrymal sac, in which the diagnosis cannot be questioned, have been benefited by this remedy.

It is very useful in certain forms of blepharitis in which the thick, inflamed lids smart and burn, with a sensation of sand in the eye and acrid lachrymation which excoriates the lids and cheek, especially if caused from caustics.

Entropium, resulting from caustic treatment of granular lids, has been cured under Natr. mur.

Dr. F. H. Boynton first called attention to Natrium mur. as a valuable remedy for follicular conjunctivitis. It is useful in this form of inflammation of the conjunctiva, in which the follicular formations are chronic and chiefly confined to the oculo-palpebral folds. It has also been of service in these cases when complicated with true trachoma.

Old cases of granular lids, with or without pannus, may require this remedy, especially if they have previously been "much treated" with caustics and are accompanied by acrid, excoriating lachrymation.

In pustules and ulcers of the cornea much benefit is frequently derived from the administration of Natrium mur., especially in *chronic recurrent cases*, though the symptoms which lead to its selection are not particularly characteristic. There may be itching and burning in the eyes or a feeling as from sand in them, usually worse in the morning and forenoon. The pains vary in character, though are not severe, with the exception of a *sharp pain over the eye on looking down*. *The lachrymation is acrid and excoriating, making the lids red and sore; the discharges from the eye are also thin, watery and excoriating* (Merc., Arsen.). The photophobia is usually well marked and the lids are spasmodically closed. *The skin of the face around*

the eye is often glossy and shining, while the lips may be sore and the corners of the mouth cracked.

Hyperæsthesia of the retina has been relieved, in which there was much lachrymation and burning in the morning, with some conjunctival injection; also in cases in which, on looking at a bright light, there was great photophobia, severe sticking in the temples and, on reading, objects seemed to swim before the sight. It is especially indicated in chlorotic females.

In asthenopia, particularly muscular, and dependent upon over-use of the eyes, in either ametropia or emmetropia, Natrum mur. is a most important remedy. By reference to the verified symptomatology of this drug, it will be seen how closely indicated it is in a large majority of asthenopic troubles. In addition to which many clinical indications have been observed, as follows: Drawing, stiff sensation in the muscles of the eyes on moving them (this is very characteristic of Natr. mur.). Pain, burning and smarting of the eyes on attempting to use them and after using them. Heat and a feeling as though there was a rush of blood to the eyes. Pain on looking steadily at distant or near objects. Severe pain over the right internal rectus muscle (BUFFUM). Use of the eyes brings on heaviness and drooping of the lids; causes letters or sketches to blur and, if continued, produces aching in the balls; lamplight is particularly troublesome; retinal images are retained; right lower lid twitches a great deal (WOODYATT). Lids smart and feel heavy on slight use of eyes, with desire to rub them; sharp shooting pains in the globe; blurred vision; constant dull aching pain in the globes; photophobia, especially to gaslight (WOODYATT). Headaches coming on in the morning, often before rising, beginning in one eye with a sensation as if the eye would be pressed out, accompanied by nausea and vomiting; when looking down, objects appear larger than when looking forward (BUFFUM). Together with the above symptoms, marked weakness of the internal recti muscles will usually be found, though in some cases the weakness of the ciliary muscle will be more pronounced. A corresponding decrease in the acuteness of vision is frequently observed and remedied by the use of Natr. mur. The following case very well illustrates its action: E. H. G., æt. 28, book-keeper, overstrained his eyes working with various colored inks, writing very fine and uninterruptedly from twelve to fifteen hours.

The general health was good. The refraction was normal, emmetropic, but considerable weakness of the internal recti prevented reading. The eye was hyperæmic and there was moderate photophobia and constant inclination to close the eyes firmly. Touch was unbearable, but hard pressure relieved. He experienced a sensation as if something sharp and sticking was in the eye. He said: "My eyes itch and burn just like chilblains; I must wipe them often and pull at the lashes." The eyes were very painful on turning them either in or out. *Natrum mur.*²⁹⁹ promptly cured.—T. F. A.

NATRUM SALICYLICUM.

Clinical.—The salicylate of soda, although an empirical remedy, often renders valuable service in relieving *severe pain in and around the eye*. In severe cases of iritis and other diseases, it may not only relieve the ciliary neuralgia, but also have a beneficial influence over the progress of the disease. Its use has been particularly noted for the relief of the pain of iritis following severe operations, as cataract extraction. From three to five grain doses repeated from one to three hours or even oftener in some cases, will usually be found necessary.

NATRUM SULPHURICUM.

Both eyes agglutinated in the morning, with photophobia.

Clinical.—As a local application in maculæ of the cornea it has seemed to hasten the absorption of the new elements and clear the cornea.

NITRICUM ACIDUM.

Yellowness about the eyes, with red cheeks. Difficulty in opening the eyes and raising the upper lid in the morning.

Burning, biting and stiches in the eyes.

Vision.—Double vision of horizontal objects at some distance. Obscuration of the eyes while reading. She can clearly distinguish nothing at night and everything seems double. Shortsighted; objects at a moderate distance were indistinct. He was obliged to stop reading in the twilight sooner than usual.

Clinical.—Nitric acid is of especial importance in diseases of the eye of syphilitic origin, or if the patient has been over-dosed with mercury or potash.

In one case of gonorrhœal ophthalmia, in which the discharge was profuse and cornea ulcerated, with burning pain, favorable results were obtained from Nitric acid³ internally and a weak solution externally.

More benefit has been derived from this remedy in *syphilitic iritis* than in any other ophthalmic disease. It seems to be adapted to those cases which are chronic in their course and unaccompanied by the customary nightly pain, or the pain is very mild in comparison with the usual iritic pains; sometimes the pain may be more severe during the day than at night. Posterior synechiæ, often very firm, will usually be found when these patients appear for treatment.

NUX MOSCHATA.

Blue rings around the eyes.

Sensation of dryness in the eyes; reading by artificial light was difficult; the *eyes would close from sleep*; the head and forehead were dull in the evening.

Everything looks too large.

Clinical.—Dr. D. J. McGuire sends me the report of a “case of episcleritis in a delicate girl of ten years, involving both eyes. The nodule over each external rectus was very large and very painful, had existed two weeks and was growing worse daily. The child was very sleepy, with dry lips and tongue, and had a tired, sleepy expression. Gave *Nux mosch.*³⁰ every three hours the first day, then three times daily. After three days, as she was much relieved, gave blank powders for two days, during which time the patient became worse. Returned to *Nux m.* with prompt relief and a cure in twelve days.”

NUX VOMICA.

Objective.—Twitching of the eyelids. Blinking of the eyes. Canthi purulent. Swelling of the eyes, with red streaks in the whites and pressive-tensive pain. Inflammation of the eyes. The eyes run water, as in a moist inflammation of the eyes or as in stopped coryza. Painless injection of the whites of the eyes. While yawning, in the morning, the eyes stand full of water, with lachrymation.

Subjective.—The margin of the lid is painful, as if rubbed sore,

especially on touch *and in the morning*. Pressure in the upper lids especially *in the morning*. The inner canthus is painful, as if sore and rubbed. The canthi are painful, as if sore. *A smarting dry sensation in the inner canthi, in the morning, in bed*. Biting in the eyes, especially in the external canthi, as from salt, with lachrymation. Itching in the eyes, relieved by rubbing.

Vision.—Vision extremely sensitive. *Vision cloudy*. *Intolerance of the daylight, in the morning*, with obscuration of vision. *Photophobia*.

Clinical.—The power of Nux vomica to relieve nervous irritability has led to its beneficial use in diverse affections of the eye, as the following clinical record will show.

In dacryo-cysto-blennorrhœa good results have been obtained from its use.—A. WANSTALL.

In ciliary blepharitis, with smarting and dryness of the lids, *especially in the morning*, our remedy will be found in Nux vom. It is also indicated in ciliary blepharitis dependent upon certain forms of gastric disturbances.

From its action in spasmodic affections we are led to its use in blepharospasmus or morbid nictitation, in which it has been given with benefit, though it is not so frequently indicated as Agaricus.

As a remedy for conjunctivitis, it is not as often called for as when the cornea becomes involved, though in both catarrhal and serofulous inflammation of the conjunctiva benefit has been derived, especially if there is marked *morning aggravation* and the usual concomitant symptoms. In acute conjunctivitis with hæmorrhages in the conjunctiva it is also sometimes indicated.

Good results were obtained from its use in ophthalmia neonatorum, in which the lids were much swollen, bled easily and the child was troubled with vomiting, constipation and flatulent colic.

Old cases of trachoma, especially if complicated with pannus and if they have had much treatment, are often benefited by this remedy. It is, however, frequently of use, either to commence the treatment or as an intercurrent remedy in trachoma with or without pannus, though it rarely effects a cure unassisted by any other drug. It has been of service in trachoma and follicular conjunctivitis occurring only in the summer and worse in the morning (compare Sepia).

Nux. vom. is frequently indicated in *ulcers* and pustules of the

cornea, especially the former, *with excessive photophobia*. An important point regarding the photophobia, as well as the other symptoms, is the *morning aggravation*, which is rarely absent. In addition to this we usually have much lachrymation and a variety of pains, none of which, however, can be said to be very characteristic, though the following are a few which have been relieved: Sharp darting pains in the eye and over it, in some cases extending to the top of the head and always worse in the morning. Burning pain in the eyes and lids. Tearing pain in the eye at night, awakening from sleep. Eye feels pressed out whenever she combs her hair. Sensation as of hot water in the eye. Pain in the lower lid as if something were cutting it. Burning pain when looking at a light, darting upward above the eyes, with pain in the eyebrow on going to bed. *Pain in the eyes in the morning*. Sometimes relief from the pain is obtained by bathing the eyes in cold water. Cases that have been overdosed by external and internal medication particularly call for this remedy.

It has proved useful in iritis, as in one case of the syphilitic variety, with moderate ciliary injection, some photophobia, hot lachrymation, morning aggravation and great sensitiveness to the air, though it cannot be often indicated.

Even after the deeper structures have become inflamed, benefit has been derived from *Nux. vom.*, as in a case of chorio-retinitis, in which there was much throbbing pain, especially in the left eye and in the morning, ball sore to touch, upper part of the sclera bright red, burning pain in the eye not relieved by bathing and aggravation of the symptoms on lying down.

In choroiditis disseminata it is a prominent remedy, especially if occurring in persons addicted to the use of stimulants; its special indications do not vary from those already given in writing of other diseases.

Of late years strychnia has been employed very extensively by the old school in the treatment of atrophy of the optic nerve and various forms of amblyopia. It is used chiefly by hypodermic injection, and in many cases with marked success. We also often find *Nux vom.* useful in atrophy of the optic nerve, checking the progress of the disease and in many cases restoring the vision to a limited extent, though it is, of course, impossible to restore the sight wholly

if genuine atrophy has once commenced. Illustrative of its action in atrophy of the optic nerve is the following: Mr. T., æt. 60, dark complexion, dyspeptic; is a smoker but does not drink. For three or four months vision had been failing. V. $\frac{20}{200}$ o. u. With convex 36, V. $\frac{20}{30}$, great difficulty. Ophthalmoscope showed white atrophy of the outer halves of both optic papillæ. Under Nux vom., 3d, 30th and 200th, the vision improved in three months to $\frac{20}{40}$, great difficulty, and with convex 30 was $\frac{2}{8}$ difficulty.

In *amblyopia potatorum*, or impairment of vision due chiefly to the use of intoxicating drinks, or even to dissipation in general, no remedy will more frequently restore to power the function of the benumbed nerve than this. Many confirmations of this assertion could be given, but the following was particularly marked: J. N., æt. 53. Diagnosis, *amblyopia potatorum et atrophia nerv. opt.* Three months previous to my seeing him he had noticed that his sight was failing. At that time he was drinking much and regularly and was an inveterate smoker. The vision had grown worse until he entered the Inebriate Asylum on Ward's Island, in which he had been for several weeks. During this time he had received no treatment, only discontinuing the use of liquor; no improvement of vision took place. The ophthalmoscope showed decided white atrophy of both optic papillæ. R. V., fingers at four feet. L. V., fingers at five feet. Nux vom., 30th and 200th was given for ten days with no benefit, when Nux v. was administered. Within six days he could count fingers at ten feet, and in two months and a half his vision became $\frac{15}{15}$ nearly, and with convex 14 could read three and a half Snellen slowly. The smoking was not stopped.

Tobacco amaurosis or amblyopia will often be benefited by the use of Nux, as can be seen from the following remarkable case: J. W., æt. 18, of a nervous temperament, had been smoking excessively from early in the morning till late at night and inhaling the smoke. One morning, three days before he was seen, on reading Greek, noticed a blur before the vision and on covering the right eye found he could not see with the left. The vision had nearly returned in the afternoon, but was again lost the next morning and did not again return. He had not used alcoholic stimulants. R. V., $\frac{20}{20}$ difficulty. L. V., fingers at six feet. No improvement with glasses.

The ophthalmoscope showed no change in refraction, media or fundus, only some sensitiveness to reflected light, which caused a stinging pain in the ball. No subjective symptoms of any kind, except the loss of vision. Two days later, having stopped the tobacco and given *Nux v.*³⁰, the vision in left eye had fallen to counting of fingers at one and a half feet. Under *Nux v.*¹, the vision at once began to improve and in three weeks was $\frac{2}{20}$ in each eye.

Dr. Boyle reports a case of *retro-bulbar neuritis* in a young girl where the loss of vision occurred suddenly; two weeks later when first seen the vision was $\frac{2}{20}$. The ophthalmoscope showed nothing abnormal in the fundus, the field for white normal, but for red very much contracted. There was soreness of the eyeball on pressing it backward, and the patient complained of feeling much worse in the mornings. *Nux vom.* was given and in three days the vision was improved to $\frac{2}{20}$ and field for red nearly normal.

Its action upon the muscles should not be overlooked, for though it is not often called for in strabismus, still it has benefited some cases, periodic in character, especially aggravated by mental excitement or when caused by an injury.

For paralytic affections of the muscles it may sometimes be useful, especially when *caused or made worse by stimulants or tobacco*. In a case recently under treatment, not of this character, it was also of service: A man, æt. 53, had noticed double vision for one week, followed by drooping of the left upper lid and complete paralysis of all the filaments of the third pair of nerves for three days. *Dull frontal headache in the morning*. Supposed to be due to exposure in a draught, though had had syphilis 23 years before. *Causticum* was given for over three weeks with no improvement, when, on account of headache, nausea and bad taste in the mouth in the morning *Nux vom.*³ was given. Headache was at once relieved and he soon began to open his eye. After eighteen days of slow improvement *Nux*¹ was prescribed and in a month the action of all the muscles was good.

Very favorable results have followed the use of this drug in asthenopia, especially when the symptoms are more pronounced in the morning; also when aggravated by stomach derangements.

ONOSMODIUM VIRGINIANUM.

The following symptoms of this drug are taken from the proving by Dr. W. E. Green¹: The ophthalmoscope shows the optic disc hyperæmic, and the retinal vessels engorged, worse in the left eye.

SUBJECTIVE—*Heaviness and dullness of the eyes.*—The eyes feel as though she had lost much sleep. Heaviness of the lids. Dull, heavy pains and soreness of the eyeballs. Eyes feel as though they were very wide open, and he feels as though he wanted to look at objects very far away. Far-off objects look large. It is disagreeable for him to look at objects near by. Tense, drawing and tired feeling in the ocular muscles. Pain in and over the left eye. Pain in the upper portion of the left orbit with a feeling of expansion. *Pains in the left side of the head and over the left eye* extending around the left side to the back of the head and neck. *Dull, heavy pains in the occiput pressing upward with dizzy sensations. Great muscular prostration and tired feeling over the entire body. The muscles feel unsteady and treacherous, as though you dare not trust them to move.* Vision impaired. Vision blurred.

We are reminded of Cimicifuga by the pains in the eyeball, and of Kalmia by the tense, stiff feeling of the muscles, but we miss the sharp, shooting pains of the latter. Ruta also bears a close relation to Onosmodium.

Symptoms are not always worse on the left side, as shown by case reported by G. S. N.: Mrs. D. had suffered for several months with headaches, which for the last two weeks had been most intense, a constant dull, stupid ache, in the right occiput and eye, worse when tired or from any sudden motion. There was some vertigo and a strained feeling in the right eye. Under Onosmodium² all the symptoms were quickly relieved.

This is one of our very best remedies in headaches from eye-strain and in muscular asthenopia.

OPIUM.

Pupils contracted.

Eyes dry and weak, with burning and a sensation as if dust were in them.

¹ Hahnemannian Monthly, 1885.

Clinical.—The use of this drug in ophthalmology has been very limited, except as an anodyne.

Two very interesting cases are, however, presented, in which Opium acted very favorably : A woman, æt. 35, had been troubled with her eyes for six weeks. Upon examination, total paralysis of the accommodation with impaired sensibility of the retina of the right eye and partial paralysis of the accommodation of the left eye was found. It was supposed to be due to the use of a cosmetic, which probably contained carbonate of lead. The other symptoms present were as follows : Almost constant frontal headache, vertigo with darting pains from the occiput to the forehead, distressing feeling of emptiness in the stomach, especially in the morning, bowels constipated and a sensation of pain and constriction as of a band encircling her chest in the line of the pleura. Nux vom.² failed. Opium³ cured.—W. A. PHILLIPS.

The second case was one of embolism of the central artery of the retina. The arteries were bloodless, veins engorged and stagnant and hæmorrhagic spots on the disc. Came on after a severe attack of neuralgia. The face was very red, numb and drawn to the right side ; tongue protruded to the right side ; speech was imperfect, nearly voiceless, except with effort ; pain in the back. All the pains were on the right side. Under the use of Opium alone he gradually recovered not only his vision but also power over the paralyzed parts.—T. F. A.

PARIS QUADRIFOLIA.

Some stitches through the middle of the eye. Jerking and twitching of the right upper lid. The eyeballs seem too large.

Clinical.—This drug produced a permanent cure of paralysis of the iris and ciliary muscle supposed to be due to an injury received two years previous. There was pain drawing from the eye to the back of the head, where there was a sore spot ; even pressure with the finger would cause her to cry out. Many black, floating specks before the vision were present.

The following symptoms have also been relieved by Paris : *Pain in the eyes as if pulled into the head.* Double vision. Headache worse in the evening, with confusion of the whole forehead and sensation as if skin of the forehead were drawn together and the

bones scraped sore, with inflamed lids, red margins and sensation as if threads drew from the eye into the middle of the head. Tension around the brow as though the skin were thick and difficult to wrinkle. "Feeling of contraction in the internal canthi."—DEADY.

PETROLEUM.

Objective.—An inflamed swelling, as large as a pigeon's egg, in the inner canthus, like an incipient lachrymal fistula, together with dryness of the right side of the nose. Lachrymation. Conjunctivitis and blepharo-adenitis.

Subjective.—Burning and pressure in the inner canthus. Itching and dryness of the lids. Burning in the eyes and pressure, with dimness on exerting them. Itching and sticking in the eyes.

The visual power is weak.

Clinical.—In disorders of the lachrymal apparatus, especially blennorrhœa of the lachrymal sac, decided benefit has been derived from Petrol.; its choice depends mainly upon the concomitant symptoms.

Within the last few years the purified preparations of Petroleum, Cosmoline and Vaseline have been used to a great extent and with much benefit as external applications in cases of blepharitis; they prevent the formation of new scabs and the agglutination of the lids, besides seeming to exert a beneficial influence over the progress of the disease. At the same time the use of Petrol. internally is highly recommended, especially if indicated by the characteristic occipital headache, rough skin, etc. Cases in which ciliary blepharitis has resulted from conjunctivitis granulosa, also when it has been a sequela of small-pox, with smarting and sticking pains in the inner canthus, have been cured by this drug.

It is sometimes indicated in trachoma with pannus, especially when occurring in a scrofulous habit, with considerable white discharge from the eye and roughness of the cheek.

It may be called for in scrofulous ophthalmia, with muco-purulent discharge from the eyes, inflammation of the lid margins and burning, itching or sticking in the eyes and lids.

Iritis, with dull pulsating pain in the occiput, may require Petroleum.

PHOSPHORICUM ACIDUM.

Clinical.—*The headaches of school children dependent upon over-use of the eyes (asthenopia) are frequently amenable to Phos. ac.*

PHOSPHORUS.

Blue rings about the eyes. Eyes sunken. Pupils contracted. Stiffness and heat in the eyes.

Vision.—He sees more distinctly in the morning and in the twilight, than during the day. Giving out of the eyes while reading. She was obliged to hold objects near in order to see distinctly; at a distance everything seemed enveloped in a smoke or mist; she could see better when the pupils were dilated by shading the eyes with the hand. Cloudiness or dimness of vision. Everything seems in a mist. A green halo about the candle-light in the evening. Flickering before the eyes and roaring in the head. Sparks before the eyes in the dark. It seems as though a black veil were before the right eye. Black floating points before the eyes. Dark objects and spots before the eyes.

Clinical.—Very little successful use of Phosphorus has been made in external affections of the eye. Its greatest sphere of action is to be found in diseases of the fundus, especially when the optic nerve and retina are involved.

In both disseminate and serous choroiditis benefit has been derived from the use of Phos. In these cases there will usually be found *photopsies or chromopsies*; in one case of choroiditis disseminata the latter were *red in color*. The following rapidly progressing case of chorio-retinitis was reported by Dr. T. F. Allen¹: "The gentleman had been writing in a cellar by poor light for several months and using tobacco to excess. Examination disclosed atrophic spots in the choroid very marked, surrounded by areolæ of active inflammation; the retina hazy, blurred; the optic disc red, somewhat swollen, with an inddefined margin; the vitreous slightly turbid, with floating opacities. He complained of a mist before vision, of pinkish globules before vision, especially after a bright light; the outlines of objects seemed uneven and wavering (trembling); *on reading, the letters looked red, especially by gas-light, and*

¹ N. Y. Jour. of Hom.

flashing of lights before vision. The patient was weak and perspired very easily, but otherwise in good health. Phosphorus²⁰⁰ removed first the red appearance of letters and very speedily all traces of acute progressive disease, leaving only the atrophied spots, which will, of course, always remain. His vision rose from $\frac{1}{16}$ to $\frac{1}{3}$, where it remains."

There seems to be no question that Phos. is a valuable remedy in clearing up the vision and relieving many subjective symptoms in old cases of glaucoma after an iridectomy has been made, as illustrated by the following cases: In a case of glaucoma after an iridectomy the patient suffered from a feeling as if something were pulled tight over the eye, with spangles (white) around the gas and a boring in the eye extending into the head. Phos. relieved the pulling sensation and headache and cleared up the vision.—T. F. A.

CASE II.—Glaucoma simplex: W. C., colored, æt. 31. Duration of disease: Left eye, four years; right eye, two years. Vision failed gradually. A greater portion of the iris in the left eye had been removed by operations eighteen and six months previously and that which remained was dilated to a rim; a large segment of the iris of the right eye had also been removed sixteen months previously. The corneæ were slightly anæsthetic. The right anterior chamber was shallow, the left normal. T. normal. The ophthalmoscope revealed "both optic papillæ almost totally white and most completely and exquisitely cupped; arteries reduced, veins not over normal in calibre; no pulsation." R. V., fingers at eight feet. L. V., fingers counted only in close contact with the eye. The field of vision of the left eye was contracted inward, downward and outward nearly to the point of fixation, while the field of the right eye was concentrically contracted, especially inward and upward. After using Phos. 1st or 3d for six months the test of vision showed: R. V. $\frac{20}{70}$. L. V. $\frac{20}{200}$.—A. WANSTALL.

In both hyperæmia and inflammation of the retina, favorable results have been obtained from this remedy. In one case it relieved very quickly a congestion of the retina in which the balls were sore on motion, no photophobia, pains extending from the eyes to the top of the head.—T. F. A.

It may be called for in various forms of retinitis. It is especially indicated in retinitis nyctalopica. From its pathogenesis we are also

led to believe that it will prove a valuable addition to our list of remedies for retinitis albuminurica and some experience seems to corroborate this view. The *degenerated condition of the blood vessels found in retinitis apoplectica* not infrequently requires the use of Phos. It not only seems to aid in restoring the proper tone to the vessels, but also appears to hasten the absorption of the hæmorrhages. (Compare with *Crotalus* and *Lachesis*.) The hæmorrhages may be confined to the different layers of the retina or (as has occasionally been the case) may have extended into the vitreous. The inflammatory symptoms are not usually prominent, the impairment of vision and hæmorrhages into the retina constituting the chief symptoms. A hæmorrhagic diathesis will often accompany the eye indications (especially hæmoptysis).

The symptom of *cherry red color before the vision*, found in optic neuritis and other diseases of the fundus, has been frequently relieved by this remedy.

Benefit has been observed from its use in stopping the progress of cataract, as in the case of an old lady, with incipient and progressive hard cataract, in whose lens were hard, white, convergent striæ with diffuse haziness; she complained that on reading the *letters seemed as if printed in red ink*, although the paper looked white and natural. V. $\frac{5}{50}$. Under Phosphorus the haziness disappeared, no more striæ appeared and in six months the vision improved to $\frac{13}{70}$.—T. F. A.

Rapidly increasing myopia has been checked in its progress by this drug.—T. F. A.

The following symptoms observed in an excessively hypermetropic person were quickly relieved: Mistiness before the vision, with attacks of vanishing of sight; eyes so weak must close them; balls seem large, difficult to get the lids over them; lids agglutinated.—T. F. A.

In weakness of the internal recti muscles it has been found indicated, as in a case of asthenopia muscularis, in which there was pain and stiffness of the eyeballs on moving them and at times a feeling of heat in the eyes as after looking at a fire (Nat. mur.)—T. F. A.

PHYSOSTIGMA.

SUBJECTIVE.—*Twitching of lids*. Drawing, twisting sensation in the eyes. Sharp, shooting and drawing sensation in the right eye.

Eyes are sore and give pain when moved from side to side. Eyes smart; lids feel sore. *The musc. internus seems not to do its work rightly and the axis of the eyes differs in each.* Felt film over the eyes and blur; objects mixed; after which dull pain over the eyes and between the eyes. Eyes feel weak. Pain in the eyeballs. *Contraction of the pupils.* *Spasm of the accommodation, which may be irregular, producing astigmatism.* Myopia. *Musce volitantes.* The accommodation recovers before the pupil.

Clinical.—Calabar bean being one of our most prominent myotics and antagonistic in its action to atropine, has been often employed to overcome the ill effects of atropine when used for purposes of examination, etc. Its action, however, is so short that frequent instillations are necessary to thoroughly counteract the action of the mydriatic and its effects are often unpleasant.

It has been used as a mechanical aid in tearing adhesions of the iris, especially to the cornea, and in cases of deep ulceration of the cornea when at the periphery, so that if perforation occurs the pupillary edge of the iris will not be drawn into the opening.

It has also been of service, used locally, in paralysis of the accommodation and dilatation of the pupils consequent upon loss of power of the oculo-motor nerve.

Its usefulness is not confined to its mechanical power, for when given internally upon physiological principles and according to the law of "similia" it is valuable.

Twitching of the lids should direct our attention to this drug, especially if combined with spasm of the ciliary muscle. In one case in which there was twitching around the eyes, patient could not read at all without much pain, frontal headache aggravated by any light, Physostigma gave quick relief.

Dr. W. H. Woodyatt, adopting the theory that myopia in a great majority of cases is due to spasm of the ciliary muscle or at least that its increase depends upon this cause, gave Physostigma 2d dec. in several cases with excellent results, often reducing the degree of myopia very perceptibly and even in some cases restoring the vision entirely. *The symptoms of irritation, pain after using the eyes, musce volitantes, flashes of light, etc.,* which might lead us to suspect spasm of the accommodation, were usually present and were soon relieved; while in other cases no symptoms of irritation were to be

perceived ; still the administration of Physostigma was followed by favorable results. The above observations have been frequently verified in practice, though hardly to the extent first reported by W. Its action in these conditions is very similar to Jaborandi, though I do not believe it to be as commonly indicated as the latter in irritability of the ciliary muscle.

It has been useful in paresis of the accommodation after diphtheria and in muscular asthenopia.—J. H. BUFFUM.

PHYTOLACCA DECANDRA.

Eyelids agglutinated and œdematous. Reddish blue swelling of the eyelids, worse on the left side and in the morning. Eyes inflamed. Lachrymation.

Aching pain along the lower half of the right orbit. *Pressure around the eyes in the afternoon as if the eyes were too large.* Smarting and sandy feeling in the eyes. Lids feel as if granulated and the tarsal edges have a scalded, hot feeling, as if raw. Photophobia.

Clinical.—There is a comparatively rare form of orbital cellulitis in which Phytolacca is a remedy of great value. The inflammation is slow in its course and not attended by severe pain. The infiltration into the cellular tissue of the orbit is very pronounced ; *hard and unyielding to touch. The eyelids are reddish-blue, hard and swollen.* The eyeball is pressed forward and its mobility impaired or lost entirely. There is chemosis and more or less dull, aching pain, lachrymation and photophobia.

It has been employed with some success in ameliorating, if not curing, malignant ulcers of the lids, as lupus and epithelioma. In blepharitis Dr. Fowler has used this remedy when the lids are thick, incruusted, dark-red, tender to touch and somewhat ulcerated.

A very interesting case of suppurative choroiditis (panophthalmitis) in the right eye of a child, after a needle operation for cataract, occurred in Dr. Liebold's clinic. The lids were enormously swollen, very hard and red, conjunctiva injected, chemosis, anterior chamber filled with pus and cornea tending toward suppuration ; child pale, weak and restless. Phytolacca was prescribed, externally and internally. Rapid subsidence of all the inflammatory symptoms followed its use.

In orbital cellulitis and panophthalmitis *Rhus tox.* should be

compared with *Phytolacca*. The former, however, more often corresponds to the symptomatology of these diseases, as the symptoms are more intense, pain more severe and inflammation more active under *Rhus* than under *Phytolacca*. The lids are also œdematously swollen and lachrymation profuse in *Rhus*, while they are hard, bluish-red and swollen in *Phytolacca*.

PLANTAGO MAJOR.

Clinical.—*Ciliary neuralgia from decayed teeth* has been relieved by this drug. "In one case there was a dull, heavy ache in the left eye, with exquisite tenderness of the ball; left upper incisor decayed. *Plantago* relieved promptly."—J. H. BUFFUM.

PRUNUS SPINOSA.

A sharp pain beginning in the right side of the forehead, shooting like lightning through the brain and coming out at the occiput. Pain in the right eyeball as if the inner portion of the eye would be torn out.

Clinical.—As a remedy for ciliary neuralgia, whether originating from some diseased condition of the eye or not, there are few, if any, drugs more often called for than *Prunus*.

The character of the pains will furnish our chief indications; thus we have pain in the eyeball as if it were crushed or wrenched, or *pain as if pressed asunder*; again we often find the *pain of a sharp, shooting* character extending through the eye back into the brain, or this sharp pain may be seated above the eye extending into and around it or over the corresponding side of the head. Sometimes the pain will commence behind the ears and shoot forward to the eye, but, as already remarked, it is generally of this sharp, piercing character. Motion usually aggravates, and rest relieves, the severity of the pains. The pains are occasionally periodic in character and may be worse at night.

These pains, to which *Prunus* is adapted, are especially found in disorders of the internal structures of the eye; therefore it has been given in many of these cases with marked benefit. Particularly in sclerotico-choroiditis post, have good results been obtained in stopping the progress of the disease.

Dr. O'Connor, who first brought this drug into notice in ophthalmic affections, says he has used it with benefit in the following cases:

“Two cases of chorio-retinitis in myopic patients, with sclerectasia posterior and fluidity of the vitreous with floating opacities in it (hæmorrhagic). One case of irido-choroiditis no fluidity of the vitreous and no floating opacities. Another case of irido-cyclitis with anterior synechiæ. Also once in an old lady, æt. 76, who had paralysis of the right side and cornea nearly opaque, with excessive congestion of the superficial and deep vessels of the conjunctiva and sclerotic.” In all these cases the pains were the chief indications.

Other cases of choroiditis, either with or without retinal complication, have been quickly relieved and the vision restored so far as possible in the degenerated condition of the tissues.

The opacities and haziness of the vitreous occurring during the course of choroidal troubles, have been known to disappear under Prunus, when given in accordance with the usual indications.

PSORINUM.

Ophthalmia, with pressing pains, as if sand were in the eyes. Soreness of the eyes and burning; she has to close them constantly. The eyes become gummy. Lachrymation.

Burning, pressing pains in the eyes. Stitches in the eyes. Itching of the lids, especially in the canthi.

Vision blurred. Fiery sparks before the eyes.

Clinical.—This remedy occupies an important position in the treatment of many ophthalmic disorders dependent upon scrofula.

Cases of ciliary blepharitis, especially if of a chronic recurrent nature, are often amenable to this drug; they are usually old chronic cases with no marked local symptoms to govern us in the selection of the remedy. Inflammation of the lids, of a more acute character, as when the internal surface has become much congested and combined with great photophobia so that the child cannot open the eyes, but lies constantly on the face, has been cured.

In old recurrent cases of pustular inflammation of the cornea and conjunctiva most benefit seems to have been gained. The chronic nature, recurrent form and scrofulous basis are our chief indications.

A case of serous choroiditis occurring in a young lady about twenty-one was greatly improved under its use. There was some ciliary congestion and great haziness of the vitreous, so that the

optic nerve was only discerned with great difficulty, and then was found decidedly hyperæmic, as was the whole fundus. Some headache was present, especially in the morning; also a profuse sweating of the palms of the hands all the time.

PULSATILLA.

Objective.—*The margin of the lower lid is inflamed and swollen, with lachrymation, in the morning. Stye on the lid, with inflammation of the white of the eye, now in one, now in the other canthus, with drawing, tensive pains in the eyes on moving the muscles of the face and with ulcerated nostrils. The inner canthus seems agglutinated with matter in the morning. The eyelids are agglutinated in the morning. Lachrymation in the cold, open air. The eyes are full of water in the wind. The eyes are full of water; they lachrymate; blear eyed. A red (inflamed) spot on the white of the eye, near the cornea.*

Subjective.—Dryness of the lids. A biting pain and a sensation of soreness in the inner canthus. Pressive pain in the inner canthus. Violent sticking in the eyelids and canthi in the evening. *Itching (biting) and burning in the lids in the evening.* Itching in the inner canthi, like the healing of an ulcer in the evening after sundown; after rubbing, there is a pressive, fine, sticking pain. Dryness of the eye and a sensation in the morning as if a foreign body were pressing in it. Dryness of the right eye and a sensation as if mucus were hanging before the eye that obscured the vision and that could be wiped away, in the evening. Pressure as from sand in the eye when reading. Pressive pain in the eyes as if there were heat in them. Pressive pain in the left eye. A pressive, burning pain in the eyes. Pressive, burning pain in the eye as if a hair were in it. *Burning and itching in the eyes, that provokes rubbing and scratching.* Itching-sticking in the eyes, that provokes scratching. Itching of the eyes.

Vision.—Dimness of vision. *Dimness before the eyes and lachrymation in the open air.* Weak vision. Dimness of vision, like a fog before the eyes. Obscuration of vision, with inclination to vomit and paleness of the face. Dizzy obscuration of vision after sitting, on rising and beginning to walk about. Obscuration of vision, like a fog before the eyes on rising from a seat and walking.

Transient obscuration of vision. It seems dark before the eyes in the morning on rising from bed. *During the menses it became black before the eyes and she felt worse on going into a warm room.*

Clinical.—This remedy is very frequently indicated in a great variety of diseases of the eye, but in its selection we are governed in a great measure by the temperament and general symptoms of the patient. Those eye troubles, especially the superficial, found in the *negro race, as well as those occurring in the mild, tearful female,* seem to be particularly amenable to Pulsatilla.

Its action upon the lachrymal sac is very decided. No remedy is more frequently needed in the *early stages of acute phlegmonous dacryocystitis* than Pulsatilla. It will sometimes abort the inflammation and prevent the formation of pus, even when the swelling at the inner angle of the eye is extensive, sensitive to touch and involves both lids. It may be useful throughout the whole course of the disease. For blennorrhœal inflammation of the lachrymal sac it is also valuable, especially if the *discharge is profuse, yellow, white, thick and bland* and occurring in a Pulsatilla temperament. It has appeared to be particularly called for in affections of the lachrymal sac found in children.

For blepharitis, both acute and chronic, it is a valuable remedy, especially if there is inflammation of the glands of the lids, both meibomian and sebaceous; also in cases of blepharitis in which there is a great tendency to the formation of styes or abscesses on the margin of the lids. It is called for in blepharitis resulting from indulgence in high living or fat food and if accompanied by acne of the face. The swelling and redness of the lids vary in different instances, as does also the discharge, though more frequently we find profuse secretions, which cause agglutination of the lids in the morning. The sensations experienced are usually of an itching, burning character, and are aggravated in the evening, in a warm room, or in a cool draught of air, but *ameliorated in the cool open air.*

If prescribed early in the treatment of *styes* (hordeola) it will, in the majority of cases, cause them to abort without the formation of pus. It is especially adapted to the attack *per se*, but may be of service in preventing the recurrence of successive crops.

In tarsal tumors, especially of recent origin, subject to inflammation or when accompanied by a catarrhal condition of the eye, help has been derived from its use.

Spasmodic action of the lids, with lachrymation and photophobia, has been relieved.

Pulsatilla has been successfully employed in a great variety of conjunctival and corneal affections. It is often the remedy for simple catarrhal conjunctivitis, especially the acute form (though also useful in the chronic) either resulting from a cold, from bathing, an attack of measles, or other cause; if there is present a variable amount of redness, even in some cases chemosis, *burning, itching or sticking pain in the eye; usually worse in the evening, when out in the wind, and after reading, but relieved in the cool open air.* The lachrymation may be profuse by day, with purulent discharge at night, though generally a moderately profuse muco-purulent discharge of a whitish color and bland character, which agglutinates the lids in the morning, is to be found. Catarrhal conditions of the conjunctiva dependent upon gastric disturbances may also require this remedy.

In purulent ophthalmia, benefit will frequently be derived from this drug if the *discharge is profuse and bland* and the concomitant symptoms also indicate its selection. The form of purulent *ophthalmia found in new-born children* (ophthalmia neonatorum) has been greatly benefited; even in some instances well marked cases have been cured without the use of any other drug. It seems, however, especially useful in this trouble as an intercurrent remedy during the treatment by *Argentum nitricum*, for often when the improvement is at a standstill a few doses of Pulsatilla will materially hasten the progress of the cure.

It has been employed with some success in trachoma, usually uncomplicated with pannus. The granulations are generally very fine; eye sometimes dry or may be bathed in an excessive secretion of bland mucus. There may also be soreness of the ball to touch and itching or pain in the eye, worse in the evening and better in the cool air or by cold applications. It is especially adapted to cases occurring in *anæmic amenorrhœic females*.

Another large class of superficial ophthalmic disorders in which Pulsatilla is particularly useful is to be found in scrofulous ophthalmia, phlyctenular conjunctivitis or keratitis. Here it has proved one of our sheet anchors in the treatment, especially *if the pustules are on the conjunctiva.* The dread of light is usually moderate in

degree, though it may be absent. The lachrymation is not acrid, but more abundant in the open air, while the other discharges may be very moderate or profuse, thick, white or yellow and bland. The pains are more often of a pressing, stinging character, though they vary greatly. The lids may be swollen, but are not excoriated, though *subject to styes*. The eyes feel *worse on getting warm from exercise, or in a warm room and generally in the evening, but are relieved in the open air and by cold applications*. The concomitant symptoms of ear disorders, thirstlessness, gastric derangement and amenorrhœa must be taken into consideration.

Pukatilla has been successfully given in ulcers of the cornea, especially if superficial and resulting from phlyctenules. Excellent results have also followed its use in those *small ulcers* which prove so intractable to treatment, occurring *near the centre of the cornea*, with no vascular supply, especially if found in strumous subjects, with phlyctenules on the cornea or conjunctiva. The photophobia and pain are usually considerable in these cases.

In a case of conical cornea occurring in a colored girl, *æt.* 23, with occasional shooting pain through the right eye, fingers could only be counted at four feet with right eye and ten feet with left eye. Two months afterward, under Puls.³⁰ she was able to count fingers at seven feet with the right eye and twenty feet with the left eye.

A case of episcleritis, circumscribed, situated between the superior and external recti muscles, was very promptly relieved by this remedy. It occurred in a man, highly myopic: the sclera was slightly bulged and some itching, sticking pain in the ball, with dimness of vision. His eyes always felt much better in the open air.

This drug may occasionally be required in idiopathic iritis, especially in young girls with delayed and scanty menstruation. More often indicated in the colored race.

Its influence upon choroidal affections was illustrated in a case of hyperæmia of the choroid consequent upon hyperopia. The patient could not look long at any object; was subject to severe neuralgic headaches extending into the eyes; head felt full and congested; was a great tea drinker. Puls. effected a cure.—T. F. A.

Payr recommends this drug in sub-acute cases of choroiditis in persons subject to arthritis vaga, venous hyperæmia of the capillaries, pressing, tearing and throbbing pain in the head, with heavi-

ness and vertigo, dull sight, photophobia and fiery circles before the eyes. Females with mild and yielding disposition, scanty and delayed menstruation.

The value of Pulsatilla in hyperæmia and inflammation of the optic nerve and retina is not, I believe, fully appreciated. Its marvellous results and indications for selection are well illustrated in the following cases: A clerk complained of a sensation as of a veil before his eyes, especially in the bright light, together with *headache when in the store, relieved in the open air.* V. $\frac{12}{0}$, difficulty. The ophthalmoscope revealed decided injection of the retinal vessels, halo around the macula lutea and hyperæmia of the optic nerve, more marked in the right eye. Within a week, under Puls.²⁰, the hyperæmic ring around the macula, dimness of vision and headache were relieved.

The second case was of so much interest that it will be given in full as published in *Trans. of Ophthal. and Otol. Soc.*, 1879. *Neuritis N. O. (choked disc).* Carl H—, æt. 32, barber, applied to me at New York Ophthalmic Hospital November 26, 1878, on account of loss of sight. Reports that his sight had always been good till five days ago, when it began to fail in his right eye; since then has been rapidly growing worse, until now can see very little with this eye; within the last twenty-four hours has noticed a blur coming over the left eye. Has not been well for some time; four weeks ago had a "kidney trouble," though cannot tell what it was; also for five weeks has had an almost *constant pain in the forehead, which at times becomes most intense, seeming as if it would drive him crazy. This pain is always much better in the open air.* His appetite is good and he feels well in every other way. He is of a light complexion and nervous temperament. *Status præsens.* R. V. fingers at four feet. L. V. $\frac{20}{0}$. Nothing abnormal externally. Media clear. R. E.—Optic papilla shows the characteristic appearances of "stauungs papilla;" disc very much swollen, reddish-gray and striated; outlines ill-defined; veins engorged and covered here and there by the exudation. Retina very little involved and macula lutea apparently normal. L. E.—Similar changes beginning, swelling of nerve entrance, especially of inner two-thirds, veins enlarged, arteries about normal and partially hidden by the swelling. Examination of the urine gave a slight trace of albumin. Heart's

action normal. Admitted him to the hospital, put him to bed and gave Bell.³

Dec. 3d.—Having found that his headache seemed to be increased while in bed, have allowed him to be up for the past two or three days and take exercise in the open air, which always relieves the severe pain in the head. The vision remains the same, as well as the ophthalmoscopic appearances. *R.* Puls.³⁰

Dec. 5th.—*R.* V., fingers at ten feet. *L.* V. $\frac{20}{0}$. Swelling of optic disc decidedly less. Headache has been better, though had a severe attack this morning. Repeat.

Dec. 11th.—Only a very little swelling of nerve entrances. The headache is greatly improved, though seems to be moderately severe every second day. Vision not tested as it was dark when examined. Discharged from hospital. Continue medicine.

Dec. 30th.—*R.* V. $\frac{20}{0}$. *L.* V. $\frac{20}{0}$. Headache only occasionally. No ophthalmoscopic appearances that would lead one to suspect that an engorged papilla had been present.

In a case of immature hard cataract with blurring of the sight, especially in the forenoon, and some conjunctival irritation, the progress was checked and vision improved under Puls.²⁰⁰—A. WASTALL.

Accommodative asthenopia, with much aching sensation in the eyes after using; also darting pains in the eyes after sewing, and asthenopia from general prostration, have been cured.—T. F. A.

RANUNCULUS BULBOSUS.

Sensation of burning soreness in the right lower lid. Smarting and feeling of soreness in the outer canthus of the right eye. Smarting in the eyes. Sore smarting within the right eye. Smarting in the eyes as from smoke. Violent pressing pains in the eyeballs, at times in one, at times in the other. Painfulness of the right eyeball. Mist before the eyes.

Clinical.—Ranunculus was found indicated in one case of herpes zoster supra-orbitalis, with bluish-black vesicles, high fever and the usual pains accompanying this disease. The success consequent upon the use of the drug was exceedingly brilliant.

RHODODENDRON.

Dilatation of the pupils. Periodical burning in the eyes without inflammation. Burning pain in the eyes; when reading or writing he has a feeling of heat in the eyes.

Clinical.—Very marked and satisfactory results were obtained from Rhod. in the following case: A man, about 40, complained of gradual failure of sight, accompanied by periodically recurring pains of the most violent character involving the eyeball, extending to orbit and head, *always worse at the approach of a storm*, and ameliorated when the storm broke out. The patient had a strongly marked rheumatic diathesis, otherwise general good health. On examination, the pupils were noticed to be somewhat dilated and sluggish. T. + 1 in both eyes. Pulsation of the retinal veins, but no excavation of the optic nerve. Field of vision not circumscribed. Hm. $\frac{1}{30}$. Vision improved by glasses, but could not be brought above $\frac{2}{30}$. The ability to use the eyes was greatly improved by convex 36, and afterward by convex 24, but the attacks of pain continued to recur and his vision suffered sensible impairment from every attack. These pains were promptly relieved under Rhod., so that within six months he was entirely relieved of the attacks, though he has continued to keep the medicine by him for several years. His vision has gradually improved, so that it is now fully $\frac{2}{30}$.—T. F. A.

In insufficiency of the internal recti muscles (asthenopia muscularis) benefit has been derived, as was well marked in a case, in which darting pains like arrows through the eye from the head, always worse before a storm, was an accompanying symptom.—T. F. A.

Ciliary neuralgia, in which the *pains are always aggravated before a storm*, will usually be relieved by Rhododendron.

RHUS TOXICODENDRON.

Objective.—*Inflammation of the lids.* A red, hard swelling, like a sty, on the left lower lid, toward the inner canthus, with pressive pain. *Great swelling of the lids.* The eyes are red and agglutinated with matter, in the morning. Relaxation of the eyelids, with puffiness of lids and hot flushed face. *Heaviness and stiffness of the*

lids, like a paralysis, as if it were difficult to move the lids. Lachrymation in the evening, with burning pain. Weeping eyes. *Inflammation of the eyes.* The white of the eye is red in the morning, with burning pressure in it.

Subjective.—Drawing and tearing in the region of the brows and in the malar bones. *Very sore around the right eye.* Violent burning, itching and prickling in the swollen eyelids. Burning in the inner canthus of the right eye. Itching in the eyes on exerting vision. Aching in the eyes. Her left eye felt enormously swollen and enlarged. Pressive pain in the eyes. Pressure as if dust were in the eye. Sharp pains run from the eyes into the head. Biting as from something sharp and acrid in the right eye. Biting in the eyes; in the morning the eyes are agglutinated with matter. *When he turns the eye or presses upon it, the eyeball is sore, he can scarcely turn it.*

Vision.—Sensation of a veil before the eyes; she could not see well. Extreme confusion of sight. Great obscurity of vision. Objects were seen double.

Clinical.—The clinical application of this drug in diseases of the eye is extensive and merits careful consideration. It is of value in many ophthalmic disorders, but it seems especially adapted to the severer forms of the inflammatory process, in which there is a great tendency to suppuration, or even when the formation of pus has already taken place.

For *orbital cellulitis* it is a remedy of the first importance and will no doubt be oftener called for than any other drug, whatever may be the origin of the trouble (whether traumatic or not), as the picture of the disease corresponds very closely to the symptomatology of the drug and experience has proven the truth of the assertion that it is *the* remedy for the treatment of this dangerous malady. Some alarming cases of this disease have been promptly arrested by this drug. In one case, one eye was entirely lost and had been operated upon with a view of providing free exit for the suppurative process and the disease was making alarming and rapid progress in the other eye. Rhus¹ speedily arrested its progress.

Epiphora of long standing with no apparent stricture of the lachrymal duct was immediately relieved under Rhus.³⁰

It will be seen from a study of the symptoms which Rhus pro-

duces upon the palpebræ that its curative power is chiefly exerted upon those symptoms of the lids which are dependent upon inflammation of the deeper structures. However, we may often find it a valuable remedy in uncomplicated blepharitis, especially of the acute form, if there is a tendency to the formation of an abscess and the lids are *œdematously swollen*, accompanied by *profuse lachrymation* and pains which are worse at night and relieved by warm applications.

We also occasionally find it useful in chronic inflammation of the lids in which there is puffiness of the lids and face, enlargement of the meibomian glands, falling out of the ciliæ, itching and biting in the lids, sensation of dryness of the eyes and burning in the internal canthus, with acrid lachrymation in the morning and in the open air, or, as is more commonly the case, constant profuse lachrymation which may be acrid or not.

Simple œdema of the lids has been relieved. (Compare Apis, Ars. and Kali carb.)

In erysipelas of the lids of spontaneous or traumatic origin it is a very important aid in the treatment, if there is œdematous erysipelalous swelling of the lids and face, with small watery vesicles scattered over the surface and drawing pains in the cheek and head.

In any of these cases in which the lids are affected, there is frequently *spasmodic closure with profuse lachrymation upon opening them*, which more than ever points to the employment of Rhus.

Ptosis has been relieved under this remedy; it is probably adapted to that variety caused from exposure to cold or wet (Caust.).

Simple conjunctivitis caused from exposure to wet, or aggravated in damp weather (Calc.) frequently calls for Rhus, especially if there is much *chemosis*, with some photophobia, profuse lachrymation and œdematous swelling of the lids.

In severe cases of conjunctivitis granulosa with pannus the intensity of the symptoms may occasionally be relieved by the use of this remedy and possibly a cure be effected.

Rhus may in rare cases be found serviceable in ophthalmia neonatorum if the lids are red, œdematously swollen and spasmodically closed. There will also be restlessness at night and other concomitant symptoms.

In ulcers and pustules of the cornea Rhus has been often employed with success, especially in the latter and superficial forms of ulceration in which the *photophobia is very great*, so that the patient lies constantly on the face. *The lachrymation is very profuse, so that the tears gush out on opening the spasmodically closed lids*, which are usually much swollen, especially the upper. The conjunctiva is quite red; *chemosis*. The skin of the face around the eye is often covered with a Rhus eruption. The remedy is especially suitable to persons of a rheumatic diathesis. The symptoms are usually worse at night, after midnight and in damp weather, therefore the patients are restless at night and disturbed by bad dreams.

Its action, however, is not confined to the superficial variety of keratitis, as great benefit has been observed from its use in *suppuration of the cornea, especially if consequent upon cataract extraction*.

In simple idiopathic or rheumatic iritis this drug has proved serviceable, especially in those cases resulting from exposure to wet, or if the predisposing cause can be referred to a rheumatic diathesis.

Mydriasis from exposure to cold and dampness has been relieved by Rhus.

Its grandest sphere of action is to be found in *suppurative iritis*, or in the still more severe cases in which *the inflammatory process has involved the remainder of the uveal tract* (ciliary body and choroid), especially if of traumatic origin, as after cataract extraction. As a remedy in this dangerous form of inflammation of the eye it stands unrivalled, no other drug having, as yet, been found equal to it in importance in this serious malady. The symptoms of the drug will be seen to correspond very closely to a great majority of the cases. *The lids are red, swollen and œdematous, especially the upper, and spasmodically closed, with profuse gushes of hot tears upon opening them; sac-like swelling of the conjunctiva and yellow, purulent, mucous discharge; pain in and around the eye; swelling of the cheek and surrounding parts, besides the usual concomitant symptoms*. For suppurative inflammation of a part or whole of the uveal tract of non-traumatic origin, Rhus has been known to restore the eye "ad integrum;" even if the formation of pus has already taken place it may cause its absorption. We also think from experience that it serves, to a certain extent, to prevent suppurative

inflammation after severe operations upon the eye, though do not by any means consider it a sure preventive.¹

In paresis or paralysis of any of the muscles of the eyeball resulting from rheumatism, exposure to cold or getting the feet wet this remedy is very useful and should be compared with Causticum in frequency of indication.

The symptomatology of Rhus and Apis are somewhat similar, but the latter is not as frequently indicated in severe inflammations of the deep structures which tend toward suppuration as the former. The Apis patient is drowsy and thirstless, while the Rhus patient is restless and thirsty (Arsen).

Rhus radicans has been employed with great success in serofulous ophthalmia in which the same symptoms are present which have been given under Rhus tox.

RUTA GRAVEOLENS.

Cramp in the lower lid, the tarsal cartilage is drawn back and forth, and after this ceases water runs from both eyes for an hour and a half.

Subjective.—Pressure deep in the orbits. Pain as from a bruise in the tarsal cartilages. Stitches in the left frontal bone only while reading. *Pressure over the eyebrow.* Itching in the inner canthi and on the lower lids that after rubbing became a biting, so that the eye filled with water. Burning beneath the left eye. *Sensation of heat and fire in the eyes and aching while reading (in the evening, by the light).* Slight pain like a pressure in the right eye, with obscuration of vision, as if one had looked too long and intently at an object which distressed the eye. Pressure on the inner surface of the left eye, with profuse lachrymation. *The eyes feel fatigued, as after reading too long.* Weary pain in the eyes while reading.

Vision.—*Vision very weak, as if the eyes were excessively strained.* Objects seem dim before the eyes, as if a shadow were flitting before it.

Clinical.—Ruta has been of service in a case of choroiditis in a

¹ NOTE.—If most prompt results are not found from the higher potencies in a few hours, the first should be resorted to. This is a most important note to make, for not a moment can be lost in arresting the disease, nor can we afford to produce an aggravation in a sensitive subject with large doses.

myope, resulting from over-straining the eyes. There was much pain in the eyes on trying to look at objects, heat in the eye (though it seems cold) and twitching in the eyeballs.—T. F. A.

Under the use of this drug the vision has been restored in amblyopia dependent upon over-exertion of the eyes in anomalies of refraction, or even when no cause has been apparent.

Its chief value is to be found in the relief of asthenopia, in which it is a remedy of the first importance. It is more often indicated in *weakness of the ciliary muscle* than of the internal recti. Such asthenopic symptoms as heat and *aching* in and *over the eyes*, feeling as if the eyes were balls of fire at night, blurring of the vision, letters seem to run together and lachrymation, which are caused or always made worse by straining the eyes at fine work or too much reading, are often relieved by a few doses of Ruta.

We must, of course, remember that a great majority of these cases are dependent upon anomalies in the refraction or accommodation which render the proper selection of glasses absolutely necessary before we can ameliorate the asthenopic symptoms.

In comparing the usual remedies employed in asthenopia it will be found that Conium and Arg. nitr. are very similar in their action to Ruta; all three are especially called for in accommodative asthenopia. Conium has more photophobia and Arg. nitr. more tendency to catarrhal symptoms than Ruta. The asthenopic symptoms which Nat. mur. relieves are more commonly dependent upon muscular asthenopia.

SANGUINARIA.

Redness of the eyes in the morning. Lachrymation. Burning dryness in the eyes. Pain over the eyes. Dilatation of the pupils. Headaches in a small spot over the right eye. Eyes relieved by hard pressure upon the eyeballs.

Clinical.—Benefit has been derived from its employment in blepharo-adenitis, with a feeling of dryness under the upper lid and burning in the edges of the lids, with accumulation of mucus in the eye in the morning.

Acute conjunctivitis, with excessive redness and numerous ecchymoses in the conjunctiva, tending towards trachoma, with moderate discharge and some pain in the eye, has been speedily cured by the local use of Sanguinaria (gtt. x : aq. c. ʒj).

SECALE CORNUTUM.

Cataracts, both hard and soft. Eyes sunken and surrounded with a blue margin. Dilatation of the pupils. Dimness of vision.

Clinical.—Favorable results were obtained from Secale in a case of suppuration of the cornea, aggravated by warm applications.—
C. A. BACON.

The unquestionable production of cataract by this drug should suggest its use in checking the progress of this disease.

From a study of the general action of Secale, it is recommended for retinitis diabetica.

SENEGA.

Weakness of the eyes, with much smarting, burning and lachrymation. Weakness of the eyes when reading, with lachrymation on exerting them too much. When looking at an object intently or permanently the eyes tremble and run. Aching pain over the orbits. Dull, aching, pressive pains about the eyes. Drawing and pressure in the eyeballs, with diminution of visual power.

Vision.—Weakness of sight and flickering before the eyes when reading, obliging one to wipe them often. Objects look shaded. While reading the eyes feel dazzled; this makes reading difficult. Flickering before the eyes and weakness of sight when continuing to read or write. When walking toward the setting sun he seemed to see another smaller sun hover below the other, assuming a somewhat oval shape when looking down, *disappearing on bending the head backward and on closing the eyes*. Flickering and running together of letters when reading.

Clinical.—The action of Senega upon the lids is very marked in the provings. This, together with its marked action upon general mucous surfaces, renders its use in catarrhal ophthalmia obvious, as also in blepharitis, in which there is smarting and dry crusts on the lids, especially in the morning.

Very marked improvement was observed from this drug in an old case of opacities in the vitreous. Within three months the vitreous had cleared to such an extent that the vision had increased, from counting fingers at ten feet, to $\frac{1}{10}$ and was still improving under Senega.³—A. WANSTALL.

Senega is of great importance in promoting the *absorption of lens fragments* after cataract operations or injuries to the lens.

In addition to and corresponding with the general muscular laxity we find remarkable symptoms of paralysis of the muscles of the eye. It has proved most brilliantly curative in paresis of the left oculomotor nerve, with paralysis of the superior rectus muscle in which the patient could only see clearly by bending the head backward, as this position relieved the confusion of double vision which caused him to take missteps. The upper lid was very weak, falling half over the eye; difficult convergence; weak back; deficient muscular power; subject to bilious headaches. Senega²⁰⁰, a dose every twenty-four hours, was given. Double vision was better in a few days. Cured in a few weeks.—T. F. A.

This remedy is of first importance in weakness or even paralysis of the recti and oblique muscles, especially in hyperphoria. The patient will usually complain of dull, tired, aching or pressive pains in, around or behind the eyes, with smarting and burning in the eyes, always worse after any use. There may be conjunctival catarrh and often general headache or dullness in the open air.—G. S. N.

SEPIA.

Objective.—*Lachrymation, morning and evening.* Lachrymation in the open air. Drooping of the eyelids, with the dull headache. Agglutination of the eyelids. A red, herpetic spot on the upper eyelid, scaly and peeling off. *Pustules on the conjunctiva of the left eye.* A swelling in the eyes, burning and a flow of tears, which affords relief. Inflammation of the eyes, with redness of the whites; stitching and pressure therein. Redness of the white of the eye in the morning on awaking, with burning, smarting and pressure. The eyes feel tired and look injected.

Subjective.—Eyelids heavy, with much frontal pain. Heat and dryness of the margins of the lids. The eyelids pain on awaking as if too heavy. Great itching of the margins of the lids. Momentary attacks of giddiness while writing. Both eyes feel heavy and the lids are inclined to close. Pain in the eyes several times, with headache and heat in the eyes. In the evening, after walking in the cold wind, I had a sore, rough, burning feeling in my eyes, aggravated by gas-light and on attempting to read. Eyes feel very sore,

as if bruised. Dragging feeling in eyes. Pressure in the right eye, as from a grain of sand, aggravated by rubbing; felt most sensitively when pressing the eyelids together. Pressure in the eyes at night. Great burning and lachrymation of the eyes. Burning in the morning. Eyes hot and dry. Eyes feel like balls of fire, especially the left, which is much injected. A slight burning feeling in the eyes and a desire to close them; they feel sore to touch. Smarting pain in both eyes. *Smarting in the right eye, in the evening*, with inclination of the lids to close against one's wish. The eyes become fatigued from reading and writing. The candle-light fatigues the eyes when reading or writing by causing a contractive sensation. Cannot bear reflected light from bright objects; annoyed by reflections from bright objects.

Vision.—Vanishing of sight. Vision is impeded by fiery zigzags before the eyes. Fiery sparks before the eyes, with great weakness. Flickering before the eyes when looking into light; he sees a zigzag circle of colors. Many black spots before the eyes. During the menses everything gets black and clouded before the eyes, in the evening, accompanied by great weakness, which passes off when lying.

Clinical.—Sepia is especially adapted to ophthalmic disorders dependent upon uterine troubles, and in prescribing this drug great reliance should be placed upon these and other accessory symptoms.

The *aggravation morning and evening*, and the amelioration in the middle of the day are almost always present.

In chronic ciliary blepharitis very favorable results have been obtained from Sepia. In addition to the scaly condition of the lid margin, *small pustules* (acne ciliaris) will usually be found on the ciliary border (Ant. crud.). The subjective symptoms will also indicate our choice, as feeling of heaviness in the lids in the morning, or on waking at night; soreness or numb pain in the internal canthi and scratching sensation in the eyes, worse at night and at any time during the day, upon closing the lids, as they feel as if they were too tight and did not cover the eye. The aggravation of the symptoms morning and evening will usually be noticed.

Tarsal tumors have been benefited by Sepia².

Acute catarrhal conjunctivitis, with *drawing sensation* in the external canthus and smarting in the eyes, ameliorated by bathing in

cold water and *aggravated morning and evening*; also conjunctivitis, with muco-purulent discharge in the morning and great dryness in the evening, have been quickly relieved under this remedy.

In follicular conjunctivitis, or a mixed form of follicular and trachomatous conjunctivitis, and in conjunctivitis vernalis, which is only observed *during the summer*, or always made worse by hot weather, Sepia is especially indicated. In one case of a lady who had suffered every summer for twenty years from the beginning of the warm weather in the spring till its close in the fall with severe conjunctivitis, much enlargement of the papillæ, and marked aggravation in the morning and usually in the evening; a prompt cure resulted under Sepia³⁰. It may be serviceable in trachoma, with or without pannus, especially in tea-drinking females. It is indicated if there is excessive irritability of the eye to both use and light, particularly night and morning, better through the day; lids close in spite of him and sparks may be flashing before the eyes.

It is sometimes indicated in phlyctenular conjunctivitis, though not as frequently as when the cornea is implicated.

For keratitis phlyctenularis, especially in females suffering from uterine disturbances, Sepia is of great value. The pains are usually of a drawing, aching or sticking character, aggravated by rubbing, pressing the lids together, or pressing upon the eye. The light of day dazzles and causes the head to ache, with lachrymation, especially in the open air. The conjunctiva may be swollen, with considerable purulent discharge, edges of lids raw and sore and eruption on the face. The usual time of aggravation is present.

Dr. C. Th. Liebold has used it with very favorable results in keratitis parenchymatosa complicated with uterine troubles.

At Dr. W. H. Woodyatt's suggestion, Sepia has been employed in several cases of cataract, especially in women, with manifest advantage, arresting the progress of the disease and often improving the vision very decidedly. The concomitant symptoms will guide us in the selection of this remedy in diseases of the lens.

A case of astigmatism resulting from granular lids, in which on reading black seemed gray, with improvement of the vision on looking out under the brows, and pain on using the eyes by artificial light, terminated in recovery under the use of Sepia.—T. F. A.

SILICEA.

Objective.—*Swelling in the region of the right lachrymal gland and lachrymal sac.* Lachrymation. Agglutination of the eyes at night, with smarting of the lids. Agglutination of the eyes in the morning. Twitching of the eyelids. Redness at first around the eyes, then also of the white of the eyes, with inflammation and lachrymation. Redness of the whites of the eyes.² *Ulcer on the left eye.* Eyes weak.

Subjective.—Pressure in the upper lid, with violent stitches, as from a splinter, and vanishing of visual power. The eyes are painful, as if too dry and full of sand, in the morning. Tension in the eyes and forehead, with weakness of the body. Piercing, stinging pain in the left eye. Sudden piercing pain in the left eye. Tearing and burning in the eyes on pressing them together. Heat and smarting in the eyes.

Vision.—Vision indistinct, misty, with flickering before the eyes. She could neither read nor write; everything ran together.

Clinical.—Silicea is more commonly indicated in caries of the orbit than any one remedy in the materia medica. Its value was very forcibly illustrated in the following case: A girl, æt. 14, had for four months a constant discharge and ulceration under the right lower lid, the result of a severe inflammation. Examination showed, over the right inferior orbital ridge cicatrices which everted the lid, together with three openings, as found over dead bone, discharging a yellow white pus. On probing, caries of the lower orbital arch was found extending over the malar and superior maxillary bones and connecting by sinuses with the upper jaw, opening over the first molar tooth, through which opening the discharge escaped into the mouth. Silicea³⁰ was prescribed. At first occasional injections of a one per cent. solution of carbolic acid was used, but soon discontinued. Under Silicea a cure was effected, leaving only a slight scar which was not adherent and the lid returned to its normal position.

In diseases of the lachrymal apparatus it is a remedy of prime importance. It is often indicated in inflammation of the lachrymal sac (dacryocystitis) characterized by all the prominent symptoms, swelling, tenderness, pain and lachrymation, especially if the patient takes cold easily or is very sensitive to a draught of air. Several

cases, even though so far advanced that suppuration seemed inevitable, have been cured without breaking externally and without the aid of an operation. But, notwithstanding, experience shows how much may be sometimes gained from the administration of Silicea and other remedies, yet we would not advise delay in opening the canaliculus as soon as pus has begun to form.

Blennorrhœa of the lachrymal sac has quite frequently been controlled, and Sil. should be one of the first remedies thought of in connection with this trouble.

The treatment of acute lachrymal fistulæ by Sil. has been attended with favorable results, but chronic cases do not seem to yield to this or any other drug.

Blepharitis, either acute or chronic, caused or aggravated from working in a damp place or from being in the cold air will often require Silicea (compare Calc.).

It has been useful in tarsal tumors when indicated by concomitant symptoms.

Silicea is often the remedy for sloughing ulcers of the cornea, with or without hypopyon; for *crescentic ulcers*; for small round ulcers which have a tendency to perforate, and also for non-vascular ulcers centrally located. The pains, photophobia and lachrymation, are not particularly marked. The discharge is frequently very profuse, though it may be moderate in quantity. But there is almost always present in these cases, in fact in the majority of ophthalmic disorders which call for Silicea, a *great sensitiveness to cold and desire to be warmly wrapped, especially about the head.*

For hypopyon it is especially valuable.

The following case of sclero-choroiditis ant. was effectually relieved by this remedy: The conjunctiva and sclera were both injected and a bluish, irregular bulging around the cornea was present. The retina was hazy, though no opacities were visible in the vitreous. There were severe pains extending from the eyes into the head, relieved by warmth; also a severe aching in the back of the head on one side, corresponding to that eye which was worse; the severity of the symptoms alternated from one eye to the other.—

T. F. A.

It has also proved useful in choroiditis in a myope in whom, upon any exertion of the eye, excessive pain extended to the head and ears.

—T. F. A.

Irido-choroiditis, with great tenderness of the eye to touch, deep ciliary injection, contraction of the pupil, posterior synechiæ and excessive sensitiveness to a draught of air will be found amenable to Silicea.

Many brilliant cures of cataract under this remedy are reported, though grave doubts are entertained regarding the correctness of the diagnosis. It may be serviceable, however, in checking the progress of cataract when indicated by concomitant symptoms, upon which chief reliance is placed in prescribing for diseases of the lens.

Ciliary neuralgia, characterized by *darting pains through the eyes and head upon exposure to any draught of air*, or just before a storm, has been speedily relieved by Silicea.

Silicea and Hepar should be compared with each other, as their actions are very similar. Both are indicated in ulcerations, are relieved by warmth and aggravated by cold. The ulceration of Hepar is, however, usually accompanied by more pain, redness, photophobia and sensitiveness to touch than that of Silicea.

SPIGELIA.

Objective.—Lids lax and paralyzed; they hang low down and must be raised with the hand, with dilated pupils. Redness and inflammation of the white of the eye; in the morning the lids are so heavy that he can scarcely open them. Redness of the white of the eye. Lachrymation.

Subjective.—Pain as if the upper lid were hard or immovable; he cannot raise it easily. Fine painful cutting on the margin of the left lower lid like a knife. Striking pressure under both lids. Pain as if the left orbit were pressed from above downward. *Tensive, tearing pain in the forehead, especially beneath the left frontal eminence, extending toward the orbits. Thrust-like tearing pain in the forehead, worse in the right frontal eminence. A shoot of pain through the forehead. Burning pain in the right side of the forehead, extending to the eye, so that he could not turn it without pain. The eyes hurt on motion, as if too large for their orbits. He could not turn the eyes in all directions without pain. Violent burrowing stitch in the middle of the eye and inner canthus that does not prevent vision, but presses the upper lid downward. Intolerable pressive pain in the eye-*

balls, still more painful on turning the eyes ; on attempting to look with the eyes turned he became dizzy, so that he was obliged to turn the whole head. Pressive pain in the eyeballs. A contractive burning pain in the right eyeball. Constant sticking pain in the right eyeball also on moving it. Itching stitch in the right eyeball that returned after rubbing.

Clinical.—Spigelia, is especially applicable to severe neuralgic pains arising in a great variety of ophthalmic troubles, particularly in rheumatic and arthritic inflammations. In all cases the character and intensity of the pains furnish the chief indications for the selection of this remedy.

Ptosis, as one would be led to suppose from the symptomatology, should often require the use of Spigelia. A case, occurring in a seamstress, after inflammation, with sharp stabbing pains through the eyes and head and much hot, scalding lachrymation, was very favorably affected by its use.—T. F. A.

It is not a remedy which we would be liable to think of in inflammatory diseases of the conjunctiva or cornea, still it has been found beneficial in exceptional cases when accompanied by the characteristic sharp pains. Even in ulcers of the cornea, with considerable infiltration into the cornea around the ulcer, its employment has been followed by brilliant results, providing *shooting, radiating pains from the eyes into the head*, usually worse at night, have been present.

Excellent results have been obtained from this drug in iritis, especially in the rheumatic form, with severe pains around and deep in the eye. The following case will illustrate its action : J. M., æt. 51, had suffered from rheumatic iritis in the left eye, with excessive ciliary neuralgia, for three weeks. There was much redness, deep ciliary injection and posterior synechiæ, with violent pain from 3 A.M. for two or three hours, continuing more or less until 3 P.M. Atropine was used externally and Sulphur internally. The adhesions were torn and the pain relieved on the first night. On the second night, although the pupil was widely dilated, the pain returned more severely than ever. The pain was as if the eye were being pulled forward and backward, with numb pain through the head, which woke him at 2 A.M. and continued the remainder of the night and all the forenoon ; it seemed as if it would drive him

crazy. Each attack of pain was accompanied by a chill. No change was made in the Atropine, but Spigelia²⁰⁰ was prescribed internally. There was only a little pain at about noon the next day, none afterward, and within five days the eye was perfectly well.

The pains of glaucoma may indicate this remedy. Benefit has also been derived from its use in sclero-choroiditis accompanied by much pain.

In accommodative asthenopia, with slight retinitis and severe neuralgic headaches; also in asthenopia, with anæmia of the optic nerve and characteristic pains dependent upon too great indulgence in tea, great benefit has been obtained from Spigelia.

It is, however, in ciliary neuralgia, intermittent or not intermittent, dependent upon some observable disease or arising from some cause unknown, that the greatest power of Spig. is exercised. The pains are various in character, though usually *sharp and stabbing, like a knife sticking through the ball back into the head, or they may seem to start from one point and then radiate in different directions; are generally aggravated by motion and at night.* The following variety of pains, as described by patients, have been cured by Spigelia, in addition to those already given: Pains around and deep in the eye. Severe pain on moving the eyes, worse at night. Severe pressure extending to the orbit after sleep, or as if the eye would ulcerate. Very severe, sharp pain in and around the left eye, seems as if it would drive him crazy, wakes him at 3 A.M. and continues the remainder of the night; also has a similar attack in the latter part of the forenoon, always accompanied by fever and sweat. Sharp pains through the right eye and corresponding side of head, worse at night and relieved by warmth, accompanied by excessive sensitiveness of the eyeball to touch. Burning or sticking pains in the eye and sensation as if the eyeball were too large. Burning pains going to the bones. Sticking, boring pains extending to the bones around the eyes, especially supra-orbital and temporal regions. Eye feels too large and as if forcibly turned around in the orbit; the pain makes one shut the eye and, on opening it, seem to see a sea of fire; with the severe pain, hot tears run out of the eye and the pains are worse in the open air and at night. After long continued use of the eyes, terrible pains every morning at six in the left eye, as if the ball were too large and was forcibly pressed out of the orbit,

with violent aching, boring and severe stitches, made worse by opening and moving the eye, often extending to the forehead. The slightest touch excites the pains, which disappear about noon. Severe, boring pain deep in the eye, aggravated on moving it; parts around the eye painful to touch and sparks before the vision. Sharp sticking pains through the ball of the eye into the head on the right side, worse at night; frontal headache and frequent winking. Intolerable pain in the supra-ciliary ridge, worse on any change of weather and in the wind. Severe, pressing, jerking, sticking pains in the left eye, so hard as to cause her to cry out and lose consciousness; every few minutes they would extend to the muscles of the left upper arm.

SPONGIA.

Clinical.—The chief use which has been made of Spongia in ophthalmic therapeutics has been in Basedow's disease, as the following case will illustrate: A woman, about 40. Eyeballs staring and perceptibly protruding; stitches in the balls and burning around the eyes, with lachrymation worse from any sudden light; often the eye feels as if twisted around; there is constant flashing of different colors, mostly deep red, figures of light, etc., even when the eye is closed, especially at night. The thyroid gland is considerably hypertrophied. The palpitation of the heart is very marked, which makes her uneasy, restless and easily frightened, especially at night. Spongia in the higher potencies effected a cure.—T. F. A.

SQUILLA.

The eyes seem swimming in cold water.

Clinical.—A man, 25 years of age, had been troubled with a large phlyctenule of the conjunctiva on the outer side of the cornea, for two weeks. He complained of a sensation as of cold water in the eye whenever in a cold wind. Squilla²⁰⁰ cured the phlyctenule and relieved the above sensation within two days.—CHAS. DEADY.

STANNUM.

Pustular swelling of the left inner canthus.

Pressure in the left inner canthus as from a sty, with lachrymation. Itching in the inner canthus. Vertigo when reading, with loss of sight.

Clinical.—Ptosis from sympathetic paralysis, in which the disease returned every Tuesday, was cured by Stannum.—J. A. CAMPBELL.

Stannum, first employed by Drs. Liebold and Hunt in blennorrhoea of the lachrymal sac, has now become one of our most common remedies for this affection. It is often used with advantage, in controlling the profuse yellowish-white discharge observed in this condition. There may be a tendency to a more active form of inflammation, especially toward night, and accompanied by sharp pain in the internal canthus.

STAPHYSAGRIA.

Subjective.—Pain as if a hard substance were lying beneath the left upper lid. Pressure in the upper lid all day, worse on closing the eye. Itching on the margin of the upper lid in the open air. *Itching of the margins of the lids.* Dryness of the eyes. The eyes are dry in the morning on waking. The eyes are dry in the evening, with pressure in them.

Clinical.—The clinical application of Staphysagria has been chiefly confined to the lids. The form of blepharitis to which it is adapted is characterized by dryness of the margins of the lids, small, hard nodules on the ciliary border and destruction of the hair follicles, with much itching of the margins of the lids.

Its greatest usefulness is in tarsal tumors, in which it is quite commonly employed, as when the glands of the lids are enlarged, with redness and tensive tearing pains, especially in the evening, or more particularly if *little, hard nodules are found on the lids, resulting from styas*, also if crops of small, tarsal tumors are constantly recurring.

Syphilitic iritis, with bursting pain in the eyeball, temple and side of face, worse from evening to morning and upon using the eyes by any light, was promptly relieved by this drug.—C. A. BACON.

SULPHUR.

Objective.—An inflamed pimple above the left eyebrow. Lachrymation in the morning, followed by dryness. Lachrymation, and burning in the morning. Swelling and pain in the eyelids, with lachrymation. Redness of the eyelids and conjunctiva. Eruption of pimples on the upper lid. *Agglutinated eyes, in the morning.*

Jerking in the lids. Eyes sunken, surrounded by blue rings. *Redness of the eyes during the day; violent itching in them in the evening.* A white vesicle on the white of the eye, close to the cornea. Much matter in the eye in the morning. Purulent mucus in the eyes. Heaviness of the eyes. Dryness of the eyes.

Subjective.—*Much itching in the eyebrows and in the tip of the nose. Dryness of the inner surface of the lids. Pressure in the eyelids in the evening. Burning of the lids, which are inflamed and red and tense on motion. Burning of the eyelids externally. Sticking and burning in the outer canthi. Burning in the edges of the lids in the morning; cutting, burning pains in the borders of the eyelids and especially in the external canthi after dinner; very distressing burning in the outer canthi, and on shutting the eyes a sensation as of a foreign body between the edges of the lids toward their external commissure, in the evening. In the forenoon, some burning on the edges of the lids. Smarting, sore pain on the inner side of the lids after midnight followed by a sensation of a rubbing dryness upon the inner surfaces. Smarting pain as from dryness of the margins of the lids. Smarting of the lids; inclination to rub them; the eyes can hardly bear the light in the evening. In the morning, slight sensitiveness of the edges of the lids. Rubbing, dry sensation (like sand) in the mucous surface of the eyelids. In the morning, on awaking, feeling of sand in the eyes, with raw pain on rubbing them. In the morning, after awaking, painful, rubbing, dry feeling in the borders of the right eyelids. Itching of the eyelids, as if they would become inflamed. Itching of the lids, obliging him to rest them every moment, in the afternoon; the eyes can scarcely endure the light at all in the evening. Itching and burning of the lids, which are red and swollen in the morning. Frequent itching, burning and smarting in the canthi, making him rub them. Itching in eyelids and burning in eyes. In the morning after awaking, itching, smarting, or feeling as of fine sand in the eyes. A sensation of prickling in both eyelids, causing him to scratch and rub them. In the afternoon, itching, burning and redness of the edges of the lids. Itching on the borders of the eyelids.*

The eyeballs are painful on moving them. Pressure in the eyeballs on walking in the open air. In the evening, dull aching and feeling of weight in both eyeballs, with loss of vision, as if a thick

veil were before the eyes. Pain as from dryness of the eyeballs and a sensation as if they rubbed against the lids.

Burning in the eyes, especially toward the external canthi, at various times of day. Burning and easy fatigue of eyes when reading. Burning of the eyes, without redness. *Burning of the eyes, with great sensitiveness to daylight*. Burning and pressure in the eyes; in the morning they were agglutinated and the whole face swollen. *Burning in the eyes with redness of them*. *In the afternoon, burning, shooting beneath the lids of the left eye, as though sand had got into it*. Sensitiveness and burning in the eyes. Burning in eyes and feet. Painful smarting of the eyes. Sensation of foreign body in the eyes. Sensation as if an inflammation of the eye were about to come on; in the morning on awaking, prickling, causing him to scratch; itching and smarting in the lids. *Violent pains in the left eye, as if it were rubbed against spicule of glass and drawn in toward the pupil; he was obliged to close the eye five or six times involuntarily; this was followed by burning in the eye and flow of tears*. *Severe cutting in right eye*. Shooting in the left eye, preventing him from reading for several days; when he attempts to read he gets, immediately, violent shooting pains through the middle of the pupil deep into the eye. Biting of the eyes and lachrymation every evening. A feeling as of sand in the eyes. *Stitches as with a knife in the right eye*.

Vision.—Dimness of vision as from a fog, with the headache. Dimness of vision of both eyes, with great sensitiveness to bright daylight; great dimness of vision (on reading), at the same time a feeling of dryness (as from fine sand) between the eyelids. Dimness of vision and weakness of both eyes, with innumerable confused, dark spots floating before the eyes. Very often a feeling of heaviness and aching in the eyeballs when reading or writing. I must cover the eyes with the hand, slightly press and rub them in order to read. *Sensation of a veil before the eyes and dim vision for near and distant objects*. *Sensitiveness of the eyes to daylight*. *Intolerance of sunlight*. Obscuration of vision while reading. Objects seem more distant than they really are. *Flickering before the eyes*. *Dark points and spots before the eyes*. Black flies seem to float not far from the eyes.

Clinical.—The clinical application of Sulphur in diseases of the eye has been more varied than that of any other remedy, though it will be seen that its sphere of action is usually well marked.

In blenorrhœa of the lachrymal sac it may be of service, though it is not often indicated.

Blepharitis, particularly the chronic form, quite frequently calls for this drug, especially if occurring in children of a strumous diathesis who are irritable and cross by day and *restless and feverish by night*. The lids are swollen, red and agglutinated in the morning, or there may be numerous small, itching pustules on the margins of the lids. There may be itching, biting, burning or sensation as if sand were in the eye, though the pains are usually of a sticking character. There is generally great aversion to water, so cannot bear to have the eyes washed. It is especially useful if the blepharitis appears after the suppression of an eruption or if the child or adult is already covered with eczema.

Eczematous affections of the lids have been often controlled when Sulph. has been given according to the indications for eczema in other portions of the body.

In conjunctivitis catarrhalis, both acute and chronic, this remedy is often very useful. The degree of redness may vary greatly, be confined to one eye, or involve both. The lids may be swollen, even puffy, or remain unaffected. But the *sharp, darting pains, like pins sticking into the eye*, will furnish our chief indications (these pains are characteristic of the drug and may occur at any time of the day or night). There may also be pressing, tensive, cutting or burning pains, feeling as of sand in the eyes, tearing in the head, poor appetite and feverishness at night, with chills during the day.

Acute and chronic trachoma has been benefited by Sulphur. It is often called for as an intercurrent remedy, even if it does not complete the cure alone, especially if the pains are *sharp and sticking* in the morning and the lids are glued together so that it is with the greatest difficulty they can be opened. Water is not a favorite application and usually aggravates the trouble.

Sulphur has been employed with success in ophthalmia neonatorum, especially in chronic cases which have a great tendency to relapse.

It is, however, the remedy "par excellence" for pustular inflammation of the cornea or conjunctiva. As its sphere of action is very wide, it is adapted to a great variety of cases, especially if chronic and occurring in scrofulous children covered with eruptions (among

which the majority of these cases are found). The character of the pains may vary, though they are usually *sharp and sticking, as if a needle or splinter were sticking into the eye, or there may be a sharp, shooting pain going through the eye back into the head, from one to three A.M.,* awaking him from sleep; although besides these we have a variety of other sensations, such as smarting, itching and burning in the eyes, a feeling of pressure as from a foreign body, stinging, burning in the eye, especially from light and in the morning, burning as from lime, biting as if salt were in the eye, sensation as if there were a number of little, burning sparks on the lids which cause them to spasmodically close, painful dryness as if the lids rubbed the eyeballs, bruised pain, etc. The photophobia is generally very marked and the lachrymation profuse, though in some cases they may be almost or entirely absent. The redness varies greatly, but is usually considerable, especially at the angles. The secretions also vary both in quantity and quality, being often, however, acrid, corrosive and sometimes tenacious. Agglutination in the morning is commonly present. The lids are often swollen, burn and smart as if bathed in some acrid fluid, or there is an itching sensation, compelling the patient to rub them most of the time. The lids, as well as the surrounding integument of the head and face, are frequently covered with an eruption. All the symptoms are, as a rule, made *worse by bathing the eyes*, so that the child cannot bear to have any water touch them. Open air, especially on first going out, usually aggravates.

The value of Sulphur in the treatment of ulcers and abscesses of the cornea is hardly less than in pustular inflammation. Its usefulness is not confined to any one species of ulcer, as it has cured not only the *superficial variety*, but also the deep, sloughing form which tends toward perforation and destruction of the whole cornea. In fact it should always be thought of in ulceration or abscess of the cornea with hypopyon, especially if of an indolent type, with no photophobia nor vascularity, as it has often produced absorption of the pus and exercised a beneficial influence over the destructive process going on in the cornea. The indications which lead us to its selection are derived chiefly from the general condition of the patient, while the eye symptoms are the same as those given above for the phlyctenular form of inflammation, except that in severe

cases the pains may be more intense. There may be severe, pressing pains in the eye, besides the characteristic stitches. The other symptoms may also be proportionately increased.

Pannus, resulting from various causes and occurring in patients of a strumous diathesis, has been frequently cured under this remedy. In some instances there has been true pannus crassum, the whole of the cornea presenting the appearance of a piece of fresh, raw beef, and yet vision has been restored by the internal administration of Sulphur. It is especially useful in the so-called herpetic pannus resulting from phlyctenular inflammation.

A case of keratitis parenchymatosa in a scrofulous subject, cornea like ground glass, photophobia, lids swollen and bleeding easily, was permanently relieved by this remedy. It will often be found to promote absorption of the infiltration after the disease has been checked by other remedies.

In severe forms of inflammation of the cornea the iris not unfrequently becomes involved (kerato-iritis), though this does not by any means contra-indicate the use of Sulph., even if hypopyon be present.

It has been employed with favorable results in inflammation of the sclera, with corneal and iritic complications, as well as in uncomplicated cases. There may be, in addition to the well known objective symptoms, only a feeling of fullness and largeness of the eyeball, worse from use or exposure to light, especially gaslight, or there may be great photophobia, acrid lachrymation and severe, tearing pains in the supra-orbital and temporal regions, as well as in the eye itself, especially worse in the evening and at night (Merc.).

In iritis, both idiopathic and syphilitic (especially the former), benefit has occasionally been derived from the use of this remedy, though it is not frequently indicated. It is especially adapted to chronic cases marked somewhat by drawing pains around the eye, but chiefly by *sharp, sticking pains* in the eyes, worse at night (Spig.) and toward morning. The eyeballs may be painful on motion and the usual characteristic symptoms are present.

The hypopyon resulting from iritis or, in fact, pus found in the anterior chamber under any circumstances, will frequently disappear after the administration of a few doses of Sulphur. (Compare Hepar and Sil.)

Benefit has been derived from the use of Sulphur in inflammatory affections of the fundus. It has been successfully employed in chorio-retinitis and uncomplicated choroiditis, if accompanied by *darting pains*, and in one case in which hemeralopia was present. It is not, however, a frequently indicated remedy in any of the acute forms of intra-ocular disease, though is sometimes useful, especially as an intercurrent; it is particularly called for in chronic cases.

Retinitis caused from over-study, with much congestion of the optic nerve, outlines ill-defined and accompanied by pain around the eye and itching in the internal canthi, has been cured.—
T. F. A.

Sulphur often acts very promptly in clearing up opacities in the vitreous, resulting from choroidal exudations and old hæmorrhages.

The following case of sympathetic irritation of the right eye occurring in a young lady was speedily relieved: The left eye had been removed six months previous on account of extensive staphylo-matous bulging of the whole eye, by abscising the cornea and evacuating the contents of the globe, thus leaving only the sclera and muscles intact. She now appeared, complaining of sharp pain in the stump extending in stitches to the healthy eye, in which there was considerable irritation and photophobia, occasional obscuration of vision and commencing presbyopia. There was constant discharge from the old stump, which was excessively sensitive to touch. Sulph.²⁰⁰ relieved in a few days.

Asthenopia, both muscular and accommodative, has been occasionally benefited by Sulphur when the character of the pains has pointed to its selection. "Gaslight hurts more than sunlight," a symptom not rarely found in these cases, has been relieved.

Benefit was derived from this remedy in the following case of paresis of the external rectus muscle: A woman, æt. 40, had, for three months, been troubled with double images to the right and downward. There was no perceptible diminution in the movements of the eye and no cause for the paresis was apparent. There was some pain in the eye on looking upward; some headache and restlessness at night. Various remedies were used for two months with no avail. Under Sulph.³⁰ a cure resulted in three weeks.

The *iodide of sulphur* has occasionally been employed in ophthal-

mic diseases with marked success, especially in strumous subjects with enlarged glands.

SYPHILINUM.

Clinical.—Very marked success has attended the use of this remedy in some cases of chronic recurrent phlyctenular inflammation of the cornea. When indicated, successive crops of phlyctenules and abrasions of the epithelial layer of the cornea will be found; the photophobia will be intense and the lachrymation profuse; the redness and pain will vary, but will be usually well marked. It is indicated in delicate, scrofulous children, especially if any trace of hereditary syphilis can be discovered. Dr. St. Clair Smith cured a case of long-standing scrofulous ophthalmia with Syphilinum²⁰⁰. There was intense photophobia, profuse lachrymation at times; at others, muco-purulent discharge; ulceration of the cornea; lids swollen and drooping; scaly eruption of face around the eyes and the general scrofulous symptoms.

TABACUM.

Pains behind the eyeball.

Clinical.—The following case, consequent upon the use of tobacco, may prove interesting: The patient was amblyopic, vision $\frac{20}{100}$, refraction normal, divergence of one and a half lines behind a screen, diplopia in the distance. On leaving off tobacco for a time he improved and saw single, but within ten minutes after returning to its use the vision became dim, black spots floated before the eyes and he saw double. Stimulants only aggravated the difficulty.

(See cure of tobacco amaurosis under Nux v.)

TELLURIUM.

Clinical.—Tellurium has proved successful in conjunctivitis pustulosa, with eczema impetiginoides on the lids and much purulent discharge from the eyes; also an offensive discharge from the ear, to which the child was subject.

It is probably more often indicated in scrofulous ophthalmia than we are now led to suppose.

The offensive otorrhœa, smelling like fish-brine, is an important concomitant symptom.

TEREBINTHINA.

Clinical.—In a comparatively rare form of ciliary neuralgia, with acute conjunctivitis, Terebinth is the remedy most frequently indicated. The injection of the conjunctiva is variable, sometimes being excessive and again very moderate, amounting to hardly more than a simple hyperæmia, but at no time commensurate with the severity of the pain. The redness is usually dark, especially in the later stages, though during the height of the inflammation may be bright. There may be chemosis and even infiltration into the cellular tissue of the orbit. Deep ciliary injection, swelling of the lids, photophobia and lachrymation may be present. The pupil is contracted, but dilates regularly, though slowly, under Atropine. The tension is changeable even within a short time, though is more frequently diminished than otherwise. The eyeball is sensitive to touch. The *pain is excessive* and always present; varies in character from a dull, “grumbling,” aching, beating, sore pain to a severe, sharp, darting pain seeming as if it would almost drive the patient crazy; not only involves the eyeball, but is especially severe *over* and around the eye, extending through to occiput on corresponding side of the head, often following the course of the supra-orbital nerve; is always *worse at night*, and is frequently accompanied by severe paroxysms, particularly in the early morning hours (1 to 3 A.M.). The corresponding side of the face is flushed. General disturbances will accompany the above, especially *scanty and high-colored urine, with pain in the back*, which is always present when Terebinth is indicated. (Compare Amyl nitrite.)

A man, about 40 years of age, had been suffering from episcleritis in the left eye for over three weeks. The eye was very red, especially at inner side of the cornea, where there was a hard, bluish-red elevation. *The pain in the eye and corresponding side of the head was intense day and night.* The pupil reacted well. The urine was very dark. Atropine and various remedies of both schools had failed to relieve. Terebinth¹ relieved the pain in a few hours and a complete cure resulted in less than a week.

This remedy, first employed in iritis by Dr. Liebold, has proved a valuable remedy, especially in rheumatic iritis. *The pains will be intense* and the characteristic urinary symptoms—frequent desire, pressure and pain in the kidneys, burning in the urethra and dark

urine—will be present. Also called for, if there is a suppression of habitual perspiration of the feet.

The following interesting case shows that it may be useful in amblyopia potatorum: "Mr. S., æt. 37 years; first seen August 17, 1876. He had been intemperate for ten years or more. Eight weeks before consulting me his sight began to grow dim. There was an almost constant, dull, aching pain in the region of the kidneys; urine dark colored and loaded with acid phosphates, sp. grav. 1,028. On examination I found vision $\frac{5}{40}$ in both eyes; fundus normal in appearance. R. Nux. vom.^s; continued it for two weeks with no benefit; then Terebinth² was given, a dose three times a day. Under this remedy, which was continued four weeks, all pain in the back ceased, the urine became normal in appearance and vision was restored, being $\frac{20}{20}$. Although the patient has only partially given up drinking, there has been no return of the difficulty.—W. P. FOWLER.

THUJA.

Objective.—Agglutination of the lids at night. Pimple on the margin of lower lid. Stye on the right eye. The white of the eye is very much inflamed and red. Weak eyes, pressure as from fine sand in them.

Subjective.—Tearing pain in the left eyebrow, disappearing after touch. Feeling as if the eyelids were swollen and a foreign body were in the eye. Burning and stinging in the edges of the eyelids in the evening. Feeling of dryness in the eyes. Feeling of sand in the eyes. Burning and stinging in both eyes and eyelids, with injection of the cornea. Pressure in the eyes. A painful stitch through the centre of the left eye, commencing in the centre of the brain.

Vision.—Dimness of vision like a mist before the eyes and pressure in them as if they would be pressed out of the head or as if they were swollen. Dimness of vision in the open air, like a veil, for near and distant objects, with confusion of the head for half an hour. The vision seems dim, with a feeling as if something were before the eyes. Muscæ volitantes. Great flickering before the eyes. Seeing of a luminous disk shining like a firefly.

Clinical.—No remedy is more frequently indicated in *tarsal tumors*

than Thuja, especially for verruæ and tumors that resemble small condylomata, though it is also useful in other varieties, not only in preventing their return after removal by the knife, but in promoting their absorption without the employment of instrumental means. This can sometimes be done by simply using the drug internally, though it usually seems to act more rapidly if employed in the tincture externally at the same time.

"In two cases of what appeared undoubted epithelioma of the left lower eyelid, one of eight months' the other of three years' standing, there was complete recovery under Thuja locally and internally."—C. M. THOMAS.

Conjunctivitis trachomatosa, in which the granulations are large, like warts or blisters, with burning in the lids and eyes, worse at night, photophobia by day and suffusion of the eye with tears, would lead us to give Thuja.

In chronic cases of large phlyctenules of the conjunctiva, which are very slow in progress, unyielding to treatment and which decidedly involve the sub-conjunctival tissue, Thuja will often be found to be the remedy.

It has occasionally been of service in inflammations of the cornea, especially in ulcerations of a syphilitic origin, even if hypopyon is present.

The action of Thuja upon the sclera is very marked indeed; probably more so than any other drug. It has been employed with excellent success in *episcleritis*, *scleritis*, *sclero-choroiditis ant.* and commencing scleral staphyloma, even when no characteristic indications were present. There will, however, usually be sensitiveness of the eyeball to touch and aching pain in and over the eye, with some heat.

In some cases warmth relieves.

For syphilitic iritis, with *gummata on the iris*, it is a grand remedy. The pains are usually severe, sharp and sticking in the eye, worse at night, with *much heat* above and around the eye, or there may be a pain in the left frontal eminence as if a nail were being driven in; in some cases the pain is described as a dull aching in the eye and sometimes seems to be relieved in the open air.

The following symptom of vision was relieved by Thuja: "Flames of light before the eyes, mostly yellow."—T. F. A.

VERATRUM VIRIDE.

Subjective.—Aching in the upper part of the right orbit. Full, pressing, heavy feeling in eyes, with slight headache. Severe shooting, suddenly-stopping pain in left eye. Pupils dilated.

Vision.—Dimness of sight. Cannot walk; if I attempt it I am very faint and completely blind. Photophobia and vertigo, relieved by closing eyes and resting head. If I assumed the erect position for even a minute, dimness of sight and partial syncope supervened. Unsteady vision.

Clinical.—In erysipelatous inflammation of the lids, face and head, especially if of traumatic origin, *Veratrum viride*, as recommended by Dr. Liebold, has proved of great value. It is usually used locally as well as internally.

From the experience of Dr. D. J. McGuire it seems that *Veratrum viride* must be an important remedy in a certain class of ocular diseases, and, as the following case is of such marked interest in illustrating the sphere of action of this remedy, it is given in full as reported to me by the doctor:

“April 14, 1879. Mrs. —, æt. 32, never had any previous eye trouble. Vision good for all distances. Has always suffered from dysmenorrhœa, with severe cephalalgia just before or after menstrual period and for the last six years occasional epileptiform convulsions, all of which symptoms were interrupted during her only pregnancy and the subsequent period of lactation. The child died when nine months old, and with the re-establishment of the menstrual function occurred the dysmenorrhœa, head pains and convulsions, the latter being more frequent than ever. The eye history as revealed at first visit was as follows: Eight weeks ago sudden, complete loss of qualitative vision of right eye, with contracted pupil; vision of left eye being only slightly disturbed. There was no pain or uneasiness until two days after the loss of vision was observed, when she had a severe attack of cephalalgia lasting one week, with unconsciousness, fainting and vomiting; objects appearing like balls of fire before the eyes. Had a subsequent similar attack three weeks later. Since which time has had aching pains in one or the other eye constantly, increased in the evening to sharp pains; also the appearance of stars, flashes of fire, etc. L. V. $\frac{1}{3}$. R. V. perception of light. The ophthalmoscope revealed a circumscribed patch of choroiditis

(with beginning atrophy) about two and one half lines in diameter, situated some three lines externally from macula, with a strip of red, elevated tissue extending up to and evidently involving the macula (thus causing the sudden loss of vision). The patient came under my care at menstrual period, at close of which she had the usual attack of head pain beginning at orbital regions and gradually extending backward to base and cord. After a few hours there was marked opisthotonos and the surface of limbs and body became highly hyperæsthetic, consecutively from above downward, following the course of the pain. A few hours later these parts became markedly anæsthetic. The muscles also showed decided atrophic changes, becoming soft and attenuated, particularly marked in those of the extremities; so much so, in fact, that it was more than three weeks before the patient could stand alone. Bell., Cimicif., Arn., Nux vom., were of no avail. The next monthly period presented the usual phases. Six hours after the headache began I saw her; the opisthotonos was already quite marked and considerable hyperæsthesia existed. *R.* Veratrum viride, five drops in a glass half full of water; dessert-spoonful every half hour until an impression was made. The patient remarked a sense of relief before the second dose was given, and five hours later, when I called, the patient was lying quietly and almost free from pain. There was, however, well marked anæsthesia, less than in previous attacks, followed by wasting in muscles and inability to walk unaided for the next ten days. I may here add that the pulse at my first visit during this attack — and I believe it to have been a characteristic one for that stage — was feeble, that is about sixty per minute in frequency, soft and compressible, but under the Verat. rapidly improved in character. The next attack followed the next menstruation, but the remedy was given at the beginning, with the effect of aborting it entirely. Subsequent attacks were controlled by the early administration of the remedy. The medicine was also given for from one to three weeks following these periods, in attenuations ranging from the 1st dec. to the 200th. August 14th: *R.* V. $\frac{15}{80}$, *L.* V. $\frac{15}{15}$. Reads Snellen No. 4. *R.* E. p. 7'', r. 13''. *L.* E. p. 7'', r. 18''. The vision has, of course, reached this point by gradual stages, which I have not thought necessary to follow here. The patient now returned to her home, several hundred miles distant, but reports that she has had

no return of the headaches or convulsions and no longer suffers from dysmenorrhœa. The vision remained good and probably improved over the above test.

Remarks.—The known influence (physiological) which this remedy exerts over the vaso-motor functions and the clinical results obtained in pelvic cellulitis¹ first led me to consider it in this class of cases believing that the eye trouble was the result of sympathetic influence. In addition it will be found that the remedy corresponded very closely symptomatically with this case.

The doctor also says: "My experience with the remedy has been quite extended, and while I have found its principal sphere of usefulness in diseases of the fundus oculi to be confined to females, it has not been entirely so. In one case of white atrophy of the disc, in a gentleman who had gone through a severe business excitement, the head pains were always promptly relieved by it. In all cases, in which the fundus disease, whether of the choroid, retina or disc, could be traced to vaso-motor influence, the results have been most satisfactory."

ZINCUM.

Objective.—Agglutination of the inner canthus in the morning, with a pressing sore feeling. Inflammation and redness of the conjunctiva of the right eye; suppuration in the inner canthus; the eyes are most painful in the evening and night, as from sand, with frequent lachrymation; even the upper lid, toward the inner canthus, is red and swollen. During the menses inflammation of the eyes.

Subjective.—Burning of the left lid, as if too dry. *Feeling of soreness in the inner canthi.* Soreness of the outer canthus, with biting pain. Pains at the root of the nose as if pressed into the head. Pressure on the margin of the left lower lid near the inner canthus. Painful pressure in the right inner canthus, with redness of the conjunctiva. Biting in the right inner canthus, relieved by rubbing. *Itching and sticking pain in the inner angles of the eyes,* with cloudiness of sight. Feeling of dryness in the eyeball. Constant burning

¹ A physical examination made by Dr. Phil. Porter showed the uterus to be enlarged in all diameters, canal lengthened and walls thickened, os being thick and indurated.

in the eyes with feeling of dryness and pressure in them. Hot, scalding tears. Constant pressure in the left eye in the evening. Burning and biting, with photophobia of the eye, which waters, especially in the evening, and is agglutinated in the morning. Tickling in the right eye, as from dust, frequently. Sore, painful biting in the eyes towards evening, especially in the right eye. Violent itching of the left eye.

Vision.—Dimness of vision. A good deal of photophobia. Green rings before the eyes.

Clinical.—The indications for Zinc. in tarsal tumors are well illustrated in the following case: "A man, æt. 48, complained of soreness and almost constant itching in the inner canthus of the right eye; also of itching in other portions of the body—back, hands and arms; there was an aggravation of all symptoms toward night. The right lower lid was literally filled with small tumors and in the upper lid several were making their appearance. The caruncle was swollen and bright red and the ocular conjunctiva congested toward the inner canthus. The margin of the lower lid was thickened, indurated, bright red and somewhat everted. Patient stated that the difficulty had been coming on for about six months. *Ry. Zincum*²⁰⁰. In one week all soreness and itching had disappeared and at the end of two months the case was discharged cured, the tumors having been completely reabsorbed."—W. P. FOWLER.

It is not infrequently called for in inflammation of the conjunctiva, especially if confined to the canthi—more particularly the internal,—and accompanied by soreness, itching and sticking pains at the angles of the eye, with agglutination. It has also removed persistent redness of the conjunctiva remaining after pustular keratitis, without any discharge, worse toward evening and in the cool air.

For pterygium it is a valuable remedy, as several well marked cases have been cured. In one case, reported by Dr. Carroll Dunham, the pterygium covered one half of the pupil and was growing rapidly; there was much conjunctival injection, lachrymation in the evening, discharge and photophobia, especially by artificial light, pricking pain and soreness, worse in the inner angle and in the evening, but particularly marked was a sensation of *great pressure across the root of the nose* and supra-orbital region. Zincum cured.

The *sulphate of zinc* has sometimes been employed in place of the

metal. "A case of dacryo-cysto-bleñnorrhœa; discharge profuse, muco-purulent, integument adjoining inner canthus red and inflamed; was entirely relieved by Zincum sulph.^s."—A. WANSTALL.

The sulphate of zinc may occasionally be used with advantage locally in acute conjunctivitis. (See Conjunctivitis, Part I.).

DESCRIPTION OF CHROMO-LITHOGRAPHS.

FIG. 1.—NORMAL FUNDUS OCULI.—In brunettes the fundus would be somewhat more deeply pigmented, while in blondes it would be less so and the choroidal vessels would be seen.

FIG. 2.—PHYSIOLOGICAL CUPPING OF THE OPTIC DISC.—A central funnel-shaped cup. See page 362.

FIG. 3.—POSTERIOR STAPHYLOMA.—Showing a white, irregularly shaped crescent slightly fringed with pigment and due to a low form of choroiditis.

FIG. 4.—CHOROIDITIS DISSEMINATA SIMPLEX.—This shows the atrophic stage of this disease where there are, white spots, more or less circular in shape, bordered by pigment and due to an atrophy of the choroid, together with some pigment spots, and are especially found at the periphery of the fundus. In the early stages the spots are of a yellowish-red color with no pigment.

FIG. 5.—RETINITIS PIGMENTOSA.—In this will be seen at the periphery of the fundus a peculiar arrangement of the pigment granules like bone corpuscles. The retinal arteries are contracted and the disc slightly atrophic.

FIG. 6.—RETINITIS ALBUMINURICA.—This illustration gives the stellate appearance at the macula, the mound-like infiltration around the disc and numerous hæmorrhages.

FIG. 7.—RETINITIS HÆMORRHAGICA.—Showing large, elongated hæmorrhages into the nerve-fibre layer of the retina.

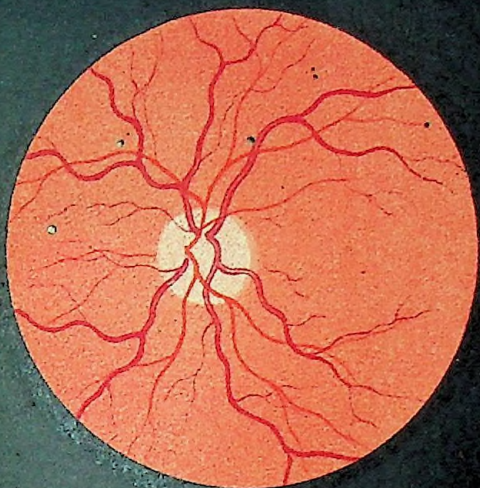
FIG. 8.—DETACHMENT OF THE RETINA.—In this will be seen the grayish-green appearance due to the separation of the retina. The detached retina is thrown up into folds and the retinal vessels are seen to bend down into these folds. There is a trembling, wavy motion to the detached portion.

FIG. 9.—NEURO-RETINITIS with hæmorrhages. The outlines of the disc are lost. The retinal vessels are in places covered by the infiltration, the arteries small and the veins large and tortuous.

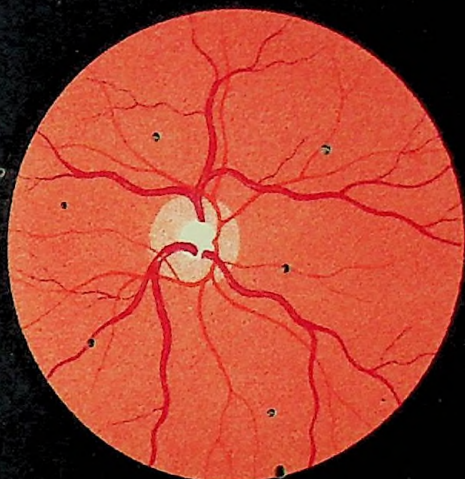FIG. 10.—OPAQUE OPTIC NERVE-FIBRES.—A physiological continuation of the optic-nerve sheath into the retina, and is seen as a white, flame-shaped appearance extending off into the retina from the optic nerve. The retinal vessels are covered in places.

FIG. 11.—ATROPHY OF THE OPTIC NERVE.—The disc appears white, and the retinal vessels greatly diminished in size, especially the arteries.

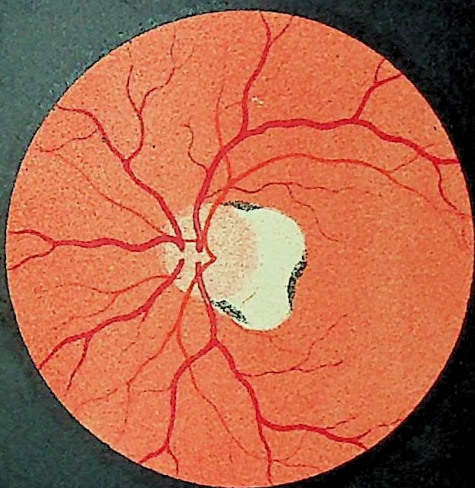
FIG. 12.—GLAUCOMA.—The disc appears slightly whiter than normal. The retinal vessels are pushed to one side of the disc and are seen to bend and disappear from view as they pass on to the disc. The retinal veins are somewhat engorged and tortuous.



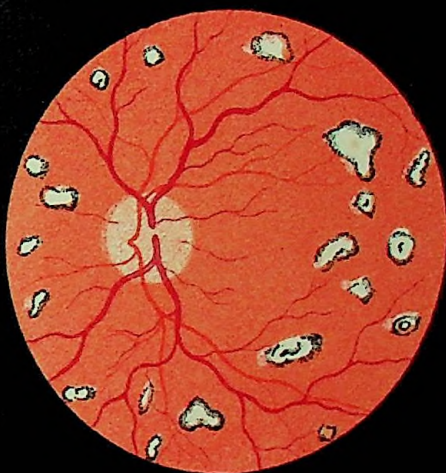1



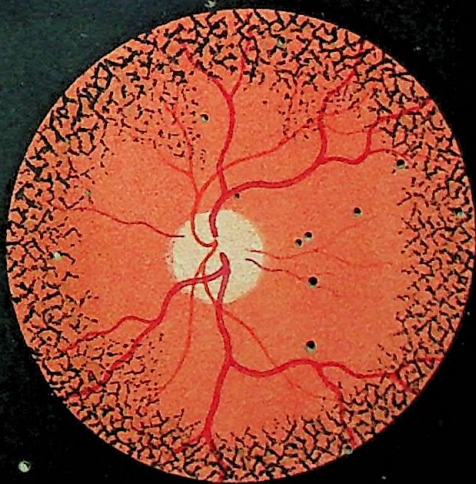
2



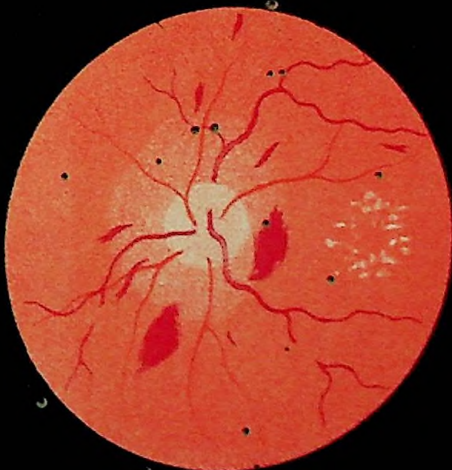
3



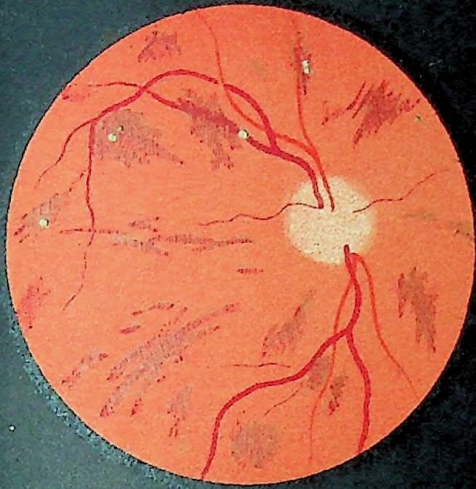
4



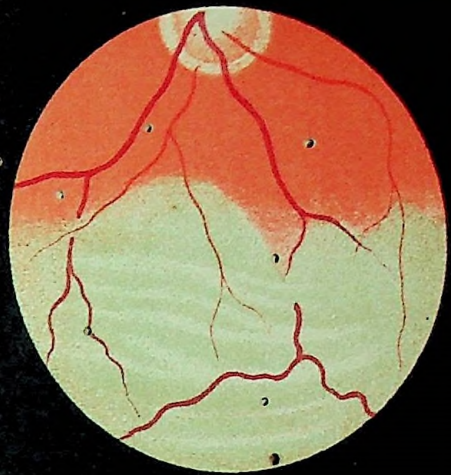
5



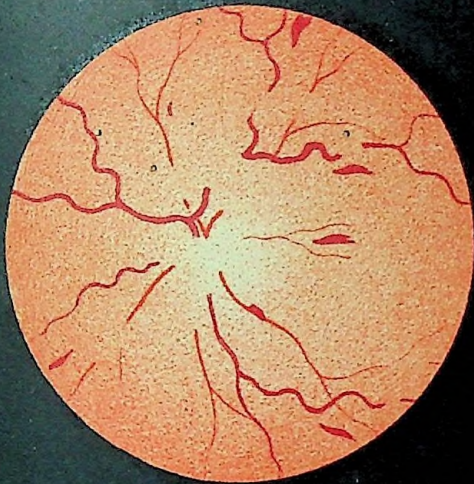
6



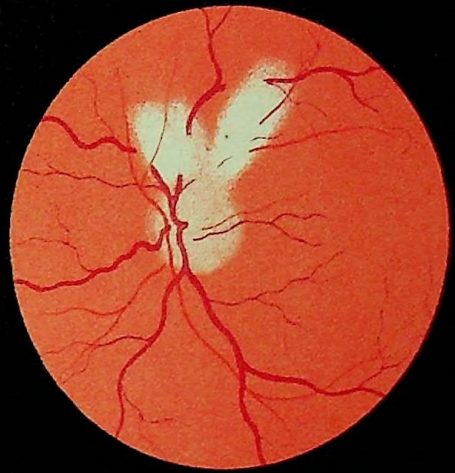
7



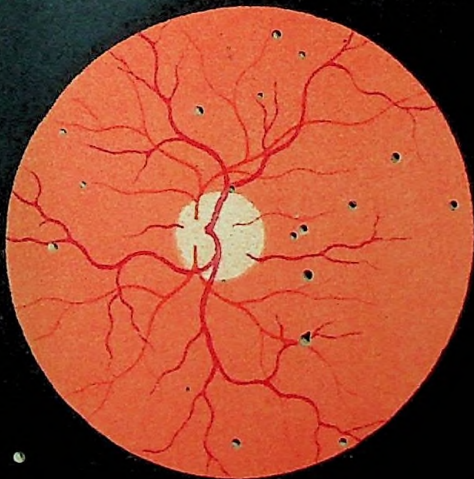
8



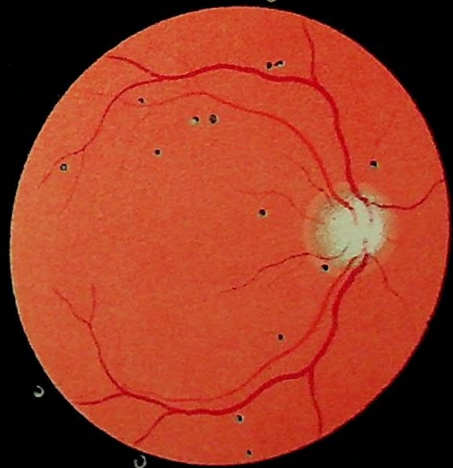9



10



11



12

BIBLIOGRAPHY.

- Alt: A Treatise on Ophthalmology. St. Louis. 1884.
Alt: Lectures on the Human Eye. New York. 1880.
Angell: Diseases of the Eye. Boston. 1891.
Annual of the Universal Medical Sciences. Philadelphia. 1888 to 1891 inclusive.
Arlt: Clinical Studies on Diseases of the Eye. Am. Ed. Philadelphia. 1885.
Berry: Diseases of the Eye. Philadelphia. 1889.
Buffum: Diseases of the Eye. Chicago. 1884.
De Wecker: Ocular Therapeutics. London. 1879.
De Schweinitz: Diseases of the Eye. Philadelphia. 1892.
Donders: Accommodation and Refraction of the Eye. London. 1864.
Gowers: Medical Ophthalmoscopy. Philadelphia. 1890.
Graefe and Saemisch: Handbuch der gesammten Augenheilkunde. 7 vols. Leipzig. 1880.
Jeffries: Color Blindness. Boston. 1880.
Juler: Ophthalmic Science and Practice. London. 1884.
Knapp: A Treatise on Intraocular Tumors. New York. 1869.
Landolt: Refraction and Accommodation of the Eye. Edinburgh. 1886.
Loring: Text-book Ophthalmoscopy. Parts 1 and 2. New York. 1886 and 1891.
Mackenzie: Diseases of the Eye. Philadelphia. 1855.
Macnamara: A Manual of the Diseases of the Eye. Philadelphia. 1876.
Metz: Anatomy and Histology of the Eye. Philadelphia. 1868.
Meyer: Diseases of the Eye. Am. Ed. Philadelphia. 1887.
Nettleship: Diseases of the Eye. Fourth Am. Ed. Philadelphia. 1890.
Noyes: Diseases of the Eye. New York. 1890.
Priestley Smith: On the Pathology and Treatment of Glaucoma. London. 1891.
Ranney: Lectures on Nervous Diseases. Philadelphia. 1889.
Schmidt-Rimpler: Ophthalmology and Ophthalmoscopy. Am. Ed. New York. 1889.
Soelberg-Wells: Diseases of the Eye. Fourth Am. Ed. Philadelphia. 1883.
Stellwag: Treatise on Diseases of the Eye. Fourth Am. Ed. New York. 1873.
Stevens: Functional Nervous Diseases. New York. 1887.
Swanzy: Handbook of Diseases of the Eye. London. 1884.
Wolfe: Diseases and Injuries of the Eye. Philadelphia. 1882.
American Ophthalmological Monographs. Cincinnati.
Annales de la Société Médico-Chirurgicales. De Liège.
Beiträge zur Pathologie der Auges. Eduard Jaeger. Wien. 1870.
Deutschmann: Ophthalmia Ueber die Migratoria. 1889.
Lucanus: Ulcus Corneæ Serpens. Inaug. Dissert. Marburg. 1832.

- Ophthalmic Hospital Reports. London.
- Ophthalmoscopischer Atlas. Dr. Hugo Magnus. Leipzig. 1872.
- Peltzer: Die Ophthalmia Militaris sive granulosa. Berlin. 1870.
- Schweigger: Vorlesungen ueber den Gebrauch des Augenspiegels. Berlin. 1864.
- Société d'Ophthalmologie. Paris.
- Transactions American Institute of Homœopathy.
- Transactions American Ophthalmological Society.
- Transactions Homœopathiq Medical Society of the State of New York.
- Transactions of the Fifth International Medical Congress. Philadelphia. 1877.
- Transactions of the Ophthalmological Society of the United Kingdom. London.
- Wilbrand: Hemianopsia. Berlin. 1881.
- Albrecht von Graefe's Archiv für Ophthalmologie. Berlin.
- American Journal of Medical Sciences. Philadelphia.
- American Journal of Ophthalmology. St. Louis.
- Anales d' Oculistique. Paris.
- Annali di Ottalmologia. Pavia. Italy.
- Annals of Ophthalmology and Otology. Kansas City.
- Archiv für Augenheilkunde. Wiesbaden.
- Archives of Ophthalmology. New York.
- Berliner klinische Wochenschrift. Berlin.
- British Medical Journal.
- California Homœopath. San Francisco.
- Centralblatt für praktische Augenheilkunde. Hirschberg. Leipzig.
- Hahnemannian Monthly. Philadelphia.
- Homœopathic Review London.
- Jahresbericht über die Leistungen und Fortschritte im Gebiete der Ophthalmologie. Tübingen.
- Journal of Nervous and Mental Disease. New York.
- Journal of Ophthalmology, Otology and Laryngology. New York.
- Klinische Monatsblätter für Augenheilkunde. Zehender. Stuttgart.
- Medical Advance. Chicago.
- Medical Analectic. New York
- Medical Era. Chicago.
- Medical Record. New York.
- Mittheilungen aus der Ophthalmiatischen Klinik in Tübingen.
- New England Medical Gazette. Boston.
- New York Medical Journal. New York.
- North American Journal of Homœopathy. New York.
- Ophthalmic Review. London.
- Recueil d' Ophthalmologie. Paris.
- Revue Generale d' Ophthalmologie. Paris, 1890.
- St. Petersburg Medicinische Wochenschrift.
- Therapeutische Monatshefte. Berlin.

LIST OF ILLUSTRATIONS.

FIG.	PAGE
1. Section through Upper Eyelid,	13
2. Wecker's Operation for Ptosis,	31
3. Wecker's Operation (completed),	31
4. Epilating Forceps,	32
5. Arlt's Operation for Trichiasis,	33
6. Knapp Ectropium Forceps,	34
7. Wharton Jones' Operation for Ectropium,	35
8. Wharton Jones' Operation (completed),	35
9. Dieffenbach's Operation for Ectropium,	36
10. Dieffenbach's Operation (completed),	36
11. Symblepharon,	37
12. Dissections of the Lachrymal Apparatus,	43
13. Agnew's Canaliculus Knife,	45
14. Stillings' Knife for Lachrymal Passage,	47
15. Set Bowman's Probes,	47
16. Agnew's Lachrymal Syringe,	48
17. Axes of Ocular Muscles,	63
18. Strabismometer,	73
19. Eye Speculum,	77
20. Fixation Forceps,	77
21. Strabismus Hooks,	77
22. Blunt-pointed Curved Strabismus Scissors,	77
23. Blunt-pointed Straight Scissors,	79
24. De Wecker's Double Strabismus Hook,	79
25. Operation for Advancement of Internal Rectus,	80
26. Stevens Phorometer;	84
27. Everted Granular Lids,	117
28. Johnson's Grattage Knife,	121
29. Knapp's Roller Forceps,	121
30. Vertical Section Through Anterior Part of the Globe,	153
31. Malarial Keratitis,	168
32. Diagrammatic Representation of the Ocular Vessels,	191
33. Angular and Straight Keratomes,	210
34. Curved and Straight Iris Forceps,	210
35. Curved Iris Scissors,	211
36. Iridectomy—The Incision,	212
37. Iridectomy—Cutting the Iris,	212

FIG.	PAGE
38. A Section Through the Ciliary Region,	214
39. Choroido-Retinitis,	238
40. Diagram Showing Minute Anatomical Structure of Retina,	257
41. Scheme of the Central Visual Apparatus,	289 ^f
42. Diagram illustrating the visual path and its relation to the visual field,	315
43. Bowman's Stop Needle,	340
44. Knapp's Scalpel Needle,	340
45. The Needle Operation,	340
46. Graefe's Linear Knife,	343
47. Noyes' Linear Knife,	343
48. Knapp's Cystotome,	343
49. Hard Rubber Lens Spoon,	343
50. Fenestrated Lens Spoon,	343
51. Cataract Extraction—The Incision,	344
52. Cataract Extraction—The Removal of the Lens,	345
53. Section Through the Ciliary Region,	356

CHROMO-LITHOGRAPHS.

1. Normal Fundus Oculi.
2. Physiological Cupping of the Optic disc.
3. Posterior Staphyloma.
4. Choroiditis Disseminata Simplex
5. Retinitis Pigmentosa.
6. Retinitis Albuminurica.
7. Retinitis Hæmorrhagica.
8. Detachment of the Retina.
9. Neuro-Retinitis.
10. Opaque Optic Nerve Fibres.
11. Atrophy of the Optic Nerve.
12. Glaucoma.

INDEX.

- Abscess of the lids, 19
 Abscessus corneæ, 169
 Causes, 170
 Course, 169
 Pathology, 169
 Prognosis, 170
 Symptoms, 169
 Treatment, 170
 Accommodation, paralysis of the, 218
 Acetic acid, 377
 Aconite, 377
 Acute phlegmonous inflammation of the lids, 19
 Agaricus, 380
 Albinism, 250
 Allium cepa, 381
 Alumen exsiccatum, 382
 Alumina, 382
 Amaurosis, 308
 Amblyopia, 308
 Congenital, 308
 From lightning, 309
 From loss of blood, 309
 Hysterical, 310
 Pretended, 310
 Toxic, 309
 Traumatic, 309
 Ammonium carbonicum, 383
 Amotia retinae, 276
 Amyloid degeneration of the conjunctiva, 136
 Treatment, 137
 Amyl nitrite, 384
 Anæmia of the retina, 280
 Anchyloblepharon, 37
 Treatment, 38
 Aniridia, 209
 Antimonium crudum, 385
 Aphakia, 351
 Apis mel., 385
 Argentum met., 388
 Argentum nit., 388
 Arnica, 391
 Arsenicum, 392
 Artificial eyes, 180
 Arum tryphyllum, 396
 Asafoetida, 396
 Asarum, 396
 Asthenic ulcer, 167
 Atrophia nervus opticus, 300
 Consecutive, 300
 Causes, 303
 Primary, 300
 Secondary, 300
 Course, 303
 Diagnosis, 303
 Pathology, 300
 Prognosis, 304
 Treatment, 304
 Atropine, 396
 Aurum, 398
 Badiago, 402
 Baryta carb., 402
 Baryta iodata, 402
 Belladonna, 403
 Blepharitis acuta, 19
 Treatment, 19
 Blepharitis ciliaris, 20
 Catarrh of the lachrymal sac, 21
 Causes, 20
 Cleanliness, 21
 Course, 20
 External applications, 21
 Fungous, 20
 Phtheiriasis ciliarum, 20
 Scales or crusts, 21
 Stricture of the duct, 21
 Symptoms, 20
 Treatment, 20
 Blepharitis marginalis, 20
 Blepharo-adenitis, 20
 Blepharophimosis, 32
 Blepharospasmus, 31
 Clonic, 31
 Tonic, 31
 Treatment, 31
 Bromium, 407
 Bryonia, 407
 Burns, 42
 Cactus grand., 409
 Calcarea carb., 409
 Calcarea hypophosph., 412
 Calcarea iodata, 412
 Calcarea phos., 413

- Calcarea pic., 413
 Calendula, 413
 Cannabis sativa, 414
 Cantharis, 415
 Carbo vegetabilis, 416
 Carbolic acid, 416
 Caries and necrosis, 55
 Treatment, 55
 Cataract, 325
 Accidents, 347
 After treatment, 346
 Causes, 328
 Complete congenital, 330
 Course, 327
 Extraction, 342
 Extraction with iridectomy, 343
 Extraction without iridectomy, 349
 Intraocular hæmorrhage, 348
 Iritis, 348
 Pathology, 325
 Suppuration of the cornea, 348
 Symptoms, 326
 Varieties of, 329
 Cataracta capsularis, 333
 Diagnosis, 333
 Prognosis, 335
 Treatment, 336
 Cataracta lamellaris, 330
 Treatment, 331
 Cataracta polaris anterior, 331
 Polaris posticum, 331
 Pyramidalis, 331
 Secundaria, 332
 Traumatica, 332
 Zonularis, 330
 Causticum, 417
 Ceanothus americanus, 419
 Cedron, 419
 Cellulitis orbitæ, 52
 Phlegmonous cellulitis, 53
 Causes, 53
 Prognosis, 53
 Symptoms, 53
 Treatment, 53
 Central amblyopia, 297
 Chalazion, 38
 Excision, 39
 Treatment, 39
 Chamomilla, 420
 Chancre of the lids, 41
 Chelidonium majus, 421
 Chimaphila umbellata, 421
 China, 422
 Chininum muriaticum, 422
 Chininum sulph., 422
 Choked disc, 293
 Choroid, 231
 Anatomy, 231
 Choroiditis, 232
 Areolaris, 236
 Choroiditis (*Continued.*)
 Circumscripta, 236
 Metastatica, 242
 Syphilitica, 237
 Choroiditis disseminata simplex, 234
 Pathology, 234
 Symptoms, 234
 Choroiditis serosa, 233
 Pathology, 233
 Symptoms, 233
 Treatment, 234
 Choroiditis suppurativa, 244
 Causes, 244
 Course, 244
 Symptoms, 244
 Treatment, 245
 Choroido retinitis centralis, 236
 Choroido retinitis syphilitica, 237
 Causes, 239
 Course, 239
 Symptoms, 237
 Treatment, 239
 Chloralum, 423
 Chrysophanic acid, 423
 Cienta virosa, 423
 Ciliary body, 214
 Anatomy, 214
 Processes, 214
 Muscle, 215
 Ciliary region, injuries implicating the,
 218
 Cimicifuga, 424
 Cina, 425
 Cinnabaris, 425
 Clear ulcer, 167
 Clematis, 426
 Colocynthis, 427
 Coloboma iridis, 208
 Coloboma of the choroid, 255
 Coloboma of the sheath, 291
 Color blindness, 312
 Commotio retinæ, 285
 Complete paralysis of the third nerve, 68
 Treatment, 68
 Comœcladia, 427
 Conium maculatum, 427
 Conjunctiva, amyloid degeneration of, 136
 Conjunctiva, 97
 Anatomy, 97
 Conjunctivitis,
 Herpetic, 126
 Pustular, 126
 Scrofulous, 126
 Strumous, 126
 Conjunctivitis catarrhalis, 98
 Causes, 98
 Course, 98
 Diagnosis, 98
 Symptoms, 98
 Treatment, 99

- Conjunctivitis crouposa, 114
 Treatment, 114
 Conjunctivitis diphtheritica, 112
 Causes, 113
 Pathology, 112
 Prognosis, 113
 Symptoms, 112
 Treatment, 113
 Conjunctivitis follicularis, 116
 Causes, 116
 Pathology, 116
 Symptoms, 116
 Treatment, 116
 Conjunctivitis gonorrhœica, 104
 Causes, 106
 Pathology, 105
 Prognosis, 106
 Symptoms, 105
 Conjunctivitis phlyctenularis, 126
 Causes, 126
 Course, 126
 Pathology, 126
 Symptoms, 126
 Treatment, 127
 Conjunctivitis purulenta, 104
 Treatment, 107
 Conjunctivitis trachomatosa, 117
 Causes, 118
 Complications, 118
 Course, 118
 Pannus, 118
 Pathology, 117
 Prognosis, 119
 Xerosis, 118
 Conjunctivitis vernalis, 136
 Treatment, 136
 Contusions, 41
 Treatment, 41
 Cornea, 146
 Anatomy, 146
 Anterior epithelial layer, 146
 Bowman's membrane, 146
 Cement, 146
 Canals, 146
 Descemet's membrane, 147
 Endothelial layer, 147
 Fascicula of fibres, 146
 Fibrillæ, 146
 Fixed cells, 147
 Migratory cells, 147
 Parenchyma, 146
 Pigment cells, 147
 Cornea conica, 181
 Crocus sativus, 329
 Crotalus horridus, 430
 Croton tiglium, 431
 Crystalline lens, 324
 Anatomy, 324
 Zonule of Zinn, 325
 Cundurango, 431
 Cuprum aceticum, 431
 Cuprum aluminatum, 432
 Cuprum sulph., 432
 Cyclitis, 215
 Cyclitis serosa, 217
 Causes, 217
 Pathology, 216
 Symptoms, 216
 Cyclitis purulenta, 217
 Causes, 217
 Prognosis, 217
 Treatment, 217
 Cysts of the iris, 205
 Epidermoid, 205
 Serous, 205
 Cysticercus in the vitreous, 328
 Dacryoadenitis, 44
 Acute, 44
 Chronic, 44
 Treatment, 44
 Dacryocystitis phlegmonosa, 49
 Cause, 50
 Course, 50
 Symptoms, 49
 Treatment, 50
 Dermoid cyst, 38
 Descemetitis, 175
 Causes, 176
 Diagnosis, 176
 Differential diagnosis, 176
 Prognosis, 176
 Symptoms, 175
 Treatment, 176
 Detachment of the choroid, 253
 Detachment of the retina, 276
 Causes, 278
 Course, 278
 Diagnosis, 279
 Pathology, 276
 Prognosis, 279
 Symptoms, 277
 Treatment, 279
 Detachment of the vitreous, 323
 Digitalis, 432
 Dislocation of the lens, 352
 Distichiasis, 32
 Arl's operation, 32
 Electrolysis, 32
 Treatment, 32
 Duboisia, 433
 Eechymosis conjunctiva, 140
 Ectopia lentis, 352
 Ectropium, 34
 Cicatricial, 35
 Conjunctival, 35
 Dieffenbach's operation, 36
 Wharton Jones' operation, 36
 Treatment, 35

- Eczema corneæ, 148
 Electricity and galvanism, 435
 Embolla arteria centralis retinae, 281
 Causes, 283
 Embolism, 282
 Prognosis, 283
 Symptoms, 281
 Thrombosis, 282
 Thrombosis of the central vein, 282
 Treatment, 283
 Empyema of the frontal sinus, 56
 Treatment, 57
 Encéphaloid of the retina, 285
 Entropium, 33
 Cicatricial, 33
 Green's operation, 34
 Spasmodic, 33
 Streatfeild's operation, 34
 Treatment, 33
 Enucleation, 180
 Epicanthus, 38
 Operation, 38
 Episcleritis, 185
 Epithelioma of the lids, 40
 Eserine, 439
 Esophoria, 87
 Symptoms, 88
 Eupatorium perf., 440
 Euphrasia, 440
 Excision of the retro-tarsal fold, 122
 Exenteration, 180
 Exophoria, 89
 Symptoms, 89
 Exophthalmic goitre, 58
 Eyelids, 17
 Anatomy, 17
 Canaliculi, 17
 Canthi, 17
 Cilia, 19
 Conjunctiva, 18
 Fornix, 19
 Inner canthus, 17
 Integument, 17
 Levator palpebrarum superioris, 18
 Outer canthus, 17
 Orbicularis palpebrarum, 17
 Punctura lachrymale, 17
 Tarsi, 18

 Ferrum, 443
 Ferrum phos., 443
 Fluoric acid, 443
 Fistula lachrymalis, 51
 Treatment, 51
 Foreign bodies in the vitreous, 321
 Treatment, 322
 Fungus hæmatodes of the eye, 285

 Galvanism, 337

 Gelsemium, 444
 Glaucoma, 355
 Anæsthesia of the cornea, 360
 Anatomy, 355
 Annular posterior synechia, 365
 Anterior synechia, 365
 Causes, 363
 Changes in refraction, 359
 Chemosis, 361
 Contraction of the field of vision, 361
 Course, 363
 Cup of glaucoma, 363
 Cup in atrophy of the nerve, 362
 Diagnosis, 366
 Dilatation and inactivity of the pupil, 360
 Dislocation and injuries of the lens, 365
 Enlargement of the ciliary veins, 361
 Excavation of the optic disc, 362
 Exophthalmos, 361
 Green reflex from the pupil, 360
 Haziness of the cornea, 360
 Haziness of the humors, 361
 Impairment of vision, 363
 Increased tension, 359
 Iridescent vision, 359
 Pain, 361
 Pathology, 358
 Photopsia, 363
 Physiological cup, 362
 Physiology of secretion and excretion, 357
 Prognosis, 366
 Recession of the near point, 358
 Shallow anterior chamber, 360
 Swelling of the lids, 361
 Symptoms, 358
 Glaucoma, varieties of, 367
 Absolutum, 370
 Acuta, 367
 Chronica, 368
 Consecutiva, 370
 Hæmorrhagica, 369
 Primary, 367
 Secondary, 367
 Simplex, 369
 Treatment, 371
 Iridectomy, 371
 Sclerotomy, 372
 Glioma retinae, 285
 Causes, 286
 Course, 285
 Diagnosis, 285
 Pathology, 285
 Prognosis, 286
 Symptoms, 285
 Treatment, 287
 Globular corneæ, 182
 Granular lids, 117

- Granuloma of the iris, 206
 Graphites, 447
 Graves' disease, 58
 Gummata of the lids, 41
 Gummata of the iris, 196

 Hamamelis virginica, 449
 Hæmorrhage in the vitreous, 321
 Hæmorrhage of the optic nerve, 292
 Hæmorrhages in the choroid, 253
 Treatment, 253
 Hæmorrhages into the retina, 269
 Hemeralopia, 311
 Treatment, 311
 Hemianopsia, 313
 Binasal, 313
 Bitemporal, 313
 Causes, 314
 Hemiachromatopsia, 313
 Homonymous, 313
 Horizontal, 313
 Monocular, 313
 Prognosis, 316
 Symptoms, 313
 Treatment, 316
 Hemiptopia, 313
 Hepar sulphur, 450
 Herpes corneæ, 151
 Cause, 151
 Treatment, 151
 Heterochroma, 209
 Heterophoria, 89
 Treatment, 89
 Hippus, 208
 Hordeolum, 28
 Causes, 28
 Course, 28
 Symptoms, 28
 Treatment, 28
 Hyalitis suppurativa, 317
 Course, 318
 Symptoms, 318
 Treatment, 318
 Hydrocotyle, 453
 Hydrops of the anterior chamber, 182
 Hyoseyamus, 453
 Hypæmia, 208
 Hyperæmia iridis, 192
 Hyperæmia of the choroid, 232
 Hyperæmia of the conjunctiva, 97
 Causes, 97
 Course, 98
 Symptoms, 97
 Treatment, 98
 Hyperæmia of the disc, 292
 Treatment, 292
 Hyperæmia retinæ, 259
 Treatment, 260
 Hyperæsthesia retinæ, 283
 Symptoms, 283

 Hyperæsthesia retinæ (*Continued.*)
 Treatment, 284
 Hypericum, 454
 Hyperphoria, 87
 Symptoms, 87
 Hyperesophoria, 83
 Hyperexophoria, 83
 Hypertrophy of the lachrymal gland,
 44

 Ignatia, 454
 Infecting ulcer, 165
 Inflammation of the cornea, 147
 Injuries of the cornea from chemical
 agents, 183
 Foreign bodies, 183
 Injuries of the sclera, 188
 Treatment, 189
 Injury of the optic nerve, 304
 Ipecacuanha, 455
 Iridæmia, 209
 Irido choroiditis, 221
 Causes, 222
 Course, 222
 Prognosis, 223
 Treatment, 223
 Irido choroiditis metastatica, 242
 Causes, 243
 Course, 243
 Pathology, 242
 Prognosis, 244
 Symptoms, 243
 Irido cyleitis, 221
 Iridodialysis, 208
 Iridodonesis, 208
 Iridoncosis, 208
 Iris, 190
 Anatomy, 190
 Circulus iridis major, 190
 Circulus iridis minor, 190
 Dilator pupillæ, 190
 Muscular fibres, 190
 Physiology, 192
 Sphincter pupillæ, 190
 Substantia propria, 190
 Iris, anomalies of the, 208
 Coloboma iridis, 208
 Aniridia, 209
 Iridæmia, 209
 Membrana pupillaris persistens, 209
 Heterochroma, 209
 Corectopia, 209
 Diplokoris, 209
 Polycoria, 209
 Iris, operations on the, 209
 Corelysis, 213
 Granuloma, 206
 Iridavulsion, 213
 Iridectomy, 209
 Iridodesis, 213

- Iris, operations on the (*Continued.*)
 Iridodialysis, 212 "
 Iridotomy, 212 "
- Iritis, 193
 Causes, 195
 Course, 195
 Complications, 196
 Pathology, 193
 Prognosis, 196
 Symptoms, 194
- Iritis, treatment of, 198
 Cold applications, 199
 Complete dilatation, 200
 Iridectomy, 200
 Warmth, 199
- Iritis, varieties of:
 Parenchymatosa, 197
 Plastic, 193
 Purulent, 193
 Rheumatica, 197
 Serous, 193, 198
 Spongiosa, 197
 Syphilitica, 196
 Traumatica, 197
- Iritomy, 212
- Ischæmia retinæ, 280
 Treatment, 281
- Jaborandi, 456
- Kali bichromicum, 459
 Kali carbonicum, 460
 Kali iodatum, 460
 Kali muriaticum, 463
 Kalmia latifolia, 464
 Keratitis dendritica, 168
 Diffuse, 171
 Fascicularis, 149
 Furrow, 168
 Interstitial, 171
 Malarial, 168
 Mycotic, 168
 Phlyctenularis, 148
 Postica, 175
 Punctata, 175
 Pustular, 148
 Scrofulous, 148
 Serpigenous, 165
 Strumous, 148, 171
 Syphilitic, 171
- Keratitis bullosa, 175
 Treatment, 175
- Keratitis, hypopyon, 165
 Causes, 166
 Course, 165
 Symptoms, 165
 Treatment, 167
- Keratitis neuro-paralytica, 170
 Prognosis, 170
 Treatment, 170
- Keratitis pannosa, 149
 Cause, 150
 Course, 150
 Pathology, 149
 Prognosis, 150
 Symptoms, 150
 Treatment, 150
- Keratitis parenchymatosa, 171
 Causes, 172
 Course, 172
 Complications, 173
 Pathology, 171
 Prognosis, 172
 Symptoms, 171
 Treatment, 173
- Keratitis phlyctenularis, 148
 Causes, 149
 Course, 149
 Pathology, 148
 Prognosis, 149
 Symptoms, 148
 Treatment, 149
- Keratitis serpigenous, 165
- Keratoconus, 181
 Treatment, 181
- Kerato globus, 182
- Kreosotum, 465
- Lachesis, 465
- Lachrymal apparatus, 43
 Anatomy, 43
 Canaliculi, 44
 Lachrymal gland, 43
 Lachrymal sac, 44
 Nasal duct, 44
 Puncta, 43
- Lachrymal gland,
 Tumors of, 45
- Lactic acid, 466
- Ledum palustre, 466
- Lesions of the conjunctiva, 142
 Chemical injuries, 142
 Foreign bodies, 142
 Treatment, 142
 Wounds, 142
- Lilium tigrinum, 467
- Lithium carbonicum, 467
- Lupus, 40
 Caustics, 40
 Electrolysis, 40
 Excision, 40
 Scraping, 40
 Treatment, 40
- Luxatio lentis, 352
 Diagnosis, 352
 Prognosis, 353
 Symptoms, 352
 Treatment, 353
- Lycopodium, 468
- Lycopus virginicus, 469

- Malingering, 310
 Meibomian cyst, 38
 Melanoma, 206
 Membrana pupillaris persistens, 209
 Mercurialis perennis, 469
 Mercurius corrosivus, 470
 Mercurius dulcis, 472
 Mercurius iodatus flavus, 473
 Mercurius iodatus ruber, 475
 Mercurius nitrosus, 475
 Mercurius præcipitatus flavus, 476
 Mercurius præcipitatus ruber, 470
 Mercurius solubis, 477
 Mezereum, 480
 Milium, 38
 Molluscum contagiosum, 38
 Moon blindness, 311
 Morbus Basedowii, 58
 Causes, 60
 Course, 59
 Symptoms, 58
 Treatment, 60
 Muriaticum acidum, 481
 Muscæ volitantes, 319
 Muscular asthenopia, 82
 Graduated tenotomy, 90
 Maddox test, 85
 Prentice phorometer, 85
 Stevens phorometer, 83
 Savage test, 86
 Myodesopia, 319
 Mydriasis, 206
 Myosis, 207
 Paralytic, 207
 Spastic, 207
 Spinal, 207

 Nævi, 38
 Naphthalin, 481
 Natrum carbonicum, 481
 Natrum muriaticum, 482
 Natrum salicylicum, 485
 Natrum sulphuricum, 485
 Neuritis descendens, 293
 Neuritis optica, 293
 Causes, 296
 Course, 295
 Pathology, 293
 Prognosis, 297
 Symptoms, 293
 Treatment, 297
 Neuritis optica, varieties of:
 Choked disc, 294
 Neuritis descendens, 295
 Neuro retinitis, 295
 Papillitis, 294
 Peri-neuritis, 295
 Neuritis retro-bulbaris, 297
 Causes, 299
 Pathology, 297

 Neuritis retro-bulbaris (*Continued.*)
 Prognosis, 299
 Symptoms, 298
 Neuro retinitis, 293
 Nictitation, 32
 Night blindness, 311
 Nitricum acidum, 485
 Non-inflammatory ulcer, 167
 Nux moschata, 486
 Nux vomica, 486
 Nystagmus, 81
 Causes, 81
 Prognosis, 81
 Treatment, 81

 Ocular muscles, 62
 Anatomy, 62
 Centre of rotation, 62
 Horopter, 64
 Edema of the retina, 260
 Edematous cellulitis, 53
 Onosmodium virginianum, 491
 Opacities of the cornea, 176
 Arcus senilis, 177
 Congenital, 177
 Gerontoxon, 177
 Prognosis, 177
 Sclerosis, 177
 Treatment, 178
 Opacitates vitrei, 319
 Causes, 320
 Course, 319
 Symptoms, 319
 Treatment, 320
 Muscæ volitantes, 320
 Myodesopia, 320
 Synchisis, 320
 Synchisis scintillans, 320
 Opaque nerve fibres, 291
 Operative treatment of cataract, 338
 Discission, 339
 Iridectomy, 338
 Needle operation, 339
 Ophthalmia neonatorum, 106
 Ophthalmia tarsi, 20
 Opium, 491
 Optic nerve, 288
 Anatomy, 288
 Lamina cribrosa, 290
 Ophthalmoscopic appearance of
 the healthy papilla, 290
 Physiological cup, 291
 Sclerotic ring, 291

 Orbit, 52
 Anatomy, 52
 Tenon's capsule, 52
 Orbital optic neuritis, 297
 Orthophoria, 83
 Oscillation of the eyeballs, 81
 Ossification of the choroid, 252

- Panophthalmitis, 244
 Papillary trachoma, 119
 Differential diagnosis of, 119
 Treatment, 119
 Papillitis, 293
 Papillomata, 38
 Paralysis, external rectus, 66
 Internal rectus, 67
 Inferior oblique, 68
 Inferior rectus, 68
 Superior oblique, 67
 Superior rectus, 67
 Paralysis of ocular muscles, 65
 Causes, 66
 Diagnosis, 66
 Primary deviation, 65
 Secondary deviation, 65
 Symptoms, 65
 Paresis musculus ciliaris, 218
 Galvanism, 219
 Prognosis, 219
 Treatment, 219
 Paris quadrifolia, 492
 Peri-neuritis, 293
 Periostitis orbitæ, 55
 Acute, 55
 Chronic, 55
 Course, 55
 Symptoms, 55
 Persistent hyaloid artery, 323
 Petroleum, 493
 Phlegmonous cellulitis, 53
 Phosphoricum acidum, 494
 Phosphorus, 494
 Physostigma, 496
 Phytolacca decandra, 498
 Pigment degeneration of the retina, 274
 Plantago major, 499
 Prunus spinosa, 499
 Psorinum, 500
 Pterygium, 137
 Membranous, 138
 Sarcomatous, 138
 Causes, 138
 Excision, 138
 Ligation, 138
 Prognosis, 138
 Transplantation, 139
 Treatment, 138
 Ptosis, 29
 Pagenstecher's operation, 30
 Treatment, 29
 Wecker's operation, 30
 Pulsatilla, 501
 Puncta and canaliculi, anomalies of, 45
 Purulent iritis, 197
 Pustular conjunctivitis, 126
 Ranunculus bulbosus, 506
 Remedies :
 Acetic acid, 377
 Aconite, 377
 Agaricus, 380
 Allium cepa, 381
 Alumen exsiccatum, 382
 Alumina, 382
 Ammonium carbonicum, 383
 Amyl nitrite, 384
 Antimonum crudum, 385
 Apis mel., 385
 Argentum met., 388
 Argentum nit., 388
 Arnica, 391
 Arsepicum, 392
 Arum triphyllum, 396
 Asafetida, 396
 Asarum, 396
 Atropine, 396
 Aurum, 398
 Badiago, 402
 Baryta carb., 402
 Baryta iodata, 402
 Belladonna, 403
 Bromium, 407
 Bryonia, 407
 Cactus grand., 409
 Calcarea carb., 409
 Calcarea hypophosph., 412
 Calcarea iodata, 412
 Calcarea phos., 413
 Calcarea pic., 413
 Calendula, 413
 Cannabis sativa, 414
 Cantharis, 415
 Carbo vegetabilis, 416
 Carbolic acid, 416
 Causticum, 417
 Ceanothus amer., 419
 Cedron, 419
 Chamomilla, 420
 Chelidonium majus, 421
 Chimaphilla umbellata, 421
 China, 422
 Chininum mur., 422
 Chininum sulph., 422
 Chloralum, 423
 Chrysophanic acid, 423
 Cicuta virosa, 423
 Cimicifuga, 424
 Cina, 425
 Cinnabaris, 425
 Clematis, 426
 Colocynthis, 427
 Comocladia, 427
 Conium maculatum, 427
 Crocus sativus, 429
 Crotalus horridus, 430
 Croton tiglium, 431

Remedies (*Continued.*)

Candurango, 381
 Cuprum aceticum, 431
 Cuprum alum., 432
 Cuprum sulph., 432
 Digitalis, 432
 Duboisia, 433
 Electricity and galvanism, 435
 Eserine, 439
 Eupatorium perfoliatum, 440
 Euphrasia, 440
 Ferrum, 443
 Ferrum phosphoricum, 443
 Fluoric acid, 443
 Gelsemium, 444
 Graphites, 447
 Hamamelis virginica, 449
 Hepar sulphur, 450
 Hydrocotyle, 453
 Hyoscyamus, 453
 Hypericum, 454
 Ignatia, 454
 Ipecacuanha, 455
 Jaborandi, 456
 Kali bichromicum, 459
 Kali carbonicum, 460
 Kali iodatum, 460
 Kali muriaticum, 463
 Kalmia latifolia, 464
 Kreosotum, 465
 Lachesis, 465
 Lactic acid, 466
 Ledum palustre, 466
 Liliun tigrinum, 467
 Lithium carbonicum, 467
 Lycopodium, 468
 Lycopus virginicus, 469
 Mercurialis perennis, 469
 Mercurius corrosivus, 470
 Mercurius dulcis, 472
 Mercurius iodatus flavus, 473
 Mercurius iodatus ruber, 475
 Mercurius nitrosus, 475
 Mercurius præcipitatus flavus, 476
 Mercurius præcipitatus ruber, 476
 Mercurius solubis, 477
 Mezereum, 480
 Muriaticum acidum, 481
 Naphthalin, 481
 Natrum carbonicum, 481
 Natrum muriaticum, 482
 Natrum salicylicum, 485
 Natrum sulphuricum, 485
 Nitricum acidum, 485
 Nux moschata, 486
 Nux vomica, 486
 Onosmodium virginianum, 491
 Opium, 491
 Paris quadrifolia, 492
 Petroleum, 493

Remedies (*Continued.*)

Phosphoricum acidum, 494
 Phosphorus, 494
 Physostigma, 496
 Physolacca decandra, 498
 Plantago major, 499
 Prunus spinosa, 499
 Psorinum, 500
 Pulsatilla, 501
 Ranunculus bulbosus, 506
 Rhododendron, 507
 Rhus toxicodendron, 507
 Ruta graveolens, 511
 Sanguinaria, 512
 Secale cornutum, 513
 Senega, 513
 Sepia, 514
 Silicea, 517
 Spigelia, 519
 Spongia, 522
 Squilla, 522
 Stannum, 522
 Staphysagria, 523
 Sulphur, 523
 Syphilinum, 530
 Tabacum, 530
 Tellurium, 530
 Terebinthina, 531
 Thuja, 532
 Veratrum viride, 534
 Zincum, 536

Retina, 256

Anatomy, 256

External granular layer, 257
 External limiting membrane, 257
 External molecular layer, 257
 Fibres of Müller, 258
 Internal granular layer, 256
 Internal limiting membrane, 256
 Internal molecular layer, 256
 Layer of ganglion cells, 256
 Layer of rods and cones, 257
 Macula lutea, 258
 Nerve-fibre layer, 256
 Pigment layer, 256
 Vascular supply, 259
 Yellow spot, 258

Retinitis,

Apoplectica, 269
 Central punctate, 273
 Circum-papillaris, 293
 Diabetica, 268
 Diffusa, 260
 Glycosurica, 268
 Leucocythæmica, 268
 Nyctalopica, 263
 Of Bright's disease, 263
 Papillo, 262
 Proliferans, 274
 Punctata albescens, 273

- Retinitis (*Continued.*)
 Renal, 263
 Serosa, 260
 Splenic, 268
- Retinitis albuminurica, 263
 Causes, 265
 Complications, 267
 Course, 265
 Diagnosis, 265
 Pathology, 263
 Prognosis, 266
 Symptoms, 264
 Treatment, 267
- Retinitis hæmorrhagica, 269
 Causes, 270
 Complications, 271
 Prognosis, 271
 Symptoms, 270
 Treatment, 271
- Retinitis pigmentosa, 274
 Causes, 276
 Complications, 276
 Course, 276
 Diagnosis, 276
 Pathology, 274
 Symptoms, 275
 Treatment, 276
- Retinitis simplex, 260
 Causes, 260
 Pathology, 260
 Prognosis, 261
 Rest, 261
 Symptoms, 260
- Retinitis syphilitica, 272
 Course, 272
 Prognosis, 272
 Symptoms, 272
 Treatment, 273
- Rhododendron, 507
 Rhus toxicodendron, 507
 Rodent ulcer, 165
 Rupture of the choroid, 254
 Cause, 254
 Prognosis, 254
- Ruta graveolens, 511
- Sanguinaria, 512
 Sarcoma, 40, 251
 Scalds, 42
 Sciera, 135
 Anatomy, 185
- Sclerectasia posterior, 247
 Scleritis, 186
 Treatment, 186
- Sclerosis of the retina, 274
 Sclerotic choroiditis anterior, 246
 Sclerotic choroiditis posterior, 247
 Causes, 248
 Complications, 249
 Pathology, 247
- Sclerotic choroiditis pos. (*Continued.*)
 Prognosis, 249
 Symptoms, 247
 Treatment, 249
- Scleritis, 186
 Sclerotomy, 372
 Secale cornutum, 513
 Senega, 513
 Senile changes of the choroid, 250
 Sepia, 514
 Silicea, 517
 Snow blindness, 311
 Spasmus musculus ciliaris, 219
 Clonic, 219
 Tonic, 219
 Treatment, 220
- Spigelia, 519
 Spongia, 522
 Squilla, 522
 Squint, 70
 Stannum, 522
- Staphyloma corneæ, 179
 Treatment, 179
- Staphyloma pellucidum, 181
 Staphyloma posticum, 247
 Staphyloma scleræ, 187
 Treatment, 188
- Staphysagria, 523
 Strabismus, 70
 Advancement of the muscle, 79
 Apparent, 71
 Critchett's operation, 79
 Operative treatment, 76
 Subconjunctival tenotomy, 78
 Tenotomy of the internal rectus, 76
 The after treatment, 80
- Strabismus convergens, 71
 Causes, 71
- Strabismus divergens, 74
 Causes, 74
- Strabismus sursum and deorsum vergens, 75
 Treatment, 75
- Stricture ductus lachrymalis, 45
 Causes, 45
 Symptoms, 45
- Stye, 28
- Subconjunctival effusions, 139
 Ecclymosis, 140
 Purulent, 140
 Treatment, 140
- Subconjunctival emphysema, 141
 Sublatio retinæ, 276
- Sulphur, 523
- Symblepharon, 37
 Operations, 37
- Sympathetic ophthalmia, 225
 Causes, 226
 Optico-ciliary neurectomy, 229
 Prognosis, 228

- Sympathetic ophthalmia (*Continued.*)
 Symptoms, 225
 Treatment, 229
- Synchysis, 319
- Synchysis scintillans, 319
- Syphilinum, 530
- Syphilitic ulcers, 41
- Tabacum, 530
- Tarsal cyst, 38
- Tellurium, 530
- Tendon resection, 91
 Contraction, 91
- Tenonitis, 54
 Symptoms, 55
 Treatment, 55
- Terebinthina, 531
- Thuja, 532
- Tinea tarsi, 20
- Toxic amblyopia, 297
- Toxic retro-bulbar neuritis, 299
 Causes, 299
 Prognosis, 300
 Symptoms, 299
 Treatment, 300.
- Traumatic purulent choroiditis, 244.
- Treatment of iritis, 198
- Trichiasis, 32
- Tumores orbitæ, 57
 Electricity, 57
 Treatment, 57
- Tumors of the choroid, 251
 Choroiditis tuberculosis, 251
 Tubercles, 251
- Tumors of the conjunctiva, 143
 Angiomata, 144
 Cysts, 144
 Carcinoma, 145
 Cysticercus, 145
 Dermoid tumors, 143
 Ectopic tumors, 144
 Epitheliomata, 144
 Entozoon, 145
 Fibromata, 144
 Fleshy excrescences, 144
 Gummata, 145
 Lipomata, 143
 Lupus, 145
 Melano sarcoma, 144
 Osteomata, 144
 Pinguecula, 143
 Pigment spots, 145
 Sarcoma, 144
 Syphilitic ulcerations, 145
- Tumors of the conjunctiva (*Continued.*)
 Vascular tumors, 144
- Tumors of the cornea, 184
- Tumors of the iris, 205
 Epidermoid cysts, 205
 Granuloma, 206
 Melanoma, 206
 Sarcoma, 206
 Serous cysts, 205
 Treatment, 206
 Tubercles, 206
- Tumors of the optic nerve, 304
 Successful operation, 305
 Symptoms, 305
 Treatment, 305
- Tuberculosis conjunctivæ, 141
 Treatment, 142
- Ulcus corneæ, 151
 Causes, 154
 Course, 154
 Paracentesis, 157
 Pathology, 152
 Prognosis, 155
 Results, 155
 Symptoms, 153
 Treatment, 155
- Ulcus corneæ serpens, 165
- Varieties of glaucoma, 367
- Veratrum viride, 534
- Vitreous body, 317
 Anatomy, 317
 Hyaloid membrane, 317
 Lenticula fossa, 317
- Warts, 38
- Wounds, 42
 Treatment, 42
- Wounds and injuries of the orbit, 58
 Treatment, 58
- Wounds of the cornea, 183
 Treatment, 183
- Xanthelasma, 38
- Xerosis conjunctivæ, 137
 Partial, 137
 Parenchymatous, 137
 Treatment, 137
- Xerosis glabra, 137
- Xerophthalmia, 137
- Zincum, 536
- Zonule of Zinn, 325

