

27-6-2024

Cutaneous warts treated with a single dose of the homoeopathic medicine Carcinisin 200C: An evidence-based case report

Sivakumar K

National Homoeopathy Research Institute in Mental Health (NHRIMH), Kottayam, Kerala, India, drshivasree@gmail.com

Mamatha Mohan

National Homoeopathy Research Institute in Mental Health (NHRIMH), Kottayam, Kerala, India, mamatha14mohan@gmail.com

Author(s) ORCID Identifier:

<https://orcid.org/0000-0003-0014-2968>


Follow this and additional works at: <https://www.ijrh.org/journal>

 Part of the [Homeopathy Commons](#)

How to cite this article

Sivakumar K, Mohan. Cutaneous warts treated with a single dose of the homoeopathic medicine Carcinisin 200C: An evidence-based case report. Indian J Res Homoeopathy 2024;18:140-146.

This Case Report is brought to you for free and open access by Indian Journal of Research in Homoeopathy. It has been accepted for inclusion in Indian Journal of Research in Homoeopathy by an authorized editor of Indian Journal of Research in Homoeopathy. For more information, please contact ijrhone@ijrhonline@gmail.com.



Cutaneous warts treated with a single dose of the homoeopathic medicine Carcinosin 200C: An evidence-based case report

Abstract

Introduction: Cutaneous warts are hyperkeratotic protrusions over the skin caused by human papilloma virus (HPV). These are common throughout the world. Cutaneous warts can occur at any age but are unusual in early childhood and infancy. Warts are often diagnosed clinically on physical examination, but some dysplastic lesions may require laboratory confirmation of HPV. Spontaneous clearance is not always possible, and offering a reliable prognosis to the individual case is impossible. Even though warts are frequently encountered in the day-to-day practice of homoeopathy, and the results are promising, there are limited research studies available in the online database. **Case Summary:** A 5-year-old female child was brought to OPD of National Homoeopathy Research Institute in Mental Health, Kottayam for the treatment of warts on different parts of body. After careful case-taking and construction of the totality of symptoms, *Carcinosin 200C* was prescribed in a single dose. In response to the medicine, warts began to reduce in size and eventually fell off in two months. The causal attribution for the outcome was assessed using MONARCH inventory for homoeopathy, which scored +9, showing the positive relationship between the intervention and the outcome. Therefore, this case demonstrates the positive role of individualised Homoeopathy in treating cutaneous warts.

Acknowledgments and Source of Funding

Nil

Cutaneous warts treated with a single dose of the homoeopathic medicine *Carcinosin 200C*: An evidence-based case report

K. Sivakumar^{1*} , Mamatha Mohan²

¹National Homoeopathy Research Institute in Mental Health (NHRIMH), Kottayam, Kerala, India, ²Department of Practice of Medicine, NHRIMH, Kottayam, Kerala, India

Abstract

Introduction: Cutaneous warts are hyperkeratotic protrusions over the skin caused by human papilloma virus (HPV). These are common throughout the world. Cutaneous warts can occur at any age but are unusual in early childhood and infancy. Warts are often diagnosed clinically on physical examination, but some dysplastic lesions may require laboratory confirmation of HPV. Spontaneous clearance is not always possible, and offering a reliable prognosis to the individual case is impossible. Even though warts are frequently encountered in the day-to-day practice of homoeopathy, and the results are promising, there are limited research studies available in the online database. **Case Summary:** A 5-year-old female child was brought to OPD of National Homoeopathy Research Institute in Mental Health, Kottayam for the treatment of warts on different parts of body. After careful case-taking and construction of the totality of symptoms, *Carcinosin 200C* was prescribed in a single dose. In response to the medicine, warts began to reduce in size and eventually fell off in two months. The causal attribution for the outcome was assessed using MONARCH inventory for homoeopathy, which scored +9, showing the positive relationship between the intervention and the outcome. Therefore, this case demonstrates the positive role of individualised homoeopathy in treating cutaneous warts.

Keywords: *Carcinosin*, Homoeopathy, Human Papilloma Virus (HPV), Periungual warts, Plane warts, MONARCH

INTRODUCTION

Cutaneous warts are benign tumours caused by human papilloma virus (HPV), visible as distinct hyperkeratotic protrusions. These are common throughout the world. Cutaneous warts can occur at any age but are unusual in early childhood and infancy. Earlier studies have estimated 2–30% of children and young adults presented with warts. Typical warts may be symptomless but tender when growing beneath the nail plate and fissured. Periungual warts are common around the nails, especially beneath the nail and nail folds and can significantly disturb nail growth. Plane warts are flat, marginally raised and generally skin-coloured or greyish yellow but may be pigmented.^[1,2] On clinical examination, warts may be flat, rough and painful papulonodular epidermal lesions over different body parts.^[3]

Warts are often diagnosed clinically on physical examination, but subclinical dysplastic protrusions may require a

microscopic examination of HPV for confirmation, including histopathology and PCR.^[4] Unpredicted clearance of warts can occur, but offering a definite prognosis is difficult and not always possible.^[1] The most common treatments comprise destroying the warty growth on the epidermis infected with the virus. Topical treatments include salicylic acid, formalin, occlusion, caustics and vitamin D analogues, cryotherapy and laser, hyperthermia and surgery.^[1] A randomised controlled trial conducted in this condition earlier could not conclude a favourable effect of homoeopathy, thus suggesting a sufficiently focused, well-designed clinical trial for this. Hence, a considerable research gap exists in exploring the efficacy of

***Address for correspondence:** K. Sivakumar,
National Homoeopathy Research Institute in Mental Health,
Kottayam, Kerala, India.
E-mail: drshivasree@gmail.com

Received: 24 July 2023; **Accepted:** 10 June 2024

Access this article online

Quick Response Code:



Website:
www.ijrh.org

DOI:
10.53945/2320-7094.1925

This is an open access journal, and articles are distributed under the terms of the Creative Commons Attribution-NonCommercial-ShareAlike 4.0 License, which allows others to remix, tweak, and build upon the work non-commercially, as long as appropriate credit is given and the new creations are licensed under the identical terms.

How to cite this article: Sivakumar K, Mohan. Cutaneous warts treated with a single dose of the homoeopathic medicine *Carcinosin 200C*: An evidence-based case report. *Indian J Res Homoeopathy* 2024;18:140-146.

homeopathic medicines in treating warts. Common remedies for treating warts include *Thuja occidentalis*, *Nitric acid*, *Causticum*, *Calcarea carbonica*, *Natrum muriaticum* and *Dulcamara*.^[5] Even though warts are local diseases, they should be treated with internal medicine based on the individualisation of the case.^[6] Oza have described the homeopathic concept and treatment of warts.^[7] Sahoo *et al* observed that selecting the right medicine with suitable potency is significant in its treatment.^[8] This case was selected to report the role of homeopathic medicine in treating cutaneous warts through a single dose.

PATIENT INFORMATION

A 5-year-old, school-going female child presented with multiple warts on her left thumb, behind the right ear, over the right leg and on both corners of her mouth in the OPD of National Homoeopathy Research Institute in Mental Health, Kottayam, Kerala, India. The complaints started one year back, which her parents attributed to her habit of sucking her thumbs, leading to skin hardness and then small warty growths appeared over the left thumb. Later, warts also extended to other locations such as behind the right ear, angle of the mouth and lastly at the right leg. She was reported to have taken treatment from the nearby Ayurveda and Homoeopathy dispensaries, as well as tried external ointments, cauterisation and warts-specific medicines, without any relief. Later, warts also developed behind her right ear and right leg and on the corners of her mouth.

The patient had a history of suffering from chickenpox at the age of one year. Her family history revealed nothing significant, other than that her grandmother's sister had a history of breast cancer.

The child lived with her parents in a rural village in the Kottayam district of Kerala. She studied in upper kindergarten at a lower primary school. The child's parents mentioned that the child was social and well-behaved with others.

Clinical findings

On inspection, the wart on the left thumb was spread around the nail, and the nail was not visible clearly. The nail looked distorted, not painful, but tender on pressure. The wart on the right leg and back of the right ear was flat and hard to touch. Warty growths on the corners of the mouth were soft and fleshy. There were hangnails visible on the affected and other fingers.

Generals

The patient sought company and was shy to talk to. The child was interested in drawing and singing, used to perform singing on stage, liked to participate in drawing competitions and received appreciation on many occasions. She was obedient and helpful but sensitive to rudeness and scolding. The child had the desire to travel, but developed nausea and vomiting while traveling on a bus.

The appetite of the child was good, while the thirst was increased, and she used to drink a little too often. She had a

sound sleep and preferred lying on her abdomen. She had a strong desire for chocolates, ice creams and sweets. Her bowels were constipated with hard stool, which she passed once in two days. Thermally chilly, she had an aversion to being fanned and used to bathe in warm water.

Diagnostic assessment

Based on clinical examination, the case was diagnosed as multiple cutaneous warts.

Therapeutic intervention

All the symptoms obtained from detailed case-taking were analysed, and the most characteristic symptoms were converted to rubrics, followed by repertorisation with Synthesis Treasure, third edition 2009V, Radar opus 2.2.16, as shown in Figure 1. The individualised homeopathy medicine, *Carcinosin*, was given based on the totality of symptoms and repertorisation in consultation with Materia Medica.^[9,10] A single homeopathic medicine, *Carcinosin* in 200 potency of the centesimal scale, in a single dose, was the first prescription. Four medicated globules sized 30 were administered in a pinch of sugar milk on an empty stomach. The medicine was prescribed for a limited duration as per the need and was followed by placebo pills for rest of the period.

The parents of the child were advised to take preventive measures such as maintaining hygiene and avoiding thumb sucking to prevent reinfection. The complaints of the patient were assessed every two weeks, or as required. The detailed follow-up and outcomes are summarised in Table 1. No adverse effects were reported during the treatment.

Follow-up and outcomes

After taking medicine, warts on the right leg and back of the right ear fell off, while the size of the wart on the left thumb reduced. After two months of treatment, all warts completely disappeared. Total improvement happened with a single dose of *Carcinosin* 200C [Figure 2]. No recurrence of lesions developed in the follow-up period till the last visit. The MONARCH^[11] score was +9, close to the maximum score of +13, suggesting a positive relationship between *Carcinosin* 200C and the disappearance of cutaneous warts.

DISCUSSION

Cutaneous warts are a common skin condition caused by viruses, and they range from a simple ailment to a troublesome, chronic complaint.^[12] Sucking the fingers and thumb for a long time leads to the hardness of the skin, and it is one of the common reasons for developing cutaneous warts.^[1] Usually, warts are presented as external local maladies classified under one-sided diseases. They often have an individualistic and immunological basis as well as familial tendencies. Warts are included under sycosis miasm. Some homeopathic medicines are effective in treating warts without any harmful side effects compared to the treatment in conventional medical practice.^[8] A double-blind and randomised trial could not find the efficacy

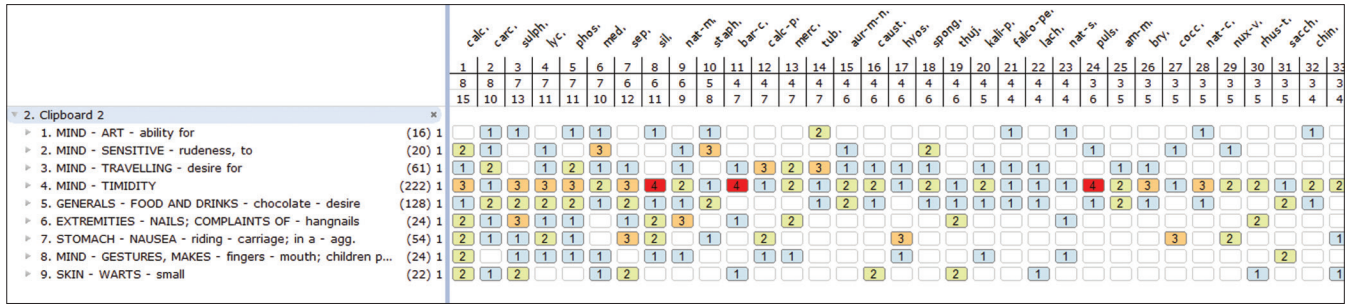


Figure 1: Repertory sheet showing repertorisation of the case

Table 1: The timeline, including follow-up			
Date	Sign and Symptoms	Prescription	Justification
26 April 2023	Multiple warts on both thumbs, behind the right ear, over the right leg. Constipation.	<i>Carcinosin</i> 200C/1 Dose	As per the totality of symptoms and repertorisation.
10 May 2023	Warts on the left thumb reduced the size. The wart on the right leg, on the right thumb, disappeared. Constipation relieved. Soft stool passed regularly.	No medicine was prescribed for 2 weeks as the improvement continued	Complaints relieved.
24 May 2023	The wart on the mouth's left angle disappeared, and the right angle one was reduced in size. Warts over the thumbs partially disappeared. Travel sickness not reported after first prescription.	No medicine was prescribed for 2 weeks as the improvement continued	Warts improved.
7 June 2023	Warts on all locations except the right angle of the mouth disappeared.	No medicine was prescribed for 2 weeks as the improvement continued	Amelioration of complaints.
21 June 2023	Warts on all locations disappeared.	No medicine was prescribed for 2 weeks as the improvement continued	
12 July 2023	No warts present over the body.	No medicine was prescribed for 2 weeks as the improvement continued	
24 July 2023	No complaints.	No medicine was prescribed for 2 weeks as the improvement continued	
16 August 2023	No complaints.	No medicine was prescribed for 2 weeks as the improvement continued	
15 September 2023	No complaints.	No medicine was prescribed for 2 weeks as the improvement continued	
17 November 2023	No complaints.	No medicine was prescribed for 2 weeks as the improvement continued	

of individualised homeopathic medicine (IHM) in comparison to the placebo but stated that well-designed clinical trials are warranted to prove the efficacy.^[5] In another randomised controlled trial with 162 cases, *Thuja occidentalis*, *Nitricum acidum* and *Antimonium crudum* were found effective in treating warts.^[13]

One of the previous case reports has provided insight into selecting IHM to treat cutaneous warts.^[8] In the present case, the child presented with multiple warts on different body parts. Cauterisation and specific Ayurveda and homeopathic medicines were tried, but without significant relief. After a careful case history, totality of symptoms and repertorisation, *Calcarea carb.* and *Carcinosin* scored the top positions in the repertorisation chart. On further analysis, we excluded *Calcarea carb.* with the absence of typical symptoms of head sweat, fat, flabby physical appearance, delayed milestones and other premature conditions, as generally seen in a *Calcarea carb.* patient. Further enquiry revealed a cancer history in

the family. In *Materia Medica Viva*,^[10] it is mentioned that warts are repeatedly cured by *Carcinosin*, be these warts on lips, on the back of hand, on fingers, adjacent to fingernails, etc. Furthermore, warty growth spreads around the nail with distortion of the nail such as irregular, proliferative growth as we see in non-benign lesions. Considering all the above indications, *Carcinosin* 200C was given in a single dose. In this case, we obtained encouraging results with *Carcinosin*, whereas specific homeopathic medicines used previously could not provide striking relief. After administering *Carcinosin* 200C, all warts disappeared within two months, and the distorted appearance of the skin over the left thumb cleared and healthy skin was restored [Figure 2]. In this case, 200C potency has been selected considering the child's age, vitality and mental activity. The causal attribution for the outcome changes was assessed using Modified Naranjo Criteria for Homoeopathy (MONARCH) The score was +9, close to the maximum (+13), showing the positive relationship between

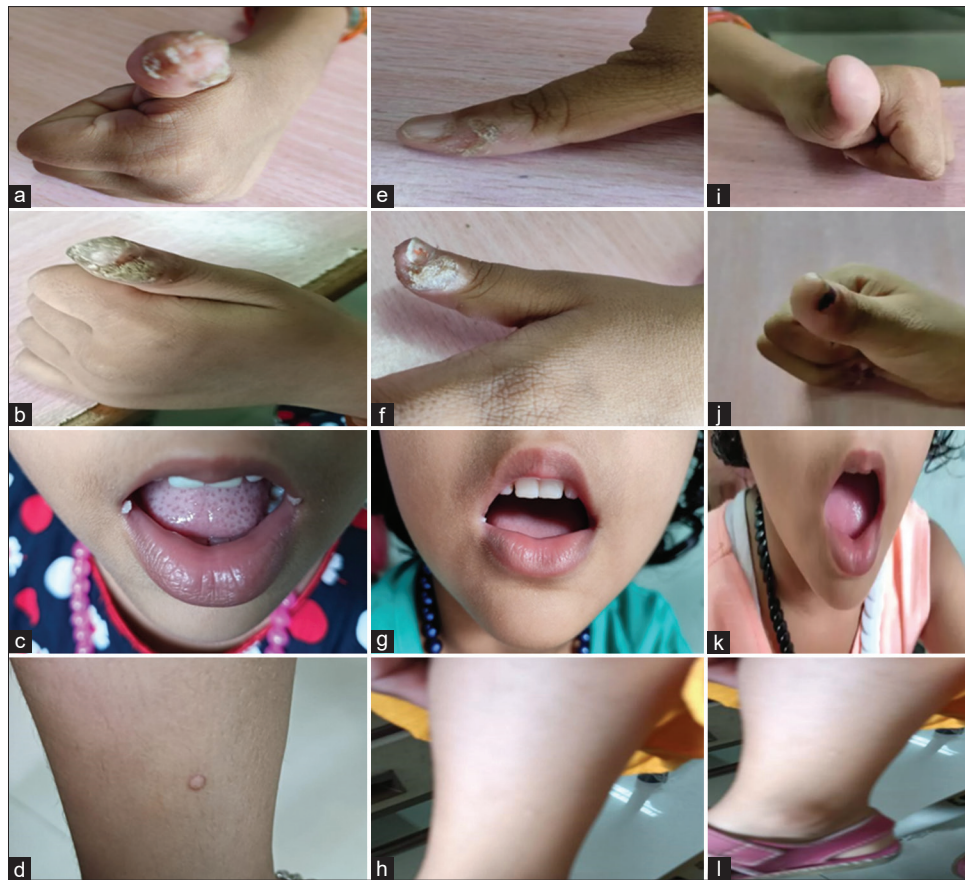

Figure 2: Warts (a-d) before treatment (24 April 2023), (e-h) during treatment (24 May 2023) and (i-l) after treatment (21 June 2023)

Table 2: MONARCH Inventory (Improved Version of the Modified Naranjo Criteria for Homeopathy Case Report)

S. No.	Domains	Yes	No	Not sure or N/A	Justification
1	Was there any improvement in the main symptom or condition for which homeopathic medicine was prescribed?	+2			Warts reduced in size after medicine
2	Did the clinical improvement occur within a plausible timeframe relative to the medicine intake?	+1			Warts disappeared within 1 month
3	Was there a homeopathic aggravation of symptoms?			0	Not sure
4	Did the effect encompass more than the main symptom or condition (i.e. were other symptoms, not related to the main presenting complaint, improved or changed)?	+1			Along with warts, constipation is also relieved.
5	Did overall well-being improve? (suggest using a validated scale or mention about changes in physical, emotional and behavioural elements)	+1			Generally, the child became active
6	Direction of cure: did some symptoms improve in the opposite order of the development of symptoms of the disease?	+1			The last developed warts on the right leg disappeared first.
7	Direction of cure: did at least one of the following aspects apply to the order of improvement in symptoms? -from organs of more importance to those of less importance? -from deeper to more superficial aspects of the individual? -from the top downward?			0	Not sure
8	Did 'old symptoms' (defined as non-seasonal and non-cyclical symptoms previously thought to be resolved) reappear temporarily during improvement?		0		Not observed
9	Are there alternative causes (i.e. other than the medicine) that, with a high probability, could, have produced the improvement? (consider the course of disease, other forms of treatment and other clinically relevant interventions)		+1		Not identifiable
10	Was the health improvement confirmed by any objective evidence? (e.g. investigations, clinical examination, etc.)	+2			Confirmed by Photographs
11	Did repeat dosing, if conducted, create similar clinical improvement?		0		Not done

Total score (Maximum score+13, Minimum -6) = +9

the intervention and the outcome [Table 2], and thus proving the casual relationship between the homeopathic medicine administered and the outcome in this case.^[11] Warts are, referred to as a local disease in Organon of medicine aphorism 189 and 193, and local maladies cannot develop, persist and become worse without some internal cause.^[14] Hence, for treating these, internal medicine should be selected based on the totality of symptoms. Moreover, *Carcinosin* is an excellent medicine for the warts of the hand and other sites.^[10] Randomised controlled trials are the gold standard for evaluating treatment efficacy in modern medicine. However, they may not be suitable for Homeopathy due to individualisation in the selection of medicine, and hence, considerable importance may be given to the case reports in Homeopathy.^[15]

CONCLUSION

A complete disappearance of cutaneous warts within two months of homeopathic treatment is evidence of the definitive role of *Carcinosin* in the cure of warts. Since it is a single case report, a well-designed study with large sample size is recommended to prove the effectiveness of homeopathic remedies for treating cutaneous warts.

Informed assent

The child's father had given a written, informed consent after the child was made to understand about reporting this case and related clinical information and images in the journal.

Declaration of patient consent

The child was happy and expressed gratitude for the successful treatment. The child's father said, 'I did not expect such quick results and complete recovery from the warts!'

Financial support and sponsorship

Nil.

Conflict of interest

None declared.

REFERENCES

1. Arthur R. Rook's Textbook of Dermatology. West Sussex: John Wiley and Sons Ltd.; 2016. p. 616-24.
2. Cardoso JC, Calonje E. Cutaneous manifestations of human papillomaviruses: A review. *Acta Dermatovenerol Alp Pannonica Adriat* 2011;20:145-54.
3. Prusty AK, Bhandari P. A co-morbid condition of warts and vitiligo treated with individualized Homeopathy: An evidence-based case report. *Homeopathy* 2022;111:139-46.
4. Shah SN. *API Textbook of Medicine*. Mumbai: The Association of Physician of India; 2009.
5. Dey S, Hashmi S, Saha S, Mandal M, Shaikh AR, Agrawal, E, *et al*. A randomized, double-blind, placebo-controlled, pilot trial of individualized homeopathic medicines for cutaneous warts. *Homeopathy* 2021;110:149-59.
6. Suri P, Chandra KK. Role of intercurrent remedy in treatment of Warts. *Homeopath Links* 2022. Available from: <https://www.thieme-connect.de/products/ejournals/html/10.1055/s-0041-1736437> [Last accessed on 25 May 2024].
7. Oza PM. Homeopathic management of warts. *Indian J Drugs Dermatol* 2016;2:45-47.
8. Sahoo AR, Barik B, Hati AK, Paital B. Right potency matters: A case report of homeopathic treatment of verruca palmaris. *Homeopath Links* 2018;31:204-8.
9. Schroyens F. *Synthesis Treasure*. Belgium: Radar Opus; 2009.
10. Boericke W. *Pocket Manual of Homeopathic Materia Medica and Repertory*. New Delhi: B. Jain Publishers; 2018.
11. Lamba CD, Gupta VK, Van Haselen RA, Rutten L, Mahajan N, Molla AM, *et al*. Evaluation of the modified Naranjo Criteria for assessing causal attribution of clinical outcome to homeopathic intervention as presented in case reports. *Homeopathy* 2020;109:191-7.
12. Kwok CS, Gibbs S, Bennett C, Holland R, Abbott R. Topical treatments for cutaneous warts. *Cochrane Database Syst Rev* 2012;2012:CD001781.
13. Labrecque M, Audet D, Latulippe LG, Drouin J. Homeopathic treatment of plantar warts. *CMAJ* 1992;146:1749-53.
14. Hahnemann CF. *Organon of Medicine*. New Delhi: B. Jain Publishers; 2008.
15. Mahajan N, Mahajan A, Bhinda A, Salodiya S. Homeopathic treatment of viral warts with *Calcarea phosphorica*. *Indian J Res Homeopathy* 2020;14:279-86.

Verrues cutanées traitées avec une dose unique du médicament homéopathique *Carcinosin* 200C – Un rapport de cas fondé sur des preuves

Introduction: Les verrues cutanées sont des protubérances hyperkératosiques sur la peau causées par le virus du papillome humain (VPH). Ceux-ci sont courants dans le monde entier. Les verrues cutanées peuvent survenir à tout âge, mais sont inhabituelles dans la petite enfance et la petite enfance. Les verrues sont souvent diagnostiquées cliniquement à l'examen physique, mais certaines lésions dysplasiques peuvent nécessiter une confirmation en laboratoire du VPH. Une clairance spontanée n'est pas toujours possible, et il est impossible d'offrir un pronostic fiable au cas individuel. Même si les verrues sont fréquemment rencontrées dans la pratique quotidienne de l'homéopathie et que les résultats sont prometteurs, il existe peu d'études de recherche disponibles dans la base de données en ligne. **Résumé de cas:** Une fillette de 5 ans a été amenée à l'OPD de l'Institut national de recherche en homéopathie en santé mentale, à Kottayam, pour le traitement des verrues sur différentes parties du corps. Après une prise de cas minutieuse et une construction de l'ensemble des symptômes, *Carcinosin* 200C a été prescrit en une seule dose. En réponse au médicament, les verrues ont commencé à diminuer en taille et ont fini par tomber en deux mois. L'attribution causale du critère de jugement a été évaluée à l'aide de l'inventaire MONARCH pour l'homéopathie, qui a obtenu un score de +9, montrant la relation positive entre l'intervention et le résultat. Par conséquent, ce cas démontre le rôle positif de l'homéopathie individualisée dans le traitement des verrues cutanées.

Hautwarzen, die mit einer Einzeldosis des homöopathischen Arzneimittels *Carcinosin* 200C behandelt wurden – Ein evidenzbasierter Fallbericht

Einleitung: Hautwarzen sind hyperkeratotische Vorsprünge über der Haut, die durch das humane Papillomavirus (HPV) verursacht werden. Diese sind auf der ganzen Welt verbreitet. Hautwarzen können in jedem Alter auftreten, sind aber in der frühen Kindheit und im Säuglingsalter ungewöhnlich. Warzen werden oft klinisch bei der körperlichen Untersuchung diagnostiziert, aber einige dysplastische Läsionen erfordern möglicherweise eine Laborbestätigung von HPV. Eine spontane Aufklärung ist nicht immer möglich, und eine zuverlässige Prognose für den Einzelfall ist unmöglich. Obwohl Warzen in der täglichen Praxis der Homöopathie häufig vorkommen und die Ergebnisse vielversprechend sind, gibt es in der Online-Datenbank nur begrenzte Forschungsstudien. **Fallzusammenfassung:** Ein 5-jähriges Mädchen wurde zur Behandlung von Warzen an verschiedenen Körperteilen in das OPD des National Homoeopathy Research Institute in Mental Health, Kottayam, gebracht. Nach sorgfältiger Fallaufnahme und Konstruktion der Gesamtheit der Symptome wurde *Carcinosin* 200C in einer Einzeldosis verschrieben. Als Reaktion auf das Medikament begannen die Warzen an Größe zu verlieren und fielen schließlich innerhalb von zwei Monaten ab. Die kausale Zuschreibung für das Ergebnis wurde anhand des MONARCH-Inventars für Homöopathie bewertet, das +9 Punkte erzielte und den positiven Zusammenhang zwischen der Intervention und dem Ergebnis zeigte. Daher zeigt dieser Fall die positive Rolle der individualisierten Homöopathie bei der Behandlung von Hautwarzen.

होम्योपैथी दवा कार्सिनोसिन 200C की एक खुराक से त्वचा के मससों का इलाज - एक साक्ष्य-आधारित केस रिपोर्ट

परिचय: त्वचीय मससे ह्यूमन पैपिलोमा वायरस (HPV) के कारण उभरते हैं। त्वचा पर मससे किसी भी उम्र में हो सकते हैं लेकिन बचपन और शैशवावस्था में असामान्य होते हैं। मससों का अक्सर शारीरिक परीक्षण के बाद चिकित्सकीय निदान किया जाता है, लेकिन कुछ डिसप्लास्टिक घावों के लिए HPV की प्रयोगशाला पुष्टि की आवश्यकता हो सकती है। स्वयं निकासी हमेशा संभव नहीं होती है, और इस मामले में विश्वसनीय पूर्वानुमान लगाना असंभव है। भले ही होम्योपैथी में मससों का अक्सर इलाज किया जाता है, और उसके परिणाम आशाजनक हैं, ऑनलाइन डेटाबेस में सीमित अध्ययन ही उपलब्ध हैं। **केस सारांश:** एक 5 वर्षीय बच्ची को शरीर के विभिन्न हिस्सों पर मससों के इलाज के लिए राष्ट्रीय मानसिक स्वास्थ्य अनुसंधान संस्थान, कोट्टायम की ओपीडी में लाया गया। सावधानीपूर्वक केस लेने और लक्षणों की समग्रता के निर्माण के बाद, कार्सिनोसिन 200 C की एक खुराक दी गई। दवा के प्रभाव से मससे आकार में कम होने लगे और अंततः दो महीने में गिर गए। होम्योपैथी के लिए मोनार्क इन्वेंटी का उपयोग करके परिणाम का मूल्यांकन किया गया था, जिसमें +9 स्कोर आया, जो हस्तक्षेप और परिणाम के बीच सकारात्मक संबंध दर्शाता है। इसलिए, यह मामला त्वचीय मससों के उपचार में व्यक्तिगत होम्योपैथी की सकारात्मक भूमिका को प्रदर्शित करता है।

Verrugas cutáneas tratadas con una dosis única del medicamento homeopático *Carcinosin* 200 – Un informe de caso basado en la evidencia

Introducción: Las verrugas cutáneas son protuberancias hiperqueratósicas sobre la piel causadas por el virus del papiloma humano (VPH). Estos son comunes en todo el mundo. Las verrugas cutáneas pueden ocurrir a cualquier edad, pero son inusuales en la primera infancia y la infancia. Las verrugas a menudo se diagnostican clínicamente en el examen físico, pero algunas lesiones displásicas pueden requerir la confirmación de laboratorio del VPH. La eliminación espontánea no siempre es posible, y es imposible ofrecer un pronóstico fiable para el caso individual. A pesar de que las verrugas se encuentran con frecuencia en la práctica diaria de la homeopatía, y los resultados son prometedores, hay estudios de investigación limitados disponibles en

la base de datos en línea. **Resumen del caso:** Una niña de 5 años fue llevada al OPD del Instituto Nacional de Investigación de Homeopatía en Salud Mental, Kottayam para el tratamiento de verrugas en diferentes partes del cuerpo. Después de una cuidadosa toma de casos y la construcción de la totalidad de los síntomas, se prescribió *Carcinosin* 200C en una sola dosis. En respuesta al medicamento, las verrugas comenzaron a reducirse de tamaño y finalmente se cayeron en dos meses. La atribución causal del resultado se evaluó mediante el inventario MONARCH para homeopatía, que obtuvo una puntuación de +9, mostrando la relación positiva entre la intervención y el resultado. Por lo tanto, este caso demuestra el papel positivo de la homeopatía individualizada en el tratamiento de las verrugas cutáneas.

用单剂量顺势疗法药物癌素 200 治疗的皮肤疣 - 循证病例报告

简介: 皮肤疣是由人瘤病毒 (HPV) 引起的皮肤角化过度突起。这些在世界范围内很常见。皮肤疣可发生于任何年龄，但在儿童早期和婴儿期并不常见。疣通常在体格检查中被临床诊断出来，但一些发育不良的病变可能需要 HPV 的实验室确认。自发清除并不总是可能的，并且不可能为个别病例提供可靠的预后。尽管在顺势疗法的日常实践中经常遇到疣，并且结果很有希望，但在线数据库中可用的研究有限。**病例摘要:** 一名 5 岁女童被带到 Kottayam 国家顺势疗法心理健康研究所的 OPD 治疗身体不同部位的疣。经过仔细的病例处理和整体症状的构建，以单剂量开具了致癌素 200C。作为对药物的反应，疣开始变小，最终在两个月内脱落。使用顺势疗法的 MONARCH 量表评估结果的因果归因，得分为 +9，显示干预与结果之间的正相关关系。因此，该病例证明了个体化顺势疗法在治疗皮肤疣方面的积极作用。